
Leibniz Institute for Zoo and Wildlife Research

(IZW)

Berlin, Germany

&

European Association of Zoo and Wildlife Veterinarians

(EAZWW)

Liebefeld-Berne, Switzerland

**PROCEEDINGS OF THE
INTERNATIONAL CONFERENCE ON
DISEASES OF
ZOO AND WILD ANIMALS
2014**

May 28th – 31st, 2014
Warsaw / Poland

Edited by

Mirjam Grobbel
Anke Schumann

ISSN 1868 - 5846

The contributions included in this volume were carefully checked and revised. Nevertheless, authors and editors are unable to guarantee the correctness of all presented data, conclusions and advice and do not accept liability for possible printings errors. The editors gratefully acknowledge the willingness of the following colleagues for reviewing the manuscripts submitted for this conference:

Dr. Bernardino, Lisbon, Portugal; DVM Bertelsen, Frederiksberg, Denmark; PD Dr. Borchers, Berlin, Germany; Dr. Bouts, Brugelette, Belgium; Prof. Dr. Clauss, Zurich, Switzerland; Dr. Czirjak, Berlin, Germany; Dr. Dehnhard, Berlin, Germany; Prof. Dr. Eulenberger, Leipzig, Germany; Dr. H. Fernández, Barcelona, Spain; Dr. M. Fernández, Madrid, Spain; Dr. Fielding, Blackpool, UK; Dr. Fritsch, Berlin, Germany; Dr. Grobbel, Berlin, Germany; Prof. Dr. Gröne, Utrecht, The Netherlands; Dr. Gruber-Dujardin, Göttingen, Germany; Prof. Dr. Gumpenberger, Vienna, Austria; Dr. Haider, Berlin, Germany; Dr. Heckers, Bad Kissingen, Germany; Dr. IJzer, Utrecht, The Netherlands; Dr. J. Kaandorp, Hilvarenbeek, The Netherlands; Dr. Kik, Utrecht, The Netherlands; Dr. König, Gießen, Germany; Prof. Dr. Krautwald-Junghanns, Leipzig, Germany; Dr. Krone, Berlin, Germany; Dr. Kummrow, Wuppertal, Germany; Dr. Kutzer, Frankfurt/Oder, Germany; Dr. Lawrenz, Wuppertal, Germany; Dr. Lécú, Paris, France; Prof. Dr. Lierz, Gießen, Germany; Prof. Dr. Liesegang, Zurich, Switzerland; Dr. Lobo Fernandes, Lisbon, Portugal; Dr. Lübke-Becker, Berlin, Germany; Dr. Marschang, Stuttgart, Germany; Dr. Jean Meyer, Villach, Austria; Dr. Möller, Kolmården, Sweden; PD Dr. Moser, Jena, Germany; Dr. Karin Müller, Berlin, Germany; Dr. Kerstin Müller, Berlin, Germany; Dr. Mutschmann, Berlin, Germany; Dr. Ochs, Berlin, Germany; Dr. Ortmann, Berlin, Germany; J. Painer, Berlin, Germany; DVM Pasmans, Merelbeke, Belgium; Dr. Pauly, Berlin, Germany; Dr. Rudnick, Rostock, Germany; Dr. Sanderson, Upton-by-Chester, UK; Dr. Schares, Wusterhausen, Germany; Dr. Schmäschke, Leipzig, Germany; D. Schrudde, Münster, Germany; Dr. Silinski-Mehr, Münster, Germany; DVM Sós, Budapest, Hungary; Dr. Speck, Leipzig, Germany; Dr. Spiezio, Bussolengo, Italy; Prof. Dr. Steinhagen, Hannover, Germany; Dr. Strauss, Berlin, Germany; Dr. Szentiks, Berlin, Germany; Dr. Unwin, Chester, UK; Dr. van Zijll Langhout, Malelane, South Africa; Dr. Vodička, Praha, Czech Republic; Prof. Dr. von Samson-Himmelstjerna, Berlin, Germany; Prof. Dr. Weissengruber, Vienna, Austria; Dr. Wenker, Basel, Switzerland; Dr. Wibbelt, Berlin, Germany

This is also the continuation of the 7th “Proceedings of the Meeting of the EAZWV” (2008) and the “Erkrankungen der Zootiere – Verhandlungsbericht des 43. Internationalen Symposiums über die Erkrankungen der Zoo- und Wildtiere“ (2007).

Published by the Leibniz Institute for Zoo and Wildlife Research (IZW)
Alfred-Kowalke-Str. 17, 10315 Berlin (Friedrichsfelde)
Postfach 70 04 30, 10324 Berlin, Germany

Printed on FSC-certified paper. The paper has been harvested, processed and manufactured in a sustainable fashion. The Forest Stewardship Council (FSC) label is the gold standard in forest management and sustainable wood products.

All rights reserved, particularly those for translation into other languages. It is not permitted to reproduce any part of this book by photocopy, microfilm, internet or any other means without written permission of the IZW. The use of product names, trade names or other registered entities in this book does not justify the assumption that these can be freely used by everyone. They may represent registered trademarks or other legal entities even if they are not marked as such.

Setting and layout: Anke Schumann, Alexander Wächter, Steven Seet, Berlin, Germany
Cover: Warsaw Zoological Garden, Warsaw, Poland
Photo cover and next page (European bison): Adam Wajrak
Printing: copy print Kopie & Druck GmbH, Berlin, Germany
Order: Leibniz Institute for Zoo and Wildlife Research (IZW)
Forschungsverbund Berlin e.V.
Postfach 70 04 30, 10324 Berlin, Germany
www.izw-berlin.de

Jointly organised by

European Association of Zoo and Wildlife Veterinarians (EAZVW)

&

Leibniz Institute for Zoo and Wildlife Research (IZW)

Scientific programme committee

Mirjam Grobbel, Berlin, Germany

Alex D. Greenwood, Berlin, Germany

Heribert Hofer, Berlin, Germany

Alexis Lécu, Paris, France

Agnieszka Czujkowska, Warsaw, Poland

Andrzej G. Kruszewicz, Warsaw, Poland

Anke Schumann, Berlin, Germany

Steven Seet, Berlin, Germany

in cooperation with

Warsaw Zoological Garden

Local organising committee

Agnieszka Czujkowska

Ewa Zbonikowska

Andrzej G. Kruszewicz



Venue

Hotel Sofitel Warsaw Victoria,

Warsaw, Poland

TABLE OF CONTENTS

Human-wildlife conflicts

Kelly A	
Human-wildlife conflicts	1
Memarian I, Dehghan MM, Molazem M, Pedram MS, Rostami A, Vali Y, Farzad S, Zehtabvar O, Shahrdari AR, Hamidi AHK, Abdolmalekiyan N	
Extinction shadows over Persian leopards (<i>Panthera pardus saxicolor</i>) due to human-animal conflict	2
Crespo-Picazo JL, García-Párraga D, Bernaldo De Quirós Y, Díaz-Delgado J, Cervera V, Martí-Bonmatí L, Arbelo M, Fernández A	
Decompression sickness: a new pathological entity in marine turtles	9
Lueders I, Young D, Botha S, Gray C, Luther I, Maree L, Van Der Horst G, Tindall B, Bertschinger HJ	
GNRH vaccination of African elephant bulls for contraception and behavioural management	10
Wasył D, Zając M, Hoszowski A, Jabłoński A, Lalak A, Samcik I, Skarżyńska M, Szulowski K	
Antimicrobial resistance in <i>Escherichia coli</i> isolated from wildlife animals in Poland	11

Parasitology

Smith DA, Stasiak IM, Hafeez MA, Delnatte P, Barta JR	
<i>Isoospora</i> spp. causing simultaneous visceral (“atxoplasmosis”) and enteric coccidiosis in superb glossy starlings, and visceral coccidiosis in black throated laughing thrushes	12
Naidenko S, Pavlova E, Kirilyuk V	
Serum prevalence of antibodies to common felid pathogens in Pallas’s cats (<i>Otocolobus manul</i>) from the Daurian steppes, Eastern Russia	13
Bartova E, Sedlak K, Nagl I, Vodička R, Ajzenberg D, Slezaková R	
Genotypes of <i>Toxoplasma gondii</i> isolated from Pallas’s cats with fatal toxoplasmosis	14
Krengel A, Knauf-Witzens T, Süß-Dombrowski C, Schwabe I, Schares G	
Fatal toxoplasmosis in two juvenile slender-tailed meerkats (<i>Suricata suricata</i>) in a German zoo – clinical, pathological and serological findings	18
Bakker J, Klomp R, Te Poele EEM, Langermans JAM, Van Geijlswijk IM	
Challenges in oral administration of clioquinol dispersed in gel to pair-housed rhesus monkeys (<i>Macaca mulatta</i>)	19

Springer A, Fichtel C, Leendertz F, Calvignac-Spencer S, Mellmann A, Nunn CL, Kappeler PM Investigating parasite spread through a lemur population	26
---	----

Conservation medicine in the Middle East

Bailey T An overview of the threats facing wildlife in the Middle East and the contribution of veterinarians to conservation programmes	27
Avni-Magen N, Eshar D, King R, Shilo-Benjamini Y, Gancz AY Wildlife conservation breeding and reintroduction programmes at the Jerusalem (biblical) zoo, Israel	28
Soares JF, Shiferaw FD, Al-Hanoosh N, Macasero W Management implications and eradication of <i>Brucella melitensis</i> in two different gazelle species (<i>Gazella erlangeri</i> , <i>Gazella marica</i>) in the Kingdom of Saudi Arabia	29
Molnár L, Beregi A, Major P, Kuzyšinová K, Molnárová M Outbreak of contagious caprine pleuropneumonia in captive dorcas gazelles (<i>Gazella dorcas</i>)	33
Baqir S, Orabah A, Al-Rasbi K, Al-Shakaili Y, Gartley C, Mastromonaco G Computer assisted and flow cytometric sperm analysis in the captive Arabian leopard (<i>Panthera pardus nimr</i>)	34

Population medicine

Gruetzmacher KS, Leendertz FH Using non-invasive methods for the detection of systemic infection in wildlife	35
Baumgartner K, Abdelgawad A, Azab W, Damiani AM, Will H, Osterrieder N, Greenwood AD Zebra-borne equine herpesvirus type 1 (EHV-1) infection in non-African captive mammals ...	36
Wojcik B, Anuszkiewicz J, Wójcik M, Augustynowicz-Czajka O, Zabłotny A The first case of <i>Mycobacterium bovis</i> ssp. <i>caprae</i> isolation from wolves (<i>Canis lupus</i>) in Bieszczady Mountains, Poland.....	37
Gerritsmann H, Stalder GL, Spargser J, Hoelzl F, Deutz A, Kuebber-Heiss A, Walzer C, Smith S Acid fast rods in an ecological hay stack: multiple strain infections and high genotypic diversity among <i>Mycobacterium avium</i> subsp. <i>paratuberculosis</i> isolated from diseased wild ruminants	38
Kiupel M, Hollinger C, Curtis B, Riegl B, Bruckner A Histologic characterisation of dark spot lesions in madracis corals	39

The role of the veterinary advisor I

Napier JE	
The role of the veterinary advisor: back to basics, it's not just medicine	40
Knauf-Witzens T, Kregel A	
Ape moves – translocation of the Wilhelma bonobos and gorillas into the new Menschen.Affen.Haus!.....	43
Hatt J-M, Bauert M, Wenger S	
The masoala rainforest exhibit at Zurich zoo - 10 years of experience from a veterinary perspective	55
Keller S, Balsiger A, Espie I, Lane EP, Kotze A, Clauss M, Codron D	
Density-dependent effects on mortality in 42 zoo animal species at the National Zoological Gardens of South Africa	56
Hagen K, Espie I, Lane EP, Kotze A, Wyss F, Clauss M, Codron D	
Mortality and diseases in greater flamingo (<i>Phoenicopterus roseus</i>) and Caribbean flamingo (<i>Phoenicopterus ruber</i>) kept at the National Zoological Gardens of South Africa	57
Bertelsen MF	
On the euthanasia of surplus animals, and the role of zoos in alleviating biological illiteracy - lessons learned.....	65

The role of the veterinary advisor II

Fiorucci L, Grande F, Pilenga C, Henriques A, Manfrini V, Flanagan C	
Veterinary management of two primiparous pregnancies, birth and <i>post partum</i> in bottlenose dolphins (<i>Tursiops truncatus</i>) with the same prediction dates	68
Feltre Y, Dodds J, Masters N, Niblett R, Somauroo J, Modi S, Shave R	
Implantable loop recorders for the diagnosis of cardiac disease in chimpanzees	69
Steinmetz HW	
Biomechanics of the normal gait in Asian elephants (<i>Elephas maximus</i>).....	70
Delaski K, Ramsay E, Gamble K	
Retrospective pathology review of red pandas (<i>Ailurus fulgens</i>) captively-housed in North America.....	71
Teare JA	
ISIS and ZIMS: what can we learn from globally shared data?	72

Free topics

Chai N, Petit P, Kohl M, Bourgeois A, Gouni V, Trehiou-Sechi E, Misbach C, Petit A, Garrigou A, Guépin R, Pouchelon JL, Chetboul V Echocardiographic evaluation of clinically healthy captive large felids	75
Leclerc A, Trehiou-Sechi E, Greunz EM, Damoiseaux C, Bouvard J, Chetboul V Severe aortic regurgitation and systemic hypertension in a North-chinese leopard (<i>Panthera pardus japonensis</i>)	76
Langan JN, Kleinschmidt LM, Warneke M, Allender MC Retrospective review of the global prevalence of myelolipomas in Goeldi's monkeys (<i>Callimico goeldii</i>) and implications for future study	77
Masters N, Franklinos L, Feltrer Y, Pocknell A, Bolt D, Smith S, Molenaar FM Successful chemotherapy of an oral anaplastic sarcoma in a pygmy hippopotamus (<i>Hexaprotodon liberiensis</i>).....	78
Hoby S, Wenker C, Zenker W, Lawrenz A, Keller R The net solution: positioning of an African elephant for anaesthesia under field conditions.....	79
Perrin K, Grøndahl C, Nissen P, Bertelsen MF Comparing etorphine-acepromazine and medetomidine-ketamine anaesthetic protocols in impala (<i>Aepyceros melampus</i>).....	80
Loth K, Reiners JK A new approach to the safe anaesthesia of antelopes and gazelles: considerations of the individual patient rather than the species by means of a jumpiness index and a mathematical factor	81
Carnimeo A, Andreani V, Capasso M, Silvestre P, Nocerino M, Guandalini A, Selleri P, Di Girolamo N Poor agreement between applanation and rebound tonometry to measure intraocular pressure in anaesthetised rhesus macaques (<i>Macaca mulatta</i>).....	82

Nutritional diseases

Clauss M, Hatt J-M Nutritional diseases: from bottle feeding to geriatric issues	83
Kneisl T, Karbe F, Stagegaard J, Will H, Baumgartner K, Liesegang A The Achilles' heel of breeding cheetahs.....	88
Gattiker C, Espie I, Lane EP, Kotze A, Codron D, Clauss M Correlations of diet composition and diet-related disorders in a collection of captive wild ruminants at the National Zoological Gardens of South Africa	89

Kilgallon C, Kinne J, Moittie S	
No country for old crocodile - fatal lead toxicity in captive Nile crocodiles: clinical syndrome and attempted chelation therapy with oral d-penicillamine.....	90
Czujkowska A, Kruszewicz A, Arciszewski MB	
Neurochemical characteristic of galanin-expressing enteric neurons supplying small intestine of wild boar. ENS - new possibilities in zoo and wild animal research?	91

Poikilotherms

Halck ML, Bertelsen MF	
The use of external temperature loggers for optimisation of the temperature gradient in reptile enclosures.....	92
Carvalho MPN, Sant'Anna SS, Grego KF, Gogone ICVP, Catão-Dias JL	
Histopathological analysis of viscera in teratogenic neotropical viperids.....	93
Da Silva MO, Bertelsen MF, Heegaard S, Garner MM	
Diseases of the snake spectacle	97
Holtze S, Lukac M, Cizelj I, Hildebrandt TB	
Ultrasound under water – featuring the olm (<i>Proteus anguinus</i>).....	98

POSTERS

Almagro V, Huzman M, Fernández-Bellon H, Novellas R, Casanova I, Ramis T	
Androgen-secreting adrenocortical tumor in a female <i>Panthera leo</i>	99
Alonso-Farré JM, Gonzalo-Orden M, Llarena-Reino M, Degollada E	
Computed tomography and magnetic resonance imaging of dolphin paraotic sinuses.....	100
Bahr J	
Veterinary work in a seal rehabilitation centre: motherless pups, lungworms and other diseases in seals	101
Balsiger A, Keller S, Espie I, Lane E P, Kotze A, Clauss M, Codron D	
Reproductive seasonality and newborn mortality at the National Zoological Gardens of South Africa	102
Barbon AR, Fountain K, Routh A	
A retrospective study of mortality in captive Livingstone's fruit bats (<i>Pteropus livingstonii</i>)....	103
Barszcz K, Olbrych K, Rożniewska N, Kupczyńska M, Warchulska K	
Aortic valve commissures in the European bison (<i>Bison bonasus</i>)	104

Bernardino RI, Fernandes TL Surgical repair of atresia ani and rectovaginal fistula in a cape buffalo (<i>Syncerus caffer caffer</i>)	105
Bertocchi M, Spiezio C, Di Ianni F, Macchi E, Parmigiani E, Quintavalla F Case report on welfare of captive tigers - ethological and physiological parameters	108
Biagi G, Pinna C, Rigoni G, Spiezio C, Sandri C Effects of yogurt dietary supplementation on the intestinal ecosystem of a population of emperor tamarins (<i>Saguinus imperator</i>).....	109
Braun V, Wüst E, Kramer M, Schmidt M Hydrocephalus internus in an African grey parrot (<i>Psittacus erithacus</i>)	110
Brazis P, Puigdemont A, Ravera I, Almagro V, Fernández-Bellon H Diagnosis of allergic dermatitis in a spotted hyaena (<i>Crocuta crocuta</i>)	111
Budd J, Lewis J, Soilemetzidou S, Whitehouse-Tedd K Anaesthetic induction protocols in Arabian leopards (<i>Panthera pardus nimr</i>)	113
Cabajal A, Fernández-Bellon H, Talló-Parra O, Almagro V, Sabés-Alsina M, López-Béjar M Corticosterone determination in shed skins from lizards and snakes: a potential tool for assessing chronic stress	114
Casares M, Gerique AC, Carbajal A, Talló-Parra O, Sabes-Alsina M, Carbonell MD, Lopez-Bejar M Effect of deslorelin implants on the testicular function in male ring-tailed lemurs (<i>Lemur catta</i>).....	115
Dolka B, # łodar z\$kiR, ŹbikŸ="kGA, Szele" z' zuk P, Led=Ÿń A Health assessment of free-living mute swans (<i>Cygnus olor</i>)	116
Douay G, Tasse J, Bertucat V, Simonin C, Bes M, Laurent F Preliminary investigation of <i>Staphylococcus aureus</i> carriage in zoo veterinarians in France	119
Fernandes TL, Bernardino RI, Peleteiro C Facial melanocytoma in an axolotl (<i>Ambystoma mexicanum</i>)	120
Fiorucci L, Grande F, Flanagan C, Silva J, Urbani N, Sampayo J, Macrelli R The importance of gastric cytology in bottlenose dolphins under human care	121
Galateanu G, Göritz F, Saragusty J, Szentiks CA, Wibbelt G, Hildebrandt TB Bear watching for foot and spine osteopathology correlation in captive bears (<i>Ursidae</i>)	122
Galateanu G, Göritz F, Wibbelt G, Szentiks CA, Hildebrandt TB First catch your hare: vertebral morphology and pathology in <i>Leporidae</i> as revealed by high-resolution computed tomography	126

Galateanu G, Hermes R, Saragusty J, Göritz F, Potier R, Mulot B, Maillot A, Etienne P, Bernardino R, Fernandes T, Hildebrandt TB New clinical imaging tools: taxa-specific distal foot radiographic views in rhinoceroses	129
Galateanu G, Saragusty J, Göritz F, Wibbelt G, Szentiks CA, Mezö Z, Hildebrandt TB Quantitative computed tomography in captive giraffes (<i>Giraffa camelopardalis</i>).....	132
Galateanu G, Szentiks CA, Krone O, Hildebrandt TB High-resolution computed tomographic assessment of dental morphology in German wolves (<i>Canis lupus</i>)	136
García-Párraga D, Griffeth RJ, Crespo-Picazo JL, Álvaro T, Valls M, Soriano-Navarro M, Martínez A, Moreno-Manzano V Optimisation of platelet-rich plasma concentration protocol in bottlenose dolphins (<i>Tursiops truncatus</i>) and <i>in vitro</i> validation testing.....	137
Germitsch N, Vybiral P-R, Codron D, Clauss M, Kotze A, Lane EP Adrenal mass as a retrospective indicator of health problems in captive cheetahs (<i>Acinonyx jubatus</i>) at the Ann van Dyk Cheetah Centre, South Africa	138
Giacomelli S, Bianchi A, Polloni A, Archetti LI, Bertoletti I, Rota Nodari S Alpha-naphtyl acetate esterase activity in white blood cells of wild ruminants: preliminary results.....	139
Grande F, Fiorucci L, Crosta L, Guerreiro E Treatment of an injured wing in an Australian pelican (<i>Pelecanus conspicillatus</i>) using a new wound-healing stimulant	142
Gutleb DR, Pflüger LS, Wallner B Semi-free versus wild Japanese macaques (<i>Macaca fuscata</i>) – a meta-analysis of endocrine and demographic parameters.....	143
Halck ML, Bertelsen MF External temperature loggers as a non-invasive method of estimating body temperature in two agamid species	144
Hatt J-M, Jaya Y, Erdiansyah R, Frey R Experiences from <i>in situ</i> and <i>ex situ</i> training of Sumatran zoo and wildlife veterinarians.....	145
Iannaccone M, Sanna Passino E, Campolo M, Bono L, Secci F, Columbano N Evaluation of chemical immobilisation with medetomidine-tiletamine-zolazepam-butorphanol and medetomidine-ketamine-butorphanol in red-eared slider turtles (<i>Trachemys scripta elegans</i>)	146
IJzer J, Keesler RI, Kik MJL, Brasseur SMJM, Verdaat H, Gröne A <i>Post mortem</i> investigation of stranded seals (<i>Phoca vitulina</i> and <i>Halichoerus grypus</i>) in the Southern Wadden Sea and North Holland province, the Netherlands, 2009 - 2013	147

Liptovszky M, Szilasi A, Papp GV A fully reversible drug combination for the deep sedation of red foxes (<i>Vulpes vulpes</i>).....	169
Lueders I, Pootoolal J, Taya K, Watanabe G, Yamamoto Y, Niemuller C, Chenier T, Scholtz E Assisted reproduction in giraffes	170
Lukac M, Horvatek Tomic D, Cizelj I, Prukner-Radovcic E <i>Proteus anguinus</i> project – first year bacteriological findings	171
Luz S, Lee P, Raghavan R The role of zoo in combating illegal wildlife trade: the last 10 years at Wildlife Reserves Singapore	172
Magnone W, Sandri C, Salvellia A, Avesani C, Pascotto E A fatal case of intestinal intussusception in a maned wolf (<i>Chrysocyon brachyurus</i>).....	173
Memarian I, Abarghouei MJO, Molazem M, Pedram MS, Vali Y, Mohajeri SF, Ghazaleh N, Shahrdari AR Post and core dental restoration of Persian leopard's (<i>Panthera pardus ciscaucasica</i>) mandibular canine teeth	174
Modesto P, Biolatti C, Grattarola C, Varello K, Iulini B, Mandola MI, Dondo A, Gorla M, Rocca F, Acutis P First report of malignant catarrhal fever in a captive pudu (<i>Pudu puda</i>)	178
Molnár L, Major P, Ptacek M Conjunctivitis of greater rhea (<i>Rhea americana</i>) in the Middle East	181
Niphuis H, Fagrouch Z, Bogers W, Verschoor E Investigating flavivirus infections in nonhuman primates	182
Painer J, Fritsch G, Hertwig C, Göritz F Anaesthesia protocol for captive brown bears (<i>Ursus arctos</i>) – quick induction, reliable maintenance and rapid recovery	183
Painer J, Jewgenow K, Dehnhard M, Arnemo JM, Linnell JDC, Odden J, Hildebrandt TB, Göritz F A unique felid reproductive cycle - the longest corpus luteum lifespan among mammals leads to a mono-oestrous reproduction in lynx (<i>Lynx lynx</i>)	184
Prokeš M, Benkő Z, Korytár L, Ondrejková A, Ondrejka R, Čechvala P Wild birds and avian chlamydiosis.....	185
Quintard B, Apery S, Lefaux B A new technique for helicobacter infection diagnosis in cheetahs (<i>Acinonyx jubatus</i>)	186
Račnik Ž, Zadavec M, Trilar T, Zorjan Rojčič Electrolytes and venous blood gases in wild living barn swallows (<i>Hirundo rustica</i>) captured during autumn migration in Slovenia	187

Risch T, Kershaw O, Ochs A Therapy-resistant endoparasitosis in a male aye-aye (<i>Daubentonia madagascariensis</i>)	188
Rossier C, Hoby S, Wenker C, Jermann T, Posthaus H A retrospective study of reptile necropsy reports from 2002 to 2012 at Zoo Basel	189
Rosu O, Udrescu LA, Birtoiu D, Manu E Chemical immobilisation of Letea feral horses (<i>Equus caballus</i>) using ketamine and medetomidine	190
Rożniewska N, Barszcz K, Kupczyńska M Infectious diseases in the context of human-wildlife conflict in Africa	196
Sabés-Alsina M, Fernández-Bellón H, Huzman M, Almagro V, Talló-Parra O, Cabajal A, López-Béjar M Ovarian teratoma in a fallow deer (<i>Dama dama</i>)	197
Salchow AM, Greenwood AD, Hölzle LE Mycobacteria in German zoos - is there a risk of infection from animals to humans?	198
Sargsyan NI, Arakelyan M, Danielyan F Helminthofauna of common reptiles of Armenia	199
Scaglione FE, Bollo E, Chiappino L, Sereno A, Mignone W, Moschi R, Garibaldi F, Tittarelli C, Guarda F Coronary artery lesions in the swordfish (<i>Xiphias gladius</i>)	203
Scaglione FE, Longato E, Pregel P, Piria M, Capobianco Dondona A, Nannarelli S, Appino S, Bollo E Pathology of free-living loggerhead turtle (<i>Caretta caretta</i>) embryos on the island of Linosa (Italy)	204
Schmitt A, Lampe K, Bayrhof G, Gruber-Dujardin E, Mätz-Rensing K, Kaup F-J, Bleyer M Lethal herpesvirus simplex infection in two common marmosets (<i>Callithrix jacchus</i>)	205
Slezaková R, Bartova E, Vodička R, Sedlak K <i>Toxoplasma gondii</i> in zoo animals	206
Soilemetzidou S, Budd J, Dorrestein G, Whitehouse-Tedd K Evaluation of Arabian ungulate pathology at the Breeding Centre for Endangered Arabian Wildlife, Sharjah, United Arab Emirates	211
Tahas S, Timofte D, Chantrey J, Lopez J Multiple mycobacterial infections in a zoo aquarium	212
Unger F, Eisenberg T, Prenger-Berninghoff E, Ludwig M-L, Rothe M, Ewers C Multidrug resistant Enterobacteriaceae in imported reptiles	213

Vicari N, Bianchi A, Manfredini A, Giacomelli S, Genchi M, Bertoletti I, Fabbi M A survey on <i>Francisella tularensis</i> in Sondrio province after importation of infected hares	214
Vybiral P-R, Germitsch N, Codron D, Clauss M, Kotze A, Lane EP Neonatal mortality in captive cheetahs (<i>Acinonyx jubatus</i>) at the Ann van Dyk Cheetah Research Centre, South Africa	215
# r " \$! D,ř<Y" zo=" kGA, Zaj* M, Jab?Y@'GA, Skřw\ \$@kr M, Sr! ~ & I, Lalak A, Szulo=" kG	
Prevalence of <i>Salmonella</i> serovars in game animals from Poland	216
Wehrmeister E, Wohlsein P, Prenger-Berninghoff E, Siebert U Intestinal displacements in phocids from German waters	217
Weinberger H, Duscher G Hepatozoonosis in a stone marten (<i>Martes foina</i>) in Vienna, Austria	218
Zadravec M, Račnikř> Treatment of hypercortisolism with trilostane (Vetoryl®) in two golden hamsters (<i>Mesocricetus auratus</i>)	219
%ř*ř ĩM, Malutrř A, # ř" \$!řD, Hoszo=" kGA, Szulo=" kG	
Prevalence of <i>Salmonella</i> spp. in subcutaneous abscesses in leopard geckos (<i>Eublepharis macularius</i>)	222
%ř*ř ĩM, # ř" \$! D, HY" zY=" kGA, Skř w \$@ka M, Lalak A, Sr! ~ & I, Szulo=" kG	
Characterisation of <i>Salmonella</i> isolated from zoo and pet snakes in Poland	223
AUTHOR INDEX	224

HUMAN-WILDLIFE CONFLICTS

KELLY A

Irish Society for the Prevention of Cruelty to Animals, Derrylglogher Lodge, Keenagh, Co. Longford, IRELAND; andrew.kelly@ispca.ie

Wildlife and human activities interact in many ways, with diverse outcomes and consequences for both wildlife and humans. In this presentation I will discuss three examples of human / wildlife conflict: invasive non-native species (INNS); wildlife rehabilitation and the international trade (both legal and illegal) of wild animals for the global pet market. All three examples involve large numbers of wild animals and have severe implications for conservation, animal welfare and in some cases public health and safety. INNS are the second biggest threat to biodiversity and ecosystem services after habitat loss and can impact on public health and safety. Species such as the American mink (*Neovison vison*) are well established and widespread but other, novel species are introduced deliberately or accidentally on an on-going basis. The European Union is in the process of developing new legislation for the prevention and management of INNS. This risk-based legislation aims to identify and manage the pathways of invasion and although the emphasis will be on prevention, rapid eradication of novel INNS and long-term management and control of established INNS raises concerns about the welfare of both target and non-target species. Here, I will review the proposed legislation and highlight the need for solutions that take into account animal welfare.

Wildlife rehabilitation is a growing global activity in which sick, injured or orphaned wild animals are cared for in specialist centres with the intention of releasing them back to the wild. Many of these casualties are the direct result of human activities and wildlife rehabilitators work to give these animals a second chance. However, little is known about the fate of released wildlife casualties and their welfare could be compromised if they are unable to survive independently in the wild following release. Here, I give an overview of the Royal Society for the Prevention of Cruelty to Animals (RSPCA) programme of post release monitoring. Methods such as mark-release-recapture, radio-and satellite telemetry have been used to demonstrate that species such as pipistrelle bats (*Pipistrellus* spp.) and common seals (*Phoca vitulina*) survive well following release.

The international trade in wild animals for the pet market involves many millions of captive-bred and wild caught wild animals. This billion Euro industry is in many cases unsustainable and although trade in some species is regulated through the Convention on the Trade in Endangered Species (CITES), the trade (both and illegal) has a negative impact on wild populations and the welfare of the animals involved. I will give an overview of the scale of the trade and discuss the animal welfare concerns of many animal welfare non-governmental organisations. Some of the animals involved in the trade pose a risk to human health and safety, risk spreading animal diseases, and some species pose a risk to the environment if they are released or escape into the wild.

All of these examples demonstrate the need to find sustainable solutions for human/wildlife conflicts that take wild animal populations and the welfare of individual animals into consideration.

EXTINCTION SHADOWS OVER PERSIAN LEOPARDS (*PANTHERA PARDUS SAXICOLOR*) DUE TO HUMAN-ANIMAL CONFLICT

MEMARIAN I¹, DEGHAN MM², MOLAZEM M², PEDRAM MS², ROSTAMI A³, VALI Y², FARZAD S², ZEHTABVAR O⁴, SHAHRDARI AR⁵, HAMIDI AHK⁶, ABDOLMALEKIYAN N⁷

¹Tehran Zoo and Pardisan Rehabilitation Centre, 1484613111 Tehran, IRAN;
Zoo.vet@tehraneramzoo.ir

²University of Tehran, Faculty of Veterinary Medicine, Dept. of Radiology and Surgery, 141556453 Tehran, IRAN

³University of Tehran, Faculty of Veterinary Medicine, Dept. of Zoo and Wildlife, 141556453 Tehran, IRAN

⁴University of Tehran, Faculty of Veterinary Medicine, Dept. of Basic Science, 141556453 Tehran, IRAN

⁵Tehran Zoo, 141556453 Tehran, IRAN

⁶Persain Wildlife Heritage Foundation and Pardisan Rehabilitation Centre, 1484613111 Tehran, IRAN

⁷Pardisan Rehabilitation Centre, 1484613111 Tehran, IRAN

Summary

In our case report, we demonstrate the direct impact of human-wildlife conflicts in case of an 8 year old male Persian leopard (*Panthera pardus saxicolor*), located near Tonekabon, Mazandaran province of Iran. The animal was found incapable of moving its hind limbs, and therefore not able to escape when the local people were throwing stones at it. For capture and transfer to Tehran, the leopard was anaesthetised. When the rescue team reached the Pardisan rehabilitation centre, the animal was further transferred to the faculty of veterinary medicine of the University of Tehran for imaging examinations. Radiography revealed one bullet shaped metallic foreign body, located at spinal canal at the level of L6. This injury was identified as the most critical, and was suspected to be the reason for the observed clinical signs. In 3D reconstruction, a hole in the right lateral pedicle of the L5 was detected, which indicated the channel of the bullet found at L6, in spinal canal. In both hind limbs, there were no signs of deep pain sensation and proprioception was negative. Due to poor prognosis, the vet team eventually decided to euthanise this endangered and genetically very valuable animal from Alborz range. Before performing euthanasia, sperm and stem cells were collected from this huge male (100 kg) for further studies. *Post mortem* findings confirmed the severe and irreversible trauma of the spinal cord.

Introduction

The Persian leopard (*Panthera pardus saxicolor*), is the largest leopard subspecies. It is native to Iran, eastern Turkey, the Caucasus Mountains, southern Turkmenistan, and parts of western Afghanistan (figure 1). It is considered endangered with a population size of less than 500 mature individuals and a declining population trend (ZIAIE, 2008; KHOROZYAN, 2008).

Spinal trauma can originate from internal or external causes. Injuries to the spinal cord can be classified as either concussive, or compressive and concussive. Common causes of vertebral

fractures in animals are injuries from traffic accidents, falling or gunshot (SHORES, 1992).

Injuries at the spine caused by gunshot commonly are thought to be stable fractures. There is, however, a potential for instability if the bullet passes transversely through the spinal canal and fractures pedicles and facets, or when the bullet gets stuck in the spinal canal. Injuries in the thoracic region of the spine are the most common, followed by the thoracolumbar area and the cervical spine (WATERS and SIE, 2003).

Judicious use of conventional radiography can provide valuable information on the condition of the vertebral column, and survey radiography should always be made before advanced imaging but mostly they are not enough to lead to a definitive diagnosis and a prediction of prognosis. Therefore, additional imaging is essential for further investigation of spinal cord and vertebrae. Because of tomographic nature, a CT is superior to radiography for identifying and characterising vertebral fractures and spinal conditions. Due to contraindication of metallic materials with the magnetic field (suspected), gunshot wounds cannot be investigated by magnetic resonance imaging (THRALL, 2012). For a long time, the Persian leopard has been widely hunted throughout its range. Nowadays, only fewer than 500 individuals live in west Asia and the majority of this endangered subspecies lives in Iran. Over the past 25 years, the leopard was exterminated in many areas of this vast range, and its number was significantly decreased in its other habitats. Surprisingly, the drastic decline of population size has been due to poaching, prey reduction and habitat loss. Lack of any direct actions focusing on conservation of the Persian leopard in Iran has brought this cat to the verge of extinction (KIABI et al., 2002).

The major conflict between Persian leopards and human is due to traditional way of keeping livestock. The herders in Iran let their livestock graze anywhere, including national parks. In this situation, loss of livestock and herd dogs due to leopard attack is inevitable. Hence, in the absence of any direct supervision from the government, herders do what they must, including killing the leopards, to protect their herds.

Extinction shadows over Persian leopards is obviously visible. According to the reports from the Iranian Department of Environment, 20 Persian leopards have been killed in Iran in the past ten months, including two cases of spinal cord trauma due to gunshot, in only two weeks. The first one was the cited case and the second one is underwent surgery and is still under treatment (figure 2 and 3). Also, recently we had another case of a female Persian leopard trapped in the gin trap, and the vet team eventually decided to amputate the hand due to gangrene (figure 4 and 5). A juvenile female Persian leopard, who died due to the pulmonary haemorrhage after being hit by a cudgel, and a 9 year old male shot in the abdominal cavity and tied with handcuffs, are two of the several examples observed this year (figure 6, 7, 8 and 9). This signifies the severity of the disaster threatening Persian leopards. In total, 63 % of the killing records from this year have been due to poaching or poisoning, and 22 % from road accidents. The provinces of Fars, Golestan and Lorestan have recorded the highest numbers of leopard poaching.

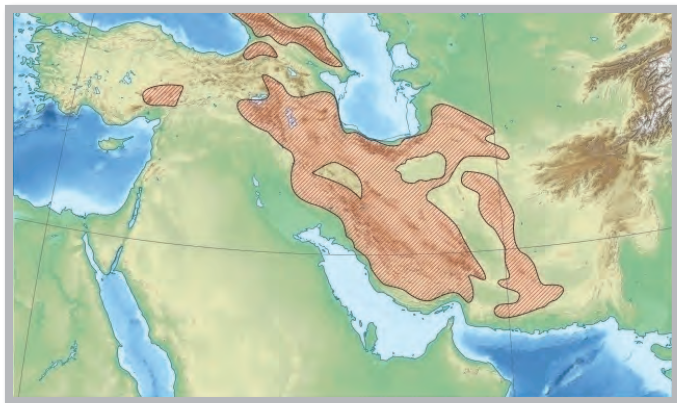


Fig. 1: Distribution of the Persian leopard (*Panthera pardus saxicolor*) depicted as brown hatched area in the topographic map of south-western Asia. (Image: Ehsan Jannati)

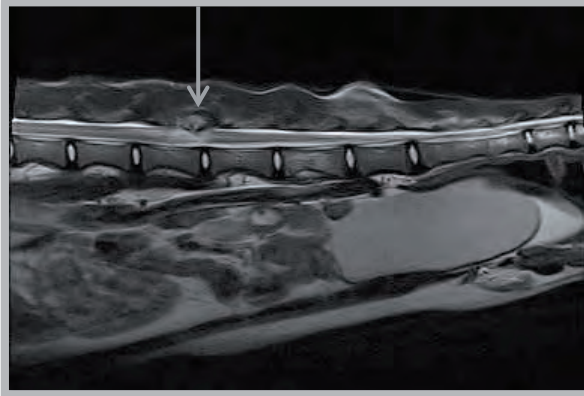


Fig. 2: MRI study consists of sagittal image of the (lumbar) spine utilising (T1, T2) acquisitions, consequence spinal cord compression between L4 and L5 of a female Persian leopard.

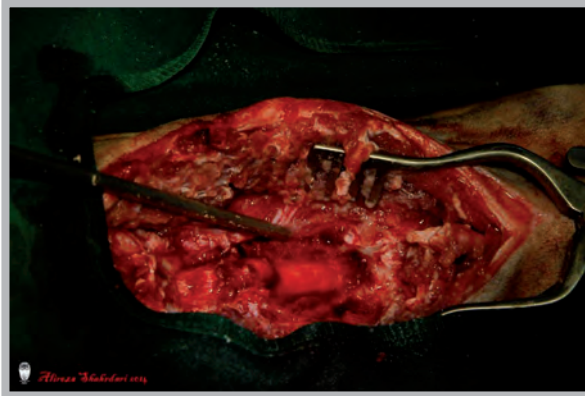


Fig. 3: Laminectomy in a 3 year old female Persian leopard with spinal trauma due to gunshot was performed after the MRI shown in figure 2. The injured part of spinal cord is visible in the picture. (Photo: Alireza Shahrhiri)



Fig. 4 & 5: The female Persian leopard, which was grabbed in the gin trap. Eventually, the vet team amputated the hand due to gangrene. (Photo: Alireza Shahrhiri)

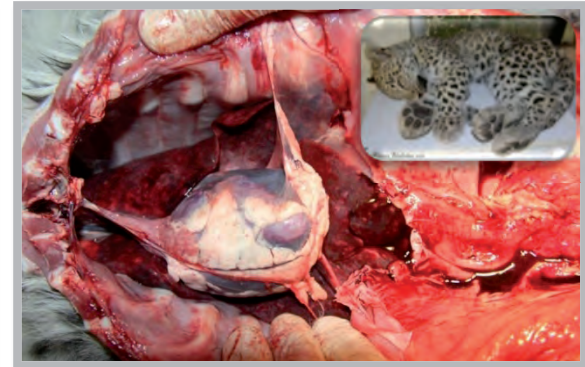


Fig. 6 & 7: A juvenile female Persian leopard, which died due to the pulmonary haemorrhage after being hit by a cudgel. (Photo: Alireza Shahrhiri)



Fig. 8 & 9: A 9 year old male Persian leopard, which was shot in the abdominal cavity and then tied with handcuffs. Photo: Alireza Shahrhiri.

The case

A huge (100 kg) 8 year old male Persian leopard was found near Tonekabon, in the province of Mazandaran, Iran. When found, the animal was unable to move either of hind limbs. Right metacarpal bones and digits were absent and distortion of carpal bones was remarkable. These problems were probably due to the leopard being trapped in a gin trap. The healing process of the wound indicated that the amputation should have happened at least a month before (figure 10). Anaesthesia was achieved using a combination of Tiletamine, Zolazepam (Zoletil 100, Virbac S.A, Paris, France) 1.5 mg/kg and Medetomidine HCL 20 mg/ml (Kyron Laboratories (Pety) Ltd., Johannesburg, South Africa) 15 µg/kg administered IM in same 1.5 ml dart by blowpipe. This provided effective anaesthesia for capture and transfer of the animal to the faculty of veterinary medicine of the University of Tehran for diagnosis imaging examinations.

Radiographs were taken in several orthogonal projections from fore limb, thoracic and abdominal areas. Additionally a CT scan was performed with KVp 130, mAs 97 and slice thickness 1.0 mm with dual detector Simense CT scan machine, and the results were evaluated in transverse scans and three dimensional reconstruction with implant and bone algorithm.

Result

Radiography revealed that right metacarpal bones and digits were absent and distortion of carpal bones was remarkable. Active laminar periosteal reactions were also detectable in several region of distal part of the affected limb that seems to be consequence of repeated trauma or infectious process. 10 to 14 days old comminuted fracture was visible in right ulna, associated with several metallic foreign bodies (gunshot) and two butterfly segments (figures 11 and 12). Several metallic densities were observed in radiographs (4 foreign bodies at dorsal region of the scapula, one on the right side near the T10, 1 in L6 and one in the silhouette of L5; several around the right humerus; size of the bullet fragments were 0.8 *1 to 1 *1.3 cm). The metallic foreign body which was located in spinal canal at the level of L6 was identified as the most critical injury, also presumed to be responsible for the observed clinical sings (figures 13 and 14). Serosal details of abdominal organs were clearly detectable at the examination time. Increased opacity of right lobes of lungs with interstitial pattern were diagnosed as consequence of long time recumbency or pulmonary haemorrhage (figures 15 and 16).

Two main metallic foreign bodies and several small pieces were detected in CT scans as was remarked in radiographs. With this method it was clearly shown that one of them was located in the spinal canal at the level of L6. In 3D reconstruction, a hole in the right lateral pedicle of the L5 was detected which indicates the path way of the gunshot which was found in spinal canal at L6 (figures 17 and 18).

There were no signs of deep pain sensation in neither of hind limbs, and proprioception was negative at the same time. Due to the bad prognosis and assumed suffering of the animal, despite the endangered status of the Persian leopard, the vet team eventually decided for euthanasia. Before performing euthanasia, sperm and stem cell samples were collected from this male for any further studies and conservation of the genetic material. The animal was again anaesthetised and then euthanised by using T61 (Intervet S. A., Amsterdam, Netherland) 0.3 ml/kg intravenously. Necroscopy confirmed sever and irreversible trauma of the spinal cord which was depicted before via imaging methods (figures 19, 20 and 21).

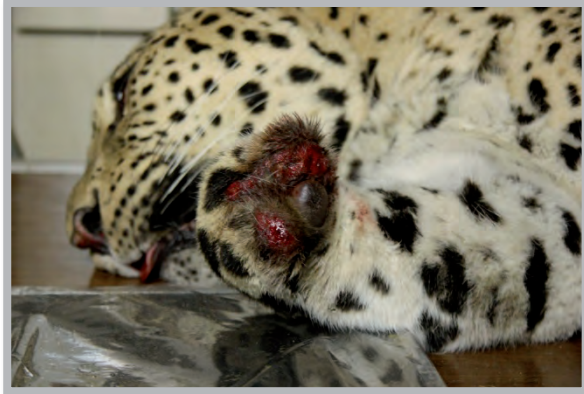

Fig. 10: Infected wound at the right front paw of a Persian leopard. Metacarpal bones and digits are missing due to being grabbed in a gin trap. Photo: Alireza Shahrhiri.

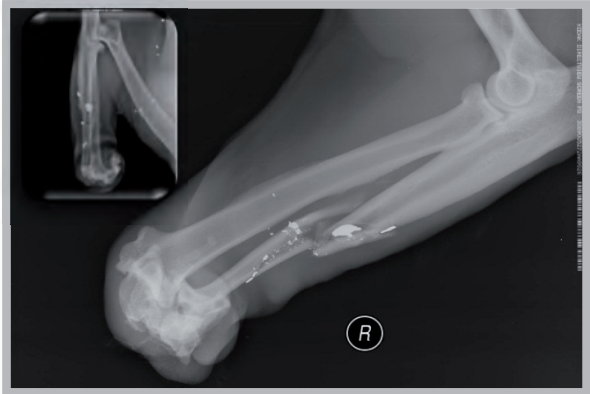

Fig. 11 & 12: Lateral view radiograph of right forelimb. An old (10 to 14 days old) comminuted fracture is visible in right ulna associated with several metallic foreign bodies (gunshot) and two butterfly segments.

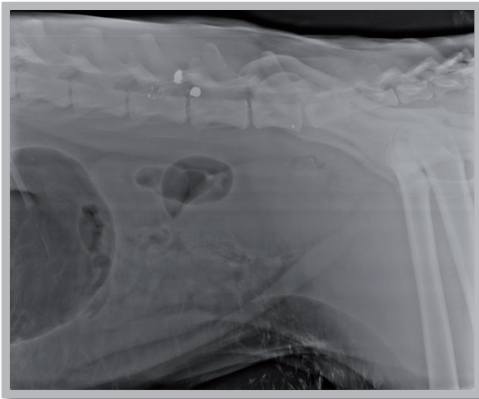


Fig. 13: Lateral view radiograph of the lumbar vertebrae. The bullet which was located in spinal canal at the level of L6 is visible.

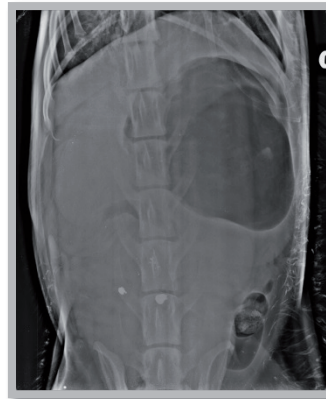

Fig. 14: Dorsoventral view radiograph of the lumbar vertebrae. The bullet which was located in spinal canal at the level of L6 is visible.

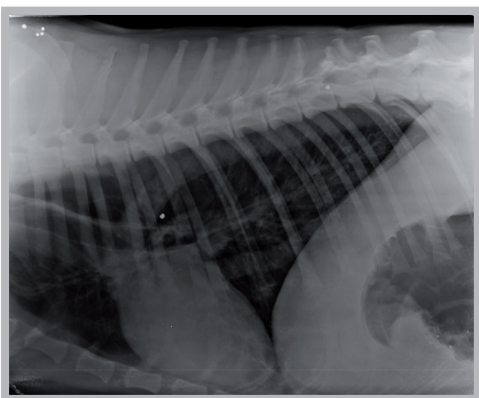


Fig. 15: Lateral view radiograph of chest. Several metallic densities are observable in radiograph (four foreign bodies at dorsal region of the scapula and one in right side near the T10).

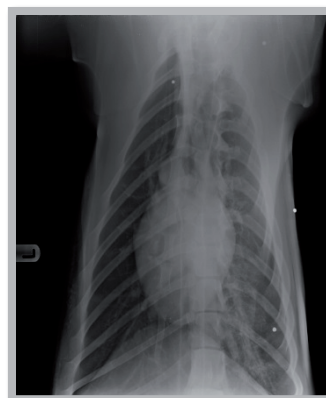

Fig. 16: Dorsoventral view radiograph of chest. Increased opacity of right lobes of lungs with interstitial pattern are diagnose as consequence of long time recumbency or pulmonary haemorrhage.

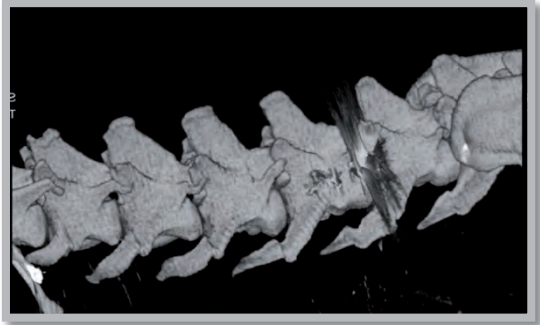


Fig. 17: A 3-dimensional reconstruction with implant algorithm, showing the gunshot.

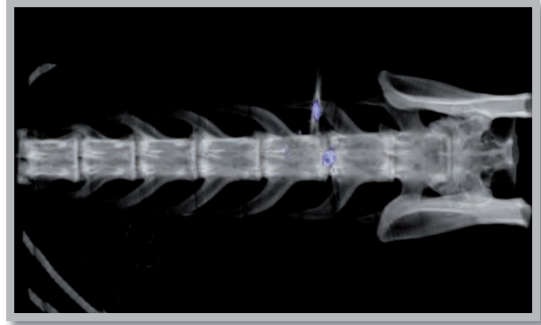


Fig. 18: A 3-dimensional reconstruction with bone algorithm, showing the gunshot (with ring artefacts) and vertebral injury.



Fig. 19: Lateral view of vertebral column after preparation. The puncture caused by bullet is visible on L5.
Photo: Alireza Shahrđari

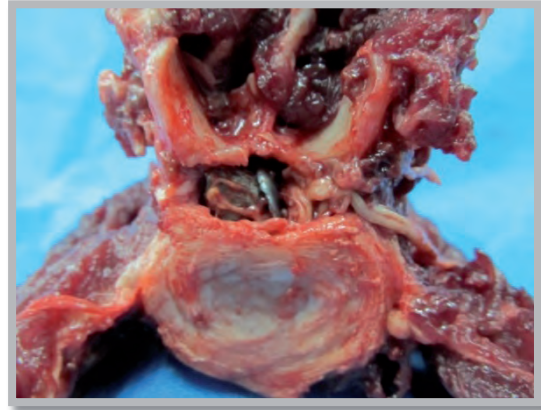


Fig. 20: Cranial view of vertebral column. The bullet and injured spinal cord are visible on L6 canal.
Photo: Alireza Shahrđari

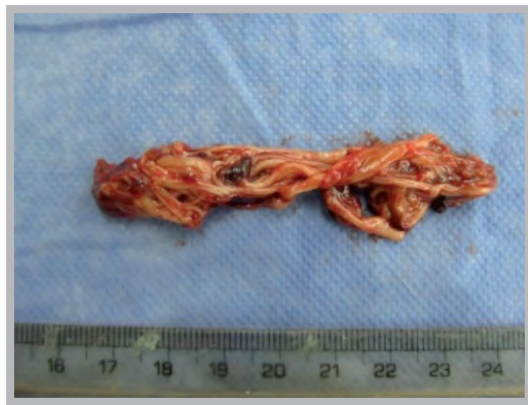

Fig. 21: Macroscopic view of the injured part of spinal cord and pieces of bullet. Photo: Alireza Shahrđari

Conclusion

The presented case shows only one example of the conflict between humans and predatory animals. People in rural areas of Iran have a long history of livestock and range management. They have experienced lots of traditional management system based on their nomadic life. The transformation of rural people's life style from nomadic to permanent settlement, as well as the change of range management from tribal to government controlled, has eliminated people's sense of ownership. As a result, the over usage of natural resources has been raised. In northern forest of Iran, free ranging cattle as well as prey poaching is one the major threats to these vulnerable habitats and its iconic species, Persian leopard.

The locals try to adapt the nature to their cattle farming by reducing predator population, which helps them to reduce their costs. This reported case is also one of the victims of these threats.

Such incidents are also caused by the rural economy. To succeed in the conservation of Persian leopard in this habitat, we need to have a short remedy and a long-term plan to address this issue. A short remedy for controlling the rapid loss of this elusive species is to engage the public and increase their awareness of the existing disaster. Another, less short-term plan, is the implementation of community-based conservation projects. The insurance for the herds attacked by Persian leopards could be another short-term remedy.

Long-term plan for conservation of Persian leopard in this habitat is to find new solutions for changing cattle rising from traditional methods to methods with more efficiency and less habitat loss. Participatory programmes to revive the prey populations in this habitat, which has been, lost at least 80 % of its populations.

Acknowledgements

We would like to thank the Tehran University small animal hospital and all the staff how helps use in this procedure. Furthermore we thank Behzad Najji, Dr. Gholami and Ali Amarlui for editing this paper.

References

- KHOROZYAN I (2008): *Panthera pardus ssp. saxicolor*. In: IUCN 2013. IUCN Red List of Threatened Species. Version 2013.2.
- KIABI BH, DARESHOURI BF, GHAEMI RA, JAHANSHAHI M (2002): Population status of the Persian leopard (*Panthera pardus saxicolor* Pocock, 1927) in Iran. *Zool. Middle East* **26**, 41 - 47.
- SHORES A (1992): Spinal trauma. *Pathophysiology and management of traumatic spinal injuries*, *Vet. Clin. North Am. Small Anim. Pract.* **22**, 859 - 867.
- THRALL D (2012): *Textbook of Veterinary Diagnostic Radiology*, Saunders, 6th ed. Saunders, Elsevier, 103.
- WATERS RL, SIE IH (2003): Spinal cord injuries from gunshot wounds to the spine. *Clin. Orthop. Relat. Res.* **408**, 120 - 5.
- ZIAIE H (2012): *A Field Guide to the Mammals of Iran*, Fourth edition. Department of the Environment, Tehran, 312 - 316.

DECOMPRESSION SICKNESS: A NEW PATHOLOGICAL ENTITY IN MARINE TURTLES

CRESPO-PICAZO JL¹, GARCÍA-PÁRRAGA D¹, BERNALDO DE QUIRÓS Y⁴,
DÍAZ-DELGADO J⁴, CERVERA V², MARTÍ-BONMATÍ L³, ARBELO M⁴, FERNÁNDEZ A⁴

¹Oceanografic, Veterinary Services, Ciudad de las Artes y las Ciencias, 46013 Valencia, SPAIN;
jlcespo@oceanografic.org

²Hospital Veterinario Valencia Sur, 46460 Valencia, SPAIN

³Radiology Service, Hospital Quirón Valencia, 46010 Valencia, SPAIN

⁴Universidad de Las Palmas de Gran Canaria, Institute of Animal Health, Veterinary Histology and Pathology, 35007 Las Palmas de Gran Canaria, SPAIN

We describe “gas systemic embolism” linked to by-catch as a new clinical and pathological entity, resembling decompression sickness (DCS), in marine turtles.

Sea turtles are along the longest and deepest diving of the air-breathing vertebrates. It has been hypothesised that at present, the minimal susceptibility to the underlying “DCS” is the result of evolution of physiologic and/or behavioural mechanisms for compensation.

By-catch induced death it is supposed to be caused by drowning, resulting in a worldwide common problem. Here we report an “*in vivo*” and “*post mortem*” diagnosis of systemic gas embolism as an additional cause of death in 31 by-catched loggerhead sea turtles (*Caretta caretta*) which were recovered dead or still alive from fishing gear. Diagnosis in live animals was made based on different clinical diagnostic techniques as well systematic and detailed necropsy and histopathology on dead turtles. Additional gas analysis was also performed on dead turtles. Based on these observations, a final diagnosis of “acute gas embolism” consistent with “DCS” was confirmed in several specimens.

This finding has direct implications for sea turtle conservation through appropriate diagnosis, treatment and subsequent release of live surfaced bycatch animals. Many of the turtles recovered alive from net gears could subsequently die because of DCS. It could be essential to review regional sea turtle bycatch interventional protocols worldwide to ensure health status of direct release animals, and to assess the real health impact of interactions between sea turtles and the different kinds of fishing gears.

GNRH VACCINATION OF AFRICAN ELEPHANT BULLS FOR CONTRACEPTION AND BEHAVIOURAL MANAGEMENT

LUEDERS I^{1,4,5}, YOUNG D², BOTHA S³, GRAY C^{1,3}, LUTHER I^{1,4,5}, MAREE L⁵,
VAN DER HORST G^{4,5}, TINDALL B⁶, BERTSCHINGER HJ⁷

¹GEOLifes- Animal Fertility and Reproductive Research, 22457 Hamburg, GERMANY;
imke.lueders@geolifes.com

²African Elephant Research Unit, Knysna Elephant Park, Plettenberg Bay, SOUTH AFRICA

³African Lion Safari, RR#1 Cambridge, Ontario N1R 5S2, CANADA

⁴National Zoological Gardens of South Africa, Research Dept., 0001 Pretoria, SOUTH AFRICA

⁵University of the Western Cape, Dept. of Life Sciences, Private Bag XI7, 7535 Bellville, SOUTH AFRICA

⁶Robberg Vet Clinic, 56 Longship Drive, Plettenberg Bay, Western Cape, SOUTH AFRICA

⁷Veterinary Faculty of Pretoria, Onderstepoort, Private Bag X04, 0110 Pretoria, SOUTH AFRICA

Elephant and human conflicts are a common problem in Asian and African range countries, where habitats continue to diminish. Bulls were observed to be more likely to approach human settlements and to become regular crop raiders. In this study on 13 African elephant bulls, we examined the effect of the commercial piglet GnRH vaccine Improvac[®] (Pfizer Animal Health, Johannesburg, South Africa) on reproductive organs, hormone levels, sperm production and behaviour. The aim was to test if this vaccine is a potential measure for aggression (musth) and fertility control of wild and captive elephant bulls.

Over a two year period, 2 wild and 11 captive African elephant males (ages: 8 - 35 years) in South Africa were examined every six months to record the changes. After first vaccination and an initial booster six weeks later, each bull received a booster vaccination every five to six months, followed by a full examination four weeks later.

Each bull was injected with 5 ml of Improvac[®] deeply intramuscular into the gluteal muscle during each vaccination, either by hand injection or dart. The examinations took place while the bulls were either fully immobilised (M99+Detomidine) or in a standing sedation (Medetomidine OR Detomidine+ Butorphanol) within a chute or pen system. Blood samples and body measurements were taken, a transrectal ultrasound and a semen collection (either by electro ejaculation or manual prostate massage) were performed.

Serum testosterone levels dropped to non-detectable levels after the 2nd or 3rd injection in all bulls. Similar, at the second examination (after three vaccinations), the testicle diameter had already significantly declined. At the end of the study, the testicle size (measured as the area in the 2D ultrasound image) had declined by almost 60 %.

While the semen collection showed viable spermatozoa in all naïve, mature bulls, after three vaccinations, either no spermatozoa were found anymore or immotile spermatozoa with a large proportion of head and tail separation were detected. Seminal plasma volumes declined. This was reflected by the reduced size and fluid content of the accessory sex glands (seminal vesicles and ampullae). None of the bulls came into musth, and in the oldest bull of the study, who was in musth when received the first injection, it ceased immediately and was not observed again. In two other cases, bulls that were known to dismantle gates or fences, or threaten tourist vehicles, were not observed to break anything ever since the vaccinations started. From our results so far, we conclude that the GnRH vaccine has the potential as a contraceptive tool and may also be used in wild "problem elephant bulls".

ANTIMICROBIAL RESISTANCE IN *ESCHERICHIA COLI* ISOLATED FROM WILDLIFE ANIMALS IN POLAND

WASYL D¹, ZAJĄC M¹, HOSZOWSKI A¹, JABŁOŃK J², LALAK A¹, SAMCIK I¹,
SKARŻYŃSKA M¹, SZULOWSKI K¹

¹National Veterinary Research Institute, Dept. of Microbiology, Partyzantów 57, 24-100 Puławy, Poland; wasyld@piwet.pulawy.pl

²National Veterinary Research Institute, Dept. of Swine Diseases, Partyzantów 57, 24-100 Puławy, Poland

Wildlife reservoirs of antimicrobial resistance were tested in *Escherichia (E.) coli* isolated from hunted red deer (n = 225), roe deer (n = 76), fallow deer (n = 24), European bison (n = 3, sanitary shot), and wild boar (n = 332). The samples were collected during 46 hunting events within two seasons (2012/2013, n = 7 and 2013/2014, n = 39) in 37 regional forests scattered over the whole territory of Poland. Direct streak of faeces on MacConkey agar followed by PCR identification (*uspA*) resulted in 542 *E. coli* (82.1 % isolation rate). Resistance (MIC, EUCAST epidemiological cut-offs) was found against 11 of 14 tested antimicrobials reaching the highest values for sulfamethoxazole (6.6 %), streptomycin (1.8 %), ampicillin, trimethoprim, and tetracycline (1.3 % each). Chloramphenicol, nalidixic acid, ciprofloxacin, gentamicin, kanamycin, and colistin resistances ranged between 0.2 % and 0.9 %. Although no significant differences were observed between *E. coli* isolated from wild boars (n = 278) and ruminants (n = 264), the values for the latter category were slightly lower with no ampicillin, gentamicin, kanamycin, chloramphenicol, and quinolone resistance. Moreover, none fallow deer and bison isolates showed any resistance. Simultaneously, the same samples streaked on cefotaxime-supplemented MacConkey agar gave estimates of cephalosporin-resistant *E. coli*. The overall prevalence was 1.7 % with single isolates obtained from fallow and red deer and nine from wild boars (prevalence within the wild boar population 2.7 %, CI95 % 1.0÷4.5 %). Cephalosporin-resistance mechanisms were identified (E-test[®], PCR) as extended-spectrum beta-lactamases (*bla*_{CTX-M}, n = 3) and *ampC*-type cephalosporinases (*bla*_{CMY-2}, n = 9, including both deer isolates). Interestingly, four CMY-2 and two CTX-M-positive isolates originated from six wild boar shot during single hunting gave assumption for a common environmental reservoir. Since none of the cephalosporin resistant isolates harboured pathogenicity markers (PCR) typical for enteropathogenic, enteroaggregative, enterotoxigenic, enteroinvasive or verotoxin-producing *E. coli* they might be considered a vector of resistance determinants, but not the pathogen themselves.

ISOSPORA SPP. CAUSING SIMULTANEOUS VISCERAL (“ATOXOPLASMOSIS”) AND ENTERIC COCCIDIOSIS IN SUPERB GLOSSY STARLINGS, AND VISCERAL COCCIDIOSIS IN BLACK THROATED LAUGHING THRUSHES

SMITH DA¹, STASIAK IM^{1,2,3}, HAFEEZ MA¹, DELNATTE P^{1,2,4}, BARTA JR¹

¹University of Guelph, Ontario Veterinary College, Dept. of Pathobiology, 50 Stone Rd E., Guelph, Ontario N1G 2W1, CANADA; dalesmit@uoguelph.ca

²Toronto Zoo, 361A Old Finch Ave, Toronto, Ontario M1B 5K7, CANADA

³Current address: Government of the Northwest Territories, Dept. of Environment and Natural Resources, Box 1320, Yellowknife, Northwest Territories X1A 2L9, CANADA

⁴Current address: Université de Montréal, Faculté de Médecine Vétérinaire, 3200, rue Sicotte Saint-Hyacinthe, Québec J2S 2M2, CANADA

Systemic coccidiosis (“atoxoplasmosis”) was identified on histopathology as the cause of significant fledgling mortality in captive superb glossy starlings (SGS) (*Lamprotornis superbus*) and black-throated laughing thrushes (BTLT) (*Garrulax chinensis*) in a Canadian zoo. Necrosis and a mixed heterophilic and mononuclear inflammatory reaction were present in association with intracellular and free parasites in a variety of tissues. Molecular evaluation of the nuclear 18S rDNA and the mitochondrial cytochrome *c* oxidase subunit I (COI) loci in tissues and oocysts obtained from the SGS revealed the presence of two distinct *Isospora* species. Oocysts of the two species were morphologically indistinguishable from each other. Simultaneous intestinal and extra-intestinal infection with two morphologically similar but genetically divergent *Isospora* spp. was thus confirmed in the SGS by species-based genotyping of the parasites. A third genotypically distinct *Isospora* sp. was identified in tissues from the BTLT, but shedding of this organism could not be confirmed as no oocysts were detected in faeces. This work shows the value of DNA barcoding techniques in detecting and differentiating pathogenic coccidia, and in connecting morphologically diverse life stages in different tissues.

Acknowledgements

We would like to thank the Toronto Zoo for graduate student support for Stasiak and Delnatte, and the staff of the Toronto Zoo for faecal sample collection.

SERUM PREVALENCE OF ANTIBODIES TO COMMON FELID PATHOGENS IN PALLAS'S CATS (*OTOCOLOBUS MANUL*) FROM THE DAURIAN STEPPES, EASTERN RUSSIA

NAIDENKO S¹, PAVLOVA E¹, KIRILYUK V²

¹A.N. Severtsov Institute of Ecology and Evolution, 119071, Leninsky pr. 33, Moscow, RUSSIA; snaidenko@mail.ru

²Daurisky State Nature Biosphere Reserve, 674480, Komsomolskaya str., 76, v. Nizhnii Tsasuchei, Ononskii District, Zabaikalskii Krai, RUSSIA

The Pallas's cat (*Otocolobus manul*) is a small endangered wild cat with a wide distribution in central Asia. Habitats of Pallas's cats are fragmented and distribution depends on topographic relief, snow depth and presence of rodents and pikas. The aim of this study was to measure the exposure to 15 different pathogens in wild Pallas's cats from the Daurian region of the Central Asian steppes, Russia, and to estimate serum prevalence of *Toxoplasma gondii* antibodies in free-ranging domestic cats and potential prey animals of Pallas's cat. The Pallas's cat is very susceptible to *T. gondii* and in captivity infection may result in the death of kittens. Serum prevalence of *T. gondii* antibodies was reported with 13 % in Pallas's cats in Mongolia, but nothing is known about the prevalence in Russia. The study was conducted in Dauriskii reserve, Zabaikalskii krai. We captured and blood sampled 20 Pallas's cats, a total of 61 house cats from the nearest village (n = 33) and herdsmen's stations (n = 28), 149 rodents of six species, and five pikas. Pallas's cat serum samples were tested for IgG antibodies against feline panleukopenia virus, canine distemper virus, feline herpes viruses, pseudorabiesvirus, feline immunodeficiency virus, feline coronavirus, influenza A virus, *Chlamydia* sp., *Mycoplasma* sp., *T. gondii*, *Candida* sp., *Dirofilaria* sp., *Trichinella* sp., *Coxiella burnetii* and feline leukemia virus antigens. EIA was to detect antibodies to eleven different pathogens (Chema-Medika and Narvak, both, Russia; IDvet (France; Immunocomb, Israel), and speed test were used for four other pathogens (including FLV antigene, Chema-Medica, Russia; BVT, France). All other samples were proceeded for IGG antibodies to *T. gondii* (EIA, Chema-Medica, Russia). Some Pallas's cats were seropositive to *T. gondii* (13 %), *Mycoplasma* sp. (13 %), feline leukemia virus (8 %) and influenza A virus (8 %), but seronegative to all other tested pathogens. *T. gondii* was present in both, house cat population and rodents of Daurian steppes. At least 15 % of house cats were seropositive to *T. gondii*. The percentage of seropositive cats was almost the same for the village (15 %) and herdsmen's stations (14 %). The percentage of seropositive animals among potential prey was 2.7 % (mainly *Cricetulus pseudogriseus*). This shows that house cats may be considered as reservoir of *T. gondii* in Pallas' cat habitats. Moreover, *T. gondii* might be able to complete its life cycle in the Pallas's cats and that these felids may also contribute to infection of other intermediate hosts. We showed for the first time that *T. gondii* is distributed in Pallas's cat habitats among their prey and competitive species (domestic cats). Consequences of this for Pallas's cat population should be studied in this region.

This study was conducted by Russian Geographical Society and RFBR (14-04-01119).

GENOTYPES OF *TOXOPLASMA GONDII* ISOLATED FROM PALLAS'S CATS WITH FATAL TOXOPLASMOSIS

BARTOVA E¹, SEDLAK K², NAGL I³, V} DIČKA R⁴, AJZENBERG D^{5,6}, SLEZAKOVÁ R¹

¹University of Veterinary and Pharmaceutical Sciences, Faculty of Veterinary Hygiene and Ecology, Dept. of Wildlife Diseases, Palackého tř. 1/3, 612 42 Brno, CZ_CH REPUBLIC; bartovae@vfu.cz

²State Veterinary Institute Prague, Dept. of Virology and Serology, Sídlištní 136/24, 165 03 Prague 6, CZECH REPUBLIC

³State Veterinary Institute Prague, Dept. of Pathology and Parasitology, Sídlištní 136/24, 165 03 Prague 6, CZECH REPUBLIC

⁴Zoological Garden in Prague, U Trojského zámku 3/120, 171 00 Prague, CZECH REPUBLIC

⁵Centre National de Référence (CNR) Toxoplasmose/Toxoplasma Biological Resource Center (BRC), Centre Hospitalier-Universitaire Dupuytren, 87042 Limoges, FRANCE

⁶INSERM UMR 1094, Neuroépidémiologie Tropicale, Laboratoire de Parasitologie-Mycologie, Faculté de Médecine, Université de Limoges, 87025 Limoges, FRANCE

Summary

Pallas's cats (*Otocolobus manul*) are small cats sensitive to *Toxoplasma gondii* infection. The cases of fatal toxoplasmosis were recorded in Pallas's cats kept in different zoos. In the Czech Republic, there were also similar cases, however still not published. The aim of this study was to characterise genotypes of *T. gondii* isolated from Pallas's cats with acute toxoplasmosis. In total, 12 Pallas's cats died during the years 2004 to 2013 in four zoos in the Czech Republic. Toxoplasmosis was proved in 8 of 12 (66.6 %) Pallas's cats. The prominent pathological and histological lesions were pulmonary oedema, necrosis and interstitial bronchopneumonia with mononuclear infiltrations, enlarged and discoloured liver with focal necrosis of hepatocytes and nonsuppurative infiltrations and enlarged spleen. Tachyzoites and tissue cysts of *T. gondii* were seen in lung, spleen, liver, brain, cerebellum and heart. *T. gondii* antibodies were detected in eight Pallas's cats *post mortem*. Successful genotyping by multiplex PCR was finished in five Pallas's cats. Despite of acute course of infection, all of the isolates belonged to genotype II, which is the most prevalent in Europe. This is the first characterisation of *T. gondii* isolated from Pallas's cats.

Introduction

Pallas's cats (syn. *Otocolobus manul*) are endangered wild cats from Central Asia kept and bred in many zoos. They belong to the animal group that is very sensitive to *Toxoplasma gondii* infection, especially the kittens. These frequently die from acute toxoplasmosis, which is therefore despite good breeding success, threatening the captive population. The first case report of fatal toxoplasmosis was on two 6 weeks old cats (RIEMANN et al., 1974), followed by a 6 year old cat from Milwaukee Zoo, USA (DUBEY et al., 1988). In 1996, 6 of 17 young Pallas's cats died because of toxoplasmosis in US American zoos (KENNY et al., 2002). In Austria, 58 % (14/24) of kittens born in Vienna zoo during the years 1998 to 2002 died due to acute toxoplasmosis (BASSO et al., 2005).

In the Czech Republic, there are in total 15 zoos and 10 zoo parks; Pallas's cats have been kept in the Prague Zoo, Čáslav Zoo, Dvůr Králové Zoo, Chomutov Zoo and Jihlava Zoo. In 2003, six Pallas's cats were

transported to Czech zoos from Mongolia. In total, 12 cases of deaths were recorded in Pallas's cats during years 2004 to 2013.

The reason of high sensitivity of Pallas's cats to toxoplasmosis has been studied (BROWN et al., 2005) however till now there is no report about genotypes of *T. gondii* in Pallas's cats. The aim of this study is to characterise genotypes of *T. gondii* isolated from Pallas's cats with acute toxoplasmosis.

Material and methods

During the years 2004 to 2013, 12 cases of death were recorded in Pallas's cats coming from four zoos (Prague, Pátek, Ústí nad Labem and Chomutov). Six Pallas's cats died in year 2004 (four Pallas's cats from Prague and two from Pátek's cats from Zoo Prague) and the other cases of death were recorded in year 2006 (Zoo Ústí nad Labem), 2007 (Zoo Prague), 2008 (Zoo Prague), 2009 (Zoo Chomutov) and 2013 (Zoo Chomutov).

The following examinations were performed at State Veterinary Institute Prague: pathological examination of carcasses, impression smear of different tissues (lungs, brain, cerebellum, liver, heart, and spleen) stained with Diff Quick, histopathology, isolation assay and detection of *T. gondii* antibodies in blood of Pallas's cats by indirect immunofluorescence (IFAT) *post mortem*.

Tissues of Pallas's cats were examined also by PCR (SAG2) and in case of positive amplification, multiplex PCR (AJZENBERG et al., 2010) for 15 microsatellites (*TUB2*, *W35*, *TgM-A*, *B18*, *B17*, *M33*, *MIV*, *MXI*, *M48*, *M102*, *N60*, *N82*, *AA*, *N61*, *N83*) was used for genotyping at Laboratoire de Parasitologie-Mycologie, Limoges, France.

Results and discussion

Toxoplasmosis was proved in 8 of 12 (66.6 %) carcasses of Pallas's cats. The prominent lesions were seen in lung (pneumonia and pulmonal oedema), liver (enlarged and discoloured) and spleen (enlarged). Microscopically, the predominant lesion was necrosis. Pulmonary lesions were characterised by necrosis and interstitial bronchopneumonia with mononuclear infiltrations. The hepatic lesions were characterised by focal necrosis of hepatocytes with nonsuppurative infiltrations. Tachyzoites and tissue cysts of *T. gondii* were seen in lung, spleen, liver, brain, cerebellum and heart (figure 1). *T. gondii* antibodies with titers in range of 640 - 5120 for IgM and 640 - 40960 for IgG were detected in eight Pallas's cats *post mortem*.

Successful genotyping by multiplex PCR was finished in five Pallas's cats (isolate: Manul1-CZ, Manul5-CZ, Manul6-CZ, Manul7-CZ and Manul3214-CZ) (table 1). All isolates were characterised as avirulent genotype II that is most prevalent in Europe. Genotypes of two isolates (manul no. 2 and 3 from Zoo Prague – see table 1) were identical what is evidence for the same source of infection. Genotypes of other three isolates from manul no. 1, 5 and 3214 were similar. However, all five genotypes are unique in the database of *T. gondii* genotypes with microsatellite markers (Daniel Ajzenberg, personal communication).

Acute fatal toxoplasmosis was described in young and also adult Pallas's cats in different zoos (RIEMANN et al., 1974; DUBEY et al., 1988; KENNY et al., 2002; BASSO et al., 2005) and similarly in our study. There is about 60 % mortality in Pallas's cats from North American zoos (BROWN et al., 2005) and 58 % mortality in Austria (BASSO et al., 2005). The reason for the high susceptibility of Pallas's cats to *T. gondii* infection was studied by BROWN et al. (2005). They found out *T. gondii* antibodies in 100 % (9/9) Pallas's cats from American zoos while only 13.3 % (2/15) prevalence in Pallas's cats from Mongolia. No evidence for exposure to *T. gondii* was found in any of the Mongolian domestic cats (n = 15) or prey species (n = 45) such as rodents and pikas. Pallas's cats have minimal

opportunity for exposure to *T. gondii* in their natural habitat of Central Asia and do not become infected with this parasite until being brought into captivity.

Tab. 1: Characteristic of five *T. gondii* isolates isolated from Pallas's cats with acute toxoplasmosis.

No.	Zoo and year/month of death	Sex, age (weight)	<i>T. gondii</i> - IFAT (titres of IgM and IgG)	Isolate
1	Děčín, 2004/3	F - subadult (2 kg)	IgM 1280, IgG 1280	Manul1-CZ
2	Praha, 2004/10	M - young (977 g)	IgM 5120, IgG 40960	Manul5-CZ
3	Praha, 2004/10	F - young (845 g)	IgM 1280, IgG 20480	Manul6-CZ
4	Děčín, 2004/12	F - adult (3.2 kg)	IgM 640, IgG neg.	Manul7-CZ
5	Ústí n. Labem, 2006/8	M - adult (3.5 kg)	IgM neg., IgG 2560	Manul3214-CZ

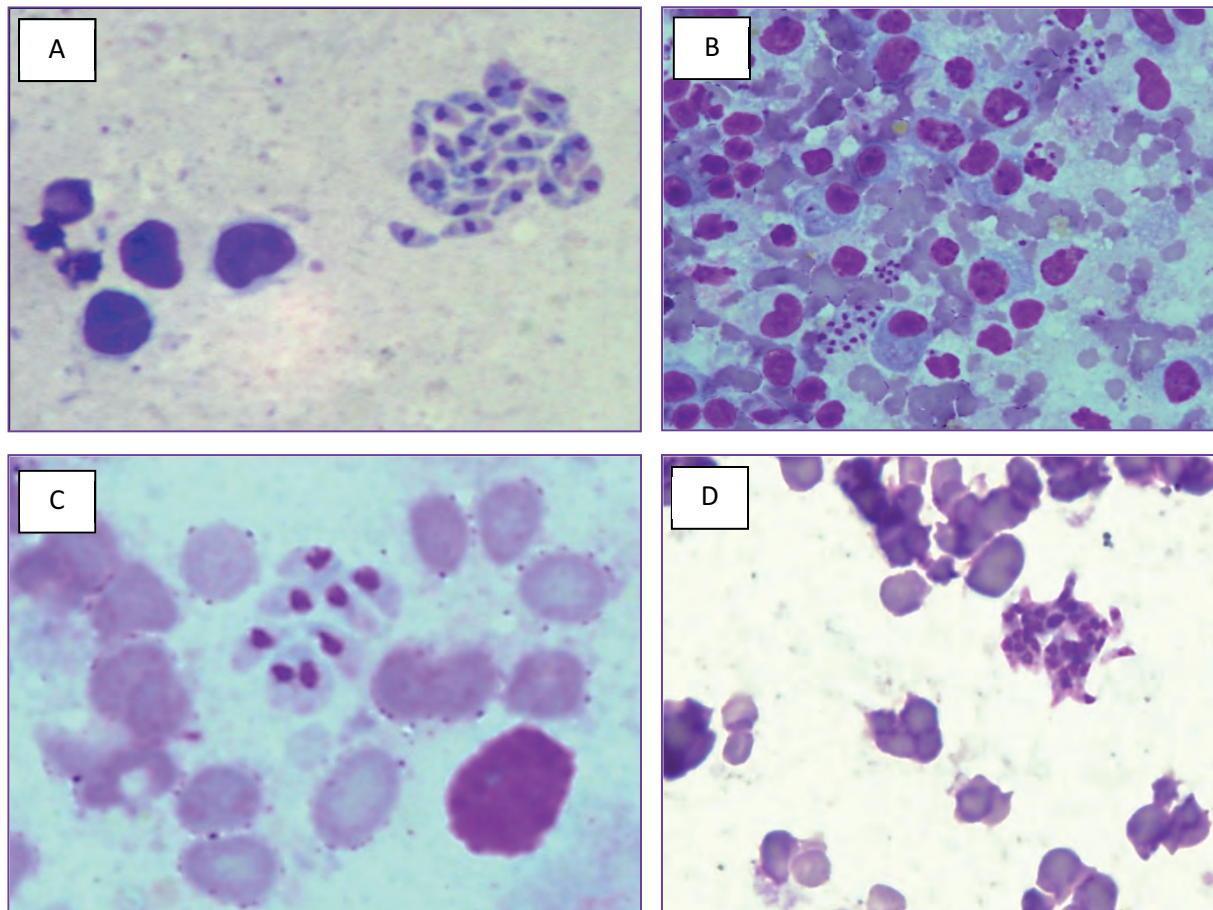


Fig. 1: Tachyzoites of *Toxoplasma gondii* in smear impressions of different tissues of Pallas's cats with acute toxoplasmosis: A – lung, B - spleen, C – liver, D - heart. Staining with Diff Quik. (Photos: Kamil Sedlák)

There are no published data focusing on characterisation of *T. gondii* isolated from Pallas's cats. In Europe, there is predominant genotype II or less frequently genotype I found in different groups of animals or human with toxoplasmosis. Genotype I is highly virulent for laboratory mice and is usually connected with acute fatal toxoplasmosis while genotype II is more frequently connected with chronic

T. gondii infection. In our study, we characterised genotype of five isolates from Pallas's cats and despite of acute course of infection all of them belong to genotype II.

References

- AJZENBERG D, COLLINET F, MERCIER A, VIGNOLES P, DARDÉ ML (2010): Genotyping of *Toxoplasma gondii* isolates with 15 microsatellite markers in a single multiplex PCR assay. *J. Clin. Microbiol.* **48**, 4641 - 4645.
- BASSO W, EDELHOFER R, ZENKER W, MOSTL K, KUBBER-HEISS A, PROSL H (2005): Toxoplasmosis in Pallas' cats (*Otocolobus manul*) raised in captivity. *Parasitology* **130**, 293 - 299.
- BROWN M, LAPPIN MR, BROWN JL, MUNKHTSOG B, SWANSON WF (2005): Exploring the ecologic basis for extreme susceptibility of Pallas' cats (*Otocolobus manul*) to fatal toxoplasmosis. *J. Wild. Dis.* **41**, 691 - 700.
- DUBEY JP, GENDRONFITZPATRICK AP, LENHARD AL, BOWMAN D (1988): Fatal toxoplasmosis and enteroepithelial stages of *Toxoplasma gondii* in a Pallas' cat (*Felis-manul*). *J. Protozool.* **35**, 528 - 530.
- KENNY DE, LAPPIN MR, KNIGHTLY F, BAIER J, BREWER M, GETZY DM (2002): Toxoplasmosis in Pallas' cats (*Otocolobus felis manul*) at the Denver Zoological Gardens. *J. Zoo Wild. Medicine* **33**, 131 - 138.
- RIEMANN HP, FOWLER ME, SCHULZ T, LOCK A, THILSTED J, PULLEY LT, HENRICKSON RV, HENNESS AM, FRANTI CE, BEHYMER DE (1974): Toxoplasmosis in Pallas' cats. *J. Wild. Dis.* **10**, 471 - 477.

FATAL TOXOPLASMOSIS IN TWO JUVENILE SLENDER-TAILED MEERKATS (*SURICATA SURICATA*) IN A GERMAN ZOO – CLINICAL, PATHOLOGICAL AND SEROLOGICAL FINDINGS

KRENGEL A¹, KNAUF-WITZENS T¹, SÜß-DOBROWSKI C², SCHWABE I², SCHARES G³

¹Wilhelma, Zoologisch-Botanischer Garten, Wilhelma 13, 70376 Stuttgart, GERMANY;
annika.krengel@wilhelma.de

²CVUA Stuttgart, Chemical and Veterinary Investigations Office Stuttgart Schaflandstraße 3/3, 70736 Stuttgart, GERMANY

³Friedrich-Loeffler-Institut, Federal Research Institute for Animal Health, Institute for Epidemiology, Seestraße 55, 16868 Wusterhausen, GERMANY

In this case report we present the clinical and pathological findings of two juvenile slender-tailed meerkats (*Suricata suricata*) which died of encephalitis due to an infection with *Toxoplasma gondii*, as well as serological results for the remainder of the group.

Slender-tailed meerkats belong to the family *herpestidae*. The diurnal mongoose is an animal which is kept in many zoos, with a life span of up to 12 - 14 years. In captivity, the diet mainly consists of insects, chicks, minced meat, commercial cat food, and a small amount of vegetables and fruits. In spring 2013, a new exhibit was opened for a new meerkat group of 2.2 animals at the Wilhelma. The first cubs (0.4) were born on May 28th 2013 and a second litter (3.0) was born on July 17th 2013. There have been no further litters since.

In August 2013, the first juvenile meerkat (MK1) showed clinical neurological signs of head tilting, circling and apathy, consistent with the findings in BASSO et al. (2009) and JUAN-SALLES et al. (1997), and died after six days despite medical treatment with antibiotics, vitamins, fluids and NSAIDS. Necropsy for MK1 revealed a focal necrotising panencephalitis, non-purulent interstitial nephritis and cachexia (MK1 had always been the runt of the litter). The second juvenile meerkat (MK2) died without noticeable clinical signs in December 2013 and showed mild encephalitis, non-reactive *Toxoplasma* cysts in the brain, lympho-plasmocytic pancreatitis, non-purulent interstitial nephritis and lympho-plasmocytic hepatitis upon necropsy. Brain material from MK2 tested positive for *T. gondii* in PCR. Serum of all animals of the remaining group (2.2 adults, 3.2 cubs) tested positive for antibodies to *T. gondii* with reciprocal IFAT titers ranging from 400 to 12.800. Coprological examination of a three day pooled faecal sample from the remaining animals revealed a parasitologically negative result.

In contrast to the two published cases of *T. gondii* infection in meerkats in Spain and Argentina, our cases did not show dissemination of the agent in the bodies of the meerkats or clinical/pathological involvement of any other organ but the brain. The importance of this new finding and its implication for management decisions will be discussed.

References

- JUAN-SALLÉS C, PRATS, N, LÒPEZ S, DOMINGO M, MARCO AJ, MORÁN JF (1997): Epizootic disseminated toxoplasmosis in captive slender-tailed meerkats (*Suricata suricata*). *Vet. Pathol.* **34**, 1 - 7.
- BASSO W, MORÉ G, QUIROGA MA, PARDINI L, BACIGALUPE D, VENTURINI L, VALENZUELA MC, BALDUCCHI D, MAKSIMOV P, SCHARES G, VENTURINI MC (2009): Isolation and molecular characterization of *Toxoplasma gondii* from captive slender-tailed meerkats (*Suricata suricata*) with fatal toxoplasmosis in Argentina. *Vet. Paras.* **161**, 201 - 206.

CHALLENGES IN ORAL ADMINISTRATION OF CLIOQUINOL DISPERSED IN GEL TO PAIR-HOUSED RHESUS MONKEYS (*MACACA MULATTA*)

BAKKER J^{1*}, KLOMP R^{1*}, TE POELE EEM², LANGERMANS JAM¹,
VAN GEIJLSWIJK IM²

¹Biomedical Primate Research Centre (BPRC), Lange Kleiweg 161, 2288GJ Rijswijk, THE NETHERLANDS; bakker@bprc.nl

²Utrecht University, Faculty of Veterinary Medicine, Yalelaan 1, 3584 CL Utrecht, THE NETHERLANDS

*first authorship shared

Summary

Entamoeba spp. is a common protozoa in rhesus monkeys (*Macaca mulatta*) and humans (JOHNSON-DELANEY, 2009; LEVECKE et al., 2007). This parasite can affect the health status of macaques as the infection can cause severe diarrhoea (JOHNSON-DELANEY, 2009). Therefore, in some cases, treatment is mandatory. Metronidazole is the most common treatment for *Entamoeba* spp. in veterinary medicine (JIANG et al., 2008; WRIGHT, 2012). To handle the animals as little as possible, oral administration of the medication in e.g. drinking water would be optimal. However, the administration of metronidazole in drinking water was not successful in rhesus monkeys due to low fluid intake attributed to undesirable taste (LABBERTON et al., 2013). We investigated whether another anti amoebic medicine, clioquinol, administered via drinking water could be used to treat rhesus monkeys. A crossover study was designed in which water, medicated fluid and non-medicated fluid was provided to macaques. The normal daily water intake of 16 macaques over a 27-day period was determined. Secondly, it was investigated whether the addition of clioquinol dispersed in gel influenced the daily fluid intake. Furthermore, it was determined if the monkeys drank sufficient medicated fluid to receive a dose of 20 mg/kg/day clioquinol. The mean water uptake was 78.8 ml/kg. Monkeys drank on average 7.8 ml/kg bw less medicated fluid vs. non-medicated fluid ($P = 0.2307$). The mean intake of clioquinol for five days was 22.4 mg/kg. This study shows that it is possible to administer clioquinol in gel to rhesus monkeys in the desired dose.

Introduction

Entamoeba histolytica and *Entamoeba dispar* are well described in primates (TOFT and EBERHARD, 1998). These amoebae are facultative pathogenic and asymptomatic carriage is common. Faecal samples from rhesus monkeys housed at the Biomedical Primate Research Centre (BPRC, Rijswijk, The Netherlands) are yearly screened for *Entamoeba* spp. The number of positive faecal samples for *Entamoeba* spp. in 2010, 2011, 2012 and 2013 were 5 % (n = 628), 11 % (n = 1020), 18 % (n = 1134) and 2 % (n = 926) respectively (unpublished data). In some cases, infected rhesus monkeys experienced acute severe diarrhoea requiring immediate treatment.

No authorised medicines for the treatment of intestinal protozoa in non-human primates are available. The selection of medicine is based on experience and on literature reports, although evidence-based information on effectiveness and dosages is often lacking. Treatment options for *Entamoeba* spp. infections include clioquinol, tinidazole and the most commonly applied metronidazole (JOHNSON and DELANEY, 2009; WRIGHT, 2012). However, medicine compliance via drinking water of the latter is difficult to ensure because of the unpleasant metallic taste of metronidazole. A decrease has been

described in fluid intake after metronidazole addition in rhesus monkeys even after flavouring with syrup (LABBERTON et al., 2013). Although it was possible to administer metronidazole to some rhesus monkeys, it was concluded that this was not a clinically effective treatment (LABBERTON et al., 2013). Clioquinol could be a better option for the treatment of *Entamoeba* spp. in group-housed rhesus monkeys (BAREGGI and CORNELLI, 2012; SCHURE et al., 2013) because of its practical insolubility in water and therefore neutral taste. Clioquinol is available as a pharmaceutical compounding oral suspension of 100 mg/ml, individually dosed. However, it was decided to prepare medicated drinking water with a clioquinol concentration of 0.3 mg/ml. As clioquinol is practically insoluble in water it is necessary to prepare a dispersion of clioquinol in drinking water with carboxymethylcellulose 0.5 % to increase the viscosity, resulting in a stable dispersion.

This study investigated whether clioquinol dispersed in a gel could be successfully administered to pair-housed rhesus monkeys. Firstly, the normal water intake of 16 rhesus monkeys over a 27-day period was determined. Secondly, non-medicated fluid (carboxymethylcellulose 0.5 %) and clioquinol (0.3 mg/ml) dispersed in a gel (carboxymethylcellulose 0.5 %) was offered and daily intake was measured. It was determined whether the addition of clioquinol dispersed in gel influenced the daily fluid intake and if the amount of fluid intake was high enough to ensure the dose of 20 mg/kg/day clioquinol.

Materials and methods

Animals, housing and care

This study included 16 rhesus monkeys (*Macaca mulatta*) that originated from and were housed at BPRC: eight healthy adult females (aged 5 to 13 years, weighing 5.35 to 12.39 kg) and eight healthy males (6 to 9 years, weighing 7.4 to 11.67 kg). Males and females were housed in separate rooms. All macaques were pair-housed in the experimental facility. The rhesus monkeys had no history of oral treatment with clioquinol. Their diet consisted of one slice of bread around 8.30 a.m., 150 g of commercial monkey pellets (Sniff-Spezialitäten GmbH, Soest, Germany) around 11 a.m., enrichment at 1 p.m. (VERNES and LOUWERSE, 2010) and 150 g fruits or vegetables around 3 p.m.

During this study the drinking nipples in the cages were shut off and 600 ml drinking bottles (crystal de luxe 600 ml, Caldex Ltd, England) were placed in custom-made holders attached to the animals cages, as monkeys are known to destroy standard holders (LABBERTON et al., 2013).

Drugs

Clioquinol (5-chloro-7-iodo-quinolin-8-ol, iodochlorhydroxyquin) is a luminal amoebicide. It has been shown to possess antiprotozoal activity. The exact mechanism is unknown (MAO and SCHIMMER, 2008; NAGATA et al., 2012; SCHURE et al., 2013). The oral dose of clioquinol in humans varies between 15 mg/kg body weight (mg/kg bw) per day for children and 750 mg per day for adults. Clioquinol is used in rhesus monkeys with a dose of 20 mg/kg bw per day over a period of five days (personal communication H. Bolhuis). As daily fluid intake among rhesus monkeys varies between 49 ml and 115 ml/kg per day with an average of 75 ml/kg per day (LABBERTON et al., 2013), it was decided to prepare a clioquinol medicated fluid of 0.3 mg/ml so that an average fluid intake of 66.7 (0.3*66.7 = 20) ml/kg per day would already be adequate to administer the desired dose of 20 mg/kg clioquinol.

Clioquinol is available as a pharmaceutical compounding oral suspension of 100 mg/ml (clioquinolum, Spruyt Hillen, The Netherlands). Clioquinol is practically insoluble in water (MARTINDALE, 1996). Therefore, dissolution in drinking water is impossible and dispersion is challenging because of immediate precipitation of the clioquinol. The viscosity of the drinking water was increased by adding carboxymethylcellulose 0.5 % (carmellosum natricum, Spruyt Hillen, The Netherlands) (Geneesmiddel Informatie Centrum van de KNMP, 2013). Due to the higher viscosity the clioquinol remained homo-

geneously distributed in dispersion for at least 16 hours, as demonstrated in a precipitation experiment (unpublished data, this study). The non-medicated fluid consisted of 0.5 % carmellosum natricum in drinking water. The final medicated fluid consisted of 0.5 % carmellosum natricum and 0.03 % clioquinol (clioquinolum, Spryut Hillen, The Netherlands) in drinking water.

Experimental design

Normal water intake of all animals was determined for 27 days. Each cage housing two animals received at 9.00 a.m. and 17.00 a.m. two bottles of 600 ml fresh drinking water. At 12.00 a.m. the bottles were checked on content: if the volume was less or equal to 200 ml in one bottle, the remaining volume was determined and discarded. Subsequently the bottle was refilled with 600 ml fresh drinking water.

A crossover study was performed in which the animals were provided with medicated fluid and non-medicated fluid. The monkeys were divided into two groups. Four couples received medicated fluid and four couples received non-medicated fluid for the first consecutive days and the next week vice versa. Between these two different trials the rhesus monkeys received two days normal drinking water in drinking bottles. The monkeys received twice a day at 9.00 a.m. and 17.00 p.m. fresh filled bottles with the specific fluid. At 12.00 a.m. the bottles were checked on the content, if the volume was less or equal to 200 ml the bottle was filled with the specific fluid for that particular couple. All administered fluids were measured with a 1000 ml measuring cup (OXO Good Grips, New York).

In addition, faecal samples were collected on three consecutive days and examined one week before the medication and one week after receiving the medicated fluid. The faecal samples were directly fixed in Sodium Acetate-Acetic Acid Formalin (SAF). From the fixed SAF faeces DNA was isolated. This DNA was screened with the PCR for *Entamoeba* spp. (FOTEDAR *et al.*, 2007; JIANG *et al.*, 2008; PETRI, 2003).

During the study, the rhesus monkeys were under close veterinary supervision. The procedures performed in this study were in agreement with the regulations for animal handling as described in the EU Directive 63/2010 and with the Weatherall report (2006).

Statistical analysis

Data were collected in Excel spread sheets (Microsoft Corporation, Redmond, USA) and average intake per pair of monkeys per week was determined. These averages were transferred for graphing and statistical evaluation in Prism 6 for Mac OS X, version 6.0c (Graph Pad Software). To determine if water intake reached a steady state, a regression line was drawn for all couples and inclination was calculated. The differences in fluid intake were initially compared using paired t-tests. To test whether there was a difference between the mean intake of medicated fluid over five days and the desired volume for 20 mg/kg a one-sample t-test was used. P values of <0.05 were considered statistically significant.

Results

The mean daily water intake over a 27-day period was 78.8 ml/kg bw. However, the water intake showed a significant increase of 9.6 ml/kg bw per week over those 27 days. It was decided to use only the last 5 days of these 27 days to calculate the mean water intake (90.5 ± 29.1 ml/kg bw) and compare these values with the intake of medicated and non-medicated fluid.

The mean intake of medicated fluid was 74.7 ± 37.5 ml/kg bw and the mean intake of non-medicated fluid was 82.6 ± 41.28 ml/kg bw. Monkeys consumed on average 15.7 ml/kg less medicated fluid in comparison to water intake ($P = 0.0329$). Monkeys drank on average 7.9 ml/kg bw less non-medicated

fluid vs. water ($P = 0.1875$). Monkeys drank on average 7.8 ml/kg bw less medicated fluid vs. non-medicated fluid ($P = 0.2307$) (figure 1, 2).

The average intake of medicated fluid was 74.7 ml/kg resulting in an average intake of cloiquinol of 22.4 mg/kg bw. This mean value did not significantly differ from 20 mg/kg ($P = 0.5624$) (figure 3). All faecal samples taken before and after cloiquinol treatment were negative for *Entamoeba* spp.

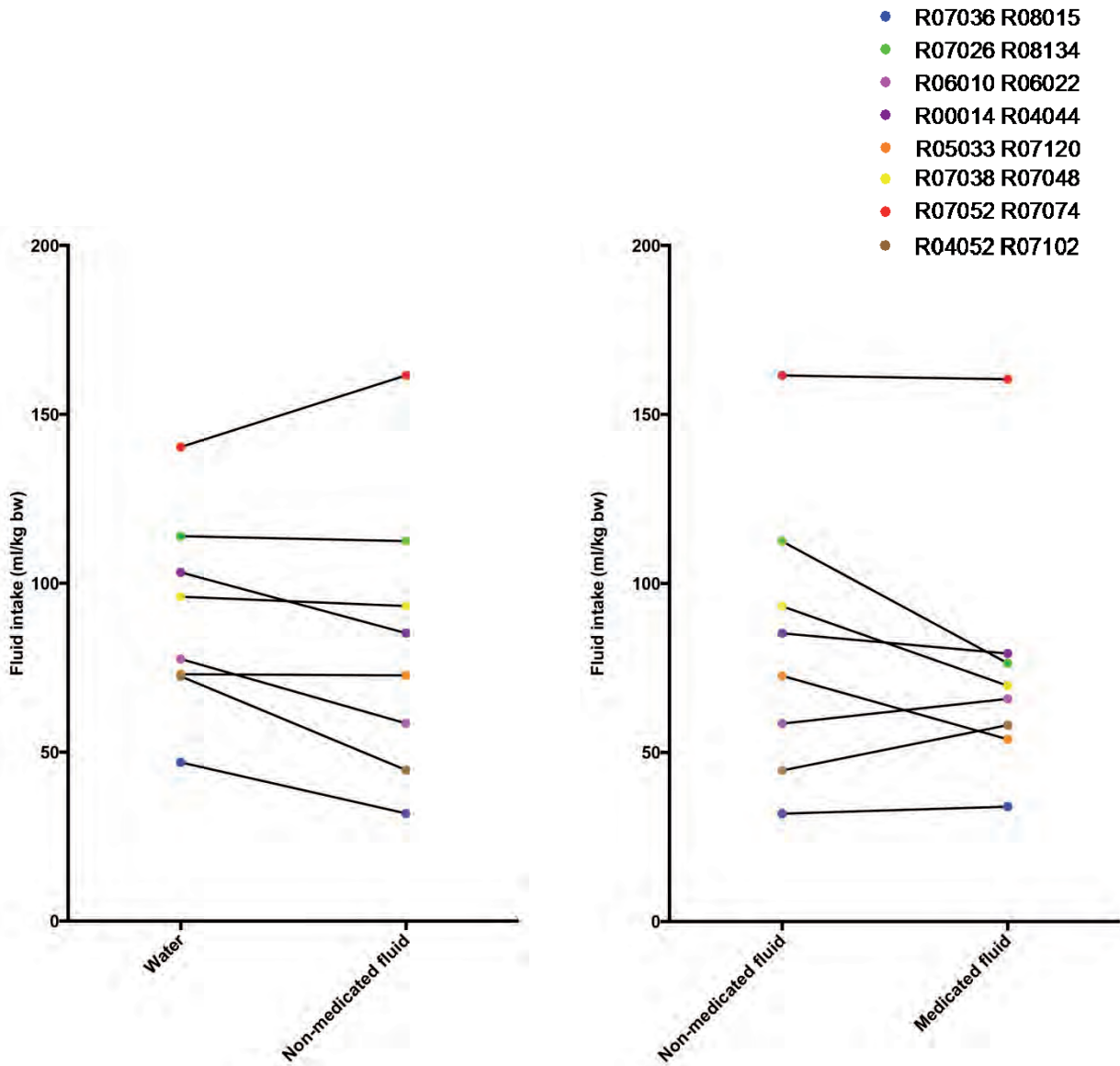


Fig. 1: Comparison of water and non-medicated fluid intake ml per kg bodyweight. The couples showed a decrease of 7.9 ml/kg bw between water and non-medicated fluid.

Fig. 2: Comparison of average non-medicated fluid and medicated fluid intake ml per kg bodyweight. The couples showed a decrease of 7.8 ml/kg bw between non-medicated and medicated fluid.

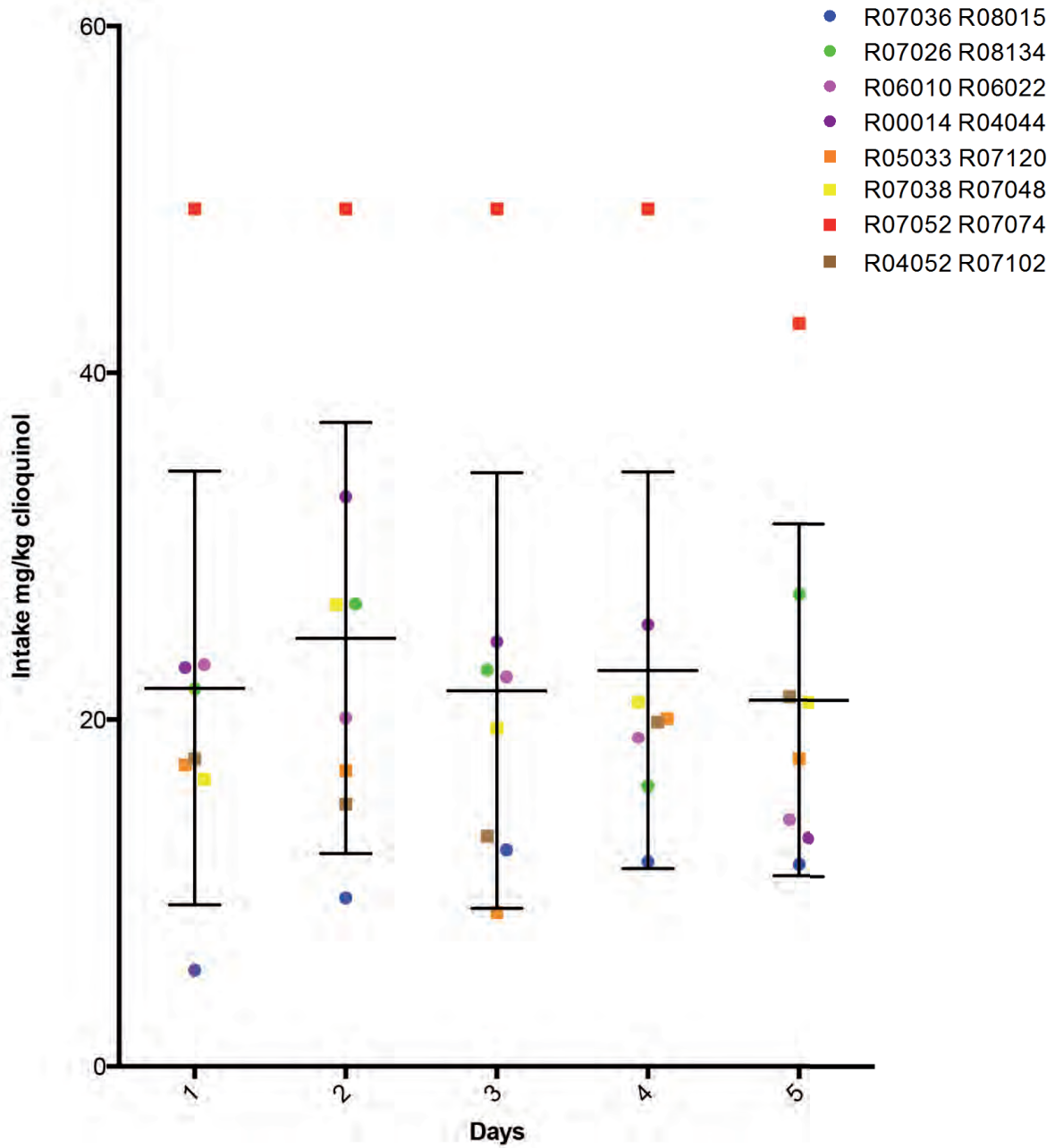


Fig. 3: Mean (\pm SD) daily intake clioquinol (mg/kg bw) per couple for five days. Circle sign: female macaques, square sign: male macaques.

Discussion

This study investigated whether replacement of drinking water by medicated fluid resulted in sufficient intake of the medication in rhesus monkeys. It showed that it is possible to administer 20 mg/kg for five consecutive days to rhesus monkeys. The monkeys had a mean intake of 22.4 mg/kg bw clioquinol in five days however the inter- and intravariation between monkeys make it difficult to ensure that all individual monkeys drank enough of medicated fluid for the therapy of *Entamoeba* spp. This is in general de major disadvantage of medicated drinking water: the price for less stressful administration of medication is less accurate individual dosing.

Switching from drinking nipples to drinking bottles is possible. However, the rhesus monkeys may require a longer adaptation period to reach a steady water uptake per kg body weight per day. Our observations suggest that more than four weeks are required for habituation to drinking bottles. However, after four weeks the animals still did not reach a steady state phase. Instituting a longer acclimation period for the macaques to become accustomed to the drinking bottles before beginning the study could have addressed the lack of familiarity. In the case of acute illness demanding immediate treatment, such as severe diarrhoea resulting from intestinal protozoan infection, such a long acclimation period is not feasible.

The daily fluid intake of the eight pairs during the last five days of the 27 days water intake measurement was higher than expected on the basis of literature reports ± 90 ml/kg versus 75 ml/kg bw. This discrepancy could result from differences in diet, housing conditions and other variables or from the macaques' unfamiliarity with the drinking bottles.

Further research is needed to evaluate the effective dose of clioquinol in rhesus monkeys. In our study a doses of 20 mg/kg/day is used for five days. However, to what extent achieving 20 mg/kg is relevant for adequate therapy is not clear, because there are no pk/pd studies or formal efficacy studies performed for clioquinol in rhesus monkeys. We aim to test this in infected animals in our colony In future studies.

The results showed that it is possible to administer clioquinol dispersed in a gel in drinking bottles to rhesus monkeys. This strategy is not yet a reliable method because of wide variation of fluid and clioquinol intake between pairs. However, drinking water medication leads by definition to concessions to the individual dosing because of the inter- and intravariation. The risk on side effects due to over-dosing is low as neurological toxicity has only been observed in animals when treated with clioquinol at doses exceeding 200 mg/kg per day for a month and doses of 400 mg/kg per day for a week (MAO and SCHIMMER, 2008; WORDEN et al., 1978). Oral administration of clioquinol by medicated drinking water will facilitate treatment of macaques infected with amoeba.

Acknowledgements

The authors gratefully thank the help of the caretakers.

References

- BAREGGI SR, CORNELLI U (2012): *Clioquinol: Review of its Mechanisms of Action and Clinical Uses in Neurodegenerative Disorders*. *CNS Neurosci Ther* **18**, 41 - 46.
- FOTEDAR R, STARK D, BEEBE N, MARRIOTT D, ELLIS J, HARKNESS J (2007): *Laboratory diagnostic techniques for Entamoeba species*. *Clin. Microbiol. Rev.* **20**, 511 - 32, table of contents.
- JIANG B, YANG GY, YU XM, CHENG AC, BI FJ (2008): *A case report: Entamoeba histolytica infections in the rhesus macaque, China*. *Parasitol. Res.* **103**, 915 - 917.
- JOHNSON-DELANEY CA (2009): *Parasites of Captive Nonhuman Primates*. *Vet. Clin. North Am. Exot. Anim. Pract.* **12**, 563 - 581.
- LABBERTON L, BAKKER J, KLOMP R, LANGERMANS JA, GEIJLSWIJK VAN IM (2013): *Challenges in oral administration of metronidazole dissolved in drinking water to rhesus monkeys (Macaca mulatta)*. *Lab. Anim.* **42**, 213 - 216.
- LEVECKE B, DORNY P, GEURDEN T, VERCAMMEN F, VERCRUYSSSE J (2007): *Gastrointestinal protozoa in non-human primates of four zoological gardens in Belgium*. *Vet. Parasitol.* **148**, 236 - 246.
- MAO X, SCHIMMER AD (2008): *The toxicology of Clioquinol*. *Toxicol. Lett.* **182**, 1 - 6.

-
- MARTINDALE W (1996): *The extra pharmacopoeia*. 31st edn. In: Reynolds JEF (Ed.): Royal Pharmaceutical Society of Great Britain, London, UK, 511.
- NAGATA N, MARRIOTT D, HARKNESS J, ELLIS JT, STARK D (2012): Current treatment options for *Dientamoeba fragilis* infections. *Int. J. Parasitol. Drugs Drug Resist.* **2**, 204 - 215.
- PETRI Jr WA (2003): Therapy of intestinal protozoa. *Trends Parasitol.* **19**, 523 - 526.
- SCHURE JM, DE VRIES M, WEEL JF, VAN ROON, FABER TE (2013): Symptoms and treatment of *Dientamoeba fragilis* infection in children, a retrospective study. *Pediatr. Infect. Dis. J.* **32**, e148 - 50.
- TOFT II JD, EBERHARD ML (1998): Chapter 3 - Parasitic diseases. In: Bennett BT, Abee CR, Henrickson R (Eds.): *Nonhuman Primates in Biomedical Research: Diseases*. *Am. Coll. Lab. Anim. Med.*, 111 - 205.
- VERNES MK, LOUWERSE AL (2010): In: *BPRC's enrichment manual for macaques & marmosets*. 41 - 50.
- WORDEN AN, HEYWOOD R, PRENTICE DE, CHESTERMAN H, SKERRETT K, THOMANN PE (1978): Clloquinol toxicity in the dog. *Toxicology* **9**, 227 - 238.
- WRIGHT SG (2012): Protozoan Infections of the Gastrointestinal Tract. *Infect. Dis. Clin. North Am.* **26**, 323 - 339.

INVESTIGATING PARASITE SPREAD THROUGH A LEMUR POPULATION

SPRINGER A¹, FICHEL C¹, LEENDERTZ F², CALVIGNAC-SPENCER S², MELLMANN A³,
NUNN CL⁴, KAPPELER PM^{1,5}

¹German Primate Center, Behavioral Ecology and Sociobiology Unit, Göttingen, Kellnerweg 4, 37077 Göttingen, GERMANY; aspringer@dpz.eu

²Robert-Koch-Institut, Junior Research Group „Novel Zoonoses“, Nordufer 20, 13353 Berlin, GERMANY

³University Hospital of Münster, Institute of Hygiene, Robert-Koch-Straße 41, 48149 Münster, GERMANY

⁴The Duke Global Health Institute, Dept. of Evolutionary Anthropology, Trent Hall, 310 Trent Drive, Durham, North Carolina 27710, USA

⁵University of Göttingen, Dept. of Sociobiology and Anthropology, Kellnerweg 6, 37077 Göttingen, GERMANY

Exposure and susceptibility of wild animals to infectious agents are influenced by a range of behavioural factors affecting species richness, prevalences and infection intensities.

The aim of this study was to investigate the effects of social contacts and habitat use on the spread of directly and indirectly transmitted infectious agents (viruses, bacteria, protozoans, helminths and arthropods) in a population of a lemur species, Verreaux's sifaka (*Propithecus verreauxi*), in their natural habitat in Madagascar.

We obtained transmission-relevant contact networks of eight social groups based on detailed behavioural observations as well as data on ranging behaviour derived from GPS collars.

Blood samples and swabs collected during routine anaesthesia as well as non-invasively collected faecal samples allowed us to detect *Plasmodium* spp., filarial worms, gastrointestinal helminths and ectoparasites, which represent different transmission modes, and to investigate their prevalences. Additionally, a molecular epidemiological approach was applied to investigate genetic similarities between *Escherichia coli* bacteria from different individuals to infer transmission pathways.

These preliminary results demonstrate that integrative field studies on the health status of wild primate populations are feasible and that they can potentially shed light on central questions pertaining to primate sociality, ecology and conservation.

AN OVERVIEW OF THE THREATS FACING WILDLIFE IN THE MIDDLE EAST AND THE CONTRIBUTION OF VETERINARIANS TO CONSERVATION PROGRAMMES

BAILEY T

Head of Aviculture and Health, International Wildlife Consultants, PO Box 19, Carmarthen, SA31 3AL Dyfed, Wales, UK; tom@falcons.co.uk

In the Middle East there are great pressures on the environment and wildlife. Indeed many species are teetering on the edge of extinction. Wildlife health, management and welfare are poorly understood concepts and are not important priorities for regional governments.

In this presentation I will review some of the factors including regional cultural and religious attitudes, economic development, regional instability and hunting that have contributed to the loss of wildlife in the Middle East. The contribution of hunters and falconers in the development of environmental agencies in the region is explained.

Examples of the conservation themes that have evolved in response to these problems and which have benefited from veterinarian contributions include:

Intensification of captive breeding efforts - The involvement of veterinarians in multidisciplinary Houbara bustard (*Chlamydotis undulata*) captive breeding projects has resulted in the intensive production of a species that is widely hunted across the region. Projects described include the International Centre for Houbara Conservation (UAE), the National Avian Research Center (UAE), the National Wildlife Research Center (Saudi Arabia) and the Breeding Centres in Morocco and Kazakhstan.

Falcon hospitals - The establishment of dedicated hospitals have promoted clinical veterinary research to improve the health and welfare of species used in the traditional Arab heritage of falconry. The work of the Middle East Falcon Research Group to raise the awareness on matters relating to captive and wild falcons and falconry will also be outlined.

Rehabilitation and rescue centres - The establishment of facilities where confiscated illegally traded wildlife receive veterinary support including at the Breeding Centre for Endangered Arabian Wildlife and National Avian Research Center (UAE) are examples where steps have been taken by government agencies to deal with the illegal trade of wildlife into the region.

Education and awareness - Can the level of awareness to wildlife health, management and welfare be raised in a region where most people live in large modern cities detached from nature? The creation of forums such as the Middle East Falcon Research Group and information resources can be used to raise awareness of veterinary and conservation issues affecting falcons and wildlife across the region promoting better care of captive and free-living populations. I will relate the story of how I, and a small group of colleagues, harnessed our frustration at the pervasive indifference to conservation to positive effect. We took action to establish Wildlife Middle East News, a bilingual information resource to raise awareness of conservation issues and to enable better management and welfare of wildlife. This case study demonstrates how individuals, such as biologists, veterinarians and environmental educators working with wildlife in narrow professional arenas can play a role in the solution of wider environmental problems.

WILDLIFE CONSERVATION BREEDING AND REINTRODUCTION PROGRAMMES AT THE JERUSALEM (BIBLICAL) ZOO, ISRAEL

AVNI-MAGEN N¹, ESHAR D², KING R³, SHILO-BENJAMINI Y⁴, GANCZ AY⁵

¹The Tisch Family Zoological Gardens, 1 Aharon Shulov Avenue, Jerusalem 91008, ISRAEL; zoovets@jerusalemzoo.org.il

²Kansas State University, College of Veterinary Medicine, Manhattan, KS 66506, USA

³Israel Nature and Parks Authority, 3 Am Ve'Olamo Street, Jerusalem, 95463, ISRAEL

⁴The Hebrew University of Jerusalem, Koret School of Veterinary Medicine, P.O. Box 12, Rehovot 76100, ISRAEL

⁵The Exotic Clinic, 26 Ben Gurion st., Herzliya, 46785, ISRAEL

The Tisch Family Zoological Gardens in Jerusalem, in co-operation with the Israel Nature and National Parks Protection Authority (INNPPA), conducts a number of breeding and reintroduction conservation programmes in Israel, focused mainly on Biblical animals that have been lost because of habitat destruction. Some of these animals are facing extinction.

The projects include the reintroduction of the Persian fallow deer (*Dama dama mesopotamica*) back to the Judean mountains after complete extinction from Israeli fauna; breeding and reinforcement of the ferruginous duck (*Aythya nyroca*) to the aquatic habitats of various nature reserves in Israel; creating a "breeding nucleus" for the Egyptian tortoise (*Testudo wernerii*) for a future reintroduction project. The Jerusalem Zoo hosts the Israeli "National Centre for Raptor Egg Incubation", gathering eggs from different research and zoological centres in Israel. Eggs of the following species have been successfully incubated here: Griffon vulture (*Gyps fulvus*), lappet-faced vulture (*Torgos tracheliotus*), lesser kestrel (*Falco naumanni*). The chicks are raised without imprinting, and these reintroduction efforts, in co-operation with the INNPPA, have been mainly successful.

These conservation projects also include medical surveys and research.

During the Persian Fallow Deer project different immobilisation protocols for transportation are compared, and the efficiency of a long term tranquiliser is evaluated. Both the ferruginous duck and the Egyptian tortoise projects involve surveying of haematologic and biochemical data. This work describes biochemical and haematological values in clinically healthy animals to illustrate quantitative, morphologic, and cytochemical features of blood cells and biochemical analyses, and to generate reference values for these species based on the collected data. A survey was done comparing the wild population of the griffon vulture with the captive one to detect pathogens such as *Chlamydophila psittaci* and *Mycoplasma* spp. with very interesting results.

From the knowledge accumulated at the "National Centre for Raptor Egg Incubation", we are establishing protocols of successful egg incubation for different parameters such as humidity, temperature, egg position, vibration, etc. Hand raising the chicks is another important issue and detecting the essential nutritional elements is an important research aim.

We hope, in the future, to report on the successful continuation of these conservation projects at the Jerusalem Zoo, as well as on further medical research.

MANAGEMENT IMPLICATIONS AND ERADICATION OF *BRUCELLA MELITENSIS* IN TWO DIFFERENT GAZELLE SPECIES (*GAZELLA ERLANGERI*, *GAZELLA MARICA*) IN THE KINGDOM OF SAUDI ARABIA

SOARES JF^{1,2}, SHIFERAW FD^{1,2}, AL-HANOOSH N¹, MACASERO W^{1,2}

¹King Khalid Wildlife Research Center, Saudi Wildlife Authority, Thumamah P. O. Box 61681, Riyadh, KINGDOM OF SAUDI ARABIA; grec31@yahoo.com

²Conservation Projects, Zoological Society of London, Regents Park, NW1 4RY London, UK

Summary

An outbreak of *Brucella melitensis* occurred in a group of Sand gazelles (*Gazella marica*) at Prince Mohammed Al-Sudairi Gazelle Breeding Center (PMSGBC) and in a group of Newmann's gazelle (*Gazella erlangeri*) housed at King Khalid Wildlife Research Center (KKWRC). Anorexia, poor body condition, enlarge testis, abortion, reluctance to walk, swollen carpal joints were the clinical signs present. All clinical cases were tested using qualitative card test, complement fixation test and ELISA. All cases were serologically positive for *B. melitensis*. Confirmation was made by culture the micro-organism in specific medium and by polymerase chain reaction (PCR). DNA sequencing confirmed that the identity of the organism involved was *Brucella melitensis*. This is the first report describing an outbreak of brucellosis in antelopes belonging to the genus *Gazella*, the management implications and process that lead to its eradication.

Introduction

In wildlife reintroduction projects, the risk of disease transmission is enhanced both, for the reintroduced animals themselves and for the native fauna (WOODFORD, 1989). Thus, extreme care should be taken to reintroduce only animals determined to be free of specific pathogens. In addition, assessment of the susceptibility of the reintroduced species to communicable infection disease is an important factor to consider in the health management of such conservation projects. *Brucella melitensis* appears to be a common disease in domestic ruminants in the Kingdom of Saudi Arabia, but is rarely diagnosed in wild ruminants, especially under remote field conditions. The presence of brucellosis in free-ranging wild ruminant populations is a major health management problem in several countries, because of the risk of transmission to livestock species (MEYER and MEAGHER, 1995; THORNE et al., 1978). It is therefore essential to record any cases of this disease identified during the course of a reintroduction programme.

Material and methods

Case 1

In total, 42 captive Newmann's gazelle (*Gazella erlangeri*) housed in King Khalid Wildlife Research Center (KKWRC), were physically restrained for a complete physical examination, blood collection and *Brucella* sp. testing. From August 2009 to July 2010, the herd was captured based on clinical symptoms. All *Brucella* positive cases were housed intermittently both at the breeding pens and in an isolated area 3 km distant from KKWRC breeding pens. During this period the *Brucella* positive cases have been treated as described elsewhere (SAWSAN et al., 2011). From August 2010 all *Brucella*

positive cases were housed in an isolated area permanently and care was provided by a keeper, which his sole responsibility was the care and wellbeing of these individuals. In July 2011, the Saudi Wildlife Authority (SWA) gave permission for euthanasia (10 mg/kg sodium pentobarbital, Eutasil, Ceva Sante Animale, Libourne, France) of all Newmann's gazelles *Brucella sp.* positive cases, due to the risk for KKWRC animal collection. During this period the animals have been treated with different antibiotic combinations. Complete necropsy studies were performed in all animals that have been euthanised or died as a result of *Brucella sp.* infection. From August 2010 onwards, all *Brucella* negative Newmann's gazelles, were housed in small pens in breeding groups of 1.2 animals with respective fawns until weaning, for better supervision and capture every three months for complete physical examination, blood collection and *Brucella sp.* testing.

Case 2

In total, 672 sand gazelles (*Gazella marica*) housed at the Prince Mohammed Al-Sudari Gazelle Breeding Center (PMSGBC) were physically restrained for a complete physical examination, blood collection and *Brucella sp.* testing. All *Brucella* positive cases were kept in its original pens until *Brucella sp.* laboratory confirmation. The 16 *Brucella sp.* positive animals and the remaining 20 animals that they share the pens with, a total of 36 adult females, were euthanised (10 mg/kg sodium pentobarbital, Eutasil, Ceva Sante Animale, Libourne, France) eight days later. Complete necropsy studies were performed in all animals that have been euthanised. From July 2011 to July 2012, this herd was captured every three months. From August 2012 until present captures are done annually. During July 2011, blood samples from domestic sheep and goats were taken from the farms in the vicinity area and tested for *Brucella sp.*

Laboratory tests

A preliminary serological investigation was done using a qualitative card test (Brucelloslide-test, bioMérieux, Marcy-l'Étoile, France) and results were available before any animal translocation between pens or different collections. Confirmation of *Brucella sp.* was done using serological, bacteriological and polymerase chain reaction (PCR). Both in sand and Newmann's gazelle serological confirmation was done using a complement fixation test (Complement fixation test, Institut Pourquier, Montpellier, France) and an ELISA test (COMPELISA, Animal Health and Veterinary Laboratory Agency, Addlestone, UK). Samples for bacterial investigation have been collected from liver, spleen, kidney, ovary, mammary gland, pre-scapular lymph node and carpal joint samples collected from euthanised animals and submitted refrigerated at 4°C to KKWRC's laboratories, where attempts to isolate the *Brucella sp.* were carried. On arrival, samples were appropriately inoculated in a specific medium (5 % *Brucella* blood agar plates, Saudi Prepared Media Laboratories, Riyadh, Saudi Arabia). The bacterial cultures were incubated for seven days under 5 % CO₂ atmosphere. A PCR was used to test synovial fluid from carpal joint from symptomatic Newmann's gazelle. In sand gazelles confirmation was achieved using a PCR from liver, spleen, kidney, ovary, mammary gland, pre-scapular lymph node and carpal joint samples collected from euthanised animals. Deoxyribonucleic acid (DNA) was extracted from the organisms isolated using a tissue extraction kit (DNeasy[®], Blood and Tissue kit, QIAGEN GmbH, Hilden, Germany) according with the manufacturer's instructions. A polymerase chain reaction (PCR) was performed using one set of PCR primer, as described elsewhere (BRICKER and HALLING, 1994). Using a basic local alignment search tool the resulting DNA sequences were compared with other sequences from National Center for Biotechnology Information, which confirmed that the identity of the organism involved was *Brucella melitensis*.

Results

Case 1

In August 2009, six adult females and one adult male Neumann's gazelle (*Gazella erlangeri*) housed at KKWRC, Thumamah, Kingdom of Saudi Arabia, exhibited poor body condition, testicular enlargement, abortion, generalised lymphadenopathy and carpal joint enlargement due to suppurative arthritis. Both serological and bacteriological tests were positive for *B. melitensis*. After treatment, all previous positive cases tested negative for the described zoonotic infection using solely PCR, and as a result the animals were returned to the breeding pens (SAWSAN et al., 2011). In December that year, all previously positive animals started showing similar clinical signs again, together with two additional cagemates, raising the total number of positive animals to nine. As a result, all positive cases were individually isolated and one keeper was appointed to solely care for these animals in an enclosure 3 km from KKWRC breeding pens. The findings of this study reveal that long term treatment of the Neumann's gazelles infected with *B. melitensis* using a combination of oxytetracycline and streptomycin, followed by only oxytetracycline, did not succeed in eradicating the infection, contradicting what has been previously published (SAWSAN et al., 2011). Between December 2009 and June 2011, different combinations of antibiotics, were used without success, with all positive cases, showing clinical symptoms once treatment ceased. In July 2011, due to the risk for the KKWRC collection, the SWA gave permission to euthanise all positive cases. At necropsy generalised lymphadenopathy and suppurative arthritis, but no further pathologic changes.

In January 2012, one female, showed clinical signs compatible with Brucellosis. In January 2013, one male Neumann's gazelle showed similar clinical signs. All animals had previously been in contact with positive animals, in 2009, which shows the long incubation period for this disease in *Gazella* sp. These gazelles positive cases and its cagemates were isolated in the same enclosure as described above. The positive animals were euthanised a month later after a confirmation test was performed. All the cagemates are tested monthly. Until the present day no further positive cases were diagnosed at KKWRC. In May 2009, a sand fox (*Vulpes rueppellii*) was brought in and housed at KKWRC. This individual was apparently healthy and no further examinations were done. A few days later this animal was brought to an enclosure near the breeding pens and care was provided by keepers that also shared responsibilities with the different gazelle species at the KKWRC breeding pens. Retrospectively this individual was found to be infected with *Brucella melitensis* on arrival and most likely was the origin of this outbreak.

Case 2

In July 2011, a herd of 16 adult female breeding sand gazelles (*Gazella marica*), kept in three adjacent pens at the PMSGBC, were presented with anorexia, poor body condition, reluctance to walk, generalised lymphadenopathy, bilateral enlargement of carpal joints and mortality. Serological investigations using qualitative card complement fixation and ELISA test showed positive results. The 16 *Brucella* sp. positive animals and the remaining 20 animals that they share the pens with, a total of 36 adult females, were euthanised. At necropsy both carpal joints revealed non-suppurative arthritis and hepatomegaly, but no further pathologic changes. A PCR was used to test liver, spleen, kidney, ovary, mammary gland, pre-scapular lymph nodes, and carpal joint from euthanised animals. Comparison of resulting DNA sequences confirmed *B. melitensis*. In addition, sera from sheep and goat farms in the vicinity also tested 33 % serologically positives for *B. melitensis* (card agglutination and complement fixation test), with many showing clinical symptoms compatible with brucellosis. Most likely this was the origin of this outbreak. Between July 2011 and July 2012 all PMSGBC were captured every three months. From July 2012 on, the PMSGBC collection is captured and tested annually. No further positive cases have been found until the present date.

Discussion

Introduction of pathogens into previously unexposed wild populations can seriously challenge conservation efforts (DASZAK et al., 2000) In wildlife reintroduction projects, the risk of disease transmission is enhanced both for the reintroduced animals themselves and the native fauna (WOODFORD, 1989). Thus, extreme care should be taken to reintroduce only animals determined to be free of specific pathogens. In addition, assessment of the susceptibility of the reintroduced species to communicable infection disease is an important factor to consider in the health management of such conservation projects. Both cases are noteworthy as it affected two vulnerable species during a reintroduction programme, and had profound implications on the management of both collections.

References

- BRICKER BJ, HALLING SM (1994): Differentiation of *Brucella abortus* bv 1, 2 and 4, *Brucella melitensis*, *Brucella ovis* and *Brucella suis* bv 1 by PCR. *J. Clin. Microb.* **32**, 2660 - 2666.
- DASZAK P, CUNNINGHAM AA, HYATT AD (2000): Emerging infectious disease of wildlife: threats to biodiversity and human health. *Science* **287**, 443 - 449.
- MEYER ME, MEAGHER M (1995): Brucellosis in free-ranging bison (*Bison bison*) in Yellowstone, Grand Teton and Wood Buffalo National Parks: a review. *J. Wildl. Dis.* **31**, 579 - 598.
- SAWSAN A, OMER WA, AL-MEGRIN I, ALAGAILI AN, MOHAMMED OB (2011): A new protocol for the treatment of *Brucella melitensis* Infection in Neumann's gazelle (*Gazella erlangeri*) from Saudi Arabia using oxytetracycline and streptomycin. *Afr. J. Biotechnol.* **10**, 11075 - 11080.
- THORNE ET, MORTON JK, THOMAS GM (1978): Brucellosis in Elk. Serological and bacteriologic survey in Wyoming. *J. Wildl. Diseases* **14**, 74 - 81.
- WOODFORD MH (1989): Veterinary Aspects of the Reintroduction of the Arabian Oryx into Saudi Arabia. In: Abuzinada, AH, Goriup PD, Nader IA (Eds.): *Wildlife Conservation and Development in Saudi Arabia. Proceedings of the First Symposium on the Potential for Wildlife Conservation and Development in Saudi Arabia. Riyadh, February 1987. Riyadh, National Commission for Wildlife Conservation and Development*, 393 - 400.

OUTBREAK OF CONTAGIOUS CAPRINE PLEUROPNEUMONIA IN CAPTIVE DORCAS GAZELLES (*GAZELLA DORCAS*)

MOLNÁR L¹, BEREGI A³, MAJOR P¹, KUZYŠINOVÁ K¹, MOLNÁROVÁ M²

¹University of Veterinary Medicine and Pharmacy, 040 01 Košice, SLOVAKIA; ladislav.molnar@uvlf.sk

²MEDY s.r.o., Clinical Diagnostic Laboratory, Poliklinika Sever, 040 01 Košice, SLOVAKIA

³Modern Veterinary Clinic, Al Wasl Road, P.O.Box 2214, Dubai, UNITED ARAB EMIRATES

Authors are presenting experience with control of an outbreak of CAPP - Contagious Caprine Pleuropneumonia in captive collection of gazelles in United Arab Emirates in three occasions in the years 2006 and 2013. The source of infection was in all cases feral or domestic goats with no clinical signs introduced to the wildlife farm. Goats were kept under quarantine 2 km away from a wild life collection containing over 1,200 gazelles and antelopes of different species. The outbreak started one month after the introduction of the domestic goats. The pathogen was spread by staff providing feeding from enclosure to enclosure. Diagnosis was confirmed by detection of the causative agent. *Mycoplasma mycoides* ssp. *capri* type (F-38) was found in lung tissue of infected animals by specific PCR which was based on the 16S rRNA genes, which enables the detection of all members of the *M. mycoides* cluster, followed by specific identification of *M. capricolum* ssp. *capripneumoniae* by restriction enzyme digestion. The causative agent, once isolated, can be identified also by immunofluorescence, by growth, or by metabolic inhibition tests. In field condition several serological tests can be used for the detection of antibodies to mycoplasma F-38. These include complement fixation (CF), passive haemagglutination (PH), and enzyme-linked immunosorbent assay (ELISA). In our case the latex agglutination test (LAT), was proven to be a very convenient field test for detecting antibodies in whole blood or in serum.

The classical disease of CAPP caused by *M. mycoides* ssp. *capri* type F-38, is a mere respiratory illness and is characterised by fever of up to 41° C, coughing and a distinct loss of vigor. Affected gazelles in advanced stages had labored breathing, frothy nasal discharges and stringy salivation was seen shortly before death. In the acute disease, which occurred in fully susceptible populations of animals, death occurs within seven to ten days after the onset of clinical signs. A more chronic form of the disease is often seen in endemic areas and may lead to recovery of a higher percentage of infected animals, many of them stay carriers of the mycoplasmas. In our case the gazelles represented mostly sand gazelle (*Gazella subgutorosa*) and dorcas gazelle (*Gazella dorcas*). They expressed no previous clinical symptoms like respiratory distress or discharge from nose and died suddenly in very good body condition. There was no species related susceptibility recorded. *Post mortem* examination showed severe fibrinous pleuropneumonia or pericarditis. Infection affected three enclosures of 2 to 4 ha size. A total of 35 % morbidity (affected gazelles of all animals in the collection) was recorded with 90 % mortality. Treatment by florfenicol (NUFLOR, Intervet/Shering-ploug, Summit, USA; 20 mg/kg i.m.) and tylosin (TYLAN.200, Elanco, Greenfield, USA; 10 mg/kg i.m.) was stopped as manual capture was too stressful for the animals. Medicated feed was not available and we also did not expect a benefit as sick individuals rejected all offered food. Double fencing built up as emergency procedure helped to stop the spreading of the infection. All gazelles were captured by passive capture and vaccinated by CAPP vaccine (CAPRIVAX[®], Kevevapi, Nairobi, Kenya). Domestic animals with unknown disease status as well as newly arriving animals are presenting a high risk to wild life collections immunologically naive to endemic diseases and should be tested. Under conditions of the Middle East domestic animals are often kept in close proximity to wild life collections. Disease can also be introduced by the food sources like green alfalfa fertilised with domestic animals manure.

COMPUTER ASSISTED AND FLOW CYTOMETRIC SPERM ANALYSIS IN THE CAPTIVE ARABIAN LEOPARD (*PANTHERA PARDUS NIMR*)

BAQIR S¹, ORABAH A¹, AL-RASBI K², AL-SHAKAILI Y³, GARTLEY C⁴, MASTROMONACO G⁵

¹Sultan Qaboos University, Muscat, College of Science, Biology Dept., PC. 123, Muscat, OMAN; baqirs@yahoo.com

²Oman Wildlife Animal Breeding Centre, Veterinary Services, Royal Court Affairs, Muscat, OMAN

³AI Lab, Livestock Research Center, Ministry of Agriculture & Fisheries, Muscat, OMAN

⁴University of Guelph, Ontario Veterinary College, Dept. of Population Medicine, Stone Rd, Guelph, ON N1G 2W1, CANADA

⁵Toronto Zoo, Reproductive Programs & Research, Meadowvale Rd, Toronto, ON M1B 5K7, CANADA

Semen evaluation in the big felid species is a challenging task. The challenges stems from the fact that ejaculates are highly diluted and small in volume. While the conventional subjective method of assessment that employs light microscopy is often used for sperm analysis, it is neither accurate nor informative of the entire ejaculate sample. The aim of this study was to use an objective method (computer assisted sperm analysis; CASA) to evaluate sperm quality in big cats from *Panthera* species. Additionally, flow cytometric analysis (FCA) was used to assess sperm viability (SYBR14/PI) and acrosomal integrity (PSA-FITC/PI). Semen was collected from two Arabian leopards (*Panthera pardus nimr*), aged at 16 and 18 years, reared in captivity at the Oman wildlife animal breeding centre (N23.70 E58.09 A5.80m), using a canine electroejaculator (½", 2 electrodes). CASA revealed different motion parameters, such as motility and progressive motility (66.57 % and 44.64 % respectively). Moreover, FCA showed that although semen was collected from aged animals, the percentage of viable sperm was relatively high in both males (46 % and 40 %). While the percentages of moribund sperm cells that were identified as a separate cell population by the FCA apparatus were similar (3 %), differences in the percentages of dead sperm cells were observed between both males (8 % and 18 %). The intactness of the acrosome of both specimens was at 20 %. Interestingly, our data shows that aged Arabian male leopards can still produce relatively high percentages of viable sperm with moderate motility. This in turn suggest that, while the levels of motility and viability might have a low fertilisation potential through natural mating and IVF, more advanced assisted reproductive technologies (ART) such as ICSI might improve the fertilisation outcome.

USING NON-INVASIVE METHODS FOR THE DETECTION OF SYSTEMIC INFECTION IN WILDLIFE

GRUETZMACHER KS, LEENDERTZ FH

Robert Koch Institute, P3, Nordufer 20, 13353 Berlin, GERMANY; leendertzf@rki.de

Infectious diseases can have a major impact on wildlife populations. Therefore detection of pathogenic microorganisms can be of vital importance for wildlife population management and also for investigation of zoonotic diseases. Monitoring for the presence and prevalence of pathogenic microorganisms requires biological material that can be obtained either through invasive sampling (e.g., blood collection, tissue biopsy or swabs taken from anaesthetised animals) or through non-invasive collection of excreted materials such as faeces or urine. In situations where immobilisation of animals is ethically impossible, interfering with other research (e.g. behavioural research), difficult, dangerous or cost and labour intensive, non-invasive diagnostics can be the most sensible tool to detect the presence of pathogens.

Pathogenic microorganisms of the gastro-intestinal tract can quite obviously be found in faeces. However, systemic pathogens that are not generally known to be excreted via faeces have nonetheless been shown to be detectable in faecal matter: In recent years non-invasive screening methods have been established for pathogenic microorganisms that cause systemic infection using faecal samples such as canine distemper virus (CDV), canine parvovirus 2 (CPV2), simian foamy virus (SFV), simian immunodeficiency virus (SIV), simian T-cell leukaemia virus (STLV), hepatitis B virus (HBV), *Plasmodium* spp., *Mycobacterium bovis* and respiratory pathogens such as human respiratory syncytial virus (HRSV) and human metapneumovirus (HMPV) in a variety of species.

Mainly PCR techniques have been employed since they do not depend on infectious particles and allow studying the phylogeny and epidemiology of circulating microorganisms. Several studies demonstrated that systemic pathogen load is correlated to detection rate in faeces. It has also been shown that antibodies can be detected in faeces as well as in urine.

Many of these protocols have been established for wild primate populations and primate infecting microorganisms but the framework can also be applied to other mammals under threat from infectious diseases. However, non-invasive diagnostics are not appropriate for the study of all pathogenic microorganisms or in all situations as sensitivity may be low and a negative result cannot reliably be interpreted as the absence of a specific microorganism. Assays have to be developed and validated for each pathogen and each species separately. Especially when working with faeces, differences in digestive tract have to be taken into consideration since they influence the detectability of pathogens. For tuberculosis (TB) for instance, *Mycobacterium bovis* can be detected in faecal matter of badgers (*Meles meles*) but was not found in faeces of bovine tuberculosis-infected African buffalo (*Syncerus caffer*) which may be related to differences in digestive systems. Keeping in mind the limitations of these methods, with assays being developed and validated for different species and pathogens, faecal antigen and antibody detection represents a promising tool for a better understanding of disease ecology.

ZEBRA-BORNE EQUINE HERPESVIRUS TYPE 1 (EHV-1) INFECTION IN NON-AFRICAN CAPTIVE MAMMALS

BAUMGARTNER K¹, ABDELGAWAD A², AZAB W^{3,4}, DAMIANI AM³, WILL H¹,
OSTERRIEDER N³, GREENWOOD AD²

¹Zoo Nuremberg, Am Tiergarten 30, 90480 Nuremberg, GERMANY;

Katrin.Baumgartner@stadt.nuernberg.de

²Leibniz Institute for Zoo and Wildlife Research (IZW), Alfred-Kowalke-Str. 17, 10315 Berlin, GERMANY; greenwood@izw-berlin.de

³Freie Universität Berlin, Institut für Virologie, Robert-von-Ostertag-Str. 7-13, 14163 Berlin, GERMANY

⁴Zagazig University, Faculty of Veterinary Medicine, Dept. of Virology, Zagazig, EGYPT

A 2 year old male polar bear (Gregor) at the Zoo Nuremberg, Germany showed loss of appetite, depression, heavy salivation, difficult breathing and nervous symptoms (seizures) in September 2012. He was treated with penicillin/streptomycin (Veracin[®], Albrecht, Aulendorf, Germany) and dexamethasone (Hexadreson[®], MSD, Unterschleissheim, Germany), and within a few days the symptoms became less evident. The treatment was continued for one month and the symptoms disappeared completely. Equine herpesvirus type 1 (EHV-1) zebra strain was detected in the saliva samples of this male polar bear.

In November 2012, the 20 year old female Indian rhinoceros Purana had an abortion in the mid stage of pregnancy. The necropsy revealed a purulent placentitis and *Streptococcus dysgalactiae* ssp. *equisimilis* and *Streptococcus bovis* I were isolated.

Six days later, Purana suffered from blurred vision, shaky movement, and muscle cramp followed by rapid respiration, nervous manifestations, and bowel prolapse. She was treated with antibiotics, first penicillin/streptomycin parentally and then chloramphenicol (Chevita, Pfaffenhofen, Germany) because of a suspected encephalitis.

Due to the worsening of the CNS symptoms Purana had to be euthanised. A necropsy showed a non-purulent meningo-encephalitis, a bilateral non-purulent optic neuritis, a bilateral non-purulent mixed cellular iridocyclitis and chorioretinitis with a fibrinous component, an ongoing righthand endophthalmitis. Equine herpesvirus type 1 (EHV-1) zebra strain viral DNA was detected. Furthermore, the viral IR6 protein was detected in several tissues, most strongly in lung. Phylogenetic analyses of sequence of gB, IR6, UL45, UL49.5, and DNA polymerase isolated from Purana's tissues were aligned with reference sequences for the same regions of EHV-1, EHV- 9, and EHV-4 confirmed that the virus was nearly identical to a recently described EHV-1 strain that resulted in both non-fatal and fatal encephalitis in polar bears. This represents transmission of EHV-1 to a species that is not naturally sympatric with the natural host of the virus and broadens the host range to Asian non-equid perissodactyls. Thus, the mortality in species that are not con-specifics of zebras may suggest exposure to EHV may yield particularly severe outcomes for non-African mammals. Mixing of geographically dispersed mammals only occurs in zoological collections and circuses which may provide pathogens such as EHV's novel opportunities to disseminate to new hosts. The data suggest that EHV-1 and its close relatives are now prevalent and can infect different animal species with devastating and often fatal outcomes.

The mode of transmission remains unclear. Keepers could be a source of transmission via fomites or clothing, but there is also the possibility that it was transmitted by unknown live or abiotic vectors.

THE FIRST CASE OF *MYCOBACTERIUM BOVIS* SSP. *CAPRAE* ISOLATION FROM WOLVES (*CANIS LUPUS*) IN BIESZCZADY MOUNTAINS, POLAND

ORŁowska B¹, ANUSZ K¹, KRAJEWSKA M², AUGUSTYNOWICZ-KOPEĆ E³, ZABOSTA A³

¹Warsaw University of Life Sciences– SGGW, Faculty of Veterinary Medicine, Dept. of Food Hygiene and Public Health Protection, Nowoursynowska 159, 02-772 Warsaw, POLAND; orłowska.blanka@gmail.com

²National Veterinary Research Institute (NVRI), Dept. of Microbiology, Aleja Partyzantów 57, 24-100 Pulawy, POLAND

³Institute of Tuberculosis and Lung Diseases, Dept. of Microbiology, Płocka 26, 01-138 Warsaw, POLAND

The first case of bovine tuberculosis (bTB) in free-ranging animals in the Bieszczady Mountains was reported in 1996 in bison (*Bison bonasus caucasicus*). Research conducted from 1997 to 2013 in this region revealed more cases in these animals. The transmission of *Mycobacterium bovis* probably originated from infected cattle. As a result additional research on tuberculosis in other species from the same area has been undertaken. Between 2012 and 2013, four wolves (*Canis lupus*), killed in road accidents or snares and found in the Bieszczady Mountains (Polish Carpathians) were sampled. The wolves did not have lesions characteristic for tuberculosis, but lymph nodes (mandibular, tracheobronchial, mediastinal) of these animals were taken and tested for the presence of mycobacteria. Solid media - Löwenstein-Jensen and Stonebrink (OXOID, Wesel, Germany) were used for bacterial culture. Species of isolated strains were identified by PCR-restriction fragment length polymorphism analysis of the *hsp65* gene and by GenoType[®] MTBC test (HainLifescience, Nahren, Germany). *Mycobacterium bovis* ssp. *caprae* was isolated from two wolves. It is the first confirmed case of isolation *M. bovis* ssp. *caprae* from wolves in Poland. In the Bieszczady Mountains *M. bovis* was isolated from cattle but the subspecies was not investigated. *M. bovis* ssp. *caprae* was reported in bisons in this region. The wolf, apart from bears, is the main predator species in the Bieszczady Mountains and is at the top of the food chain. The main prey of the wolf in the Polish Carpathians are red deer, roe deer and wild boar. Wolves hardly ever hunt for bisons in the Bieszczady Mountains, but they can feed on bison's carrion. Domestic ungulates have marginal importance as a food source for wolves and wolves rather kill sheep than cattle (sheep farming is far more common in the region than cattle farming), still direct and indirect submission of pathogens between livestock and wolves cannot be excluded. All prey species of the wolves are a potential source of infection for wolves and it needs to be the subject of further research. The research will be continued.

**ACID FAST RODS IN AN ECOLOGICAL HAY STACK:
MULTIPLE STRAIN INFECTIONS AND HIGH GENOTYPIC DIVERSITY AMONG
MYCOBACTERIUM AVIUM SUBSP. PARATUBERCULOSIS
ISOLATED FROM DISEASED WILD RUMINANTS**

GERRITSMANN H¹, STALDER GL¹, SPERGSER J², HOELZL F¹, DEUTZ A³,
KUEBBER-HEISS A¹, WALZER C¹, SMITH S¹

¹University of Veterinary Medicine, Research Institute of Wildlife Ecology, Savoyenstraße 1, 1160 Vienna, AUSTRIA; hanno.gerritsmann@fiwi.at

²University of Veterinary Medicine, Institute of Bacteriology, Mycology and Hygiene, Veterinärplatz 1, 1210 Vienna, AUSTRIA

³Styrian Provincial Government – Veterinary Affairs, Bahnhofviertel 7, 8850 Murau, AUSTRIA

We present an epizootiological investigation on *Mycobacterium avium* subsp. *paratuberculosis* (MAP) at the livestock-wildlife interface in Austria (GERRITSMANN et al., 2014). In 2006, paratuberculosis was declared a notifiable disease in livestock due to a considerable increase in cattle seropositive against MAP. At the same time, during an increase of paratuberculosis cases in wildlife, MAP isolates were obtained from domestic cattle (n = 7), roe deer (*Capreolus capreolus*; n = 5), red deer (*Cervus elaphus*; n = 18), chamois (*Rupicapra rupicapra*; n = 1), European mouflon (*Ovis orientalis musimon*; n = 4), and Alpine ibex (*Capra ibex*; n = 3) showing signs of clinical disease.

Isolates were genotyped using eight Mycobacterial Interspersed Repetitive Units – Variable Number of Tandem Repeats (MIRU-VNTR) loci (THIBAUT et al., 2007). Subsequently, PCR products of different sizes were subject to sequence analysis, either with or without prior cloning reactions, for confirmation. Among the 39 isolates, more than 15 genotypes and several multiple strain infections (15.4 %) were identified. Mixed infections by at least two strains were confirmed in three samples and three isolates yielded mixed infections of three or more strains. Our typing method resulted in a discriminatory index of 0.90. MIRU-VNTR profiles were not limited to certain species or sampling locations. Detection of 15.4 % multiple strain infections with MIRU-VNTR typing and confirmation by cloning reactions, raised questions about previously underappreciated aspects of the organisms' ecology. As this is known for other mycobacteria, we suggest that MAP infections could be polyclonal. Our results indicate that genotyping a single MAP colony could bias our understanding of its epizootiology. Recent developments in the field of multiple strain infections highlight this (BALMER and TANNER, 2011).

References

- BALMER O, TANNER M (2011): Prevalence and implications of multiple-strain infections. *The Lancet Infect. Dis.* **11**, 868 - 878.
- GERRITSMANN H, STALDER GL, SPERGSER J, HOELZL F, DEUTZ A, KUEBBER-HEISS A, WALZER C, SMITH S (2014): Multiple strain infections and high genotypic diversity among *Mycobacterium avium* subsp. *Paratuberculosis* field isolates from diseased wild and domestic ruminant species in the eastern Alpine region of Austria. *Infect. Genet. Evol.* **21**, 244 - 251.
- THIBAUT VC, GRAYON M, BOSCHIROLI ML, HUBBANS C, OVERDUIN P, STEVENSON K, GUTIERREZ MC, SUPPLY P, BIET F (2007): New variable-number tandem-repeat markers for typing *Mycobacterium avium* subsp. *paratuberculosis* and *M. avium* strains: comparison with IS900 and IS1245 restriction fragment length polymorphism typing. *J. Clin. Microbiol.* **45**, 2404 - 2410.

HISTOLOGIC CHARACTERISATION OF DARK SPOT LESIONS IN MADRACIS CORALS

KIUPEL M¹, HOLLINGER C¹, CURTIS B¹, RIEGL B², BRUCKNER A³

¹Diagnostic Center for Population and Animal Health, Michigan State University, Beaumont Road 152A, East Lansing, MI, 48848, USA; kiupel@dcpah.msu.edu

²NOVA Southeastern University, Oceanographic Center 8000 North Ocean Drive, Dania Beach, FL 33004, USA

³Khaled bin Sultan Living Oceans Foundation, 8181 Professional Place, Suite 215, Landover, MD 20785, USA

Scleractinian or “stoney” corals are composed of polyps that produce a hard calcium carbonate exoskeleton also known as corallite. This ability makes them critical reef builders and essential for global biodiversity. There has been a recent dramatic decline of coral reefs. While climate changes and pollution have largely been implicated as potential causes, numerous coral diseases have devastated populations around the globe. Despite their importance, coral diseases are poorly characterised and often identified entirely based on their gross appearance. Considering the importance of coral for the marine ecosystem, it is of the utmost importance that we increase our effort toward a better understanding of coral diseases.

Dark spots disease (DSD) is an increasingly abundant lesion of scleractinian corals associated with high morbidity and variable mortality in Caribbean corals. DSD has been associated with increased zymogen granules and endolithic fungi in *Agaricia* and *Siderastrea* species, but the pathogenesis of DSD remains unclear. We recently observed DSD in two Caribbean *Madracis* species. The purpose of this study was to histologically characterise DSD in *Madracis* corals. *Madracis* corals with DSD and grossly unaffected controls were collected from the Inaguas and Hogsty Reef, Bahamas. A standardised histologic process was established to ensure high quality microscopic sections. Coral samples were fixed in “Z-Fix” diluted at 4:1 with sea water from the dive site to maintain an isotonic solution. Using a specialised rotary saw allowed cutting of thin tissue slabs that could be sandwiched between filter paper and gauze. This prevented movement of the sample during loss of structural support and allowed embedding of single layers of polyps with minimal tissue folding. Samples were decalcified extremely slowly with a neutral EDTA solution to maintain superb morphology and processed for HE staining. Samples of grossly normal appearing corals and transition zones as well as areas of discolouration and tissue loss of affected corals were examined microscopically. The earliest microscopic changes of DSD in *Madracis* spp. were recognised as degenerative lesions in the mesenterial filaments characterised by nematocyte disarray and loss, subsequent zymogen cells hyperplasia and support cell proliferation. No infectious agents were observed during these early changes. Lesions progressed as aboral swelling of the gastrodermis followed by loss of zooxanthellae and cellular degeneration and necrosis and ultimately affected the whole polyp. Darker pigmentation was observed in remaining zooxanthellae during advanced disease stages. Severely affected polyps commonly had secondary colonisation and invasion by fungal hyphae. The discolouration of DSD is most likely caused by the zymogen cell accumulation and the primarily deep alterations during the early stages of the disease explain the lack of grossly visible tissue loss. Darker pigmentation of zooxanthellae may contribute to discolouration. While no initiating cause for DSD was identified microscopically, the consistency of the observed disease progression is highly suggestive of a uniform disease mechanism.

THE ROLE OF THE VETERINARY ADVISOR: BACK TO BASICS, IT'S NOT JUST MEDICINE

NAPIER JE

Omaha's Henry Doorly Zoo & Aquarium (OHDZA), 3701 South 10th Street, Omaha, Nebraska, USA;
julie.napier@omahazoo.com

Summary

Husbandry is defined as the care, cultivation, management, breeding, and conservation of animals. While maintaining good health is crucial, animals should be encouraged to thrive in their environment, not just survive. So when practiced at a high standard, husbandry protects a valuable resource and enhances reproductive success to secure future generations. For the zoo veterinarian, husbandry encompasses a wide variety of issues that go beyond the identification of major medical problems and use of the latest diagnostic techniques and procedures. Development and maintenance of sound preventative medicine includes quarantine, routine examination, vaccination and therapeutic protocols. Veterinarians, as animal experts with a scientific perspective, have the unique ability to advocate for their animals in every aspect of their husbandry and subsequent welfare. It is as applicable in the day to day responsibilities for their respective collections as in an advisory capacity for a specific managed captive population. The formation of a group of veterinary advisors can strengthen the role of the veterinarian in both of these areas.

Introduction

Traditionally, a zoo veterinarian serves as a medical consultant to accredited zoological facilities for management of clinical cases and preventative health in the animals. The Veterinary Advisor addresses issues pertaining to a specific species or group of species. In the United States, these advisors are all part of an entity known as the Veterinary Advisory Group (VAG). The concept of the VAG originated with the Infectious Disease Committee of the American Association of Zoo Veterinarians (AAZV) and the Conservation and Science Department of AZA (formerly AAZPA) in 1993. The need for such a group was highlighted at the 1992 International Conference on Implications of Infectious Diseases for Captive Propagation and Reintroduction Programs of Threatened Species. This meeting, held in Oakland, California, United States, was sponsored by AZA, AAZV, and the Captive Breeding Specialist Group of the International Union for the Conservation of Nature/Species Survival Commission (CBSG/IUCN/SSC).

A general lack of information on the incidence, distribution and risks of disease in captive and wild populations emphasised the need for the development of effective quarantine protocols necessary to prevent disease transmission and definitive diagnostic tests to detect and monitor disease. The lack of a working database for informed risk assessment necessitated the formation of the VAG. In 1994, the VAG in the United States consisted of 69 Species Survival Plans (SSPs) and 41 Taxon Advisory Groups (TAGs) with a total of 82 vet advisors representing a 75 % participation rate. As of today, there are 122 SSPs and 46 TAGS with 134 vet advisors representing 85 % participation. The VAG meets every year at the annual AAZV meeting to discuss disease concerns, the accumulation of data regarding health, housing, nutrition and contraception issues, and to evaluate ways to further the

involvement of the veterinary advisors in all aspects of the well-being, care and conservation regarding their respective species.

The Veterinary Advisor is usually designated by the head or chair of the management group for a specific species. The list of advisors is provided on the AAZV website. Two benefits to this approach are that they offer the SSP Coordinator a reasonable expectation of the role of a Veterinary Advisor, and they provide the Veterinary Advisor with an outline of basic standards that should be met. The exact role and responsibilities of the Veterinary Advisor will differ among the various species populations based on size and need and the understanding between the chair and the vet for a given species.

The guidelines of the veterinary advisor encompass the following responsibilities:

1. To identify and review the major medical problems of their species/taxa and recommend diagnostic evaluations including laboratory information, therapeutic protocols, and preventive medicine measures.
2. Participate in the development and distribution of medical protocols through the species/taxa husbandry manual, studbook, etc. including protocols for transportation (pre-shipment, between institutions and/or for reintroduction), quarantine, preventive medicine, vaccinations, parasite surveillance/treatment recommendations, immobilisation anaesthetic techniques and handling, successful reproduction strategies, neonatal exams, annual exams, special needs for pregnant and geriatric animals, diagnosis of zoonotic disease, and necessary personal protective equipment (PPE) for personnel, individual animal identification methods, and necropsy (in conjunction with the Pathology Advisor if applicable).
3. In conjunction with the Management Group and Nutrition Advisors, review unique housing, environmental and/or nutrition requirements.
4. Advise the management groups on animal enrichment, animal welfare issues, euthanasia policies, guidelines for surplus animals, and significant federal legislation as it pertains to captive breeding, movement, and/or reintroduction.
5. Provide reports to the management groups including such information as morbidity report (description of significant illnesses), mortality report (in conjunction with the Pathology Advisor, if applicable), significant diagnostic tests and their availability, accuracy, and cost, updates on vaccine recommendations, and updates on recommended contraception methods. This may need to be done annually or every, two, three, to five years depending on the size of the population in captivity.
6. Assist in coordinating data collection efforts between other science advisors, scientific specialists, collection managers, and veterinarians so species information is as uniform and centralised as possible.
7. Act as a reviewer for proposed research projects and protocols that pertain to the species/taxa, advising the management groups of the value and potential health and welfare issues posed by such proposals.
8. Maintain a list of current and past research projects, field projects, and requests for samples and create a list of references and/or relevant sources of information (including web sites) as needed or relevant.
9. Facilitate the development of centralised sera and tissue banks or encourage the banking of samples at participating institutions so samples can be made available for researchers as needed.
10. Recommend disease monitoring and surveillance programmes as necessary.

Discussion

Even now, the basics of good medicine including quarantine, proactive health assessments, sero-surveillance, biomaterials banking, and vaccination will serve a zoo veterinarian well in their daily activities and routine collection care. While the latest techniques are interesting and find novel application, it must be remembered that well-executed baseline health monitoring is imperative for the most effective care and appropriate selection of these advanced techniques.

In the role of the Advisor, a veterinarian is identified to provide this support to their colleagues and a specific species or taxon. Through health assessment, nutrition, enrichment, substrate, training, reproduction, and multiple other surveys, they can accumulate and disseminate a variety of useful information to the individuals and institutions holding that particular species. They have a leadership role in that capacity and make dispersal of information more efficient.

Animal care in a zoo setting is a collaborative effort. There are multiple individuals at a variety of levels involved in daily animal care and any decision making regarding the zoo animal in a collection, ranging from keeper, to curator, to director, to veterinarian. In most cases, when an animal becomes ill, the expectation is the veterinarian will assume the leadership role in the management of that animal's care, and having access to a veterinary advisor facilitates this role. However, involving the animal care staff in every aspect of managing that particular case from diagnostic approaches to treatment protocols is imperative in order to foster a team attitude. The end results will be superior care and better communication. Perhaps, more importantly, the veterinarian, perceived as a team player, opens the door to be approached more frequently, to be involved in the day to day care concerns.

The best and often most overlooked tool for the veterinarian against disease is this simple communication. Conducting health surveys for specific populations and publishing those results is one way to accomplish that goal. Another, simpler, but no less important way is to be available to the animal care staff when animals are not clinical. Talking about the animals, looking at them when nothing is noticeably wrong, discussing nutrition, housing, enrichment and training, not just illness and disease; these things strengthen the relationship between the animal care staff and the veterinarian.

A veterinarian, both in their role as an advisor to a designated species or taxon, and as the day to day clinician to a zoological collection, should be a part of any discussion that involves animal welfare including the aforementioned basics, not just health issues. This attitude cannot be fostered without superior communication and collaboration.

For more information, please check the following websites:

<http://www.aazv.org>

click on Resources

<http://www.aza.org>

click on Animal care and management

APE MOVES – TRANSLOCATION OF THE WILHELMA BONOBOS AND GORILLAS INTO THE NEW MENSCHEN.AFFEN.HAUS!

KNAUF-WITZENS T, KRENGEL A

Wilhelma - Zoological and Botanical Gardens, Wilhelma 13, 70376 Stuttgart, GERMANY; tobias.knauf-witzens@wilhelma.de

Summary

In spring 2013, a new house for African apes was completed at Stuttgart Zoo. Two groups of 4.9 bonobos and 5.7 gorillas, respectively, were moved from the old housing, which served as their home for the last 40 years, into the new enclosure. Since crate training was impossible, most animals had to be immobilised. This occasion was used to perform a complete health check, including blood sampling and TB-testing, and to obtain samples for different studies. Additionally, a complete heart screening was performed on each adult animal by the international primate heart project (IPHP) and a reproductive assessment of all adult females was made. In order to coordinate all cooperating institutions and colleagues, preparation for this event started several months in advance. Altogether, 38 people (veterinarians, laboratory technician/veterinary assistant, veterinary student, curator, keepers, biologists and cardiologists) were involved in every translocation procedure, which took one full day for each group of apes. All animals arrived safely in their new housing and recovered well from anaesthesia. This manuscript describes in detail the different protocols used for this successful relocation and provides first medical results.

Introduction

The Wilhelma has been keeping great apes since 1958 (NEUGEBAUER, 1993), some of them originating from their natural habitat. In 1973 the “new ape house” was opened (HOLTKÖTTER, 2005). It set milestones in the management of primates and was built to follow high hygienic standards due to prophylactic reasons which resulted in the construction of a sterile design fondly called “bath room architecture” but which was capable to control common disease outbreaks like shigellosis or strongyloides infections (BRACK et al., 1995; WINGER et al., 1995). Nevertheless after more than 30 years of use it had come of age and it was decided to plan and build a new primate house for two African ape species: the Menschen.Affen.Haus. It was opened in May 2013 and houses gorillas and bonobos. Its design is based on the current state of the art of modern zoo keeping and includes the steadily grown knowledge of keeping great apes and their species-specific needs, the recommendations from the EEP husbandry guidelines as well as the experience from 55 years of care taking apes at the Wilhelma (WILHELMA, 2013).

The translocation of groups of apes needs meticulously planning (HOBY et al., 2011). Preparations started several months in advance. Arrangements between all participants like co-workers, specialists and laboratories had to be coordinated and were adjusted until the very start of the enterprise (KRENGEL and KNAUF-WITZENS, 2013). This article gives an overview of the veterinary aspects of this translocation.

Materials and methods

Animals (table 1):

The group of bonobos (*Pan paniscus*) consisted of 3.9 adult and sub-adult animals and one ten day old neonate. The ages ranged from six years to approx. 45 years in the oldest female. In wild born animals ages can only be given as estimates. This group was moved on April 16th 2013.

The group of gorillas (*Gorilla gorilla gorilla*) consisted of 1.4 adult and 1.2 juvenile animals ranging from one year to approx. 49 years in the oldest female. It was moved on April 30th 2013. In total, 3.1 juvenile gorillas from the nursery ageing one to two years were moved on May 2nd 2013.

Tab. 1: Identification of the animals translocated on April 16th 2013: 4.9 bonobos, April 30th 2013: 2.6 gorillas and May 2nd 2013: 3.1 gorillas from the nursery. GAN: Global Accession Number assigned by ZIMS; Sex: M = male, F = female. n.a. = not assessed. Prior to transport weights were estimated and the animals weight during transport. Animals sorted by age.

GAN	Name	Sex	Age in years	Birth	Est. weight [kg]	Weight [kg]
Bonobo (<i>Pan paniscus</i>)						
18791258	Kombote	F	~45	Wild	45	41.8
27641621	Hermien	F	~35	Unknown	45	46.8
8365526	Zorba	M	~33	Wild	50	41.6
MIG12-29745874	Mobikisi	M	~33	Wild	60	49.0
7297282	Chipita	F	~20	Wild	45	39.0
24402460	Ximba	F	~18	Wild	25	25.0
MIG12-28404521	Liboso	F	15	Captive	40	27.2
MIG12-28386603	Haiba	F	11	Captive	35	31.2
12177019	Banbo	F	10	Captive	30	29.6
18791857	Kasai	M	8	Captive	30	33.4
27564708	Huenda	F	6	Captive	20	20.8
MIG12-28591025	Nayembi	F	6	Captive	30	25.0
HJZ13-00342	Lubao	M	10 days	Captive	n.a.	n.a.
Gorilla (<i>Gorilla gorilla gorilla</i>)						
18788756	Mimi	F	~49	Wild	60	76.0
18788758	Undi	F	~40	Wild	98	96.4
4132858	Kolo	F	26	Captive	70	81.0
7471429	Kibo	M	22	Captive	200	160.0
18790702	Mutasi	F	18	Captive	75	86.4 (incl. Milele)
MIG12-28343245	Mawenzi	F	4	Captive	25	25.8
MIG12-28343246	Kimwali	M	3	Captive	20	21.0
HJZ12-00038	Milele	F	1	Captive	8	n.a.
Gorilla (<i>Gorilla gorilla gorilla</i>) nursery						
SSD11-00799	Okanda	M	2	Captive	n.a.	15.0
MIG12-29801349	Tano	M	1	Captive	n.a.	11.7
DVY12-00038	Vana	F	1	Captive	n.a.	8.6
HJZ12-00078	Tebogo	M	1	Captive	n.a.	9.8

Human participants:

Eight veterinarians, three cardiologists, five biologists, one laboratory technician/veterinary assistant, one vet. student, one curator and 19 keepers actively participated in each translocation. Three teams were formed. Each team was led by a veterinary surgeon.

Team A was stationed at the old ape house and was responsible for the immobilisation of the animals, general health checks and collection of the samples. Team B transported the animals from the old house into the new house and was responsible for the monitoring of the immobilisation. Team C was stationed at the veterinary quarantine of the new house and performed sonographic assessments of the heart, reproductive tract and inner organs. Monitoring of the immobilisation, placing the animals into their individual wake up cages and to observe their recovery were essential duties of this team. Apart from the teams each animal was appointed an individual keeper who accompanied this specific animal, took care of it and linked the different stations.

Endoparasitic evaluation:

In the new house the indoor enclosure has a biofloor consisting of pine bark, the outside enclosure is natural flooring. To prevent the contamination of the new floors with endoparasites the animals were screened repetitively at least once a month from November 2012 until March 2013 (table 2). On nine occasions a total of 57 samples were examined using either our in-house laboratory or one of three external laboratories: Landesgesundheitsamt Baden-Württemberg, Stuttgart, Germany; Vet Med Labor GmbH, Ludwigsburg, Germany and Labor Prof. Gisela Enders MVZ GbR, Stuttgart, Germany. Pooled and individual faecal samples were assessed natively, coloured with iodine or by using established methods for flotation, sedimentation and larval migration via the Baermann-Wetzel funnel technique (e.g. BOCH et al., 2006). Entamoebas were differentiated using PCR. For *Cryptosporidium* and *Giardia* an ELISA was used. After the detection of hookworms in November 2012 and pinworms in one individual via transparent adhesive tape in January 2013 all animals were treated orally with 0.4 mg/kg body weight (BW) ivermectin (Alfamectin[®] 6 mg/g; Alfavet Tierarzneimittel GmbH, Neumünster, Germany).

Immobilisation:

Since crate training was impossible most animals had to be immobilised. Each animal was estimated for its weight and an individual anaesthesia protocol was created including former medication and individual particularities.

On the evening before and the morning of the transport premedication was given using diazepam (Valium[®] "Roche" 10 mg-Tabletten, Roche, Vienna, Austria) at a dosage of 0.1 mg/kg BW. All animals were fasted for at least 18 hours prior to transport.

Each ape was darted by blowpipe using a mixture of ketamin 5.0 mg/kg BW (Ketamin[®] 10 %, medistar, Holzwickede, Germany) and xylazin 0.5 mg/kg BW (Xylazin[®] 2 % Serum-Werk Bernburg AG Bernburg, Germany; Rompun[®] TS, Bayer Vital GmbH, Leverkusen, Germany). An intravenous catheter (Vasocan[®] Braunüle[®], B. Braun Melsungen AG, Melsungen, Germany) was inserted into the *vena cephalica* and a drip of Ringer-lactate solution (Ringer Lactat Lösung nach Hartmann B. Braun Vet Care, B. Braun Melsungen AG, Melsungen, Germany) was infused during the anaesthesia at a rate of 2 - 5 ml/kg BW/h. To maintain immobilisation situational dependent dosages of propofol (Propofol 1 % MCT Fresenius, Fresenius Kabi, Bad Homburg, Germany) were given i.v. ranging around 1.0 mg/kg BW. The animals were intubated (HanauLife[®] Mac Macintosh laryngoscope with blade No. 2 to 4; tracheal tube, ID 7,0 to 14,0, Kruuse, Langeskov, Denmark) and inhaled with isoflurane (Isofluran CP[®] 1 ml/ml, CP-Pharma Handelsge. mbH Burgdorf, Germany) at 1.0 % to 2.5 % (figure 1). After induction of isoflurane no more propofol injections were necessary. At the end of the examinations and placement of the animals into the wake up cages isoflurane was disconnected,

the tube and the intravenous catheter removed and the animals left in their boxes to wake up. Animals below the age of three years were not immobilised.

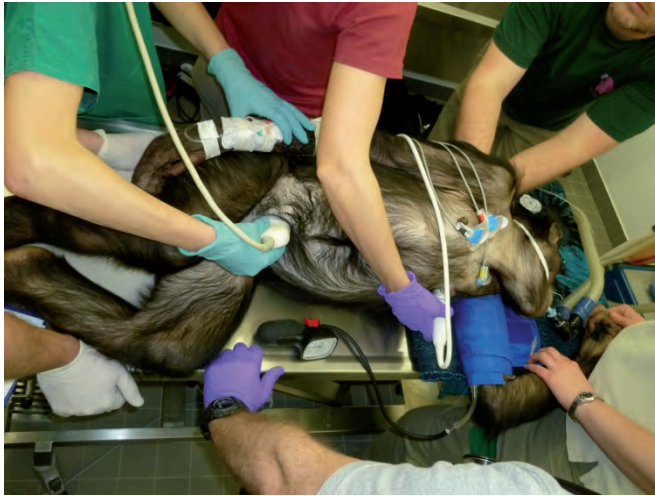

Fig. 1: Intubated and fully covered animal being examined parallel by both teams of sonographers. (Photo: T. Knauf-Witzens)

Health check:

All animals were weighed (EOS 300K200NXL, Kern, Balingen, Germany). General body condition, lymphnodes (*Lnn. cervicales, axillares, inguinales et subiliaci*), oral cavity and teeth, ears, eyes, limbs, hands and feet were examined, heart and lungs auscultated. Where necessary teeth were extracted or nails clipped.

Blood was drawn from the *vena cephalica* or *vena inguinalis* and sent in for further analysis to specialised laboratories: Vet Med Labor GmbH, Ludwigsburg, Germany: haematology and biochemistry (large check-up) and additionally for the bonobo group troponin (TNT-HS) and nt-pro BNP; Landesgesundheitsamt Baden-Württemberg, Stuttgart, Germany: serology for hepatitis B virus (HBV: HBs-Antigen M-ELISA), human immunodeficiency virus (HIV: anti-HIV1/2 M_ELISA) and echinococcus (ELISA, Immunblot); Labor Prof. Gisela Enders MVZ GbR, Stuttgart, Germany: gorilla group: serology for Epstein-Barr-virus (EBV: EBV VCA-IgG-AK (IFT), EBV VCA-IgM-AK (IFT), EBV EBNA -1-IgG-AK (EIA), EBV-IgG Immunoblot: p72 (EBNA1), p18 (VCA), p23 (VCA), BZLF1, p138 (EA), p54 (EA)), herpes simplex virus (HSV: HSV-AK IgG Typ 1/2 (Enzygnost[®] EIA), HSV-AK IgM (Enzygnost[®] n.RF EIA)), troponin (T. high sensitive) and nt-pro BNP (Roche E170); bonobo group: hepatitis B virus (HbsAG (CLIA)), HIV (HIV-1/2 AK + p23 AG (Murex, CLIA) and echinococcus-AK (IFT). Prionics AG, Schlieren, Switzerland performed the interferon gamma test (IFN-g, Primagam[®]). They collected heparinised blood from the Wilhelma and performed the test in Switzerland within seven hours after withdrawal from the animal. To export the samples CITES papers needed to be acquired and customs regulation organised in advance. An intrapalpebral tuberculin test was performed using old world mammalian tuberculin (MOT: tuberculin mammalian, human isolates intradermic, Synbiotics Corporation, San Diego, USA) in the bonobos. 0.1 ml solution was injected into the dermis of the right upper eye lid using a 0.45 x 12 mm needle (Terumo[®]) (figure 2). This scheme was changed to a comparative test using bovine PPD (CZV bovines tuberculin PPD, CZ Veterinaria S.A., Spain) and MOT in the gorillas. The test was read after 48 and 72 hours post injection (figure 3) and was quantified in categories as described by BUSHMITZ et al., 2009. To prevent endoparasite transmission all animals were dewormed during transport using 0.4 mg/kg BW ivermectin (Diapec[®] R 1 %: Albrecht GmbH, Aulendorf, Germany).

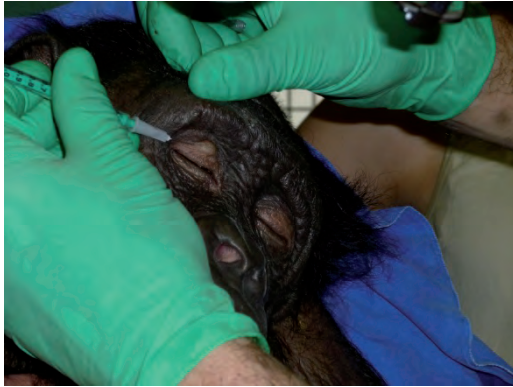

Fig. 2: Performance of intrapalpebral application of tuberculin into the upper eye lid. (Photo: T. Knauf-Witzens)



Fig. 3: Interpretation of the swelling 72 hrs after tuberculin injection: moderate swelling grade 3. (Photo: N. Staes)

Collection of samples for scientific studies:

Since it is very rare to sample a whole group of apes we used the occasion to supply different studies with requested samples. For genetic studies EDTA-blood was provided for the great ape biobank (Hvilsom, Copenhagen, Denmark) and oral mucosa swabs and plucked hair for the University of Antwerp, Belgium. A study for the detection of mycobacteria (SALCHOW, 2012) was supported with serum, deep throat swabs, anal swabs and faeces; another one for MRSA with nasal and perianal swabs (JÖRGENS, 2012; JÖRGENS et al., 2013).

Sonography (figure 1):

Electrocardiography and echocardiography were performed by the International Primate Heart Project, Cardiff Metropolitan University, Great Britain (IPHP) (SHAVE et al., 2013). Reproductive assessments and scans of inner organs of the bonobos were achieved by Max Planck Institute for Evolutionary Anthropology, Leipzig, Germany and the Leibniz Institute for Zoo and Wildlife Research, Berlin, Germany.

Results

Endoparasitic evaluation (table 2):

A total of nine samples revealed one or more parasite species (15.8 % of all samples). Single or mixed infections with *Entamoeba coli*, *E. dispar* and/or *Chilomastix mesnili* were diagnosed in seven out of 57 samples (12.3 %) from both groups of apes. *Blastocystis hominis* was seen as a co-infection in four out of these seven cases (7.0 % of all samples). Once a co-infection of *B. hominis* and *Ch. mesnili* with *Giardia lamblia* and hookworm eggs was diagnosed (1.8 %). Subsequent faecal examinations for *Giardia* using either native preparations or ELISA were negative. *Enterobius vermicularis* was diagnosed in one bonobo by flotation. He was proven to be the only shedder by adhesive tape samples collected from the perianal region. After treatment all control examinations were negative. *Dicrocoelium dendriticum* was diagnosed once with a positive control examination, but the laboratory was uncertain about these results and thus consulted a specialist for further analysis (Dr. P. Kimmig, Labor Enders, Stuttgart, Germany). His assessment and following examinations could not confirm a trematode infection.

Tab. 2: Results of endoparasitic examinations from both groups of apes sampled between November 2012 and March 2013. Different tests were applied: native swabs, native swabs coloured with iodine, flotation, sedimentation, migration: Baermann-Wetzel funnel technique, PCR to differentiate *Entamoeba dispar* from *E. histolytica*, ELISA for the detection of *Cryptosporidium* or *Giardia*, adhesive tape. Co-operating laboratories: LGA: Landesgesundheitsamt Baden-Württemberg, Stuttgart; IDEXX: Vet Med Labor GmbH, Ludwigsburg; Enders: Labor Prof. Gisela Enders MVZ GbR, Stuttgart. Abbreviations are underlined.

Date	Species	Test	Laboratory	Positive/total samples	Positive results
12.11.12	Bonobo	Native	LGA	1/1	<i>E. coli</i> , <i>B. hominis</i> , <i>Ch. mesnili</i>
	Gorilla	Native	LGA	1/1	<i>B. hominis</i> , <i>Ch. mesnili</i> , <i>D. dendriticum</i>
16.11.12	Gorilla	Native	LGA	1/1	<i>E. coli</i> , <i>B. hominis</i> , <i>D. dendriticum</i>
19.11.12	Gorilla	Native (<i>D. dendriticum</i>)	Enders	0/4	-
26.11.12	Gorilla	Native	LGA	2/4	<i>B. hominis</i> , <i>Ch. mesnili</i> , <i>G. lamblia</i> , Hookworms
10.12.12	Gorilla	Native, iodine, flotation, ELISA	IDEXX	0/4	-
10.1.13	Bonobo	Native, PCR	LGA	1/4	<i>E. dispar</i>
		Native, iodine, flotation, migration, ELISA	IDEXX	1/4	<i>E. vermicularis</i>
	Gorilla	Native	LGA	0/4	-
		Native, iodine, flotation, migration, ELISA	IDEXX	0/3	-
21.1.13	Bonobo	Native, flotation, sedimentation, migration, adhesive tape	In-House	1/4	<i>E. vermicularis</i>
	Gorilla	Native, flotation, sedimentation, migration	In-House	0/4	-
13.2.13	Bonobo	Native, flotation, sedimentation, migration	In-House	0/4	-
	Gorilla	Native	In-House	0/4	-
14.3.13	Bonobo	Native	LGA	0/3	-
		Native	In-House	0/4	-
	Gorilla	Native	LGA	1/4	<i>E. dispar</i>
		Native	In-House	0/4	-

Immobilisation:

Premedication with diazepam resulted in mildly sedated bonobos starting approximately one hour after medication. Especially the two older males were somnolent. Therefore the gorillas were treated with only half the dosage in the morning. After approximately six hours the effect started to wear off and the animals became more uneasy facing distant immobilisation. Seven out of 19 animals had to be darted repetitively due to incomplete injection of the drugs. After the first dart the median time for the animals to go down and to be handled safely were 20 and 21 minutes in bonobos and gorillas,

respectively. Immobilisation lasted around 8 and 15 minutes in bonobos and gorillas, respectively before first signs of recovery like intensified muscle tonus, movements of finger or limbs and lifting of the head appeared. When these signs were noticed propofol was injected i.v. which resulted in complete relaxation after about five to ten seconds. This effect lasted dose dependant for 3 to 19 minutes in bonobos and 7 to 31 minutes in gorillas. During this time all tests and the transport into the new house could be completed. All animals arrived relaxed but the female with the neonate in which the use of anaesthetic drugs was reduced to a necessary minimum. A side effect of propofol was apnoea of up to two minutes. After disconnection from isoflurane the recovery time until the animals were in a sitting position took between 16 to 97 minutes in bonobos and 5 to 90 minutes in gorillas. The shortest duration for the whole procedure was 1h 39min in bonobos and 1h 36min in gorillas, the longest 2h 36min and 3h 08min, respectively. The mean rectal temperatures were 35.6°C and 36.5°C, mean heart rates were 103/min and 86/min in bonobos and gorillas, respectively, mean breath rates were 29/min and mean oxygen saturation 92 % in both species.

Health checks and preliminary results from cooperating studies:

All animals were in good general health. All lymphnodes were within physiological ranges. Several teeth, especially in the older female gorillas and one older male bonobo were fractured. In three bonobos teeth had to be extracted because of a) loose teeth in an old female, b) a fractured *incisivus* in a young male and c) a persistent deciduous tooth in a young female. In the gorillas signs of dental caries were noticed in several animals. One wild-born female bonobo had a healed bullet wound resulting in partial loss of the tongue and lower jaw including its teeth (Chipita). In the bonobos small multifocal ulcers and papilomas were noticed in the oral cavity. In some gorillas swollen tonsils and small circumscribed multifocal ulcerations and a coated tongue were evident. Mucosal swabs revealed an alternating mixture of *Escherichia coli*, *Streptococcus agalctiae* and *Klebsiella pneumoniae*, *S. pneumoniae*, *S. dysgalactiae* and beta-haemolysing Streptococci. All gorillas had had contact with EBV (high avidity of p23-band, however without EBNA-1 AK) and Herpes simplex (high IgG titres, negative IgM). In Kibo, the silverback, a fistula 2 cm in diameter was noticed beneath the upper lip (figure 4). In the older females first signs of cataract were noticed. In the three year old gorilla a *pectus carinatum* was palpable during examination. To rule out rickets radiographic images were obtained and sent to a human radiologist for further analysis and rickets could be ruled out (figure 5 and 6).

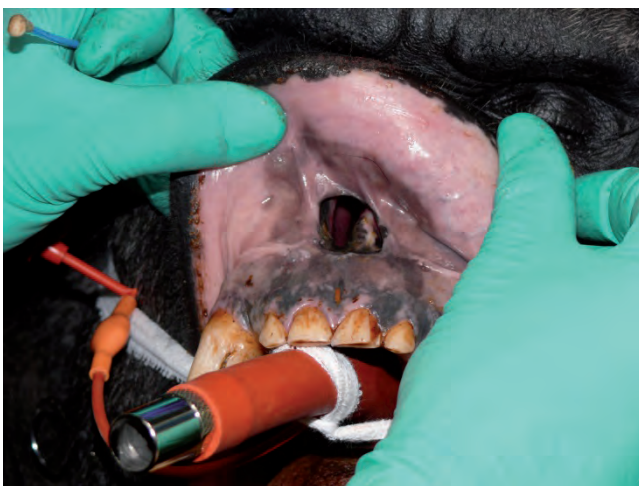

Fig. 4: Oro-nasal fistula in the silver back Kibo.
(Photo: T. Knauf-Witzens)

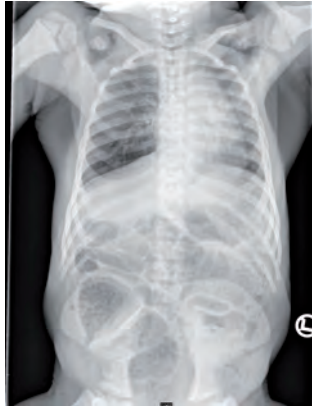

Fig. 5: Ventro-dorsal X-ray of 1.0 gorilla Kimbali. (Photo: Wilhelma)

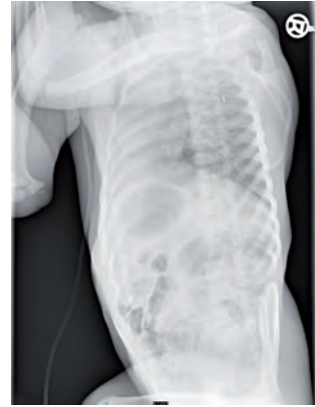

Fig. 6: Latero-lateral X-ray of 1.0 gorilla Kimbali. (Photo: Wilhelma)

Haematological and biochemical blood values were within standard ranges (BRACK et al., 2009; MCCLURE et al., 1972) (data not shown).

Serology for HBV and HIV were negative in all animals. Results for echinococcus ELISAs in the gorillas were negative, two bonobos had questionable, three animals positive results. Serum from these animals was re-evaluated using more sensitive tests (IFT and immunblot) and all samples were negative.

In seven bonobos the intrapalpebral tuberculin test using MOT resulted in suspicious or positive tests (grade 3 or 4) (figure 3). Therefore the scheme was changed to a comparative test and bovine PPD was introduced additionally to MOT for the gorillas; all results were negative. All INF-g tests of both species were negative as well as the PCR examinations for *Mycobacterium tuberculosis* complex of deep throat swabs (SALCHOW et al., published in this proceeding). Results from serum, anal swabs and faeces for nontuberculous mycobacteria (NTM) are still pending (SALCHOW, personal communication).

Nasal and perianal swabs for MRSA all but one animal were negative (JÖRGENS, unpublished). Details on the mycobacteria and MRSA study will be published in the near future.

The father of the new born bonobo Lubao was identified to be Kasai, son of Chipita.

Sonography:

Transabdominal sonography of the liver did neither reveal abnormalities nor signs of echinococcus cysts or trematode infestation in any animal. In the bonobos three more females were found to be pregnant (figure 7) and the age of the foetuses were estimated to be 133, 190 and 190 days predicting two births end of May and one in August 2013.

Conclusions of the heart assessments were put into relation with two heart markers (data not shown). The older males of both species, Kibo and Mobikisi but especially Zorba, had conspicuous sonographic findings and elevated heart markers. More detailed results will be published in the near future.

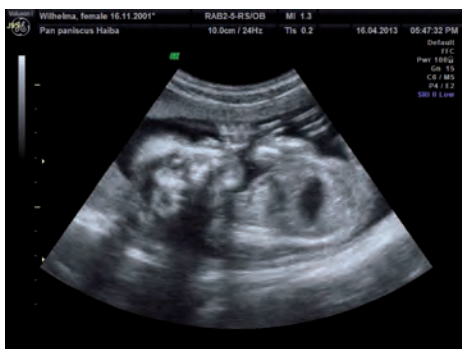

Fig. 7: Sonographic display of a foetus approx. 133 days old. (Photo: IZW)

All African apes of the Wilhelma, 4.9 bonobos and 5.7 gorillas, were moved into the new ape house in spring 2013. The group of gorillas was moved 14 days after the bonobos and were followed several days later by the gorilla nursery.

Prior to transport all animals were intensively screened for endoparasites and several organisms were identified. *Entamoeba coli*, *E. dispar* and *Ch. mesnili* were considered as apathogenic without the necessity of treatment. *B. hominis* was considered as a facultative pathogen which can cause diarrhoea during proliferation (LGA, pers. communication). Since there were no signs of disease at the time these organisms were diagnosed no treatment was implemented. *Enterobius vermicularis* is an endoparasite that is best diagnosed using sticky tape in the perianal region (BRACK et al., 1995). This disease and the hookworm infection were treated successfully. For biosecurity reasons all keepers were screened by the occupational physician. The infestation with *D. dendriticum* was questionable. Near Stuttgart zoo there are no swampy areas from which contaminated grass could act as vector. Additionally the animals had been kept under semi-sterile conditions with no contact to boggy grounds. A specialist and subsequent examinations reassured us that the first diagnosis probably was an artefact. *G. lamblia* was only diagnosed once. Subsequent samples tested negative although including ELISA. Interestingly, the parasite load decreased over time. Two months prior to translocation only one sample identified *E. dispar*. But since endoparasites tend not to shed eggs or oocytes permanently only an infestation can be proven, never its absence. Later this year this was proven when a new female was introduced into the gorilla group that tested parasitological negative at arrival but later started to intermittingly shed *B. hominis*.

The goal of the translocation was to move all animals safely and to prevent harm from both: ape and human being. Therefore anaesthesia was planned to be as short as possible and the examinations were reduced to a minimum. Concerning immobilisation pre-anaesthesia using diazepam resulted in more relaxed animals that were slower in motion, needed less drugs and were faster to be handled. This was clearly visible in the animals that were darted last and where the effect of diazepam had weaned off. The gorillas seemed to be less prone to diazepam and next time we would use a higher dosage in this species. The intravenous access was used to support the circulatory system, for emergency treatments and to extend anaesthesia. The application of propofol kept the animals in a relaxed and steady state until they could be connected to isoflurane. Intubation kept the airways of the animals open, prevented foreign body aspiration and gave an emergency access to the respiratory tract. Recovery times seemed to be individually long. No correlation between misjudgement of body weights resulting in under- or overdosing of anaesthetic drugs, number of darts applied or amount propofol injected nor the time the animals were manipulated was visible.

Health checks revealed findings not noticed during routine adspecation. One wild born bonobo had a healed bullet wound in its mouth. Our silver-back had an oral vestibulo-nasal fistula which does not disturb him. One juvenile gorilla had a *pectus carinatum*; rickets could be ruled out. As a differential diagnosis human medicine describes the Marfan syndrome as a heritable disease causing ventricular bigeminy but which is more commonly associated with *pectus excavatum* (ARSLAN-KIRCHNER, 2008). Dissection of the aorta or aneurysm at the base of the aorta, respectively, were difficult to be distinguished due to the limited time of examination and tachycardia in this gorilla and further studies are needed to evaluate this abnormality. Nevertheless the EEP was informed about this circumstance and it was recommended not to breed with this animal for the moment. Teeth were examined and where possible quick removals were performed. For more accurate dentistry separate appointments with a dentist will be needed.

In the gorillas ulcerations of the oral mucosa including the soft palate as well as enlarged tonsils led to further analysis identifying past infections with EBV and HSV. FELLINGER (1996) describes the connection of EBV with nasopharynx carcinomas in human beings, PLESKER (2004) and BRACK et al. (1995) mention among other things oral vesicles and ulcers in combination with HSV. The detected microbacteria were all facultative pathogens which belong to the normal oral flora, especially when

considering that some animals practice coprophagia (Labor Enders, personal communication). Nevertheless no treatment was performed and no clinical symptoms referring to a disturbance in the oral cavity have been displayed since. The haematological and biochemical values were mostly within normal ranges. Outliers can be brought in context with multiple injections (raised CK or LDH) or growth in juveniles (raised AP). HIV1/2 cross reacts with SIV (PLESKER, 2008) and we have controlled this by comparing this test with results from specific SIV-tests in the past (unpublished data). Therefore we have been using HIV-tests in our routine diagnostic. HBV and Echinococcus have been described in zoo primates (GRETHE et al., 2000; RIETSCHEL and KIMMIG, 1994, REHMANN et al., 2005), therefore the Wilhelma apes were tested to determine potential zoonotic risks and to rule out infection prior to release into a naturally floored outside enclosure, respectively. All tests were negative.

Seven bonobos displayed mild to moderate reactions to MOT on their eye lid. From the authors own experience MOT can cause cross reactions with non-tuberculosis mycobacteria (unpublished data) which was supported by different colleagues (SCHRÖDER, pers. communication; RIETSCHEL, 2004). Therefore multiple tests were arranged for further analysis. Deep throat swabs were all negative for MBTC using PCR. To obtain the best test results for the IFN-g tests heparin blood samples were picked up by the analysing company (Prionics, Zurich, Switzerland), transported and analysed in their own laboratories within seven hours after blood collection. All samples were negative. The results were discussed with the official veterinarian and interpreted as cross reactions with NTM. Similar experiences exist from other zoos (e.g. WENKER et al., 2010) that came to the same conclusion: the questionable group needs to be reassessed, especially using cultivation of gastric lavages.

Pregnancies were detected in three animals and their gestation length was estimated. The births took place on May 25th, July 5th and August 15th. Apart from one birth the predictions were correct.

Heart examinations have become more and more important in great apes and standardised examination protocols are under development (MURPHY et al., 2011; SHAVE, 2013). Due to time limitations examinations were partially incomplete. Some sonographically obtained conclusions were concerning, therefore serum heart values were assessed. The two older bonobo males were especially concerning, but up to now have not displayed any clinical signs of reduced heart function like oedema or heart coughing. One of them has been trained to be scanned without anaesthesia. The relationship between heart assessments and heart markers showed incoherent results in some animals. Since the reference values were given for human beings, they might be in a different range for apes. Also bonobos tended to have higher values than gorillas which could give a hint for species specific values. The shorter life span of apes in comparison to human beings also needs to be taken into account. Further studies are needed to create more understanding on ape heart assessments.

In conclusion the translocation of two groups of African apes at the Stuttgart zoo was a success. Detailed preparations were essential to ensure a smooth course and one had to be prepared for the unexpected at all times. Both groups were intensively examined and many important findings were collected - at the same time keeping the time of immobilisation as short as possible. In conclusion we would follow the same protocol for the next translocation.

Acknowledgements

We thank all colleagues and participants for their support, in particular the keepers of our great apes and the primate curator Dr. M. Holtkötter. Thank you also to Ms. M. Balz, the heart and soul of our animal hospital, for her careful preparations and review. The ultrasound examinations were performed by R. Shave and A. Drane (IPHP, Cardiff, UK), Drs. B. Drews and K. Röllig (IZW, Berlin, Germany) and Dr. T. Schäufele (Robert-Bosch Hospital, Stuttgart, Germany). Drs. N. Schauerte and C. Geiger (Frankfurt Zoo, Germany), Dr. W. Rietschel, A. Salchow and D. Jörgens completed our veterinary

team. We received friendly support from Drs. P. Kopp and N. Pantchev (IDEXX, Vet Med Labor, Ludwigsburg, Germany), Dr. R. Oehme and colleagues (LGA, Stuttgart, Germany), Labor Enders, Stuttgart, Germany and our veterinary intern Mrs. C. Spahr. Flexibility and spontaneity of all participants was needed at all times, but a special thank you goes to Prionics AG, Schlieren, Switzerland for the collection of the samples and their assessments on a public holiday.

References

- ARSLAN-KIRCHNER M, VON KODOLITSCH Y, SCHMIDTKE J (2008): *The importance of genetic testing in the clinical management of patients with Marfan syndrome and related disorders. Dtsch. Arztebl. Int.* **105**, 483.
- BOCH J, SCHNIEDER TH, SUPPERER R, BAUER B (2006): *Veterinärmedizinische Parasitologie. Stuttgart: Parey.*
- BRACK M, GÖLTENBOTH R, RIETSCHEL W (1995): *Primaten. In: Göltenboth R, Klös H-G (Eds.): Krankheiten der Zoo- und Wildtiere. Berlin: Blackwell, 25 - 66.*
- BUSHMITZ M, LECU A, VERRECK F, PREUSSING E, RENSING S, MÄTZ-RENSING K (2009): *Guidelines for the prevention and control of tuberculosis in nonhuman primates: recommendations of the European Primate Veterinary Association Working Group on Tuberculosis. J. Med. Primatol.* **38**, 59 - 69.
- FELLINGER J, RIETSCHEL W, CZERNY CP (1996): *Prevalence of Epstein-Barr virus (EBV) antibodies in primate stocks of zoological gardens. J. Med. Primatol.* **25**, 327 - 332.
- GRETHE S, HECKEL J-O, RIETSCHEL W, HUFERT FT (2000): *Molecular epidemiology of hepatitis B virus variants in nonhuman primates. J. Virol.* **74**, 5377 - 5381.
- HOBY S, ADAMI C, WENGER S, WYSS F, WENKER C (2011): *Zoo Basel retour: Erfahrungen mit der Gruppenanästhesie bei Gorillas und Schimpansen. 31. Arb. Tagung der Zootierärzte im deutsch.spr. Raum, 113 - 115.*
- HOLTKÖTTER M (2005): *Ein Rückblick – 47 Jahre Menschenaffenhaltung in der Wilhelma. Wilhelma Magazin* **1**, 8 - 11.
- JÖRGENS D (2012): *Multiresistente Staphylokokken – potentielle Zoonoseerreger in Zoos? 32. Arb. Tagung der Zootierärzte im deutsch.spr. Raum, 169 - 170.*
- JÖRGENS D, GREENWOOD AD, RIETSCHEL W, HECKEL J-O, SALCHOW A, KNAUF-WITZENS T, HEOLZLE LE (2013): *Multidrug-resistant staphylococcus in zoo animals with a focus on primates – is there a zoonotic potential for humans? Proc. Internat. Conf. Diseases Zoo Wild Anim., 143.*
- KRENGEL A, KNAUF-WITZENS T (2013): *Umzug ins neue Heim- die afrikanischen Menschenaffen der Wilhelma ziehen in das Menschen.Affen.Haus!. 33. Arb. Tagung der Zootierärzte im deutsch.spr. Raum, (IN PRINT).*
- MCCLURE HM, KEELING ME, GUILLOUD NB (1972): *Hematologic and blood chemistry data for the gorilla (Gorilla gorilla). Folia Primatologica* **18**, 300 - 316.
- MCMANAMON R, LOWENSTINE LJ (2012): *Cardiovascular disease in Great Apes. In: Miller RE, Fowler ME (Eds.): Fowler's Zoo and Wild Animal Medicine. Current Therapy, Vol. 7. Elsevier Saunders, St. Louis, USA, 408 - 415.*
- MURPHY HW, DENNIS P, DEVLIN W, MEEHAN T, KUTINSKY I (2011): *Echocardiographic parameters of captive western lowland gorillas (Gorilla gorilla gorilla). J. Zoo Wildl. Med.* **42**, 572 - 579.
- NEUGEBAUER W (1993): *Die Wilhelma: ein Paradies in der Stadt. Stuttgart: Theiss, 84.*
- PLEASKER R (2004): *Zoonotic risks in handling non-human primates. 2. Tagung der FG ZWE, Göttingen, Germany, 63 - 67.*

-
- REHMANN P, GRÖNE A, GOTTSTEIN B, SAGER H, MÜLLER N, VÖLLM J, BACCIARINI LN (2005): Alveolar echinococcosis in the zoological garden Basle. *Schweiz. Arch. Tierheilkd.* **147**, 498 - 502.
- RIETSCHEL W, KIMMIG P (1994): Alveoläre Echinokokkose bei einem Javaneraffen. *Tierärztl Praxis*, **22**, 85 - 88.
- RIETSCHEL W (2004): Tb or not tb (nicht von Shakespeare). *Zoolog. Garten N.F.* **74**, 289-298.
- SALCHOW A (2012): Untersuchung zum Vorkommen und zur Bedeutung ausgewählter Mykobakterien bei Zootieren. 32. Arb. Tagung der Zootierärzte im deutsch.spr. Raum, 171 - 173.
- SHAVE R, OXBOROUGH D, SOMAUROO J, FELTRER Y, STRIKE T, ROUTH A, CHAPMAN S, REDROBE S, THOMPSON L, UNWIN S, SAYERS G, MURPHY H, RAPOPORT G, STÖHR E (2013): Echocardiographic assessment of cardiac structure and function in great apes: a practical guide. *Int. Zoo Yearbook*. doi: 10.1111/izy.12026.
- WILHELMA (2013): Menschen.Affen.Haus! - Die neue Anlage für Afrikanische Menschenaffen. Heidelberg: ABC Druck. http://www.wilhelma.de/fileadmin/images/neuigkeiten/Menschenaffenhaus/Brosch%C3%BCre_Affenhaus_2013.pdf
- WINGER A, RIETSCHEL W, KNOLLMANN-SCHANBACHER G, STRA E (1995): Shigella-Keimträger, eine dauernde Gefahr für Primaten und Pflegepersonal in zoologischen Gärten. *Verh.ber. Erkr. Zootiere* **37**, 375 - 387.
- WENKER C, HOBY S, STEINMETZ HP (2010): Diagnostic TB-screening of great apes in Basel Zoo. 6th Göttingen Symposium, Tuberculosis in nonhuman primates, Göttingen, 2. Dezember.

THE MASOALA RAINFOREST EXHIBIT AT ZURICH ZOO - 10 YEARS OF EXPERIENCE FROM A VETERINARY PERSPECTIVE

HATT J-M¹, BAUERT M², WENGER S¹

¹University of Zurich, Vetsuisse Faculty, Clinic for Zoo Animals, Exotic Pets and Wildlife, Winterthurerstrasse 260, 8057 Zurich, SWITZERLAND; jmhatt@vetclinics.uzh.ch

²Zurich Zoo, Zürichbergstrasse 221, 8044 Zurich, SWITZERLAND

In 2003, Zurich Zoo opened its Madagascar rainforest exhibit, based on the biosphere of the Masoala peninsula. On a surface of 11,000 m² some 430 animals of 60 species are kept together. The temperature is between 20 and 30°C, relative humidity is approximately 80 % and daily rainfall averages 80,000 l. With the exception of Aldabra tortoises (*Geochelone gigantea*), animals are not restricted to distinct areas of the exhibit and most species can potentially enter into direct contact with visitors. This type of management represents a rare setting and requests special approaches from an animal health management point of view.

Based on hospital hygiene recommendations, microbiological analyses from lakes and rain were initially performed at selected points every three months and cultured for yeast, moulds and bacteria with special emphasis for *Legionella* sp. After eight years the intervals have been reduced to every six months.

All animals to be released in the exhibit underwent a minimum of 30 day quarantine, which included testing for endoparasites and enteral *Salmonella* spp. Additional tests were performed based on the species and origin of animals. Due to the permanent high humidity several Aldabra tortoises (*Geochelone gigantea*) developed a fungal dermatitis on the carapax, which needed treatment. Interspecific aggression from Bamboo lemurs (*Haplemur alaotrensis*) against red-fronted lemur (*Eulemur rufifrons*) necessitated a hand-rearing once. Bamboo lemurs (*Haplemur alaotrensis*) also tended to be overweight. In the red ruffed lemurs (*Varecia rubra*) a GnRH-analogue implant (Suprelorin[®] 4.7 mg, Virbac, Glattbrugg, Switzerland) was applied on an annual basis to inhibit reproduction.

Acknowledgements

The authors wish to acknowledge the excellent care and help of data collection by the keepers of the Masoala rainforest exhibit.

DENSITY-DEPENDENT EFFECTS ON MORTALITY IN 42 ZOO ANIMAL SPECIES AT THE NATIONAL ZOOLOGICAL GARDENS OF SOUTH AFRICA

KELLER S¹, BALSIGER A¹, ESPIE I², LANE EP², KOTZE A², CLAUSS M¹, CODRON D^{1,3}

¹University of Zurich, Vetsuisse Faculty, Clinic for Zoo Animals, Exotic Pets and Wildlife, Winterthurerstrasse 260, 8057 Zurich, SWITZERLAND; mclauss@vetclinics.uzh.ch

²National Zoological Gardens of South Africa, 232 Boom St, Pretoria, SOUTH AFRICA

³Florisbad Quaternary Research, National Museum, PO Box 266, Bloemfontein 9300, SOUTH AFRICA

Density-dependent effects on reproduction, health or mortality are rarely considered in the zoo literature but have received some attention recently. Using data from 1980 to 2012 of the National Zoological Gardens of South Africa, considering only species that were in groups or pairs with offspring, and with more than 50 individuals in the database (24 artiodactyl species, 13 carnivores, four primates, and the rock hyrax), density dependence was assessed statistically with a set of tests that included direct and delayed effects (i.e., on mortality of the same year or of the following year). We tested whether, across all years, mortality of a year was correlated to the number of animals alive in that year, the previous year, or a combination of both. This was performed for overall mortality and for neonate mortality alone. In 50 % of the species investigated, a density-dependent effect on mortality was statistically significant in the dataset, including 41 % of the artiodactyls, 50 % of the carnivores, and all four primate species; R^2 of these correlations reached up to 0.69, indicating that a large part of mortalities could be explained by density dependence in some species (e.g. *Callithrix* sp., *Lycaon pictus*, or *Potamochoerus porcus*). The results indicate that density-dependent mortality is not a general pattern in group-kept captive wild animals. Yet, they also suggest that such mortality might occur more often than intuitively expected. Zoo management strategies should include monitoring for density dependence, and, if necessary, introduce measures to adjust animal numbers to prevent them.

This study was part of the Zoo Research Camp (ZRC) 2013 organised by the National Zoological Gardens of South Africa and the Vetsuisse Faculty, University of Zurich, Switzerland.

MORTALITY AND DISEASES IN GREATER FLAMINGO (*PHOENICOPTERUS ROSEUS*) AND CARIBBEAN FLAMINGO (*PHOENICOPTERUS RUBER*) KEPT AT THE NATIONAL ZOOLOGICAL GARDENS OF SOUTH AFRICA

HAGEN K¹, ESPIE I², LANE EP², KOTZE A², WYSS F¹, CLAUSS M¹, CODRON D^{1,3}

¹University of Zurich, Vetsuisse Faculty, Clinic for Zoo Animals, Exotic Pets and Wildlife, Winterthurerstrasse 260, 8057 Zurich, SWITZERLAND; mclauss@vetclinics.uzh.ch

²National Zoological Gardens of South Africa, 232 Boom St, Pretoria, SOUTH AFRICA

³Florisbad Quaternary Research, National Museum, PO Box 266, Bloemfontein 9300, SOUTH AFRICA

Summary

Flamingos are known for susceptibility to traumatic injuries and other diseases. So far, no species-specific management concepts exist for individual flamingo species. In this study, we demonstrate that although the causes of mortality were similar between a group of *Phoneicopterus roseus* and a group of *P. ruber* that were kept at the same facility under identical husbandry conditions, mortality was significantly higher in *P. ruber*, which suggests a higher disease susceptibility potentially due to climatic differences between the species natural habitat and those of the zoological institution. *P. ruber* also showed a comparatively high occurrence of haemosiderosis in females, thus confirming one earlier report for flamingos in general. Mortality in *P. roseus* was correlated to population size, suggesting that density-dependent effects were partly responsible for health issues, and that although it is desirable to keep flamingos in large groups, group size must be adjusted to the respective facility.

Introduction

Flamingos (*Phoenicopterus* spp.) are very long-lived birds (FOWLER and CUBAS, 2001) and present a variety of health problems in captivity. Trauma is mentioned as one of the most common medical issues in zoos (WYSS and WENKER, 2014). Endoparasites and ectoparasites are also common findings. Infectious diseases reported in flamingos include various viral, bacterial, and fungal pathogens, such as aspergillosis and poxvirus (HUMPHREYS, 1975; TERASAKI et al., 2010). Several diseases are based on nutritional deficiencies, including metabolic bone disease or capture myopathy/vitamin E deficiency (YOUNG, 1967; HUMPHREYS, 1975; FOWLER and CUBAS, 2001). Neoplasia has also been reported (VAN WETTERE et al., 2010). Acute death, most likely related to cardiac failure, can also occur when flamingos are stressed, and has sometimes been linked to atherosclerosis (HUMPHREYS, 1975; WYSS and WENKER, 2014).

NORTON (2005) mentions visceral gout as a pathological finding, but argues that it could possibly be a consequence of dehydration. According to ZSCHIESCHE and JAKOB (1989), *Phoenicopteriformes* show a particularly high incidence of amyloidosis. Haemosiderosis in flamingos is mentioned only as an anecdotal finding, most likely linked to excess dietary iron or vitamin deficiency (DIERENFELD et al., 2005). WADSWORTH et al. (1983) detected haemosiderosis in flamingos and associated it to the length they had spent in captivity. Neither LOWENSTINE and MUNSON (1999) nor KLASING et al. (2012) list flamingos as a susceptible species for haemosiderosis.

In this study, we evaluated necropsy reports for two flamingo species kept at the same facility. The greater flamingo (*Phoenicopterus roseus*) is native to various parts of Africa, including South Africa, also southern Europe, the Middle East, South and South West Asia (BIRDLIFE, 2014). In contrast, the

habitat of the Caribbean flamingo (*Phoenicopterus ruber*) is mainly found in vicinity of the Caribbean Sea (BIRDLIFE, 2014). The major aim of this study was to test whether differences in the health status and mortality between the two species occurred. Additionally, a similar set of necropsy information was available from a zoological garden of the temperate zone (WYSS and WENKER, 2014).

Material and methods

The two flamingo groups at the National Zoological Gardens Pretoria are housed in two neighbouring enclosures separated by a visitor walkway. Both enclosures measure app. 80 x 45 m, with one side of each enclosure lined by a waterway and a central pool of app. 20 m diameter. Water features have a concrete substrate; the remainder of the enclosure has a grass cover, apart from a clay breeding area of app. 3 m diameter in both enclosures. There were no differences in husbandry between the species. Necropsy reports of greater flamingos and Caribbean flamingos, which died at the National Zoological Garden of South Africa between 1991 and 2013, were evaluated. Necropsies had been performed according to standard protocol. For the greater flamingo there were 91 necropsy reports, including 33 male, 29 female and 29 of unknown gender, with 15 neonates (< 1 month old), 39 juveniles (< 1 year old) and 37 adults. For the Caribbean flamingo there were 121 reports, including in 48 males, 45 females and 28 of unknown gender, with 15 neonates, 30 juveniles and 76 adults.

We used the stocklist, in which all individuals of the greater and the Caribbean flamingo housed in the zoo during that period of time were registered, and also every death, birth, new arrival or departure was listed, to establish population size per year, and also calculated the yearly mortality as the number of animals that died in a year divided by the number of animals ever alive in that year. Relationships between annual population size and annual mortalities were tested by correlation analysis. Differences in the occurrence of specific diseases between certain animal groups were tested by chi-square tests. Parametric or nonparametric tests were used depending on whether data were normally distributed. Statistical analyses were performed in SPSS 21.0 (SPSS Inc., Chicago, IL), with the significance level set to 0.05 (results of up to 0.10 considered as trends).

For comparison, an unpublished evaluation of necropsy reports of greater flamingos from the Zoological Garden of Basle, Switzerland, following the same classification of health problems, is also displayed.

Results and discussion

The distribution of the causes of death at the National Zoological Gardens Pretoria was very similar between both species (figure 1a, b). The most common cause was trauma, followed by infections. Amyloidosis, gout, haemosiderosis, metabolic bone disease and hypercalcaemia were categorised as metabolic diseases and were the third most common cause of death in the Caribbean flamingo. Myopathy, septicaemia, gastrointestinal issues, starvation and heart failure are also noteworthy causes. Drowning, bone deformity, genital tract problems and neoplasia only occurred in one or two cases and therefore were pooled in one group named "other". Considering the three major categories of trauma, infectious diseases and all other deaths, there was no significant difference between the species ($\chi^2 = 2.54$, $P = 0.281$). Comparing the same three categories within greater flamingos between Pretoria and Basle, the difference tended towards significance ($\chi^2 = 5.58$, $P = 0.061$), with more trauma and less infection at Basle (figure 1c). The causes of death and their distribution among individuals reflect what is reported in literature, which confirms that trauma is one of the most frequent causes of death, followed by infections (WYSS and WENKER, 2014). The difference between the two greater flamingo groups could lie in the fact that at the temperate zone institution, animals have to be trans-

ferred to, and kept in, a winter house of limited space (WYSS et al., 2013), which might predispose more for traumatic injuries.

When looking at haemosiderosis, amyloidosis, gout and enteritis, including reports in which one of these findings is mentioned as a health issue, but not necessarily cause of death, the Caribbean flamingo has an occurrence of at least 6 % for each of them (figure 2). The differences between the species were significant for haemosiderosis ($\chi^2 = 3.88$, $P = 0.049$), and tended towards significance for amyloidosis ($\chi^2 = 2.76$, $P = 0.097$), and were not significant for gout ($\chi^2 = 0.64$, $P = 0.423$) and enteritis ($\chi^2 = 1.90$, $P = 0.168$). None of these diseases could be significantly linked to another condition, such as poor body condition, rickets or each other. The high prevalence of amyloidosis and gout was not surprising as both are known to occur frequently in flamingos (NORTON, 2005). Avian amyloid appears to be mainly of the AA-type, which suggests a disease or stress relation (TANAKA et al., 2008). The latter theory was supported by COWAN (1968) who linked amyloidosis to birds more susceptible to stress. It is indisputable however, that the main predisposition can be any chronic inflammation, such as mycobacteriosis for example (COWAN, 1968; LANDMAN et al., 1998). TANAKA et al. (2008) noticed a correlation between pododermatitis, an inflammatory condition, and the occurrence of amyloidosis in mute swans. Since pododermatitis has a very high prevalence in flamingos (NIELSEN et al., 2010; WYSS et al., 2013) this could explain the amyloidosis. In the necropsy reports of this study, foot lesions had not been described in particular, so that it can only be concluded that such lesions probably were not of a magnitude that regularly caught attention. As foot lesions in flamingos depend on the substrate they are kept on (WYSS et al., 2014), the grass enclosures at the facility investigated here might have contributed to a low occurrence and severity; however, NIELSEN et al. (2012) found that grass can also have a negative effect on flamingo foot health. In the literature, lymphoplasmacytic enteritis in flamingos is not mentioned. Haemosiderosis was noted in 10 % of all pathology reports of Caribbean flamingos; in literature, it is mentioned as an anecdotal finding (DIERENFELD et al., 2005), or in an individual case report (BRAYTON, 1992), with only one study reporting a similarly high occurrence as in our study (WADSWORTH et al., 1983). One flamingo in Pretoria even appeared to have died of liver failure due to massive haemosiderosis. In general, haemosiderosis it is thought to be related to an inability to cope with high levels of iron in the diet (KLASING et al., 2012). However, no cause of massive iron intake was found in that flamingo. Other causes for increased iron storage in the liver may include acute phase responses to infection, trauma, or neoplasia (KLASING et al., 2012).

It appeared that in the Caribbean flamingo, females had higher prevalence of several diseases than males (figure 3); while this difference was not significant for amyloidosis ($\chi^2 = 2.07$, $P = 0.149$), gout ($\chi^2 = 0.55$, $P = 0.460$) or enteritis ($\chi^2 = 0.45$, $P = 0.501$), it was significant for haemosiderosis ($\chi^2 = 9.63$, $P = 0.002$). In the species investigated here, male and female contribute equally to breeding so breeding activity per se cannot explain the difference (PERRY, 2005), but a negative calorie balance in females during egg production could be a part of the phenomenon. PUERTA et al. (1989) found that females of *P. ruber chilensis* have a higher erythrocyte number, which in itself should not be linked to haemosiderosis. Anyhow, HAWKEY et al. (1984) and PEINADO et al. (1992) found no significant haematological sex differences in Caribbean flamingos. Nevertheless, the study of WADSWORTH et al. (1983) also suggests, without giving the complete data, that female flamingos are more often affected by haemosiderosis than males.

The average population size over the years was higher in the greater flamingo (190 ± 20) than in the Caribbean flamingo (154 ± 30); this difference was significant (t-test, $P = 0 < 0.001$). Compared over the years, mortality was lower in the greater flamingo (median 1.0 %, range 0 - 9.0 %) than in the Caribbean flamingo (4.0, 0 - 7.0 %, figure 4); this difference was also significant (U-test, $P = 0.005$). While there was no correlation between population size and mortality in the Caribbean flamingo ($\xi = 0.02$, $P = 0.947$, figure 4), there was a significant correlation in the greater flamingo ($\xi = 0.86$, $P < 0.001$, figure 4). When excluding the four years with the highest mortality in the greater flamingo, a significant correlation was found ($\xi = 0.74$, $P < 0.001$), indicating that the effect was not only due to

these four 'outlier' years. When these four years were excluded, the difference in the yearly mortality between the species became even more evident (mortality greater flamingo 0.6 ± 0.7 %, Caribbean flamingo 3.3 ± 1.9 %, t-test, $P < 0.001$). To our knowledge, this is the first report of a species difference in mortality in flamingos, and also the first report of an apparent density-dependent effect on mortality in captivity in this group. As the enclosures of the two species are located directly next to each other, and husbandry and feeding regimes are identical, other reasons than a different predisposition to health problems appear unlikely. It is tempting to assume that this might be due to the difference in the natural habitat, given that the greater flamingo is a native species in South Africa. Therefore, the greater flamingo might be more adapted to the environmental conditions at this zoological institution, whereas the Caribbean flamingo, indigenous in the Caribbean, is not. In Pretoria for example, maximum temperature ranges between 19 and 28 °C, with an average of 21.9°C, and the relative humidity ranges between 48 and 65 %. Cuba, habitat of the Caribbean flamingo, has an average temperature of 30.4°C and a relative humidity between 70 and 80 % (INFORMATION 2014; KLIMATABELLE 2014). This leads to the assumption that habitat requirements differ among flamingo species. Interestingly, this does not translate into evident differences in the causes of death (figure 1), just into a higher general mortality. In other species, such location-related problems are well-known. For example, breeding colonies of Humboldt penguins (*Spheniscus humboldti*) in zoos in the UK have approximately half the chick output of free-living, undisturbed wild colonies, and in these and other penguin species, aspergillosis, an opportunistic fungal infection, is more prevalent in captive than in wild populations (BLAY and CÔTÉ, 2001; ELLENBERG et al., 2006; BUNTING et al., 2009). Density-dependent effects on morbidity and mortality are well known in free-ranging populations (SINCLAIR, 2003) and production animals (BURGER and KAISER, 1996), but have received comparatively little attention in the literature on zoo animal management (MÜLLER et al., 2013). In the absence of other evident patterns in the diseases of the greater flamingo in this study, the relevance of keeping captive populations below a certain threshold (that may have to be determined empirically) appears important when trying to reduce mortalities. Regularly comparing stock numbers and mortality records thus is an important aspect of the management of animals kept in herds or flocks (MÜLLER et al., 2013).

Conclusion

It was confirmed that trauma is the main cause of death in captive flamingos, and management efforts should increase to reduce trauma-related mortality. Regarding haemosiderosis, the high incidence in Caribbean flamingos and the female predisposition cannot be explained by high dietary iron intake. The species related difference in mortality could be explained by dissimilar husbandry requirements, which so far are not mentioned in husbandry guidelines. Therefore, species-specific guidelines, as suggested by KING and BRAČK} (2014), appear warranted. Additionally, the density-dependent effects such as documented here should be taken into account for future husbandry recommendations, especially in connection with current attempts to increase flamingo flock sizes in captivity (KING and BRAČK} , 2014).

Acknowledgements

This evaluation was part the Zoo Research Camp (ZRC) 2013 organised and funded by the National Zoological Gardens of Pretoria and the Vetsuisse Faculty of the University of Zurich. We also thank our sponsors for additional support: Alumni Vetsuisse Zürich, Zürcher Universitätsverein, Royal Canin, Schweizerische Vereinigung für Kleintiere, Provvet AG, Vereinigung Schweizerischer Futtermittel-

fabrikanten, Eisenhut and Maestrani, and Clifford Nxomani, Adrian Tordiffe, Mark Howitt, Sarah Chabangu for support on site.

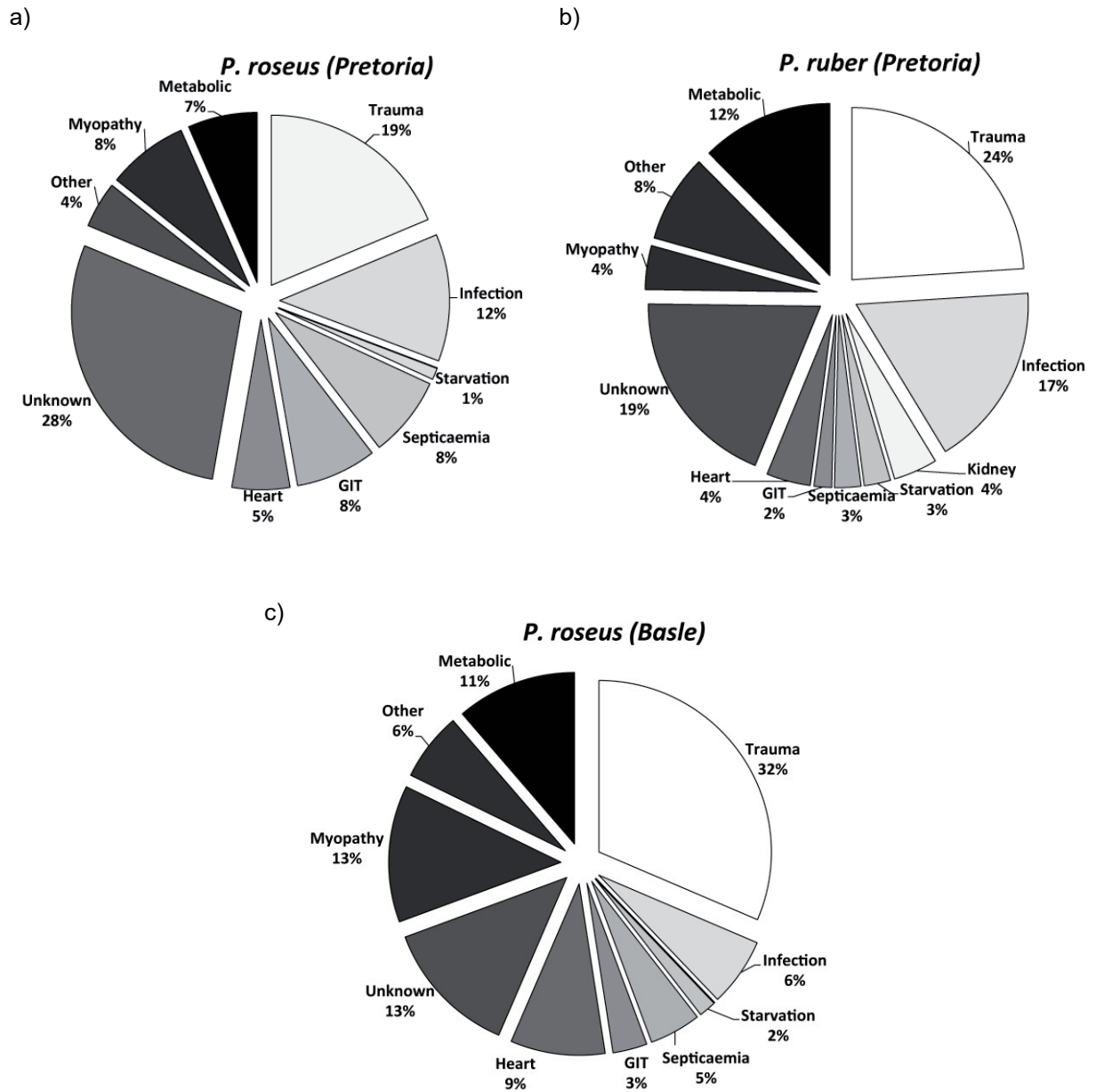


Fig. 1: Causes of death in a) *P. roseus* and b) *P. ruber* at the National Zoological Gardens Pretoria, South Africa and c) *P. roseus* at the Zoological Garden of Basle, Switzerland.

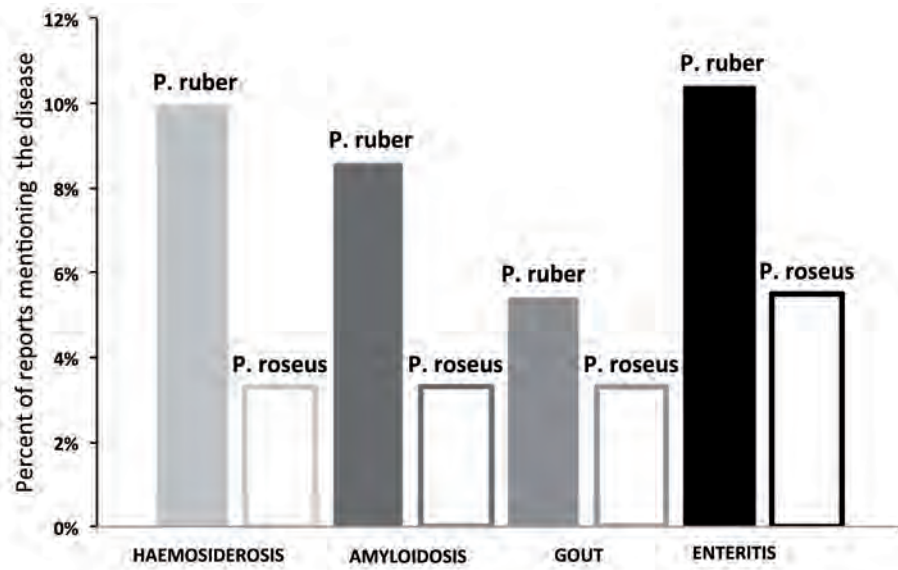


Fig. 2: Percent of reports in which haemosiderosis, amyloidosis, gout and enteritis was mentioned for *P. roseus* and *P. ruber* (of the total number of reports evaluated).

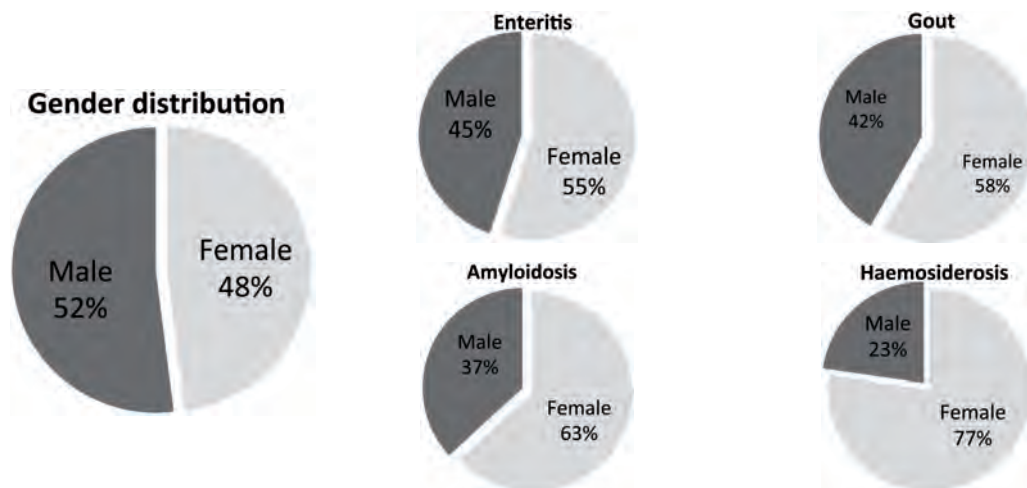


Fig. 3: Comparison of the proportion of males and females in the whole population and among the cases of enteritis ($n = 20$), gout ($n = 12$), amyloidosis ($n = 19$) and haemosiderosis ($n = 22$) in *P. ruber*.

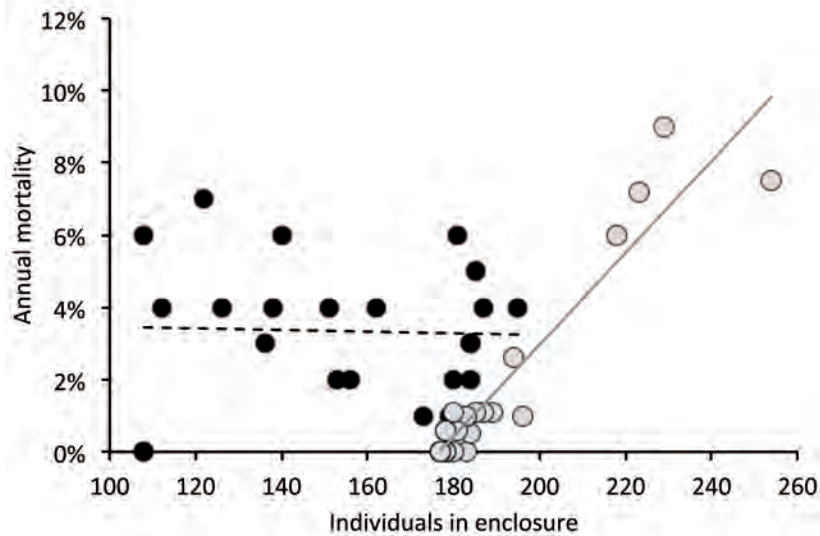


Fig. 4: Mortality of *P. roseus* (grey circles) and *P. ruber* (black circles) in relation to the total amount of flamingos in the enclosure.

References

- BIRDLIFE (2014): IUCN Red List for birds. Downloaded from <http://www.birdlife.org> on 19/01/2014.
- BLAY N, CÔTÉ IM (2001): Optimal conditions for breeding of captive humboldt penguins (*Spheniscus humboldti*): A survey of British zoos. *Zoo Biol.* **20**, 545 - 555.
- BRAYTON C (1992): Amyloidosis, hemochromatosis, and atherosclerosis in a Roseate flamingo (*Phoenicopterus ruber*). *Ann. New York Acad. Sci.* **653**, 184 - 190.
- BUNTING EM, MADI NA, COX S, MARTIN-JIMENEZ T, FOX H, KOLLIAS GV (2009): Evaluation of oral itraconazole administration in captive Humboldt penguins (*Spheniscus humboldti*). *J. Zoo Wildl. Med.* **40**, 508 - 518.
- BURGER H, KAISER HE (1996): Crowding. *In Vivo* **10**, 249 - 254.
- COWAN DF (1968): Avian amyloidosis: II. Incidence and contributing factors in the family Anatidae. *Pathol. Vet. Online* **5**, 59 - 66.
- DIERENFELD ES, SHEPPARD CD, MCDONALD DL (2005): Nutrition. In: Brown C, King C (Eds.): *Flamingo Husbandry Guidelines. A Joint Effort of the AZA and EAZA in Cooperation with WWT.* Dallas Zoo, Dallas, TX, 109 - 129.
- ELLENBERG U, MATTERN T, SEDDON PJ, JORQUERA GL (2006): Physiological and reproductive consequences of human disturbance in Humboldt penguins: The need for species-specific visitor management. *Biol. Conserv.* **133**, 95 - 106.
- FOWLER ME, CUBAS ZS (2001): *Phoenicopteriformes*. In: *Biology, Medicine and Surgery of South American Wild Animals.* Iowa State Press, 95 - 102.
- HAWKEY C, HART MG, SAMOUR HJ, KNIGHT JA, HUTTON RE (1984): Haematological findings in healthy and sick captive rosy flamingos (*Phoenicopterus ruber ruber*). *Avian Pathol.* **13**, 163 - 172.
- HUMPHREYS PN (1975): Pathological conditions. In: Kear J, Duplaix-Hall N (Eds.): *Flamingos. T and AD Poysner, Berkhamsted, Hertfordshire, England,* 199 - 202.
- INFORMATION WAC (2014): <http://www.weather-and-climate.com> accessed on 19/01/2014.

-
- KING CE, BRAČKO A (2014): Nineteen years of management for *Phoenicopteriformes* in European Association of Zoos and Aquaria institutions: the Fabulous Flamingo Surveys and strategies to increase reproduction in captivity. *Int. Zoo Yb.* **48** (in press).
- KLASING KC, DIERENFELD ES, KOUTSOS EA (2012): Avian iron storage disease: variations on a common theme? *J. Zoo Wildl. Med.* **43**, S27 - S34.
- KLIMATABELLE (2014): <http://www.klimatabelle.info> accessed on 19/01/2014
- LANDMAN WJM, GRUYS E, GIELKENS ALJ (1998): Avian amyloidosis. *Avian Pathol.* **27**, 437 - 449.
- LOWENSTINE LJ, MUNSON L (1999): Iron overload in the animal kingdom. In: Fowler ME, Miller RE (Eds.): *Zoo and Wild Animal Medicine. Current Therapy 4*. W.B. Saunders, Philadelphia, 260 - 268.
- MÜLLER DWH, HAMMER S, HAMMER C, HATT J-M, CLAUSS M (2013): A conceptual approach to density-dependent management of zoo animals kept in herds. *Int. Zoo Yb.* **47**, 208 - 218.
- NIELSEN AM, NIELSEN SS, KING CE, BERTELSEN MF (2010): Classification and prevalence of foot lesions in captive flamingos (*Phoenicopteridae*). *J. Zoo Wildl. Med.* **41**, 44 - 49.
- NIELSEN AMV, NIELSEN SS, KING CE, BERTELSEN MF (2012): Risk factors for foot lesions in captive flamingos (*Phoenicopteridae*). *J. Zoo Wildl. Med.* **43**, 744 - 749.
- NORTON TM (2005): *Phoenicopteriformes (Flamingos)*. In: Fowler ME, Miller RE (Eds.): *Zoo and Wild Animal Medicine*. 5th ed. Saunders, St. Louis, 129 - 135.
- PEINADO VI, POLO FJ, VISCOR G, PALOMEQUE J (1992): Haematology and blood chemistry values for several flamingo species. *Avian Pathol.* **21**, 55 - 64.
- PERRY J (2005): Reproduction. In: Brown C, King C (Eds.): *Flamingo Husbandry Guidelines. A Joint Effort of the AZA and EAZA in Cooperation with WWT*. Dallas Zoo, Dallas, TX, 68 - 108.
- PUERTA ML, HUECAS V, DEL CAMPO AL (1989): Hematology and blood chemistry of the Chilean flamingo. *Comp. Biochem. Physiol. A* **94**, 623 - 625.
- SINCLAIR ARE (2003): Mammal population regulation, keystone processes and ecosystem dynamics. *Phil. Trans.R. Soc.Lond. B* **358**, 1729 - 1740.
- TANAKA S, DAN C, KAWANO H, OMOTO M, ISHIHARA T (2008): Pathological study on amyloidosis in *Cygnus olor* (Mute swan) and other waterfowl. *Med. Mol. Morphol.* **41**, 99 - 108.
- TERASAKI T, KANEKO M, MASE M (2010): Avian poxvirus infection in flamingos (*Phoenicopterus roseus*) in a zoo in Japan. *Avian Dis.* **54**, 955 - 957.
- VAN WETTERE AJ, DEGERNES LA, BARNES HJ (2010): Combined hepatocellular-cholangiocarcinoma in a lesser flamingo (*Phoenicopterus minor*). *Avian Pathol.* **39**, 275 - 278.
- WADSWORTH PF, JONES DM, PUGSLEY SL (1983): Hepatic haemosiderosis in birds at the Zoological Society of London. *Avian Pathol.* **12**, 321 - 330.
- WYSS F, WENKER C, HOBY S, GARDELLI B, STUDER-THIERSCH A, VON HOUWALD F, SCHUMACHER V, CLAUSS M, DOHERR MG, HÄFELI W, FURRER S, BÉCHET A, ROBERT N (2013): Factors influencing the onset and progression of pododermatitis in captive flamingos (*Phoenicopteridae*). *Schw. Arch. Tierheilkd.* **155**, 497 - 503.
- WYSS F, WENKER C (2014): *Phoenicopteriformes*. In: Miller RE, Fowler ME (Eds.): *Zoo and Wild Animal Medicine: Current Therapy*, ed 8. Saunders elsevier, 106 - 113.
- WYSS F, WENKER C, HOBY S, VON HOUWALD F, SCHUMACHER V, DOHERR MG, ROBERT N (2014): The effect of fine granular sand on pododermatitis of captive greater flamingos (*Phoenicopterus roseus*). *Anim. Welf.* **23**, 57 - 61.
- YOUNG E (1967): Leg paralysis in the Greater flamingo and Lesser flamingo *Phoenicopterus ruber roseus* and *Phoeniconaias minor* following capture and transportation. *Int. Zoo Yb.* **7**, 226 - 227.
- ZSCHIESCHE W, JAKOB W (1989): Pathology of animal amyloidoses. *Pharmacol. Therap.* **41**, 49 - 83.

ON THE EUTHANASIA OF SURPLUS ANIMALS, AND THE ROLE OF ZOOS IN ALLEVIATING BIOLOGICAL ILLITERACY - LESSONS LEARNED...

BERTELSEN MF

Copenhagen Zoo, Center for Zoo and Wild Animal Health, Roskildevej 38, 2000 Frederiksberg, DENMARK; mfb@zoo.dk

The challenge

In the developed countries, the population is getting farther and farther away from farming and hunting - and what one might call a natural and balanced view on life and death. We increasingly no longer see animals as creatures that we take good care of... before we kill them and eat them, but as fellow citizens, and meat is perceived as something that we obtain from the supermarket. Schools in many countries are steering away from dissections, visits to abattoirs etc. and the media largely depicts farmers as bad guys and typically shows only negative stories of meat production. The result is an increasing level of "biological illiteracy" where the general public has no idea, and in reality does not want to realise that the meat that most of us eat comes from animals.

Now, who has the responsibility of educating them? Schools? Veterinarians? Museums? Zoos?

This lack of basic biological knowledge provides a challenge for zoos that a) have to feed their carnivorous animals, b) have to manage populations rationally. In this context, a zoo essentially has three choices:

1. Pretend that animals are only born, only euthanise geriatric or very sick animals (and preferably even then do not tell anybody), and feed carnivores minced meat off exhibit joining everybody else in the belief that it really was not animal derived.
2. Manage populations rationally including culling of certain individuals, feeding carnivores real meat etc. but not publicising details on meat supply, surplus animals, population control etc., or
3. Take on the responsibility of showing people how things actually are: let the public see lions eating a recognisable piece of horse, and ultimately also stand by the fact that -as an example- while 100 % of female impalas can find a new home, perhaps only 5 % of the males can.

Most US zoos live by option 1, most European zoos by option 2 (although an increasing number of countries are leaning toward 1), and a few zoos, primarily in Scandinavia support option 3. It can be very easy -and perhaps even temporarily convenient- to go from option 3 to 2 or from 2 to 1 on this list, but moving the other way will take years...

The case; "Marius-gate"

On February 9th 2014, Copenhagen Zoo culled a healthy 2 year old male giraffe. The animal was being pushed out of the group by the dominant male, and the individual was considered surplus by the EEP meaning that he would take up valuable space for genetically more important animals if relocated. The animal was killed by a rifle shot to the brain (*out of public view*) and subsequently moved to the zoo's kitchen area where a *post mortem* examination was conducted and the carcass was cut into portions appropriate for feeding. Interested visitors were invited to see the *post mortem* exam, but *nobody was accidentally exposed* as the PM took place in a non-public area. The remains of the giraffe were used in a range of research projects and for feeding of zoo carnivores, the latter in public view.

The zoo has practiced this policy for decades, and never encountered mentionable problems with it. This time however, the fate of the giraffe was picked up by a tabloid newspaper prior to the euthanasia, and the big brown eyes of the giraffe combined with an online petition to “save” the animal initiated a public outcry via the social media and sparked a media storm. Within the next five days the zoo received more than 30,000 emails, thousands of phone calls, Facebook postings and Tweets. Media from more than 30 countries picked up the story including the BBC and CNN.

The people involved -including staff simply answering the phones- were called everything from murderers to psychopaths, were threatened with all sorts of evil, and were accused of having caused severe damage to the zoo community, and even to have destroyed zoos’ role in conservation.

After the initial uproar, where media coverage was completely one-sided condemning the Zoo for killing a healthy animal (!) followed a period of more nuanced reporting, trying to find out what had actually happened and the rationale behind. Throughout this period the zoo remained unified and all statements and correspondence were calm, sober and scientific. Complete honesty and transparency was followed throughout the incident, and gradually -at least in Denmark- the Zoo has actually come out on top, being credited for its honesty and seriousness. In fact polls about a week after the episode showed > 90 % of the population in favour of the decision. Gradually -but with some delay- thousands of emails actually supporting the Zoo started coming in from private persons, organisations, conservation bodies etc., and towards the end of the “incidence”, the supporting messages were a majority.

A case for culling

Culling of surplus animals is used all over the world in order to adapt the populations of animals to the available space. Due to the unbalance in nature created by human activities this is essential in order to avoid that some animals destroy their own and other animals’ habitat and thus decrease the overall fitness of the populations. The zoo situation is very similar - a certain amount of space is available and the populations must be adapted to fit into this space without crowding and consequently decreased welfare, at the same time trying to keep a natural wide-based population pyramid.

The arguments for culling in zoos are beyond the scope of this abstract, but briefly include natural breeding behaviour providing enrichment, some possibility of selection, accommodation for situations where birth sex ratios differ from adult herd situations, a means of maintaining viable population demographics etc. The alternatives are largely problematic: separation of genders, contraception, sending animals to sub-standard facilities etc.

Any zoo should strive to provide excellent conditions for their animals. While animals have no expectations of how long they will or can live, they certainly sense the quality of their life. All zoo animals should have a good life, whether it be long or short, and in my opinion, zoos should prioritise *quality* of life over *quantity* of life.

While several zoo directors publically declared that a situation similar to the one described above would never have occurred at their facility, who can identify a single zoo in the world that has never culled a healthy animal for any reason, be it surplus, meat supply or pest control?!

A case for “public dissections”

Two basic parts of human nature are curiosity and skepticism of the unknown. Zoos can employ the one to fight the other. For decades, Copenhagen Zoo has conducted public “dissections” of chickens, goats and other animals to demonstrate anatomy and physiology. We have also had a butcher demonstrate where meat comes from by turning half a pig into delicious cuts in front of zoo visitors (and the pig enclosure) every day of the peak season. More recently, we have made similar demon-

strations using culled zoo animals including zebras, ostriches and reindeer, always with respect for the animals and the visitors, and with narration and explanation of everything that happens. There is massive interest in these demonstrations, and visitors –particularly children– show great participation and ask all the right questions.

It is worth mentioning that Danish schools and museums are doing the same thing, and that many forests have similar sessions in the hunting season, demonstrating how a freshly shot deer is prepared.

Zoos have taken on the mission of showing animals to the public, thereby providing understanding and instilling care. By expanding the concept to also include the fascination of anatomy and physiology, and even pathology, genetics and population dynamics, we can also expand the understanding!

Take home messages

Do

- stick to honesty and professionalism.
- ensure that the entire zoo staff understands and agrees with company policies.
- believe that biologists and veterinarians are best equipped to make decisions for zoo animals – not the public opinion.
- believe that zoos can change the public opinion (not overnight, though).

Don't

- give animals human names.
- refer to sub-adult or young adult animals as “babies”.
- announce culling ahead of time, but do stand by decisions made.
- fear that you would unleash the same reaction every time.

VETERINARY MANAGEMENT OF TWO PRIMIPAROUS PREGNANCIES, BIRTH AND POST PARTUM IN BOTTLENOSE DOLPHINS (*TURSIOPS TRUNCATUS*) WITH THE SAME PREDICTION DATES

FIORUCCI L¹, GRANDE F¹, PILENGA C¹, HENRIQUES A¹, MANFRINI V¹, FLANAGAN C²

¹Zoomarine Italia, Via Casablanca n.61, 00040 Pomezia, (Rome), ITALY; veterinari@zoomarine.it

²Mundo Aquatico S.A. - Zoomarine - Est. Nacional 125, Cortelhas, Guia, 8201-864 Albufeira, PORTUGAL

In September 2012, Zoomarine Rome experienced two births of bottlenose dolphins (*Tursiops truncatus*) for the first time. In preparation for the births the veterinary and training protocols of Zoomarine Portugal were adapted and implemented. The protocols included 24 hours observations from a month prior to births to one month *post partum*. Rectal temperature and intermammary glands distance were measured twice a day since the eleventh month of gestation. Daily ultrasonographic examination and weekly blood sampling of the pregnant female were performed during the last two weeks prior to the expected day of delivery. Check-up comprehensive of clinical examination, biometric measurements (length and weight), faecal and blowhole microbiology analysis, and a complete blood profile of the calf were planned every thirty day after birth. The design and construction of a hydraulic medical platform was fundamental to quickly intervene in case of necessity. The two primiparous females, both ten years of age, gave birth within the prediction dates and eleven days apart, with two very different outcomes. The first calf presented a cephalic position at birth and has developed normally without medical intervention besides regular weight control and blood and faecal sampling. The second calf had an uneventful birth but died suddenly nine days later with acute respiratory distress which did not respond to emergency medical treatment. In both cases, suckling and breathing trends were normal. Peracute septicemia by *Pseudomonas aeruginosa*, *Escherichia coli*, and *Pseudomonas* spp. was identified at the necropsy as cause of death. Water analysis at that moment presented 1 CFU/100 ml of *P. aeruginosa*. Microbiological and nutritional parameters of the milk did not show abnormalities. With this general overview we intend to share information regarding the issues solved and the experiences learned from these two births, with the goal of improving protocols to implement the percentage of neonatal survivability.

IMPLANTABLE LOOP RECORDERS FOR THE DIAGNOSIS OF CARDIAC DISEASE IN CHIMPANZEES

FELTRER Y¹, DODDS J¹, MASTERS N¹, NIBLETT R², SOMAUROO J³, MODI S⁴, SHAVE R⁵

¹ZSL, Zoological Society of London, International Primate Heart Project, Veterinary Dept., Regent's Park, London NW1 4RY, UK; yedra.feltrere@zsl.org

²International Primate Heart Project, Medtronic Limited, Croxley Green Business Park, Hatters Lane, Watford, Hertfordshire WD18 8WW, UK

³International Primate Heart Project, Countess of Chester NHS Trust, Liverpool Road, Chester CH2 1UL, UK

⁴International Primate Heart Project, Heart and Chest Hospital NHS Foundation Trust, Thomas Drive, Liverpool L14 3PE, UK

⁵Cardiff Metropolitan University, Dept. of Exercise Physiology, International Primate Heart Project, Cardiff CF23 6XD, UK

Cardiovascular disease is an important cause of morbidity and mortality in captive chimpanzees. Ventricular arrhythmias are associated with an increased risk of sudden death. At ZSL Whipsnade Zoo (WZ) two closely related young male chimpanzees (*Pan troglodytes*) have died, likely as a result of arrhythmogenic right ventricular cardiomyopathy (ARVC), a condition recognised in humans and domestic animals to have a genetic component (TONG et al., 2013). Diagnosis of cardiac arrhythmias in chimpanzees is challenging and information is usually gathered under general anaesthesia with short-duration electrocardiograms (ECG). As part of the International Primate Heart Project, implantable loop recorders (a semi-permanent ECG recording device) have been surgically implanted in the backs of two related male chimpanzees at WZ. These have been implanted in order to record ECGs during normal activity and to aid diagnosis. The two chimpanzees are closely related to the deceased animals and based on human genetic analysis are positive for ARVC, although the sensitivity and specificity of gene testing for ARVC is unknown in chimpanzees. The chimpanzees have been trained to present their backs so that information may be downloaded from the devices. These data are being analysed for the overall arrhythmic burden. Knowledge derived from these data will provide a better understanding of heart function and disease in great apes. The preliminary results for these animals will be discussed.

References

TONG LJ, FLACH EJ, SHEPPARD MN, POCKNELL A, BANERJEE AA, BOSWOOD A, BOUTS T, ROUTH A, FELTRER Y (2013): Fatal arrhythmogenic right ventricular cardiomyopathy in 2 related subadult chimpanzee (*Pan troglodytes*). *Vet. Pathol.*, <http://vet.sagepub.com/>. Published online 29th of August 2013.

BIOMECHANICS OF THE NORMAL GAIT IN ASIAN ELEPHANTS (*ELEPHAS MAXIMUS*)

STEINMETZ HW

Gebr. Knie, Schweizer National-Circus AG, Knies Kinderzoo, Oberseestrasse, 8640 Rapperswil, SWITZERLAND; hp.steinmetz@knieskinderzoo.ch

Degenerative joint disease is a major health problem in captive Asian elephants (*Elephas maximus*). Besides overweight, genetic predisposition and age, lack of exercise was recognised an important factor causing chronic degenerative joint disease in many species, as well the Asian elephant.

The current study measured the biomechanics and forces of the normal gait of trained and less trained Asian elephants (n = 10) with portable force plates and a specialised capturing and analysing software. Results have shown that during the normal gait large forces act on the musculoskeletal system of Asian elephants, especially of the joints of the distal extremities. Differences in forces acting on distal extremities in relation to body weight were seen between trained and less trained elephants. Besides a healthy body weight, intact foot confirmation, good foot health and well-trained muscles are required to cushioning these forces and reduce the biomechanical stress on the extremities articulations.

Thus, captive management of Asian elephants should promote regular training programmes, stimulating elephants to move and exercise every day. Important is to respect the ability of an individual animal and train all musculoskeletal regions for various topographic environments and situations. All animals will benefit not only in regards of prevention of degenerative joint disease, but the better overall fitness could also assist e.g. in a better parturition.

RETROSPECTIVE PATHOLOGY REVIEW OF RED PANDAS (*AILURUS FULGENS*) CAPTIVELY-HOUSED IN NORTH AMERICA

DELASKI K¹, RAMSAY E², GAMBLE K¹

¹Lincoln Park Zoo, 2001 N. Clark St., Chicago, IL 60614, USA; kdelaski@lpzoo.org

²University of Tennessee-Knoxville and Knoxville Zoo, College of Veterinary Medicine, 2407 River Dr., Knoxville, TN 37996, USA

Red pandas are managed as an AZA Species Survival Plan (SSP) Yellow Program in North America, and as a European Endangered Species Programme (EEP) in Europe. Though very thorough pathology reviews have been conducted for the European studbook, the North American population had not been analysed similarly since 1982. Complete gross and histopathology reports were requested from institutions housing red pandas from 1992 through 2012 to initiate this process. Of the 530 red pandas that died during this interval, 96 % were accounted, and 81 % of these animals had complete necropsy reports available. Reports were classified by age and reviewed for primary etiology associated with mortality. Similar to the European population, a substantial portion of the deaths (40 %) were considered neonatal (< 30 days). However, in contrast to cases in Europe, no cases of *Angiostrongylus* infections were noted. In neonatal and juvenile (30 - 365 days) red pandas, aspiration pneumonia was the most common primary finding, In adults (1 - 10 years), gastrointestinal disease, including gastritis and enteritis, was the most common primary finding. The primary finding in geriatric (> 10 years) red pandas was degenerative cardiac disease.

ISIS AND ZIMS: WHAT CAN WE LEARN FROM GLOBALLY SHARED DATA?

TEARE JA

International Species Information System, 7900 International Drive, Suite 1040, Bloomington, MN 55425, USA; jatearedvm@gmail.com

Summary

The International Species Information System (ISIS) collects, organises and shares information about captive wildlife between more than 800 member institutions around the world. The newest ISIS software, the Zoological Information Management System (ZIMS), is a web-based, real-time data collection system that captures both animal husbandry and medical information. Improving captive wildlife care and management through international collaboration is within the ISIS mission; data collection into a single system from a global network of members is a means to reach that objective. The ability to aggregate, collate and analyse information from multiple sources can provide an insight and understanding that often cannot be obtained using information from a single source. Two instances of analysis of shared records will illustrate the potential power and usefulness of this method.

Introduction

Private companies targeting you with specific advertisements based on your internet usage and stories about government analysis of electronic records involving private citizens are daily realities in the 21st century. However, data mining can also have positive effects. Analysis of large sets of electronic prescription records has demonstrated the ability to identify negative drug interactions that are too rare to detect during routine clinical trials (TATONETTI et al., 2012). This analysis uses only anonymous prescription records, yet is still able to directly impact health care for individuals and to provide benefits for society as a whole.

Since 1974, the International Species Information System (ISIS) has been collecting, organising and sharing information on captive wildlife for member institutions. Five generations of software has culminated in ZIMS, a single, global, real-time, accurate Zoological Information Management System. The animal husbandry and management portion of the system has been running since 2012 and is currently being used worldwide by more than 650 member institutions. Physiological reference intervals for over 900 species were added in mid-2013 and the next improvement, the April 2014 release of ZIMS 2.0, added medical record capabilities to the system.

This collaboration by ISIS members has produced of a unique data resource. ISIS is committed to improvements in animal care through analysis of shared data and believes that the benefits of this shared data have not yet been fully exploited. Two projects, one based on husbandry data and one on medical data, will demonstrate the potential importance of data mining and analysis of information from ISIS records.

Methods and results

Animal husbandry records: Most zoo professionals are aware that reproductive success with flamingos is related to flock size. There have been a number of studies supporting this observation

(PICKERING et al., 1992; STEVENS and PICKETT, 1994). Smaller flocks can reproduce successfully, but a flock size over 20 seems to yield a reasonable chance of reproductive success, and most captive flocks are managed using this knowledge. However, this analysis was based on surveys from a limited number of institutions based in just a few geographic regions. Additional questions remain unanswered. Will the relationship between flock size and reproductive success remain true with a more global analysis? Is the optimum flock size really 20 birds or are bigger flocks preferable?

An analysis of 2013 records for Chilean flamingo (*Phoenicoptarus chilensis*) at 167 ISIS member institutions yielded the values shown in table 1. It confirms that a flock size below 20 is associated with few offspring. Flocks with over 20 birds are more likely to reproduce, although it also appears that there is a large (more than 200 %) jump in success rate when the flock size is over 30. Further increases in flock size, seems to offer little improvement in reproductive success. While this is an analysis of only a single year of ISIS records, it does provide an interesting case study of the animal management information that can be quickly extracted from globally shared records.

Tab. 1: Chilean Flamingo reproduction in 2013 at 167 ISIS institutions.

Flock Size	Flocks with Chicks
1 - 10	0.0 %
11 - 20	5.0 %
21 - 30	13.0 %
31 - 40	33.3 %
41 - 50	26.7 %
51 - 100	21.1 %
101 - 300	50.0 %

Medical records: Shared medical information can also significantly impact animal care. Diagnostic testing is only useful to the clinician when there is an “expected range” of results for comparison; in essence, knowing what might be an abnormal test result is dependent on knowing what is “normal”. Serum chemistry and haematology reference intervals for a large number of species was one of the earliest tangible products delivered by ISIS. The number and quality of these reference intervals has increased over time, and the most recent publication (TEARE, 2013) followed the American Society of Veterinary Clinical Pathologists (ASVCP) published guidelines (FRIEDRICHS et al., 2012).

Those ASVCP guidelines recommend that any reference interval be calculated from a minimum of 40 results from healthy individuals and a sample size of 120 is preferred. Accumulating 40 test results at a single institution can be difficult for many species. Even within human medicine, some healthy populations (e.g., pediatric patients) are sampled so infrequently, that reference intervals are calculated by combining results from multiple institutions (SCHNABL et al, 2008). ISIS also uses this multi-institutional approach and inspection of the underlying numbers for one species will illustrate why this is often the only viable technique for producing reference intervals in zoological medicine.

Tab. 2: Examples of haematology reference intervals for *Vulpes zerda* calculated by ISIS from data submitted by 48 member institutions using the MedARKS software.

Test Name	Units	Reference Interval	Mean	Median	Animals
White Blood Cell Count	*10 ⁹ cells/L	1.93 - 10.76	5.30	5.01	180
Red Blood Cell Count	*10 ¹² cells/L	5.76 - 11.03	8.31	8.31	150
Haemoglobin	g/L	106 - 201	152	151	160
Haematocrit	L/L	0.329 - 0.601	0.463	0.462	186
MCV	fL	45.1 - 66.3	55.0	54.7	148

Currently 99 ISIS members hold fennec fox (*Vulpes zerda*), with a median population of just two animals at each institution. Under these conditions, collecting and analysing 40 blood samples to obtain a valid reference interval becomes very difficult for any single institution. However, when just 48 of those institutions contributed blood test results from healthy animals to the ISIS data set, then 186 current and historical animals became available for analysis (each institution still reported results for

an average of less than four individuals). Calculations are complex, and include multiple algorithms to identify and reject outlier values, but reference intervals for this “combined” fox population still offer a level of confidence and reliability that is not available when dealing with smaller populations (table 2).

Discussion

Sharing captive wildlife information at a global level is not dependent on either an electronic format or a common format, but both factors make sharing more efficient and allow tools to be developed which can be easily applied to multiple species. The fennec fox reference intervals project could have been done with paper records and a spreadsheet programme, but the analysis of the next species would have taken the same amount of effort. Instead, the reference interval analysis tool developed by ISIS was applied to the over six million test results in the database, resulting in more than 900 sets of species-specific reference intervals; a completely unique and valuable resource that is only possible because ISIS member institutions shared their records in a common electronic format.

As clinicians we often find ourselves working on an unfamiliar species and wondering about appropriate anaesthesia protocols or the common medical issues diagnosed in that species. Even the simple question of whether a specific drug has been used in a particular species can often be difficult to ascertain with current resources. With ZIMS prescription records and the right analysis tool, it would be easy to determine how many times the drug had been used in the species, to calculate the average dosage prescribed and even determine the number of instances where adverse effects were reported. As the number of records in ZIMS grows, and as ISIS builds more analysis tools, it will become possible to answer additional important questions about captive wildlife. Proper analysis of ZIMS records will help to fill gaps in the existing knowledge and support evidence-based medical care decisions for captive wildlife.

A global collection of anaesthesia, prescription, biochemical test result and physiological measurement records is being assembled by ISIS member institutions. The current reference intervals based on existing records can be considered a “proof of concept” regarding the value of shared medical records for the global community of veterinarians working with captive wildlife. In the future, ISIS hopes to be able to offer additional services that would allow clinicians to quickly and easily obtain significant medical and physiological information about a wide variety of species under their care.

References

- FRIEDRICHS KR, HARR KE, FREEMAN KP, SZLADOVITS B, WALTON RM, BARNHART KF, BLANCO-CHAVEZ J (2012): *ASVCP reference interval guidelines: determination of de novo reference intervals in veterinary species and other related topics*. *Vet. Clin. Pathol.* **41**, 441 - 445.
- PICKERING S, CREIGHTON E, STEVENS-WOOD B (1992): *Flock size and breeding success in flamingos*. *Zoo Biol.* **11**, Issue 4, 229 - 234.
- SCHNABL K, CHAN MK, GONG Y, ADELI K (2008): *Closing the Gaps in Paediatric Reference Intervals: The CALIPER initiative*. *Clin. Biochem. Rev.* **29**, 89 - 96.
- STEVENS EF, PICKETT C (1994): *Managing the social environments of flamingos for reproductive success*. *Zoo Biol.* **13**, 501 - 507.
- TATONETTI NP, YE PP, DANESHJOU R, ALTMAN RB (2012): *Data-Driven Prediction of Drug Effects and Interactions*. *Sci. Transl. Med.* **4**, 125.
- TEARE JA (2013): *ISIS Physiological Reference Intervals for Captive Wildlife: A CD-ROM Resource*. Bloomington, MN, USA: International Species Information System.

ECHOCARDIOGRAPHIC EVALUATION OF CLINICALLY HEALTHY CAPTIVE LARGE FELIDS

CHAI N¹, PETIT P², KOHL M¹, BOURGEOIS A¹, GOUNI V³, TREHIOU-SECHI E³, MISBACH C³,
PETIT A³, GARRIGOU A³, GUÉPIN R³, POUCHELON JL^{3,4}, CHETBOUL V^{3,4}

¹Muséum National d'Histoire Naturelle, Ménagerie du Jardin des Plantes, 57 rue Cuvier, 75005 Paris, FRANCE; chai@mnhn.fr

²Zoo de la Palmyre, 17570 Les Mathes, FRANCE

³Unité de Cardiologie d'Alfort, Centre Hospitalier Universitaire Vétérinaire d'Alfort (CHUVA), Ecole Nationale Vétérinaire d'Alfort, Université Paris-Est, 7 avenue Général de Gaulle, 94704 Maisons-Alfort cedex, FRANCE

⁴INSERM, U955, Equipe 03, 51 avenue du Maréchal de Lattre de Tassigny, 94010 Créteil cedex, FRANCE

The aims of this study were to characterise and report transthoracic echocardiographic findings in clinically healthy large felids, with the intent to detect sub-clinical heart diseases, to assess the presence of physiological regurgitations, and to provide reference values for use in cardiologic evaluation when a heart disease is suspected in these species. During a study period of five years (2008 - 2013), 29 animals were evaluated under anaesthesia: 16 cheetahs (*Acinonyx jubatus soemmeringui*) with a mean age of 1.5 ± 0.8 years (range 0.7 - 3.5 years), five Amur leopards (*Panthera pardus orientalis*), one snow leopard (*Uncia uncia*), and six clouded leopards (*Neofelis nebulosa*). For this study, all these leopards will be gathered in one so-called group "Leopards" with a mean age of 4.3 ± 5.6 years (range 0.1 - 18.5 years). Two-dimensional and M-Mode echocardiography as well as conventional Doppler examination were performed on all animals by the same trained observer by use of an ultrasound unit equipped with 3S (1.5 - 3.5 MHz), 5S (2.0 - 5.0 MHz), and 7S (6S-D (2.4 - 8.0 MHz) phased-array transducers. With animals lying in left lateral recumbency, five right parasternal views of the heart were obtained: two short-axis views of the left ventricle at the level of the papillary muscles and the mitral valve, one short-axis view of the heart base (at the level of the aortic and pulmonary valves), and two long-axis views (4- and 5-chamber views). With the animals lying in right lateral recumbency, images obtained included the left apical 4- and 5- chambers views, with pulsed-wave Doppler recordings of the peak systolic aortic flow velocity. All valves observed in each view were examined using colour-flow Doppler mode for evidence of regurgitant jets and turbulent blood flow. Valves were also examined for structural abnormalities.

Mitral valve remodelling and aortic cusp abnormalities, probably of congenital origin, respectively leading to mitral insufficiency in all the felids, and to aortic regurgitation in 94 % cheetahs and 62 % leopards, were diagnosed. Leopards showed a predominance of early systolic mitral regurgitations whereas all mitral regurgitation jets in cheetahs were holosystolic. Nevertheless, no differences were found between the two groups regarding two-dimensional structural mitral valve abnormalities.

Tricuspid regurgitation was found in all cheetahs and in 54 % of leopards, whereas pulmonary regurgitation was pointed out in 47 % of cheetahs and 38 % of leopards. Interestingly, none of the latter regurgitations were associated with two-dimensional structural valve abnormalities, thus suggesting their physiological origin as described in humans, cats, and also dogs.

In conclusion, valvular diseases in clinically healthy big cats are common. Longitudinal follow-up of affected animals is therefore required to assess their clinical outcome.

SEVERE AORTIC REGURGITATION AND SYSTEMIC HYPERTENSION IN A NORTH-CHINESE LEOPARD (*PANTHERA PARDUS JAPONENSIS*)

LECLERC A¹, TREHIOU-SECHI E², GREUNZ EM¹, DAMOISEAUX C²,
BOUVARD J², CHETBOUL V^{2,3}

¹Parc Zoologique et de Loisirs de Thoiry, 78770, Thoiry, FRANCE; leclerc.antoine@yahoo.fr

²Université Paris-Est, Ecole Nationale Vétérinaire d'Alfort, Centre Hospitalier Universitaire Vétérinaire d'Alfort (CHUVA), Unité de Cardiologie d'Alfort, 7 avenue Général de Gaulle, 94700 Maisons-Alfort, FRANCE

³INSERM, U955, Equipe 03, 51 avenue du Maréchal de Lattre de Tassigny, 94000 Créteil, FRANCE

Ligan, an 18 year old male North-Chinese leopard (*Panthera pardus japonensis*) was followed for chronic renal failure and recurrent fatigability. The animal had been anaesthetised on several occasions for renal failure monitoring and perfusion, and a heart murmur had been noticed. Despite regular perfusions and an oral treatment with benazepril (Fortekor F20, Novartis Santé Animale, Rueil-Malmaison, France; 0.25 mg/kg/d SID), blood urea and creatinine levels remained high. The animal was anaesthetised for a cardiac check-up using medetomidine (Medetor, Virbac, Carros, France; 40.5 µg/kg) and ketamine (Ketamine 1000, Virbac, Carros, France; 2.9 mg/kg). Auscultation confirmed a grade IV/VI left basal diastolic heart murmur. Echocardiography and Doppler examination revealed a significant holodiastolic aortic insufficiency with an important colorimetric extension and of high velocity (5.34 m/s) despite anaesthesia, indicating a systemic diastolic arterial hypertension. The use of medetomidine in the anaesthetic protocol is likely to have induced a decrease of the arterial blood pressure values and therefore the systemic hypertension detected in this case could be even more pronounced than shown during the anaesthesia. Other significant results included a dotted and mildly hypertrophic myocardium, a left ventricular wall asynchronism with hypokinesia of the left ventricular free wall, and a mild mitral insufficiency without secondary left atrial dilation. A "mixed" uremic and hypertensive cardiomyopathy was suspected. Amlodipine was prescribed at 0.125 mg/kg/day SID orally (Amlodipine 5 mg, Mylan, Saint-Priest, France) and benazepril continued, with controls of the blood urea and creatinine levels. Three months after the onset of the amlodipine treatment, a non-invasive systemic arterial blood pressure measurement using the oscillometric method performed under general anaesthesia revealed an important arterial hypertension (mean pressure = 147 mmHg, mean systolic pressure = 183 mmHg, and mean diastolic pressure = 128 mmHg). The amlodipine dosage was increased to 0.25 mg/kg/day (Amlodipine 10 mg, Mylan, Saint-Priest, France). The general condition of the animal improved and the clinical signs of recurrent lethargy disappeared. A control examination was performed 19 months after the first echocardiography, with the same anaesthesia protocol, and showed a marked improvement of the cardiac parameters (aortic insufficiency velocity = 2.55 m/s). The basal heart murmur was decreased (II/VI), as well as the urea and creatinine blood levels. In conclusion, similarly to domestic cats, systemic arterial hypertension may be associated with chronic renal failure in large felids and its management using amlodipine can contribute to improve both clinical status and cardiovascular function. Further studies are needed to assess the prevalence and impact of such "cardio-renal" associations in these species.

Acknowledgements

We would like to thank all the staff from Thoiry Zoo for their help with this case.

RETROSPECTIVE REVIEW OF THE GLOBAL PREVALENCE OF MYELOLIPOMAS IN GOELDI'S MONKEYS (*CALLIMICO GOELDII*) AND IMPLICATIONS FOR FUTURE STUDY

LANGAN JN^{1,2}, KLEINSCHMIDT LM³, WARNEKE M², ALLENDER MC¹

¹University of Illinois, College of Veterinary Medicine, 1008 W. Hazelwood Drive, Urbana, Illinois 61802, USA; jennifer.langan@cvs.org

²Chicago Zoological Society, Brookfield Zoo, 3300 Golf Road, Brookfield, Illinois 60513, USA

³Iowa State University, College of Veterinary Medicine, 1600 South 16th Street, Ames, Iowa 50014, USA

Myelolipomas have been reported as rare mesenchymal tumors composed of adipose and haematopoietic tissue. Pathogenesis is poorly understood with hypotheses including neoplastic transformation, viral infection and chronic tissue hypoxia contributing to tumorigenesis. A broad range of descriptions have been published. This is because myelolipomas have a histological appearance similar to mature adipose and haematopoietic tissue and are considered to be tumor-like proliferative lesions more than a true neoplasm in some reports. Despite this, myelolipomas have been reported in many species, including domestic dogs and cats, cattle, birds, wild felids, and non-human primates. Myelolipomas in Callitrichidae have historically been detected at necropsy and rarely *ante mortem*. Multiple cases of hepatic myelolipomas in Goeldi's monkeys (*Callicimio goeldii*) at Chicago Zoological Society's Brookfield Zoo prompted an international retrospective study to determine the prevalence and investigate factors associated with this condition. A total of 816 necropsy reports (1965 - 2013) collected from institutions representing four continents were reviewed. Myelolipomas were reported in 16.8 % of all reviewed pathology cases, with no significant difference by sex. There was a significantly older mean age in affected animals compared to unaffected animals. Approximately half of the myelolipomas were diagnosed as focal and half multifocally in the liver. They were less common in the adrenal glands, spleen, and mediastinum. The majority of cases occurred in North America. This study is being presented to 1) create awareness of the prevalence of myelolipoma in Goeldi's monkeys, 2) to encourage future collaborative studies to determine the prevalence and health impacts in living collections and 3) to investigate potential etiologies for this condition in this species.

SUCCESSFUL CHEMOTHERAPY OF AN ORAL ANAPLASTIC SARCOMA IN A PYGMY HIPPOPOTAMUS (*HEXAPROTODON LIBERIENSIS*)

MASTERS N¹, FRANKLINOS L², FELTRER Y¹, POCKNELL A³,
BOLT D⁴, SMITH S⁴, MOLENAAR FM¹

¹Zoological Society of London, Whipsnade Zoo, Dunstable, Bedfordshire, LU6 2LF, UK;
nic.masters@zsl.org

²34 Upper High Street, Worthing, Sussex, BN11 1DR, UK

³Finn Pathologists, One Eyed Lane, Weybread, Diss, Norfolk, IP21 5TT, UK

⁴The Royal Veterinary College, Hawkshead Lane, North Mymms, Hatfield, Herts AL9 7TA, UK

Documented neoplasia in hippopotami is limited: an oral osteoma, a pheochromocytoma and a uterine leiomyoma. The use of chemotherapeutic agents in hippopotami has not previously been reported.

An adult female pygmy hippopotamus (*Hexaprotodon liberiensis*) presented with an oral, fleshy mass caudal to the upper right canine. Differential diagnoses included neoplasia, abscess formation related to dental disease and foreign body reaction. No improvement was seen after seven days of antimicrobial treatment based on culture and sensitivity.

Examination under general anaesthesia demonstrated that the mass (4x5 cm) was invading the ventral aspect of the maxillary gingiva. Radiography identified a well-delineated soft tissue opacity, without involvement of the teeth or maxillary bone. Biochemistry and haematology results were unremarkable. Histopathological examination with immunohistochemistry diagnosed an anaplastic sarcoma, of smooth or striated muscle origin.

Radical surgical excision (the preferred treatment option) was deemed unfeasible due to significant technical and post-operative requirements. Marginal surgery and intralesional chemotherapy were chosen as a more realistic and welfare-oriented treatment plan. Surgical debulking was performed and mitomycin C (0.4 mg/cm³ of tumour), then cisplatin (1 mg/cm³ of tumour) in an emulsion with sesame oil, were injected into remaining abnormal tissue, following a protocol extrapolated from comparable equine cases

Eight weeks later, the defect had re-filled with red, friable tissue. Post-debridement the deficit appeared larger than before, and, on the basis of poor prognosis, chemotherapy was not repeated. Histopathological examination revealed focal remnants of anaplastic sarcoma and partial erosion of tooth. Regrowth with continued tissue invasion and destruction was expected.

However, after six months, radiographs showed the deficit being delineated by the roots of the canine and the first molar. The gingiva was growing over the remaining cavity and no grossly abnormal tissue was identified. There were no significant changes in biochemistry and haematology, nor any adverse clinical effects noted. The combination of surgical debulking, chemotherapy and subsequent debridement of the area has thus far proved effective in this animal.

Animal management staff continue to monitor for recurrence through visual examination under trained behaviour. Further assessment under general anaesthesia will be performed twelve months after initial presentation. Diagnostics will include; physical examination with debridement and histopathology as appropriate, repeat radiography of the maxilla, and radiography of the thorax if evidence of invasion and possible metastasis is present. Similar annual assessments are anticipated presuming recurrence is not present.

THE NET SOLUTION: POSITIONING OF AN AFRICAN ELEPHANT FOR ANAESTHESIA UNDER FIELD CONDITIONS

HOBYS¹, WENKER C¹, ZENKER W², LAWRENZ A³, KELLER R⁴

¹Zoo Basel, Binningerstrasse 40, Postfach, 4011 Basel, SWITZERLAND; hoby@zoobasel.ch

²Tierarztpraxis Neuwiesen, Neuwiesenstrasse 6, 8610 Uster, SWITZERLAND

³Zoo Wuppertal, Hubertusallee 30, 42117 Wuppertal, GERMANY

⁴Grosstier-Rettungsdienst Schweiz und Fürstentum Liechtenstein (GTRD CH/FL), Schützenhausstrasse 56, 8424 Embrach ZH, SWITZERLAND

A 17 year old captive African elephant (*Loxodonta africana*) bull with a body weight of 4.6 tons was treated for unilateral tusk extraction due to a chronic suppurative pulpitis. The technique was adapted from an earlier description (WELSCH et al., 1989). However, the surgery was hampered by the fact that the elephant laid on the wrong side for an optimal surgical access to the tusk, although ropes were used to ensure that the elephant fell on the correct side (FOWLER, 1995). Due to limited space and inadequate capacity of the crane in place, turning of the elephant was not possible. A second surgery was planned to remove the remaining ivory and pulp tissue. A net made out of polypropylene multifilament was adapted from a net used for emergency support of horses and was first tried on two adult African elephant cows in standing sedation to estimate the adequate size. The net was fixed to the elephant bull after sedation within eight minutes. Subsequently, general anaesthesia was induced. The net was raised by a crane as the elephant became visibly immobilised, and the elephant was fully suspended in the net within ten minutes. Correct positioning in lateral recumbency on mattresses and rubber hoses was accomplished straightforward. Special attention was given to the position of the ears to allow access to the auricular veins for fluid therapy and to the legs to allow massage during the prolonged surgery. The net was easy to handle and provided a safe, fast and gentle tool that may facilitate pachyderm positioning for various veterinary-related purposes.

References

FOWLER ME (1995): *Restraint and handling of wild and domestic animals*. Iowa: Iowa State University Press, 257 - 269.

WELSCH B, JACOBSON ER, KOLLIAS GV, KRAMER L, GARDNER H, PAGE CD (1989): *Tusk extraction in the African elephant (Loxodonta africana)*. *J. Zoo Wildl. Med.* **20**, 446 - 453.

COMPARING ETORPHINE-ACEPROMAZINE AND MEDETOMIDINE-KETAMINE ANAESTHETIC PROTOCOLS IN IMPALA (*AEPYCEROS MELAMPUS*)

PERRIN K¹, GRØNDAHL C¹, NISSEN P², BERTELSEN MF¹

¹Copenhagen Zoo, Centre for Zoo and Wild Animal Health, Roskildevej 38, 2000 Frederiksberg, DENMARK; kap@zoo.dk

²University of Copenhagen, Dept. of Anaesthesia, Rigshospitalet, Blegdamsvej 9, 2100 Copenhagen, DENMARK

Impala (*Aepyceros melampus*) are a notoriously difficult species to manage in captivity and anaesthesia is associated with a high risk of complications including mortality. Historically, opioid-based protocols have been commonly employed (BALL, 2007). More recently due to both safety concerns and the lack of easy availability of potent opioids in Europe, the use of medetomidine-ketamine combinations have been advocated (BUSH et al., 2004). No studies have compared these in-depth, so the aim of this study was to evaluate an opioid-based protocol with medetomidine-ketamine.

Ten female impala (*Aepyceros melampus*) were studied in a random cross-over design. Subjects received either protocol EA; 15 µg/kg etorphine (Captivon 98[®], Wildlife Pharmaceuticals Ltd, White River, South Africa) and 0.15 mg/kg acepromazine (Calmivet Sololution injectable[®], Vetoquinol, Lure, France), or protocol MK; 110 µg/kg medetomidine (Zalopine[®], Orion Pharma Animal Health, Espoo, Finland) and 4.3 mg/kg ketamine (Ketaminol Vet[®], MSD Animal Health, AN Boxmeer, Holland) on day 1. Anaesthesia was repeated three days later with the alternative protocol. Subjective assessments of the quality of induction, muscle relaxation and recovery were made by a blinded observer. Objective monitoring included blood pressure, end tidal CO₂, regional tissue perfusion and blood gas analysis.

Significant differences were seen between the two protocols. EA had a quicker and more reliable induction and a faster recovery. Lower respiratory rates were observed with correspondingly higher paCO₂, however arterial oxygen saturation was the same or better. Blood pressures with EA were lower with higher heart rates, but regional perfusion was significantly higher.

In conclusion, EA provided superior induction, muscle relaxation and recovery. Arterial oxygenation and tissue perfusion were equal or higher than with the MK protocol despite the differences seen in other parameters.

Acknowledgements

The authors would like to thank Helle Flaga, Mari-Ann Da Silva and Mette Halck for their assistance in carrying out this study.

References

- BALL RL (2007): Antelope. In: West G, Heard D, Caulkett N (Eds.): Zoo Animal and Wildlife Immobilization and Anesthesia. Iowa USA: Blackwell Publishing Professional, 616 - 617.
- BUSH M, RAATH JP, PHILLIPS LG, LANCE W (2004): Immobilisation of impala (*Aepyceros melampus*) with a ketamine hydrochloride/medetomidine hydrochloride combination, and reversal with atipamezole hydrochloride. Tydskr. S. Afr. Vet. Ver. **75**, 14 - 18.

A NEW APPROACH TO THE SAFE ANAESTHESIA OF ANTELOPES AND GAZELLES: CONSIDERATIONS OF THE INDIVIDUAL PATIENT RATHER THAN THE SPECIES BY MEANS OF A JUMPINESS INDEX AND A MATHEMATICAL FACTOR

LOTH K, REINERS JK

Serengeti-Park Hodenhagen GmbH, Am Safaripark 1, 29693 Hodenhagen, GERMANY;
loth@serengeti-park.de

Each species of antelope and gazelle has its own anaesthesia recommendation with intra-species variations of dosages because of diverse individual responses to anaesthetic agents.

In this study a classification is developed to dose anaesthetics for darted immobilisation of each individual regardless of the species: First, the jumpiness index (JI) from grade 1 to grade 5, which describes the animal's excitement and flight behaviour. Second, the shoulder height [cm] – body weight [kg] – quotient (SH-BW) by estimated data, which describes the animal's shape.

In total, 50 anaesthetic protocols of 16 species of captive antelopes and gazelles in the Serengeti-Park Hodenhagen (04/2013 to 02/2014) were analysed. Anaesthetics were combinations of α 2-agonists medetomidine, detomidine, xylazine and opioids butorphanol, etorphine with acepromazine, and ketamine. Reversing drugs were atipamezol, naloxone and diprenorphine.

Xylazine combinations worked best for animals with JI 1-2 and every SH-BW. Etorphine combinations were best for those with JI 4-5 and SH-BW ≥ 0.6 . Medetomidine combinations were usable for all JI grades, but best for JI 3-5 animals with 0.06 mg/kg (JI 3) to 0.36 mg/kg (JI 5) in average. Ketamine was used from 2.3 mg/kg (JI 2) to 5.3 mg/kg (JI 5) in average. Atipamezole reversed the α 2-agonists with a mean dosage from 0.2 mg/kg (SH-BW < 1) to 0.9 mg/kg (SH-BW > 1.5) It was administered 1:2 because it never takes 5min without re-narcotisation.

Including further cases it should become possible to calculate whole individual anaesthetic protocols. To verify objectivity of this classification colleagues are invited to test this.

POOR AGREEMENT BETWEEN APPLANATION AND REBOUND TONOMETRY TO MEASURE INTRAOCULAR PRESSURE IN ANAESTHETISED RHESUS MACAQUES (*MACACA MULATTA*)

CARNIMEO A¹, ANDREANI V², CAPASSO M³, SILVESTRE P³, NOCERINO M³, GUANDALINI A², SELLERI P¹, DI GIROLAMO N¹

¹Clinica per Animali Esotici, Centro Veterinario Specialistico (CVS), Via Sandro Giovannini 53, 00137 Rome, ITALY; nicoladiggi@gmail.com

²Centro Veterinario Specialistico (CVS), Dept. of Ophthalmology, Via Sandro Giovannini 53, 00137 Rome, ITALY

³Parco Zoo delle Star, Via Fossignano, 04011 Aprilia (Latina), ITALY

Intraocular pressure (IOP) reflects a balance between aqueous humor production and outflow, and is an essential ophthalmic diagnostic procedure also in exotic animals (SELLERI et al., 2012; DI GIROLAMO et al., 2013). Applanation and rebound tonometers are currently used in veterinary ophthalmology to measure IOP. The aim of this study was to evaluate whether rebound and applanation tonometry could be used interchangeably in rhesus macaques (*Macaca mulatta*).

Thirty-two rhesus macaques were anaesthetised with ketamine hydrochloride (3 mg/kg intramuscularly), dexmedetomidine (40 µg/kg intramuscularly), methadone (0.2 mg/kg intramuscularly) for surgical castration. Contingently, the IOP was measured using a rebound tonometer (Tonovet; Tiolat Oy, Helsinki, Finland) and an applanation tonometer (TonoPen; Reichert inc., Depew, NY, USA). The rebound tonometer was used first to avoid any aqueous massage by the applanation tonometer. Three readings were performed for each eye alternatively in three minutes by a single investigator. Analysis of Bland-Altman and Deming regression was employed to determine agreement between the two instruments.

Results of the Bland-Altman plots demonstrated poor agreement between the two tonometers. The rebound tonometer provided significantly higher values than the applanation tonometer (mean difference 5.2 mmHg [95 % CI: 3.7 to 6.6]). The difference was proportional, increasing at higher IOP values.

Basing on results of the present study the two tonometric techniques are not interchangeable in anaesthetised rhesus macaques. Therefore, specific reference ranges for each instrument are required and multiple evaluation of the same eye should be made with the same instrument.

References

- DI GIROLAMO N, ANDREANI V, GUANDALINI A, SELLERI P (2013): Evaluation of intraocular pressure in conscious ferrets (*Mustela putorius furo*) by means of rebound tonometry and comparison with applanation tonometry. *Vet. Rec.* **172**, 396.
- SELLERI P, DI GIROLAMO N, ANDREANI V, GUANDALINI A, D'ANNA N (2012): Evaluation of intraocular pressure in conscious Hermann's tortoises (*Testudo hermanni*) by means of rebound tonometry. *Am. J. Vet. Res.* **73**, 1807 - 1812.

NUTRITIONAL DISEASES: FROM BOTTLE FEEDING TO GERIATRIC ISSUES

CLAUSS M, HATT J-M

University of Zurich, Vetsuisse Faculty, Clinic for Zoo Animals, Exotic Pets and Wildlife, Winterthurerstrasse 260, 8057 Zurich, SWITZERLAND; mclauss@vetclinics.uzh.ch

From neonates that have to be hand-raised to animals beyond their prime that have difficulties ingesting the regular diet for their species, all animals at a zoo have to be fed, mostly on a daily basis. The decision what is fed is based on various concepts, often summarised as the juxtaposition of the concept of a complete (formulated) diet and a diet consisting of 'natural' diet items, illustrated in the articles of RATCLIFFE (1966) and WACKERNAGEL (1966) on the one hand and that of HEDIGER (1966) on the other. When arguing about the differential use of pelleted diets or roughages, or mineralised minced meat vs. whole carcasses, this debate remains alive today. However, as goes nearly without saying, the decision what is fed is most often based on what has been fed before. In the preparation of husbandry guidelines, for example, it can still often be seen that the feeding chapter merely comprises an inventory of what is currently being fed at various zoos rather than a recommendation of what should be fed. A confusion of actual recommendations and summaries of current practices may make introducing dietary changes more difficult.

Different approaches are used to investigate nutrition-related problems in zoo animals. A first step is an evaluation of the diets fed in captivity and a comparison with the species' natural diet (e.g. SCHWITZER et al., 2009; TAYLOR et al., 2013), with speculative links to typical problems known in the species that are logical but lack empirical evidence in the form of proven association between the problem and the diet of individuals with that problem. Another approach is to compare clinical or pathological measures between free-ranging and captive animals (PAGLIA et al., 2000; FUJITA and KAGEYAMA, 2007; KAISER et al., 2009), with speculative links to typical diets ingested in the wild or fed in captivity but again without a proven association. As a step closer to making that association, cases or case series of diseases known to be nutrition-related from domestic veterinary medicine are described with their clinical and *post mortem* pathology, together with varying levels of details of the nutritional history (e.g. CLAUSS et al., 2009a; SCHILCHER et al., 2013); here, the link is more compelling, yet negative controls are often lacking. At an increasing level of complexity, investigations on a larger number of animals are performed, and risk factors for animals with and without a problem are identified, such as the occurrence of metabolic bone disease in koalas (*Phascolarctos cinereus*) and exposure to UVB light (PYE et al., 2013), the link between obesity and acyclicity in African elephants (*Loxodonta africana*) (FREEMAN et al., 2009), or a link between the amount of roughage investigated and faeces consistency in tapirs (CLAUSS et al., 2009b). Availability and reliability of both clinical and necropsy records, and records of the diets fed or ingested, are major limiting factors for such studies. The most sophisticated approach, evidently, are controlled experimental studies (e.g. HOBY et al., 2010; MCCUSKER et al., 2011). One difficulty in such studies is that the target problem may be difficult to demonstrate, if it is not related to a clear immediate deficiency (such as e.g. in metabolic bone disease MBD) but to long-term health effects (such as e.g. in subacute ruminal acidosis). Another difficulty evidently is the transfer of both, logical concepts and empirical results, into common husbandry practices. One of our favourite examples for this difficulty is the clear, experimental approach to iron storage disease (ISD) in marmoset by MILLER et al. (1997) that showed that iron levels above 350 ppm dry matter resulted in critical illness; yet, even in 2011 complete feeds for marmosets were promoted that contained declared iron levels above this value (CLAUSS and PAGLIA, 2012). There are examples where nutritional research led to immediate changes, such as in the

development of circulating vitamin E levels in rhinoceroses after the first presentation on the topic (CLAUSS et al., 2002), but other examples warn that measures have to be implemented to maintain alertness to problems after they have been recognised for once (BESSELMANN et al., 2008).

One factor that may limit the compliance of zoo managers to adopt recommended dietary strategies is the absence of evident, acute signs of disease or abnormality. In this respect, gorillas could be considered an interesting example. Subjectively, it appears that gorillas are the one primate species in which current recommendations to reduce the amount of unnatural diet items, such as commercial fruits, meat, grain or milk products (OFTEDAL and ALLEN, 1996; NRC, 2003; SCHWITZER et al., 2009), are widely followed, in contrast to many other primate species. This might be due to the fact that the problem of regurgitation/reingestion is particularly prominent in this species and (also) linked to diet (LUKAS, 1999); note that however, this problem is also reported in other great apes and may also be related to the same diet factors (BAKER and EASLEY, 1996; CASSELLA et al., 2012).

Another, and possibly the most critical factor that may limit the compliance of zoo managers to adopt recommended dietary strategies is the apparently banal fact that there is no easily accessible, comprehensive collection of these recommendations, in a form comparable e.g. to taxonomy-structured compendia on zoo animal medicine (FOWLER and MILLER, 2005). In older zoo literature and recommendations derived from it, lists of diet items that can be fed to animals are available (KRUMBIEGEL, 1976; ENGELMANN, 2006; BLASZKIEWITZ et al., 2009; GRUMMT and STREHLOW, 2009) without amounts or proportions, or collations of diets actually fed (RECHCIGL, 1977b; RECHCIGL, 1977a), but their value for the design of current diet regimes may be limited. There are excellent textbooks on comparative nutrition (ROBBINS, 1993; BARBOZA et al., 2009; CHEEKE and DIERENFELD, 2010) and also on more focused taxonomic groups (KLASING, 1998; HUME, 1999), including detailed scientific treatments of nutrient recommendations (NRC, 2003; NRC, 2007), but it is difficult and time-consuming to extract practical diet solutions from them. Various conference series, such as the Dr. Scholl conferences, the Comparative Nutrition Society proceedings (<http://www.cnsweb.org>), the Nutrition Advisory group proceedings and fact sheets (<http://nagonline.net/>), the Zoo Animal Nutrition book series of the European Nutrition Group (<http://www.filander.de/zoo.html>), or volumes 6, 16 and 39 of the International Zoo Yearbook all represent additional valuable resources, yet the difficulty remains that no summarizing collection exists in which, in a standardised and easily accessible format, recommended diets are given for relevant zoo animal taxa or groups. For current zoo animal nutrition, such a task is probably the most important next step. For the time being, the maybe best overview over zoo animal nutrition can be found in the five nutrition chapters of KLEIMAN et al. (1996), and in various textbooks for specific groups, e.g. for reptiles in CALVERT (2004b; 2004a) and DONOGHUE (2006). For the hand-raising of neonates, lists of milk composition are available (JENNESS and SLOAN, 1970; OFTEDAL, 1984) as well as various compilations (e.g. TAYLOR and BIETZ, 1982) and numerous individual articles, and there are commercial preparations designed to achieve any kind of milk nutrient composition (e.g. Zoologic Milk Matrix, <http://www.petag.com/>).

Species- or taxon-specific knowledge in the feeding of zoo animals is important, with various examples such as galactose intolerance that leads to cataracts in macropod joeys when fed lactose-containing milk (such as cow's milk) (STANLEY, 2002), the fact that vitamin D₂ has no effect on calcium absorption in new world monkeys which therefore require a source of vitamin D₃ (HUNT et al., 1967), or a particular proneness for copper deficiency in blesbok (DIERENFELD et al., 1988), to name just a few. On the other hand, several general themes are prevalent in zoo animal nutrition, such as MBD, ISD, obesity, and dental disorders, as well as the encouragement of natural behaviours (HOSEY et al., 2013). Whereas MBD is particularly affecting growing animals, the effects of obesity, ISD and dental disorders accumulate over time and therefore affect adult and geriatric animals. In particular, dental

abnormalities are common in very old animals (e.g. MARTIN JURADO et al., 2008), and dietary adjustment for this group often requires the presentation of diet items that can be ingested without intensive mastication (e.g. HATT et al., 2004). In particular, the prevention of obesity has received increased attention at recent zoo nutrition meetings, and regular body condition scoring and/or weighing of animals, with corresponding adjustments in diet, are widely recommended. Additionally, reports on collection-wide dietary changes, in particular with the aim of increasing dietary fibre, and reducing sugars (as in commercial fruit) and starches (as in grain-based products) have been presented (FIDGETT, 2012; HATT, 2012; TAYLOR et al., 2012; PLOWMAN, 2013) that demonstrate not only the feasibility of such large-scale changes, but also their cost-efficiency. Efforts to spread knowledge on the nutrient composition to zoo animal keepers to motivate and increase the acceptance of diet changes (e.g. CLAUSS et al., 2012) should continue; for example, a series of posters on the topic is available (also in English language) at the Dierenwelzijnsweb (<http://www.groenkennisnet.nl/dierenwelzijnsweb/Pages/dierentuinvoeding.aspx>). Last but not least, diets fed to zoo animals represent visible cues for zoo visitors on the biology of the species; in this respect, feeding diets of biological logic is an integral part of the pedagogic concept of a zoo.

References

- BAKER KC, EASLEY SP (1996): *An analysis of regurgitation and reingestion in captive chimpanzees. Appl. Anim. Behav. Sci.* **49**, 403 - 415.
- BARBOZA PS, PARKER KL, HUME ID (2009): *Integrative wildlife nutrition. Springer-Verlag, Berlin Heidelberg.*
- BESSELMANN D, SCHAUB D, WENKER C, VÖLLM J, ROBERT N, SCHELLING C, STEINMETZ H, CLAUSS M (2008): *Juvenile mortality in captive lesser kudu (Tragelaphus imberbis) at Basle zoo and its relation to nutrition and husbandry. J. Zoo Wildl. Med.* **39**, 86 - 91.
- BLASZKIEWITZ B, PUSCHMANN W, ZSCHEILE D, ZSCHEILE K (2009): *Zootierhaltung. Tiere in menschlicher Obhut. Säugetiere 5., überarbeitete und erweiterte Auflage. Harri Deutsch Verlag, Frankfurt/Main.*
- CALVERT I (2004a): *Nutritional problems. In: Girling SJ, Raiti P (Eds.): BSAVA Manual of Reptiles. British Small Animal Veterinary Association, Quedgeley, Gloucester, 289 - 308.*
- CALVERT I (2004b): *Nutrition. In: Girling SJ, Raiti P (Eds.): BSAVA manual of reptiles. British Small Animal Veterinary Association, Quedgeley, Gloucester, 18 - 39.*
- CASSELLA CM, MILLS A, LUKAS KE (2012): *Prevalence of regurgitation and reingestion in orangutans housed in North American zoos and an examination of factors influencing its occurrence in a single group of Bornean orangutans. Zoo Biol.* **31**, 609 - 620.
- CHEEKE PR, DIERENFELD ES (2010): *Comparative animal nutrition and metabolism. CAB International, Wallingford, UK.*
- CLAUSS M, JESSUP DA, NORKUS EB, HOLICK MF, STREICH WJ, DIERENFELD ES (2002): *Fat soluble vitamins in blood and tissues of free-ranging and captive rhinoceros species. J. Wildl. Dis.* **38**, 402 - 413.
- CLAUSS M, KELLER A, PEEMÖLLER A, NYGRÉN K, HATT J-M, NUSS K (2009a): *Postmortal radiographic diagnosis of laminitis in a captive European moose (Alces alces). Schw. Arch. Tierheilkd.* **151**, 545 - 549.
- CLAUSS M, WILKINS T, HARTLEY A, HATT J-M (2009b): *Diet composition, food intake, body condition, and fecal consistency in captive tapirs (Tapirus spp.) in UK collections. Zoo Biol.* **28**, 279 - 291.
- CLAUSS M, HUMMEL J, HATT J-M (2012): *Nutrient composition tables for fruits and vegetables as a decision tool for zoo animal keepers. Proc. Europ. Zoo Nutr. Conf.* **7**, 51 - 53.

-
- CLAUSS M, PAGLIA DE (2012): Iron storage disease in captive wild mammals - the comparative evidence. *J. Zoo Wildl. Med.* **43**, S6 - S18.
- DIERENFELD ES, DOLENSEK EP, MCNAMARA TS, DOHERTY JG (1988): Copper deficiency in captive blesbok antelope (*Damiliscus dorcas phillipsi*). *J. Zoo Anim. Med.* **19**, 126 - 131.
- DONOGHUE S (2006): Nutrition. In: Mader DR (Ed.): *Reptile Medicine and Surgery*. Saunders Elsevier, St. Louis, 251 - 298.
- ENGELMANN WE (Ed.) (2006): *Zootierhaltung. Tiere in menschlicher Obhut. Reptilien und Amphibien*. Verlag Harri Deutsch, Frankfurt am Main.
- FIDGETT A (2012): Changing hoofstock rations at Chester Zoo. Presentation at the Forage Workshop of the 7th European Zoo Nutrition Conference, 27-30 January 2012, Zurich.
- FOWLER ME, MILLER RE (Eds.) (2005): *Zoo and Wild Animal Medicine*. 5th ed. Saunders, St. Louis.
- FREEMAN EW, GUAGNANO G, OLSON D, KEELE M, BROWN JL (2009): Social factors influence ovarian acyclicity in captive African elephants (*Loxodonta africana*). *Zoo Biol.* **28**, 1 - 15.
- FUJITA S, KAGEYAMA T (2007): Polymerase chain reaction detection of *Clostridium perfringens* in feces from captive and wild chimpanzees (*Pan troglodytes*). *J. Med. Primatol.* **36**, 25 - 32.
- GRUMMT W, STREHLOW H (Eds.) (2009): *Zootierhaltung–Tiere in menschlicher Obhut. Vögel*. Verlag Harry Deutsch, Frankfurt am Main.
- HATT J-M, WENKER C, CASTELL J, CLAUSS M (2004): Dietary and veterinary management of a lingual abscess in a geriatric captive black rhino (*Diceros bicornis*) with iron storage disease. *Proc. Eur. Ass. Zoo Wildl. Vet.* **5**, 339 - 340.
- HATT J-M (2012): Commissary organisation and design. *Proc. Europ. Zoo Nutr. Conf.* **7**, 49 - 50.
- HEDIGER H (1966): Diets of animals in captivity. *Int. Zoo Yb.* **6**, 37 - 58.
- HOBY S, WENKER C, ROBERT N, JERMANN T, HARTNACK S, SENGER H, AEBISCHER C-P, LIESEGANG A (2010): Nutritional metabolic bone disease in juvenile veiled chameleons (*Chamaeleo calypttratus*) and its prevention. *J. Nutr.* **140**, 1923 - 1931.
- HOSEY G, MELFI V, PANKHURST S (2013): *Zoo animals: behaviour, management, and welfare*. Oxford University Press, Oxford, UK.
- HUME ID (1999): *Marsupial nutrition*. Cambridge University Press, Cambridge.
- HUNT RD, GARCIA FG, HEGSTED DM, KAPLINSKY N (1967): Vitamins D₂ and D₃ in New World primates: influence on calcium absorption. *Science* **157**, 943 - 945.
- JENNESS R, SLOAN RE (1970): The composition of milks of various species: a review. *Dairy Sci. Abstr.* **32**, 599-612.
- KAISER TM, BRASCH J, CASTELL JC, SCHULZ E, CLAUSS M (2009): Tooth wear in captive wild ruminant species differs from that of free-ranging conspecifics. *Mamm. Biol.* **74**, 425 - 437.
- KLASING K (1998): *Comparative avian nutrition*. CAB International, Wallingford, UK.
- KLEIMAN DG, ALLEN ME, THOMPSON KV, LUMPKIN S (Eds.) (1996): *Wild Mammals in Captivity. Principles and Techniques*. University of Chicago Press, Chicago.
- KRUMBIEGEL I (1976): *Gefangene Tiere richtig füttern*. DLG-Verlagsgesellschaft, Frankfurt/Main, Germany.
- LUKAS KE (1999): A review of nutritional and motivational factors contributing to the performance of regurgitation and reingestion in captive lowland gorillas (*Gorilla gorilla gorilla*). *Appl. Anim. Behav. Sci.* **63**, 237 - 249.
- MARTIN JURADO O, CLAUSS M, HATT J-M (2008): Irregular tooth wear and longevity in captive wild ruminants: a pilot survey of necropsy reports. *J. Zoo Wildl. Med.* **39**, 69 - 75.
- MCCUSKER S, SHIPLEY LA, TOLLEFSON TN, GRIFFIN M, KOUTSOS EA (2011): Effects of starch and fibre in pelleted diets on nutritional status of mule deer (*Odocoileus hemionus*) fawns. *J. Anim. Physiol. Anim. Nutr.* **95**, 489 - 498.

-
- MILLER GF, BARNARD DE, WOODWARD RA, FLYNN BM, BULTE JWM (1997): Hepatic hemosiderosis in common marmosets (*Callithrix jacchus*): effect of diet on incidence and severity. *Lab. Anim. Sci.* **47**, 138 - 142.
- NRC (2003): *Nutrient requirements nonhuman primates. Second revised edition.* National Research Council, The National Academy Press, Washington D.C.
- NRC (2007): *Nutrient requirements of small ruminants. Sheep, goats, cervids and New World camelids.* National Academy of Science Press, Washington D.C.
- OFTEDAL OT (1984): Milk composition, milk yield and energy output at peak lactation: a comparative review. *Symp. Zool. Soc. Lond.* **51**, 33 - 85.
- OFTEDAL OT, ALLEN ME (1996): *The feeding and nutrition of omnivores with emphasis on primates.* In: Kleiman DG, Allen ME, Thompson KV, Lumpkin S (Eds.): *Wild Mammals in Captivity. Principles and Techniques.* University of Chicago Press, Chicago, 148 - 157.
- PAGLIA DE, MILLER CL, FOERSTER SH, WYNNE JE, TSU ICH, KENNY DE (2000): Evidence for acquired iron overload in captive tapirs (*Tapirus* spp.). *Proc. Am. Ass. Zoo Vet.* **2000**, 124 - 126.
- PLOWMAN A (2013): Diet review and change for monkeys at Paignton Zoo Environmental Park. *J. Zoo Aquar. Res.* **1**, 73 - 77.
- PYE GW, GAIT SC, MULOT B, DE ASUA MDR, MARTINEZ-NEVADO E, BONAR CJ, BAINES SJ, BAINES EA (2013): Metabolic bone disease in juvenile koalas (*Phascolarctos cinereus*). *J. Zoo Wildl. Med.* **44**, 273 - 279.
- RATCLIFFE HL (1966): Diets for zoological gardens: aids to conservation and disease control. *Int. Zoo Yb.* **6**, 4 - 22.
- RECHCIGL M (Ed.) (1977a): *CRC handbook series in nutrition and food. Section G: Diets, culture media, food supplements. Volume I: Diets for mammals.* CRC Press Inc., Cleveland, OH.
- RECHCIGL M (Ed.) (1977b): *CRC handbook series in nutrition and food. Section G: Diets, culture media, food supplements. Volume II: Food habits of, and diets for invertebrates and vertebrates - zoo diets.* CRC Press Inc., Cleveland, OH.
- ROBBINS CT (1993): *Wildlife feeding and nutrition.* Academic Press, San Diego.
- SCHILCHER B, BAUMGARTNER K, GEYER H, LIESEGANG A (2013): Investigations on rumen health of different wild ruminants in relation to feeding management. *J. Zoo Aquar. Res.* **1**, 28 - 30.
- SCHWITZER C, POLOWINSKY SY, SOLMAN C (2009): Fruits as foods – common misconceptions about frugivory. In: Clauss M et al. (Eds.): *Zoo Animal Nutrition IV.* Filander Verlag, Fürth, 131 - 168.
- STANLEY RG (2002): Marsupial ophthalmology. *Vet. Clin. North Am. Exotic Anim. Pract.* **5**, 371 - 390.
- TAYLOR LA, WARREN A, SIMPSON N, CLAUSS M, SCHWITZER C (2012): Is it worth it? The cost of feeding fruits. *Proc. Europ. Zoo Nutr. Conf.* **7**, 11.
- TAYLOR LA, SCHWITZER C, OWEN-SMITH N, KREUZER M, CLAUSS M (2013): Feeding practices for captive greater kudu (*Tragelaphus strepsiceros*) in UK collections as compared to diets of free-ranging specimens. *J. Zoo Aquar. Res.* **1**, 7 - 13.
- TAYLOR SCS, BIETZ A (1982): *Infant diet/care notebook compiled by the Infant Diet/Care Committee.* American Association of Zoological Parks and Aquariums; available at: <http://catalog.hathitrust.org/Record/009473424>
- WACKERNAGEL H (1966): Feeding wild animals in zoological gardens. *Int. Zoo Yb.* **6**, 23 - 37.

THE ACHILLES' HEEL OF BREEDING CHEETAHS

KNEISL T¹, KARBE F¹, STAGEGAARD J², WILL H¹,
BAUMGARTNER K¹, LIESEGANG A³

¹Zoo Nuremberg, Am Tiergarten 30, 90480 Nürnberg, GERMANY; tinakneisl@aol.com

²Ree Park - Ebeltoft Safari, Stubbe Søvej 15, 8400 Ebeltoft, DENMARK

³University of Zurich, Institute for Animal Nutrition, Vetsuisse Fakultät, Winterthurerstrasse 270, 8057 Zurich, SWITZERLAND

Two zoos, both having bred cheetahs (*Acinonyx jubatus*) successfully for many years, experienced calcaneus fractures in several cubs for the first time. In previous years, temporary lameness, defective position and even fractures occurred in the front limbs of 3 to 5 months old cheetahs. These cases correlated with an unbalanced diet of meat only suspecting Metabolic Bone Disease (MBD). This case report from two different zoos describes these fractures and discusses the practical problems associated to feeding and possible methods of prophylaxis and treatment of MBD in cheetahs.

Complete carcass feeding with small mammals and poultry play an important role in the nutrition of adult cheetahs. Usually the portion of complete animals in the ration of young cheetahs is even higher. Additionally meat of large mammals is fed to cheetahs. Several times a week raw meat is dusted with a mineral supplement for carnivores. In our cases unfavourable changes (more meat and less complete carcasses due to a shortage of feed animals) in the practical feeding of the young cheetahs led to a suboptimal diet.

The causes for MBD are a lack of vitamin D, which causes the genuine rickets, a lack of calcium and/or a poor calcium-phosphorus ratio. In young cheetahs the enteral absorption of calcium as well as the incorporation of calcium into the bones is independent of vitamin D. Mineral supplements for big cats contain high levels of vitamin D (e.g. Carnivore Supplement (Mazuri[®], St.Louis, USA): 225 IU/g). For this reason, minimal amounts should be sufficient and a lack of vitamin D as the reason for rickets seems unlikely. In these cases feeding mainly meat causes an inappropriate calcium-phosphorus ratio as well as an absolute lack of calcium which leads to depletion of calcium from the bones via the parathyroid hormone path (All Meat Syndrome). Additionally feeding of mineral supplements cannot compensate for the lack of calcium because the animals are not able to ingest the huge amounts of calcium required (> 40 g of calcium carbonate per kg meat). Only the regular feeding of complete small mammals or adult chickens assures the adequate supply of calcium whilst the livers of the feed animals provide the sufficient amount of vitamin A and D. It is essential to adapt the feeding plan to the amount of calcium as well as to the energy requirements because excessive energy amounts result in an increased secretion of the hormones insulin, growth hormone and IGF-1, and this eventually leads to MBD.

The method of choice in treating fresh calcaneus fractures is osteosynthesis with pins and tension banding. Conservative methods usually fail due to the tendon traction of the hamstring which prevents the bones from healing. In both cases in Nuremberg surgery was possible and after removing the implants 3.5 months later the cats were free of lameness. In Ebeltoft, the calcaneus fracture was diagnosed a couple of days after it had occurred and due to contracture surgery was not possible anymore. The fracture healed without surgical treatment through cage rest and only a slight lameness remained.

Complete carcass feeding of chickens and/or small mammals seems essential for a successful upbringing of cheetahs. Even without any supplementation no deficits are likely to happen, if the feeding animals are sufficiently supplemented themselves and enough of these are provided to the growing cheetahs.

CORRELATIONS OF DIET COMPOSITION AND DIET-RELATED DISORDERS IN A COLLECTION OF CAPTIVE WILD RUMINANTS AT THE NATIONAL ZOOLOGICAL GARDENS OF SOUTH AFRICA

GATTIKER C¹, ESPIE I², LANE EP², KOTZE A², CODRON D^{1,3}, CLAUSS M^{1*}

¹University of Zurich, Vetsuisse Faculty, Clinic for Zoo Animals, Exotic Pets and Wildlife, Winterthurerstrasse 260, 8057 Zurich, SWITZERLAND; *mclauss@vetclinics.uzh.ch

²National Zoological Gardens of South Africa, 232 Boom St, Pretoria, SOUTH AFRICA

³Florisbad Quaternary Research, National Museum, PO Box 266, Bloemfontein 9300, SOUTH AFRICA

Although diet-related disorders have received much attention in the zoo literature, evidence-based results on relationships between diet and disease beyond case reports or case series are still rare, often due to a lack of dietary information that can be linked statistically to clinical or necropsy reports. We investigated 24 species of captive wild ruminants from one facility for which quantitative feeding instructions and necropsy reports between 1991 and 2012 were available. Species were classified as grazer (GR), intermediate feeder (IM) or browser (BR). Feeding type and body mass were significantly related to the diet fed, with smaller and BR species receiving higher proportions of non-roughage diet items. There were no significant differences between feeding types in the occurrence of parakeratosis/ruminitis/ acidosis (PRA) at necropsy and no direct correlation between the proportion of non-roughage diet items and PRA across species. However, there was a significant effect of the proportion of non-roughage diet items on PRA when body mass was also taken into account: larger species, and those that received more non-roughage diet items, had higher prevalence of PRA. The results underline that diet and lack of structured feed items can be related to the disease complex of acidosis in ruminants, but also suggest that this is modified by factors related to animal size. These latter may include susceptibility to acidosis, or husbandry-related opportunities to monopolise non-roughage feeds and ingest higher proportions than intended by feeding instructions.

This study was part of the Zoo Research Camp (ZRC) 2013 organised by the National Zoological Gardens of South Africa and the Vetsuisse Faculty, University of Zurich, Switzerland.

NO COUNTRY FOR OLD CROCODILE - FATAL LEAD TOXICITY IN CAPTIVE NILE CROCODILES: CLINICAL SYNDROME AND ATTEMPTED CHELATION THERAPY WITH ORAL D-PENICILLAMINE

KILGALLON C¹, KINNE J², MOITTIE S¹

¹Dubai Falcon Hospital, Dubai, UNITED ARAB EMIRATES; conchubhair2001@yahoo.co.uk

²Central Veterinary Regional Laboratory, Dubai, UNITED ARAB EMIRATES

Crocodylians are purportedly unsusceptible to the toxic effects of lead. This report documents the clinical signs and pathology attributable to the cumulative effects of iatrogenic lead toxicity which were observed in a group of Nile crocodiles (*Crocodylus niloticus*) at a private collection following the prolonged intermittent feeding of bird carcasses contaminated with ammunition pellets. *Ante mortem* lesions included extensive tooth loss, non-regenerative anaemia, anorexia, weakness, lethargy; limb paresis and deep skin ulceration. Physical examinations and phlebotomy were carried out under physical restraint using roping techniques. Haematological and blood chemistry changes included chronic non-regenerative anaemia and elevations of aspartate aminotransferase (AST) and creatine kinase (CK) levels. Median (min - max) blood lead concentrations in the group were 3.68 (3.21 - 5.42) ppm. The group was treated using d-penicillamine administered orally at doses and frequencies calculated based upon the principles of allometric scaling. After three weeks of treatment, blood lead concentrations within the group had dropped significantly (2.33 (2.11 – 3.75); $P < 0.03$). Despite therapy, all animals died. Significant quantities of lead pellets at varying stages of degradation were present in the stomach of two animals. Moderate to severe demyelination of the brain stem, renal tubule necrosis, and hyaline necrosis of skeletal muscle suggestive of secondary myopathy, were dominant histopathological features. Contrary to anecdotal evidence, Nile crocodiles appear to be susceptible to fatal lead poisoning after cumulative exposure to high levels of this heavy metal.

NEUROCHEMICAL CHARACTERISTIC OF GALANIN-EXPRESSING ENTERIC NEURONS SUPPLYING SMALL INTESTINE OF WILD BOAR. ENS - NEW POSSIBILITIES IN ZOO AND WILD ANIMAL RESEARCH?

CZUJKOWSKA A¹, KRUSZEWICZ A¹, ARCISZEWSKI MB²

¹Warsaw Zoo Garden, Ratuszowa 1/3 03-461 Warsaw, POLAND; azyl@zoo.waw.pl

²University of Life Sciences in Lublin, Faculty of Veterinary Medicine, Dept. of Animal Anatomy and Histology, Akademicka 13, 20-950 Lublin, POLAND; mb.arciszewski@wp.pl

The aim of the study was to evaluate whether and to what extent galanin is expressed in enteric neurons and nerve fibres supplying distinct regions of wild boar small intestine (duodenum, jejunum, ileum). Its presence, coexpression and description of enteric nervous system (ENS) structure in wild boar would be a good starting point in future analyses of gastrointestinal tract (GI) of that wild species. Choice of the galanin was due to its broad presence both in enteric nervous and central nervous system, and its wide array of biological activities. At central level galanin mediates feeding behaviour, nociception, cotransmission experiments have also shown its neuroprotective and antinociceptive activity. In ENS galanin positive neurons are classified as motoneurons, interneurons, and secretomotoric neurons. It's broad function and ubiquity makes it a perfect neuropeptide for comparison of chemical coding of different species, both wild and domestic. Enteric nervous system (ENS) is also called a "second brain" due to the number of neurons and neuropeptides that are engaged in its function. ENS is capable of autonomous function, but also receives innervation from autonomic nervous system. Its structure consists of two major ganglia (myenteric and submucosal), that have multiple connections between each other and are present at all the length of GI tract. ENS is involved in multiple aspects of GI tract functioning like: local blood flow, peristaltic, mucosal transport and secretion, modulation of immunological and neuroendocrine process.

Double immunohistochemical staining was applied in order to study the co-localisation of galanin with different neuropeptides in enteric neurons and nerve fibers innervating wild boar small intestine. Expression of galanin was found in 5 to 10 % of myenteric neurons and in 45 to 65 % of submucous neurons, depending on the intestine region. In all three segments of small intestine, moderately numerous to numerous galanin-immunoreactive (IR) nerve fibres were found between neurons of both ENS ganglia, smooth muscle circular layer and between gland and villi of the mucosa. In longitudinal smooth muscle layer of the jejunum and ileum (but not duodenum) single galanin-IR nerve fibres were found. Around duodenal Brunner's glands, blood vessels of the jejunal submucous layer as well as in lamina muscularis mucosae of all regions of wild boar small intestine the presence of single galanin-expressing nerve fibres was noted. In myenteric and submucous neurons of small intestine co-expression of galanin with SP, VIP and calbindin was found. Enteric nerve fibres of small intestine that were galanin positive showed additionally expression of SP, VIP and CRF. The presented work is the first description of the chemical code of neurons in small intestine of wild boar, and according to current literature wild boar similarly to other mammals has a unique chemical code of neuropeptides. Surprisingly our results showed certain differences when comparing wild boar with domestic pig, possibly related to domestication process of that species.

In last twenty years the ENS attracted more attention due to intensive research on gastrointestinal diseases that are related to ENS dysfunction/damage, like: Hirschprung disease, irritable bowel syndrome, constipation, gastroesophageal reflux disease etc. Research on chemical coding of enteric neurons in different species of wild and zoo animals would be a new direction, as there are many aspects of management that can influence GI tract, and it would be very interesting to compare wild and captive populations.

THE USE OF EXTERNAL TEMPERATURE LOGGERS FOR OPTIMISATION OF THE TEMPERATURE GRADIENT IN REPTILE ENCLOSURES

HALCK ML, BERTELSEN MF

Copenhagen Zoo, Center for Zoo and Wild Animal Health, Frederiksberg, DENMARK; mlh@zoo.dk

Reptiles are ectothermic and regulate their body temperature by physiological and behavioural alterations. The preferred optimal temperature zone (POTZ) is defined within the preoptic area of the anterior hypothalamus. Body temperatures within this zone permit optimal performance for digestion, locomotion etc. It is essential for the reptile to be able to select temperatures within the POTZ. Enclosures must therefore provide a temperature gradient allowing animals to thermoregulate by actively seeking warmer or colder locations within the enclosure. In practice, however, it may be difficult to obtain reliable information regarding temperature preferences of many reptile species, and to assess the environment provided.

We describe a simple, novel technique to assess whether the quality of the available temperature gradient of an enclosure is appropriate for its inhabitant, using externally attached temperature loggers (iButton thermochron DS1921G) in combination with temperature measurements from the enclosure. Briefly, the extremes of the selected temperatures are compared with the available thermal gradient. If the reptile uses the extremes of the thermo gradient of the enclosure, these should be widened to adjust the gradient to the individual species.

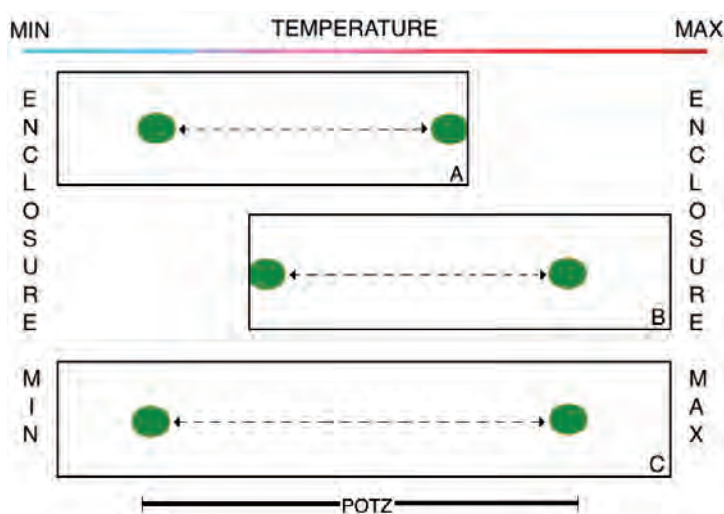


Fig. 1: The green circles represent the reptile.

A: The maximum temperature in the enclosure is too low.
B: The minimum temperature in the enclosure is too high.

C: The temperature is well adjusted to the reptile. Neither the minimum or maximum temperature in the enclosure is used. The reptile can freely select temperatures within POTZ.

Case example:

In six red-footed tortoises (*Chelonoidis carbonaria*) a logger was attached to the plastron and carapace with duct tape. The maximal and minimal temperatures selected by the tortoises were recorded while they were in their terrarium. All of the tortoises used the maximal temperature available in the terrarium. When a larger temperature gradient was provided, the tortoises increased their average temperature, and did not use the maximal temperature available. In conclusion, the temperature gradient was too small in the enclosure to begin with, and the maximal temperature was increased. The exact importance of the availability of POTZ is unknown, but may optimise reptile health including growth, digestion, and reproduction.

HISTOPATHOLOGICAL ANALYSIS OF VISCERA IN TERATOGENIC NEOTROPICAL VIPERIDS

CARVALHO MPN¹, SANT'ANNA SS^{1,2}, GREGO KF², GOGONE ICVP¹, CATÃO-DIAS JL¹

¹University of São Paulo, School of Veterinary Medicine and Animal Science, Dept. of Pathology, Laboratory of Wildlife Comparative Pathology, Avenida Orlando Marques de Paiva, 87, 05508-270 – Cidade Universitária, São Paulo – SP, BRAZIL; marcelocarvalho@usp.br

²Butantan Institute, Laboratory of Herpetology, 1500 Vital Brasil Avenue, 05503-900, São Paulo – SP, BRAZIL

Summary

A wide variety of developmental anomalies are observed in reptiles. External malformations are reported in snakes, but little is known about visceral changes. The aim of this study was to investigate and characterise histopathological alterations presented in the viscera of teratogenic neotropical viperids of two species, *Bothrops jararaca* and *Crotalus durissus* and correlate the findings with external macroscopic malformations. From 76 analysed snakes, 100 % of rattlesnakes and 98.3 % of pit vipers presented visceral changes. Unexpected findings were non-infectious renal pathological processes, such as renal tubular cystic disease and glomerulocystic disease. This research demonstrated the effect of external malformation in internal organs, as well as concomitant visceral and external alterations, revealing changes that further undermine affected individual survival.

Introduction

Congenital malformation or teratogenicity may be defined as a structural defect that originates during embryonic life, whether it is discovered in an embryo or at any time after birth (BELLAIRS, 1981; KALTER, 2003). Such malformations have been recognised in most classes of vertebrates and are often incompatible with prolonged life (BELLAIRS, 1981). They may be gross or microscopic and may be present in any organ and/or tissue (WARKANY, 1947). Teratogenicity has been studied in humans, domesticated and laboratory animals, but little is known about their impact and occurrence in wild animal populations (LEIPOLD, 1980; KALTER, 2003).

A wide variety of developmental anomalies is observed in reptiles (FRYE, 1991). Congenital malformation in these animals may arise due to genetic and/or environmental factors (SANT'ANNA et al., 2013). The gene pools of some species are severely restricted or concentrated because of geographic limitations such as islands or highly isolated populations caused by habitats fragmentation. Moreover, other species are unisexual and, therefore, reproduce parthenogenetically, yielding small isolated clones of genetically near-identical individuals (BILLY, 1986; FRYE, 1991). Temperature and humidity are known factors that can significantly induce developmental anomalies, but also environmental contaminants, radiation and infections are cited as important causes (BELLAIRS, 1981; WALLACH, 2007; JOHNSON, 2010).

In snakes, external malformations are reported, e.g. bicephaly, hydrocephaly, brachygnathia, harelip, micrognathia of upper maxilla, head malformation, schistosomia, kinked tail, incomplete tail, dwarfism, anophthalmia, microphthalmia, buphthalmos, fusion of scales, scale heterotopy and spine malformations (kyphosis, scoliosis and lordosis) (PENDLEBURY, 176; BELLAIRS, 1981; FEDERSONI, 1981; ANDRADE AND ABE, 1993; WALLACH, 2007; SANT'ANNA et al., 2013). On a lower frequency, viscera malformations are

also described, involving cardiac, kidney, stomach, oesophagus, liver, gallbladder and tracheal deformities (SCOTT, 1925; ORÓS et al., 1997; JENSEN and WANG, 2009; PALMIERI et al., 2013).

Although data are found in the literature, few articles approach the histopathologic characterisation of lesions, associating findings with external deformities (SCOTT, 1925; ORÓS et al.; JENSEN and WANG, 2009; PALMIERI et al., 2013). The aim of this study was to investigate and characterise histopathological alterations presented in the viscera of two species of teratogenic neotropical viperids: *Bothrops jararaca* (South American pit viper) and *Crotalus durissus* (South American rattlesnake), correlating the findings with macroscopic external malformations.

Material and methods

All procedures were approved by the Ethics Committee on Animals Use (2691/2012) and by SISBIO license (34863-1).

From 2007 to 2013, newly captured individuals of *Bothrops jararaca* and *Crotalus durissus* sent to Butantan Institute, Brazil, were measured, weighted, and adult females were assessed by ultrasound in order to determine whether they were pregnant. Pregnant snakes were housed individually in plastic boxes with corrugated cardboard as substrate, and water *ad libitum* in a climate-controlled room with 24 - 26°C and 70 % relative humidity. Live mice (*Mus musculus*) were offered monthly for feeding.

After birth or abortion, offspring were measured, sexed, weighed and examined for the presence of gross malformations. Individuals with external deformities were euthanised and necropsied.

The malformations observed were classified according to FRYE (1991), ROTHSCCHILD et al. (2012) and SANT'ANNA et al. (2013), and included spinal malformations (lordosis, kyphosis, scoliosis and kyphoscoliosis), ocular deformities (anophthalmia, microphthalmia and buphthalmos), scale malformations (ventral scale fusion and ventral scale heterotopy), head anomalies (bicephaly, brachygnathia, hydrocephaly, micrognathia of the upper jaw, prognathism, harelip and deformed head), and body malformations (schistosomia, kinked tail tip and incomplete tail).

Considering the obtained litters, 59 pit vipers and 19 rattlesnakes (total of 78 teratogenic snakes) were selected from a group of 124 teratogenic individuals for visceral histopathologic analysis. Samples from oesophagus, stomach, small intestine, large intestine, cloaca, trachea, thymus, heart, thyroid, lungs, liver, gallbladder, kidneys, spleen, pancreas, adrenal glands and gonads were fixed in 10 % neutral buffered formalin and embedded in paraffin. Sections, 5µm thick, were stained with haematoxylin and eosin (HE); 12 healthy neonate snakes (six pit vipers and six rattlesnakes - three male and three female for each species) were euthanised and served as control for histopathological changes.

Results and discussion

Of all analysed snakes, 100 % of rattlesnakes and 98.3 % of pit vipers presented visceral changes. Most relevant histopathologic findings were plotted according to external malformations; (table 1 for pit vipers and table 2 for rattlesnakes).

Liver and/or kidney fatty degeneration was the most frequent finding, observed in 100 % of rattlesnakes and 91.4 % of pit vipers. However, they were also noted in the control group suggesting a lack of correlation between fatty degeneration and external malformations. This event probably occurred due to the physiological process of yolk absorption in neonates (MCLELLAND, 1979), resulting on lipid accumulation in liver and kidneys.

All inflammatory processes present in pit vipers with schistosomia were analysed and classified, which exhibited a diversity of affected organs as heterophilic coelomitis (8 %), nephritis (18 %) and myo-

carditis (8 %), probably due to exposed viscera. There is no reported data about their occurrence on reptiles affected by schistosomia.

Glomerulocystic was found in conjunction with spinal, head and body deformities in both, pit vipers and rattlesnakes, whereas renal tubular cystic disease was evident in pit vipers only, associated to external alterations in the same regions. Cortical and/or medullar renal cyst formation can be induced by various chemicals/substances, such as long-acting corticosteroids, diphenylamine, polychlorinated biphenyls, alloxan, and diphenylthiazole as described in laboratory animals. (MAXIE and NEWMAN, 2007) Therefore it is possible that environmental contaminants could play a role in the occurrence of visceral and external malformations in free living snakes.

This study presented a first overview of visceral lesions encountered on teratogenic snakes and their association with external malformations. Additional studies should be conducted in order to clarify the complexity of these lesions and their interaction. This research demonstrated the effect of external malformation on internal organs, as well as concomitant visceral and external alterations, revealing changes that further undermine affected individual survival.

References

- BELLAIRS A d'A (1981): *Congenital and developmental diseases*. In: Cooper JE, Jackson OF: *Diseases of the reptilia*. London: The pitman press, 469 - 485.
- BILLY AJ (1986): *Developmental deformities in the parthenogenetic lizard *Cnemidophorus uniparens* (Teiidae) and the "anomalous male" phenomenon*. *Can. J. Zool.* **64**, 2418 - 2424.
- FRYE FL (1991): *Developmental anomalies*. In: Frye FL (1991): *Reptile care: an atlas of diseases and treatments*. New Jersey: TFH Publications, 393 - 413.
- HARTMAN DS (1989): *An overview of renal cystic disease*. In: Hartman DS: *Renal cystic disease*. Philadelphia: WB Saunders Company, 1 - 5.
- JENSEN B, WANG T (2009): *Hemodynamic consequences of cardiac malformations in two juvenile ball pythons (*Python regius*)*. *J. Zoo Wildlife Med.* **40**, 752 - 756.
- KALTER H (2003): *Teratology in the 20th century*. *Neurotoxicol. Teratol.* **25**, 131 - 282.
- LEIPOLD H (1980): *Congenital defects in zoo and wild mammals: a review*. In: Montali R, Migaki G (Eds.): *The Comparative Pathology of Zoo Animals*. Smithsonian Institution Press, Washington, 457 - 470.
- MAXIE MG, NEWMAN (2007): *SJ Urinary system*. In: Jubb KVF, Kennedy PC, Palmer NC: *Pathology of domestic animals*. Philadelphia: Elsevier, 425 - 522.
- ORÓS J, RODRÍGUEZ JL, MONTEROS A, RODRÍGUEZ F, HERRÁEZ P, FERNÁNDEZ, A (1997): *Tracheal malformation in a bicephalic honduran milk snake (*Lampropeltis hondurensis*) and subsequent fatal *Salmonella arizonae* infection*. *J. Zoo Wildlife Med.* **28**, 331 - 335.
- PALMIERI C, SELLERI P, Di GIROLAMO N, MONTANI A, DELLA SALDA L (2013): *Multiple congenital malformations in a dicephalic spur-thighed tortoise (*Testudo graeca iberica*)*. *J. Comp. Pathol.* **149**, 368 - 371.
- ROTHSCHILD BM, SCHULTZE H, PELLEGRINI R (2012): *Herpetological Osteopathology: Annotated Bibliography of Amphibians and Reptiles*. Springer: New York, 461.
- SANT'ANNA SS, GREGO KF, LORIGADOS C A B, FONSECA-PINTO ACBC, FERNANDES W, SÁ-ROCHA LC, CATÃO-DIAS JL (2013): *Malformations in neotropical viperids: qualitative and quantitative analysis*. *J. Comp. Pathol.* **149**, 503 - 508.
- SCOTT HH (1925): *Congenital malformations of the kidney in reptiles, birds, and mammals*. *J. Zool.* **95**, 1259 - 1269.
- WARKANY J (1947): *Etiology of congenital malformations*. *Adv. Pediatr.* **2**, 1 - 63.

Tab. 1: Main visceral alterations for each external malformation in pit vipers (*Bothrops jararaca*).

External malformation	Renal tubular dilation		Renal tubular cystic disease		Glomerulocystic disease n* (%)	Heterophilic coelomitis n* (%)	Heterophilic hepatitis n* (%)	Heterophilic myocarditis n* (%)	Heterophilic interstitial nephritis n* (%)	Heterophilic enteritis n* (%)	Heterophilic interstitial pneumonia n* (%)
	n* (%)	n* (%)	n* (%)	n* (%)							
Brachygnathia (n = 3)			2/3 (67)		2/3 (67)	1/3 (33)			1/3 (33)		
Buphthalmos (n = 5)							2/4 (50)				1/4 (25)
Harelip (n = 2)							1/2 (50)				
Hydrocephaly (n = 7)		1/7 (14)							1/7 (14)		1/7 (14)
Incomplete tail (n = 2)										1/1 (100)	
Kinked tail tip (n = 15)						1/15 (7)		1/12 (8,3)		1/12 (8)	1/9 (11)
Kyphoscoliosis (n = 10)			1/10 (10)				1/10 (10)		1/10 (10)	1/10 (10)	
Kyphosis (n = 14)								1/13 (7,7)			
Lordosis (n = 6)		1/5 (20)			1/5 (20)						
Micrognathia of upper maxilla (n = 2)							1/2 (50)				
Prognathism (n = 3)							1/3 (33)				
Schistosomia (n = 12)	3/11 (9)		1/11 (9)		1/11 (9)	1/12 (8)		1/12 (8,3)	2/11 (18)		
Scoliosis (n = 9)	1/6 (17)		1/6 (17)		1/6 (17)				1/6 (17)		

* Affected / analysed individuals

Tab. 2: Main visceral alterations for each external malformation in rattlesnakes (*Crotalus durissus*).

External malformations	Diffuse heterophilic epicarditis n* (%)	Renal congestion n* (%)	Renal tubular dilation n* (%)	Glomerulocystic disease n* (%)	Renal interstitial edema n* (%)
Kyphoscoliosis (n = 6)	1/5 (20)		1/5 (20)	1/5 (20)	
Kyphosis (n = 7)		1/6 (17)	3/6 (17)	2/6 (33)	1/6 (17)
Schistosomia (n = 1)	1/1 (100)			1/1 (100)	
Scoliosis (n = 8)		1/7 (14)	4/7 (14)	3/7 (43)	2/7 (29)

* Affected / analysed individuals

DISEASES OF THE SNAKE SPECTACLE

DA SILVA MO^{1,2}, BERTELSEN MF¹, HEEGAARD S^{2,3}, GARNER MM⁴

¹Copenhagen Zoo, Centre for Zoo and Wild Animal Health, Roskildevej 38, 1870 Frederiksberg, DENMARK; mds@zoo.dk

²University of Copenhagen, Dept. of Neuroscience and Pharmacology, Eye Pathology Institute, Frederiks V's vej 11, 2100 Copenhagen, DENMARK

³University of Copenhagen, Glostrup Hospital, Dept. of Ophthalmology, Nordre Ringvej 57, 2600 Glostrup, DENMARK

⁴Northwest ZooPath, 654 W. Main Street, Monroe, WA 98272, USA

The snake spectacle is an integumental structure that despite its transparency holds numerous blood vessels and nerves. Similarly to the skin, the spectacle may also suffer from disease. In captive snakes, environmental temperature and humidity along with terrarium hygiene are the husbandry factors most important to spectacle health.

In a retrospective study, the records of 5,500 snakes submitted to a private diagnostic service in the USA during the past 15 years were reviewed to identify snakes with disease affecting the spectacles. Eighty-one cases (1.5 %) were identified and reviewed histologically.

Fifty-eight snakes had bacteria, fungal hyphae and algae in the spectacle lesions. Thirteen snakes had retained layers of keratin, termed spectacul dysecdysis (SD). Five snakes had concurrent spectaculitis and SD. The eight snakes with SD that did not have spectaculitis had an otherwise normal spectacle but with at least three keratin layers. The keratin was withheld by crust formations on the inner surface of the periocular scales, sometimes due to mite infestation.

Another focal lesion observed was indentation of the spectacle. Conditions that were seen to affect the spectacle to a much lesser extent were systemic diseases, such as inclusion body disease, gout, myeloproliferative disease and lymphoma.

Overall, the prevalence of spectaculitis in necropsy specimens appears to be low.

ULTRASOUND UNDER WATER – FEATURING THE OLM (*PROTEUS ANGUINUS*)

HOLTZE S¹, LUKAC M², CIZELJ I³, HILDEBRANDT TB¹

¹Leibniz Institute for Zoo and Wildlife Research (IZW), Alfred-Kowalke-Str. 17, 10315 Berlin, GERMANY; holtze@izw-berlin.de

²Faculty of Veterinary Medicine, University of Zagreb, Heinzelova 55, Zagreb 10000, CROATIA

³Zagreb Zoo, Maksimirski perivoj b.b., Zagreb 10000, CROATIA

The olm (*Proteus anguinus*) is the only European solely cave-dwelling vertebrate. The species populates labyrinths of subterranean waterways in the Dinaric karst which are hardly accessible to humans. Therefore, data on distribution and numbers are scarce. Due to pollution and habitat degradation, this amphibian is classified as vulnerable on the IUCN Red List.

Olms have a surprisingly high life expectancy of over 70 years in captivity. Nonetheless, their reproductive success is severely restricted by i) a late sexual maturity at age 16.5, ii) infrequent reproduction (every 12.5 years) with iii) small clutch size (35.2 eggs), and iv) a low (~0.4) hatching rate. Captive breeding so far has only been observed in a semi-natural cave habitat in the French Pyrenees. To our knowledge, currently the only animals in captivity are located in Zagreb Zoo as a part of the Croatian “*Proteus anguinus* project”, aimed at increasing knowledge of the species. Partly they were captured from the wild and partly found and delivered to the zoo after having been flushed out of their cave systems due to high water levels during spring.

So far, little is known about the olm’s biology and physiology. Moreover, captive breeding programmes for maintenance and restoration of natural populations are highly desirable. To address these issues, we examined 13 individually housed captive olms at Zagreb Zoo via ultrasonography (Voluson I, GE healthcare, Austria; 4 - 12 MHz) and ultrasound biomicroscopy (Vevo 2001, Visualsonics, Canada; 70 MHz linear transducer; maximal resolution ~20 µm). As ultrasound under water can be performed without body contact, the animals were examined noninvasively at their usual ambient water temperature of 8°C. We determined general health status - captive animals display an elevated vulnerability to infections and mortality - as well as gender, reproductive status, and heart rate. In one deceased captive animal we performed necropsy and histologic sampling to verify our ultrasound findings. Their miniature size was challenging, however, the ultrasonographic appearance of inner organs was consistent with that of other amphibians.

All individuals (average weight 14.2 ± 5.2 g) with one exception were female; we identified a potential breeding pair, taking into consideration gonadal development and geographical origin (as possibly different subspecies exist). Different stages of lung development were observed, and several minor abnormalities noted in different organs. Gall bladder size was measured as an indicator of feeding status. In two individuals, dermal alterations were detected resembling those found in the deceased individual, which helped to initiate treatment earlier than usual. The heart rate (43.8 ± 5.5 bpm) was surprisingly high, given the species’ low metabolism at ambient temperature.

Ultrasound will be a useful non-invasive tool for the monitoring of health and reproductive status of olms and may be crucial for future captive breeding programmes; furthermore, it may provide interesting insights into physiological parameters such as digestion, heart rate and blood flow velocity.

ANDROGEN-SECRETING ADRENOCORTICAL TUMOR IN A FEMALE *PANTHERA LEO*

ALMAGRO V¹, HUZMAN M¹, FERNÁNDEZ-BELLON H¹, NOVELLAS R², CASANOVA I³, RAMIS T³

¹Parc Zoològic de Barcelona, Parc de la Ciutadella s/n. 08003, Barcelona, SPAIN;
valmagro@bsmsa.cat

²Universitat Autònoma de Barcelona, Dept. Animal Medicine and Surgery, 08193 Bellaterra, Barcelona, SPAIN

³Universitat Autònoma de Barcelona, Dept. Animal Health and Anatomy, 08193 Bellaterra, Barcelona, SPAIN

A 20 year old non-cycling female lion (*Panthera leo*) was observed to have grown a mane over a period of a few weeks. Ultrasound examination under anaesthesia evidenced a 12 cm solid mass of heterogeneous echogenicity which was situated cranially and medially to the left kidney. The rest of the abdominal ultrasound and thoracic X-ray examination showed no abnormalities.

A biopsy was performed during the next immobilisation and histopathology showed a possible adrenocortical carcinoma. Decreasing haematocrit values and increasing leukocytosis with neutrophilia were seen between the first and second blood tests. More over dehydroepiandrosterone (DHEAs) remained at high levels.

Taking into account the high probability of complications, surgery was not performed. Instead, metronomic therapy (cyclophosphamide 24 mg PO SID total dose; Oristà, Barcelona, Spain and piroxicam 20mg PO SID total dose; Feldene[®], Pfizer, Madrid, Spain) was attempted coupled with close monitoring of behaviour and feeding. However, cyclophosphamide had been stopped after six days due to vomiting episodes and piroxicam after 24 days because the animal refused the medication. After cyclophosphamide was stopped blood test showed that DHEAs decreased considerably. Six months after initial diagnosis, the lion developed sudden anorexia and lethargy. Euthanasia was performed after ultrasound examination showed widespread metastases in several organs. Necropsy and histopathological examination confirmed the adrenocortical carcinoma with metastases in the lung, liver and spleen. To our knowledge this is the first case of an androgen-secreting adrenocortical tumor in a female lion.

COMPUTED TOMOGRAPHY AND MAGNETIC RESONANCE IMAGING OF DOLPHIN PARAOTIC SINUSES

ALONSO-FARRÉ JM¹, GONZALO-ORDEN M², LLARENA-REINO M³, DEGOLLADA E⁴

¹Parc Zoològic de Barcelona, Parc de la Ciutadella s/n 08003, Barcelona, SPAIN;
jmalonso@bsmsa.cat

²University of León, Veterinary Faculty, Dept. of Animal Medicine, Surgery and Anatomy, Campus de Verganzana, 24071, León, SPAIN

³Marine Research Institute, CSIC, Dept. of Ecology and Biodiversity, C/Eduardo Cabello n°6, 36208 Vigo, SPAIN

⁴Autonomous University of Barcelona, Veterinary Faculty, Dept. of Anatomy and Embryology, Edifici V, Campus UAB, 08193 Bellaterra, SPAIN

The dolphin paraotic sinuses are relevant cavities within the head of the dolphin due to its relation with sound transmission process of the cetacean sonar. Parasitism of these air-filled structures has been described in numerous odontocete species; most of them as necropsy findings. Nematodes of the genus *Crassicauda* and trematodes of the genus *Nasitrema* have been reported causing severe lesions in these sinuses, and even death of some individuals. The diagnostic methods for its clinical evaluation are very limited and a laborious anatomical dissection is necessary to access to the paraotic sinuses in dead animals. With the aim to provide a reference guide for a clinical or pathological imaging of the dolphin air sinuses, thirteen dolphins and ten dolphin's heads belonging to three species: common dolphin (*Delphinus delphis*), striped dolphin (*Stenella coeruleoalba*) and bottlenose dolphin (*Tursiops truncatus*) were scanned by means of Computed Tomography (CT) and Magnetic Resonance Imaging (MRI). After the examinations, ten dolphins were frozen and cross-sectioned with a band saw. The paraotic sinuses were clearly visualised and identified in the CT and MRI scans, and the corresponding head sections. Furthermore, in one case, a massive infestation of *Crassicauda* sp. could be also described. The CT and MRI have resulted to be very useful for the exploration of the normal paraotic sinuses as well as the diagnosis of its parasitism, demonstrating the utility of these imaging techniques for the inspection and pathological evaluation of these structures presenting a difficult evaluation or access both *in vivo* and *post mortem*.

VETERINARY WORK IN A SEAL REHABILITATION CENTRE: MOTHERLESS PUPS, LUNGWORMS AND OTHER DISEASES IN SEALS

BAHR J

Robbenzentrum Föhr, Achtern Diek 5, 25938 Wyk auf Föhr, GERMANY; janine_insel@hotmail.com

Marine Mammal Rehabilitation Centres all around the world take care for motherless seal pups and injured conspecifics. This presentation will provide an overview on a complete rehabilitation programme, from First Aid measurements, over treatment and recovery right through to the release of the animal into its natural habitat. It will reflect the everyday work in such a centre for seals and other wildlife, and will highlight some extraordinary situations we have to face every day. The aim is to explain why the rehabilitation of wildlife has become a necessity. It shows the treatment which is available for weak, dehydrated or injured animals, or for those that suffer from infections. Finally, it depicts individual steps of care, which are applied in pursuit of our ultimate goal, the animal's health and release into its natural habitat.

As an example for an upcoming problem in the rehabilitation of North Sea seals is the infection with lungworms. Over the past four to five years, an increasing number of animals, especially from the tidal areas, have been found suffering from these parasites. The infection is predominantly affecting common seals (*Phoca vitulina*) but it is quickly spreading to grey seals (*Halichoerus grypus*) also. Lungworm infections are quite common in wildlife, but the number of severely diseased seals used to be low and increased only recently. Two main species of worms, small and large, have been identified from the affected animals: *Ostrongylus circumlitus* and *Parafilaroides gymnurus*. This is a very serious and highly dangerous development, which could have a devastating effect on the population of seals if further increasing by the same degree as it recently did. Studies in Great Britain revealed that even with normal weight seals have a very sensitive immune system. The reasons for the sudden increase and intensity of lungworm infections is still unknown. However, human intervention and the disturbance our modern way of life causes to the wildlife and their habitats might be a major reason. Overfishing, global warming, pollution of the seas and the environment – it all takes its toll. Rehabilitation in wildlife is an absolute necessity today and sadly, will most probably become ever more important in the future.

REPRODUCTIVE SEASONALITY AND NEWBORN MORTALITY AT THE NATIONAL ZOOLOGICAL GARDENS OF SOUTH AFRICA

BALSIGER A¹, KELLER S¹, ESPIE I², LANE EP², KOTZE A², CLAUSS M¹, CODRON D^{1,3}

¹University of Zurich, Vetsuisse Faculty, Clinic for Zoo Animals, Exotic Pets and Wildlife, Winterthurerstrasse 260, 8057 Zurich, SWITZERLAND; mclauss@vetclinics.uzh.ch

²National Zoological Gardens of South Africa, 232 Boom St, Pretoria, SOUTH AFRICA

³Florisbad Quaternary Research, National Museum, PO Box 266, Bloemfontein 9300, SOUTH AFRICA

Reproductive seasonality in wild animal species usually persists in captivity and may influence neonatal mortality. Using data from 1980 to 2012 of the National Zoological Gardens of South Africa, considering only species with more than 50 individuals in the database (24 artiodactyls, 13 carnivores, four primates, and the rock hyrax), birth seasonality, neonatal mortality, and several management effects were assessed. The data revealed that overall, there were seasonal differences in neonatal mortality, with peaks in the autumn/winter months. In artiodactyls, indeed, seasonal breeders usually had low (< 25 %) neonatal mortality; non-seasonal breeders had both low and high neonatal mortality, with no evident pattern between these groups except for a higher occurrence of the 'mismothering' category in the high mortality group. In carnivores and primates, seasonal breeding was evident in some species and was not linked to low neonatal mortality. Furthermore, in primates, the highest neonatal mortality was actually found in the strictest seasonal breeder. There were no systematic differences in density-dependent mortality between seasonal and non-seasonal breeders. Additional analyses showed that, hand-reared animals and neonates that were marked and received newborn treatment, both had significantly lower neonate mortalities than mother-reared and unmarked/untreated animals, confirming the soundness of these veterinary and husbandry measures to reduce neonatal mortality. The results suggest that, in captive artiodactyls, seasonal reproduction may have protective effects for newborns. The absence of such a pattern in carnivores and primates indicates husbandry regimes for these species that make them less susceptible to climatic influences than other animals.

This study was part of the Zoo Research Camp (ZRC) 2013 organised by the National Zoological Gardens of South Africa and the Vetsuisse Faculty, University of Zurich, Switzerland.

A RETROSPECTIVE STUDY OF MORTALITY IN CAPTIVE LIVINGSTONE'S FRUIT BATS (*PTEROPUS LIVINGSTONII*)

BARBON AR¹, FOUNTAIN K², ROUTH A¹

¹Durrell Wildlife Conservation Trust, Les Augres Manor, La Profonde Rue, Trinity, JE3 5BP, JERSEY; alberto.barbon@durrell.org

²Top Cat Veterinary Centre, 146 Mackie Avenue, Brighton, BN1 8SB, UK

Livingstone's fruit bat (*Pteropus livingstonii*) is an IUCN-listed endangered species endemic to the islands of Anjouan and Moheli in the Comoros Islands, which lie in the Indian Ocean between Africa and Madagascar. A captive breeding programme was started in 1993 at the Durrell Wildlife Park in Jersey due the population, currently estimated between 1,200 and 1,500 individuals, decline as a consequence of political instability, population growth and poverty in the islands contributing to widespread loss of the montane forest habitat of the bats through felling for cash crops and subsistence farming.

Pathology records of bats which died between 1993 and 2013 in the European captive population were examined and analysed by age group, cause of death and certain husbandry aspects, such as type of enclosure where specimens were housed.

The following causes of death were established: conspecific aggression, stillbirth/abortion, maternal neglect, congenital hypothyroidism, trauma, septicaemia, cardiomyopathy, neoplasia, welfare/arthrosis, pneumonia, encephalitis, renal failure and unknown cause.

Neonatal mortality, primarily due to conspecific aggression and still-birth accounted for a significant proportion of the mortalities recorded. The most common causes of death in adults were congestive heart failure and trauma. Housing changes introduced over the years appear to have reduced the mortality in the colony, but no significant differences were found between enclosures regarding certain causes of death such as abortions or trauma by conspecifics.

AORTIC VALVE COMMISSURES IN THE EUROPEAN BISON (*BISON BONASUS*)BARSZCZ K¹, OLBRYCH K¹, R} ŻŁ # SKA N¹, KŁPCZYŃSKA M¹, WARCHULSKA K²

¹Warsaw University of Life Sciences, Faculty of Veterinary Medicine, Dept. of Morphological Sciences, Nowoursynowska 159, 02-776 Warsaw, POLAND; karolina.barszcz@onet.eu

²Warsaw University of Life Sciences, Faculty of Veterinary Medicine, Dept. of Pathology and Veterinary Diagnostics, Nowoursynowska 159, 02-776 Warsaw, POLAND

In veterinary medicine new diagnostic methods, as coronarography and therapeutic methods, as aortic anuloplasty, are being introduced in both domestic and wild species. The study was performed on 17 hearts of adult European bison (*Bison bonasus*) of various ages and both sexes. Observations were performed with the use of Ecleris surgical microscope. Aortic valve morphology did not prove any differences relating to sex or individual features. It is composed of three semilunar leaflets: right, septal and left. Each of them has double-sided smooth surface with its convex part directed towards the chamber and concave part to the aortic lumen. Their characteristic shape allows formation of pocket spaces between the leaflets – these are aortic sinuses where coronary artery ostia are located. Approaching the aortic wall, fragments of free edges of neighbouring leaflets become closely adjoined. When they get fixed on the aortic wall they also get slightly forked. The structures – commissures – visibly differentiate. They were discovered between the following semilunar leaflets: the right and septal ones; the septal and left ones and the left and right ones. Considering clinical importance of these structures, some detailed changes are suggested: right aortic valve commissure (*commissura valvae aortae dextra*); left aortic valve commissure (*commissura valvae aortae sinistra*); intermediary aortic valve commissure (*commissura valvae aortae intermedia*). The present study provides basic data useful for e.g. angiography performed for diagnosis of cardiac diseases and as a basis for surgical interventions. The morphology of the aortic valve has clinical applications for procedures involving valve replacement.

SURGICAL REPAIR OF ATRESIA ANI AND RECTOVAGINAL FISTULA IN A CAPE BUFFALO (*SYNCERUS CAFFER CAFFER*)

BERNARDINO RI, FERNANDES TL

Jardim Zoológico e de Aclimação em Portugal, Estrada de Benfica, 158-160, 1549-004 Lisboa, PORTUGAL; ruibernardino@zoo.pt

Summary

A type II atresia ani associated with rectovaginal fistula* in a 5-week-old female Cape buffalo (*Syncerus caffer caffer*) was surgically repaired. Four months post-surgery the animal has a steady development, with a very good body condition and is passing normal faeces.

Introduction

Congenital anorectal malformations (ARMs) are seldom described in animals (FOWLER, 2008) and humans, with atresia ani being the most common one with an overall incidence not higher than 1 % in reported species (ELLISON et al., 2012; WIEDEMANN et al., 2005). In humans ARMs affect 1 in 4,000-5,000 births (BEUDEKER et al., 2013). In zoo and wild animals this malformation is even more scarcely described with sporadic cases referred in an alpaca (*Vicugna pacos*) (DEL CAMPO et al., 1993), a camel (*Camelus dromedarius*) (ANWAR and PUROHIT, 2012), a common squirrel monkey (*Saimiri sciureus*) (STILLS and BULLOCK, 1981), a tapir (*Tapirus* sp.) (JANSSEN et al., 1996), and presumably in a buffalo (MARLER et al., 1977). These references are primarily *post mortem* reports without information regarding surgical repair and consequent follow up.

Atresia ani is a congenital defect of the anorectum, resulting in anal canal closure and/or abnormal routing of faeces considered hereditary in species such as swines (WIEDEMANN et al., 2005), calves (STEENHAUT et al., 1976) and humans. This may be present as a unique condition or in conjunction with other malformations, namely in the intestinal and/or urogenital tract or affecting the distal vertebrae.

Case report

A 5 week old female Cape buffalo (*Syncerus caffer caffer*) was observed following the keepers information that the animal had difficulty passing faeces and formed a swelling in the perineal area while straining to defecate. A diagnosis of atresia ani associated with retrovaginal fistula was made under anaesthesia and promptly surgically repaired.

The calf was immobilised after tranquilisation of the mother with 100 mg azaperone (Stressnil® 40 mg/ml, Esteve Veterinária, Carnaxide, Portugal) administered by remote intramuscular (i.m.) injection. The calf's weight was estimated to be 60 kg and immobilising drugs were prepared accordingly. A combination of midazolam 0.01 mg/kg (Midazolam Hameln®, 5 mg/ml, Hikma Farmacêutica, Terrugem, Portugal), detomidine 0.01 mg/kg (Domidine®, 10 mg/ml, Divasa-Farmavic,

* Accordingly to small animal classification (ARONSON, 2003).

Vialonga, Portugal) and ketamine 3 mg/kg (Imalgene 1000, 100 mg/ml Merial, Rio de Mouro, Portugal) was initially administered by remote i.m. injection. The animal was left undisturbed, but 22 minutes later it was still very active and a second dart containing the same combination of drugs was administered. After the administration of supplemental 3 ml of Propofol i.v. (Propofol Lipuro 1 %, B Braun, Melsungen, Germany) and 1 ml of Ketamine i.v. (Imalgene 1000, 100 mg/ml Merial, Rio de Mouro, Portugal) we used a different combination of drugs that included 0.4 ml Immobilon[®] (Immobilon L.A.[®], Etorphine 2.45 mg/mL plus Acepromazine 10 mg/mL, Novartis Animal Health, Litlington, UK) and 0.35 ml xylazine (Rompun[®], 20 mg/ml, Bayer, Germany) i.m. After this, the animal was successfully intubated and maintained on 1.5 % isoflurane (Isoflo[®], Abbott Laboratories Lda., Berkshire, UK) throughout the procedure. Reversion of anaesthesia was accomplished by administering 0.4 ml diprenorphine i.v. (Revivon[®] 3.26 mg diprenorphine hydrochloride, Novartis Animal Health, Litlington, UK). Amoxicilin 15 mg/kg i.m. (Clamoxyl[®] LA, Pfizer, Seixal, Portugal) and flunixin meglumine 2.2 mg/kg i.m. (Fynadyne[®] 50 mg/ml, Schering-Plough, Ségre, France) were administered i.m. once pre-surgically.

For the surgical procedure the animal was positioned in ventral recumbency and a circular incision about two centimetres in diameter was made over the anal bulge (the external sphincter was not present) after the perineal area was prepared for aseptic surgery. The skin flap created was excised and a blunt dissection was continued into deeper plans to correctly expose the blind cull-de-sac of the rectum, after detached from adhesions. The rectum was mobilised through the new stoma (stay sutures can be used) and the rectal pouch was directly sutured to the subcutaneous tissue and skin (360 degrees) with monofilament absorbable (simple interrupted suture pattern; 2/0 polyamide, Dafilon[®], B Braun Aesculap, Tuttlingen, Germany) and non absorbable (simple interrupted suture pattern; 2/0 glyconate, Monosin[®], B Braun Aesculap, Tuttlingen, Germany) suture material respectively. Due to the possibility of contamination of subcutaneous tissues with faecal material it was decided to suture first the rectal pouch to the skin and lastly opening the rectal canal with scissor medially to the sutures.

The rectovaginal fistula opening was directly visualised through rigid vaginoscopy and a foley catheter 20 Fr (Romed[®] - Holland, Herenweg, NL) was positioned inside the fistula from the dorsal vaginal wall to the rectal lumen. The surgical repair was initiated with a vertical midline perineal incision (three to four centimetres) extending from the ventral reconstructed anus to the vulva. After isolation, the fistula was excised and the rectal and vulvar connection separately sutured with a simple continuous pattern (2/0 glyconate, Monosin[®], B Braun Aesculap, Tuttlingen, Germany). Subcutaneous tissue and skin were sutured also with a monofilament absorbable suture 2/0 through an intradermal suture for apposition of the skin incision. A final lavage was made in the vulva and vagina.

Post-operatively the animal began eliminating faeces through the reconstructed anal canal and was reintegrated with the mother in the same day of the procedure after complete recovery. Four months later the animal is in a very good corporal condition.

Discussion

In some cases of atresia ani, the presence of a rectovaginal fistula functions as a drain for the retained faeces making it possible to survive in the first months of age.

Surgical resolution can be considered in these cases and the approach varies according to the type of atresia ani since it should be taken into consideration the distance from the blind rectal pouch to the anal dimple and the presence of other malformations.

During the surgical reconstruction of the anal canal and anus the key points are the position and the diameter of aperture. It should be kept in mind that the outcome varies between stenosis and faecal

incontinence and that the patient is growing. When in doubt the smaller diameter should be the option, since it is a condition easier to adjust in the future. The assessment of the results is made through the growing period, particularly in heavier species.

It should be emphasised that this malformation was proved to be a hereditary condition in some species and so reproduction of these individuals is not recommended.

In zoo species congenital conditions can be challenging to diagnose, particularly in animals that are managed as a group.

Surgical correction in Cape buffalos with rectovaginal fistula and atresia ani may result in a favourable outcome if it is done relatively early.

References

- ANWAR S, PUROHIT GN (2012): Rare congenital absence of tail (anury) and anus (atresia ani) in male camel (*Camelus dromedarius*) calf. *Open Vet. J.* **2**, 69 - 71.
- AROSON L (2003): Diseases of the rectum and anus. In: Slatter Ded (Ed.): *Textbook of Small Animal Surgery*. 3rd ed. Philadelphia, Pennsylvania: Saunders WB, 682 - 708.
- AZIZI S, MOHAMMADI R, MOHAMMADPOUR I (2010): Surgical repair and management of congenital intestinal atresia in 68 calves. *Vet Surg.* **39**, 115 - 120.
- BEUDEKER N, BROADIS E, BORGSTEIN E, HEIJ HA (2013): The hidden mortality of imperforate anus. *Afr. J. Paediatr. Surg.* **10**, 302 - 306.
- DEL CAMPO CH, VITS L, DEL CAMPO MR, FERGUSON JG (1993): A case of atresia ani with rectovestibular fistulae in an alpaca (*L. pacos*). *Dtsch. Tierarztl. Wochenschr.* **100**, 495 - 497.
- DENNIS SM, LEIPOLD HW (1972): Atresia ani in sheep. *Vet. Rec.* **55**, 488 - 490.
- ELLISON GW, PAPAOGLOU LG (2012): Long-term results of surgery for atresia ani with or without anogenital malformations in puppies and a kitten: 12 cases (1983 - 2010). *J. Am. Vet. Med. Assoc.* **240**, 186 - 192.
- FOWLER ME (2008): Congenital and hereditary conditions in camelids. In: Fowler ME, Miller RE (Eds.): *Zoo and Wild Animal Medicine. Current Therapy 6*. W.B. Philadelphia: Saunders Company, 391 - 403.
- HARI KRISHNA NVV, DEVI PRASAD V, MALLIKHARJUNA RAO Ch (2009): Agenesis of vulva and terminal urethra with atresia ani et recti in a buffalo calf. *Buffalo Bulletin* **28**, 165 - 167.
- JANSSEN DL, RIDEOUT BA, EDWARDS ME (1996): Medical management of captive tapirs (*Tapirus sp.*). *Proc. Am. Assoc. Zoo Vet., Puerto Vallarta, Mexico*, 1 - 11.
- MARLER RJ, BAKER W, LEIPOLD HW, COOK JE, KRUCKENBERG SM (1977): Atresia ani and rectovaginal fistula in buffalo. *J. Am. Vet. Med. Assoc.* **171**, 988 - 989.
- RAHAL SC, VICENTE CS, MORTARI AC, MAMPRIM MJ, CAPORALLI EH (2007): Rectovaginal fistula with anal atresia in 5 dogs. *Can. Vet. J.* **48**, 827 - 830.
- STEENHAUT M, DE MOOR A, VERSCHOOTEN F, et al. (1976): Intestinal malformations in calves and their surgical correction. *Vet. Rec.* **98**, 131 - 133.
- STILLS JR HF, BULLOCK BC (1981): Congenital Defects of Squirrel Monkeys (*Saimiri sciureus*). *Vet. Pathol.* **18**, 29 - 36.
- WIEDEMANN S, FRIES R, THALLER G (2005): Genomewide Scan for Anal Atresia in Swine Identifies Linkage and Association with a Chromosome Region on *Sus scrofa* Chromosome 1. *Genetics* **171**, 1207 - 1217.

CASE REPORT ON WELFARE OF CAPTIVE TIGERS - ETHOLOGICAL AND PHYSIOLOGICAL PARAMETERS

BERTOCCHI M¹, SPIEZIO C², DI IANNI F¹, MACCHI E³, PARMIGIANI E¹, QUINTAVALLA F¹

¹University of Parma, Faculty of Veterinary Medicine, Animal Health Dept., Obstetric and Reproduction Unit, Via del Taglio 10, 43126 Parma, ITALY; mara.bertocchi@studenti.unipr.it

²Parco Natura Viva – Garda Zoological Park, Research and Conservation Dept., Località Figara 40, 37012 Bussolengo, VR, ITALY

³University of Turin, Faculty of Veterinary Medicine, Dept. of Veterinary Morphophysiology, Via Leonardo da Vinci 44, 10095 Grugliasco, TO, ITALY

In recent years animal welfare assessment methods have been developed which combine ethological and physiological parameters. Management of big cats in captivity appears to be particularly complex, these animals are indeed prone to develop behavioural problems. This study was performed to assess the welfare of a non-breeding pair of tigers (*Panthera tigris*), as the female was under contraception, using ethological and physiological parameters. The tigers were housed at an Italian zoological garden. During the day the animals were kept together in the outdoor enclosure, whereas overnight the tigers were individually housed. Twenty 45-min sessions for each subject were run. Focal animal sampling method was used to record individual and social behaviours; in addition faecal cortisol level was monitored by collecting faecal samples once a day from the two tigers: nine from the female and five from the male. The concentration of cortisol metabolites was determined by enzyme immunoassay (EIA). Single case analysis was run to analyse behavioural data and cortisol levels. Findings highlight that species-specific behaviours were performed by both animals. However significant differences between the two tigers were observed in stress-related behaviours ($P < 0.01$): the female showed stereotypical behaviour (pacing) whereas the male did not. No significant differences in faecal cortisol levels were observed ($P = 0.28$) although the female showed higher levels than the male. Results for both ethological and physiological parameters seem to indicate a poorer welfare status for the female than the male. Integrating physiological and ethological approach can be useful to assess animal welfare.

EFFECTS OF YOGURT DIETARY SUPPLEMENTATION ON THE INTESTINAL ECOSYSTEM OF A POPULATION OF EMPEROR TAMARINS (*SAGUINUS IMPERATOR*)

BIAGI G¹, PINNA C¹, RIGONI G¹, SPIEZIO C², SANDRI C²

¹University of Bologna, Dept. of Veterinary Medical Sciences (DIMEVET), via Tolara di Sopra 50, 40064 Ozzano Emilia, ITALY; giacomo.biagi@unibo.it

²Parco Natura Viva – Garda Zoological Park, Research and Conservation Dept. and Veterinary Dept., Località Figara 40, 37012 Bussolengo, VR, ITALY

It is well known that the consumption of yogurt by humans can exert several beneficial health effects mainly because fresh yogurt contains live lactic acid bacteria with probiotic properties. However, yogurt contains significant amounts of lactose that might be responsible for discomfort in lactose-intolerant individuals. Today, despite the fact that yogurt and cheese are used in laboratory animals' facilities and in some zoos as enrichment for nonhuman primates, little is known about the ability of these animals to tolerate the presence of lactose in their diet. The aim of the present study was to evaluate the effect of feeding fresh yogurt on the intestinal ecosystem of a population of adult emperor tamarins (*Saguinus imperator*). The study was conducted from December 2012 to February 2013 at Parco Natura Viva (Bussolengo, Italy). After a pre-adaptation period of 30 days of withdrawal of yogurt and fresh cheese from their diet (mainly consisting of various types of fruits with the addition of insect larvae as a source of protein), nine adult emperor tamarins received about 30 g of fresh yogurt per animal every two days for 28 days. On days 0, 21 and 28 of yogurt administration faecal samples were collected from each animal and immediately frozen for further analyses (pH, moisture, ammonia, volatile fatty acids - VFA, biogenic amines and bacterial populations). Data were analysed by one-way Anova with time as the main effect and the Newman-Keuls test was used as a post-hoc test; differences were considered significant at $P < 0.05$. All animals remained in good health throughout the study. Results are shown in table 1. Faecal pH and moisture were higher on day 21 than on day 0 but this difference was not observed on day 28. Faecal concentrations of ammonia, VFA and biogenic amines were not influenced by treatment with the only exception of spermine that was significantly reduced on days 21 and 28 compared with day 0. With regard to bacterial populations, numbers of faecal coliforms and enterococci were significantly lower on day 28 than on day 0. The present results show that tamarins tolerated the presence of yogurt in their diet well. However, ingestion of yogurt had only limited effects on animals' intestinal ecosystem. In particular, several differences observed between day 21 and day 28 suggest that longer-term monitoring for effects is warranted.

Tab. 1: Faecal analyses of emperor tamarins receiving the administration of fresh yogurt.

	T0 (d 0)	T1 (d 21)	T2 (d 28)	Anova P	SEM
pH	7.42ab	7.94b	6.78a	0.024	0.3
Moisture, %	81.6ab	85.4b	79.0a	0.041	16.2
Ammonia, mmol/l	119	111	108	0.135	3.8
Total VFA, mmol/l	95.4	82.6	92.4	0.633	9.6
Spermine, μ mol/l	30.1	16.4	4.4	0.047	6.6
Coliforms, cells/g	5.34b	4.95b	3.36a	0.017	0.2
<i>C. perfringens</i> , cells/g	4.12	4.11	3.63	0.500	0.1
Enterococci, cells/g	5.26b	4.78b	3.72a	0.005	0.3
Bifidobacteria, cells/g	7.61ab	7.42a	7.70b	0.041	0.1

Different letters within the same row indicate a significant difference ($P < 0.05$).

HYDROCEPHALUS INTERNUS IN AN AFRICAN GREY PARROT (*PSITTACUS ERITHACUS*)

BRAUN V¹, WÜST E², KRAMER M¹, SCHMIDT M¹

¹Justus-Liebig-University Giessen, Small Animal Clinic, Dept. of Veterinary Clinical Sciences, Frankfurter Str. 108, 35392 Giessen, GERMANY; Veronika.Braun@vetmed.uni-giessen.de

²Justus-Liebig-University Giessen, Clinic for Birds, Reptiles, Amphibians and Fish, Frankfurter Str. 91-93, 35392 Giessen, GERMANY

A 4 year old female African grey parrot (*Psittacus erithacus*) was initially presented with a two months history of weakness and regurgitation. The bird was presented emaciated and with a poor general condition. Based on clinical findings the bird became antifungal medication, showed improvement of clinical signs and was discharged home. After four weeks the bird was presented again with neurological signs such a tremor of the whole body and head tilt. Repeated microbiological investigation of crop and cloacal swabs showed multi resistant *E. coli* and suspected diagnosis was meningitis. The parrot this time was treated with terbinafin (Lamisil[®], Novartis Consumer Health GmbH, Munich, Germany) 0.15 ml orally BID, celecoxib (Celebrex[®], Pfizer, Illertissen, Germany) 0.25 ml BID, chloramphenicol (Chloromycetin[®], Pfizer Corporation, Vienna, Austria) 0.2 ml i.m. q8h and Ringer lactate/Glucose/vitamin B Infusion for two weeks without clinical improvement. Additionally the bird developed seizures, non responding to phenobarbital treatment. The owner desired no further diagnosis and the patient was decided to be euthanised.

Post mortem magnetic resonant imaging of the head was made using a human spine coil (Gyrosan NT von Philips Medical System, 1 Tesla, Syn Spine Coil). Sagittal, transverse and dorsal T2-weighted turbo spin echo (TSE) images were acquired. Sagittal images revealed a generalised enlargement of the subarachnoid space around the forebrain especially around the occipital lobes and the cerebellum. The CSF-space between the foliae cerebelli was distended. The dorsal and transverse images revealed moderately enlarged lateral ventricles that are normally hardly visible in birds. The aqueductus mesencephali was patent. The diagnosis of internal and external hydrocephalus was made. Based on the findings of the distended subarachnoid space and the patent aqueduct the malformation was classified as communicating hydrocephalus.

Pathological examination showed internal and external hydrocephalus with prominent rarefaction of neuropils and enlargement of ventricles with neuronal atrophy especially periventricular. Marked cerebellar atrophy in particular in the rostral lobe was seen. Histological examination revealed atrophy in the granular layer, Purkinje cells and molecular layer. No evidence for inflammatory or neoplastic cause of suspicious CSF obstruction was found. Inflammatory alteration such an acute endotoxic inflammation is without any cellular reaction but clinical signs were not acute onset and no anamnestic hints for intake of endotoxins were present. Initially cerebellar symptoms before seizures and underlying cerebellar atrophy (atrophy of Purkinje cells) could indicate degenerative changes followed by hydrocephalus ex vacuo. This is seen in canine degenerative disorders as neuraxonal dystrophy lipofuscinosis. However, no pathological findings for such disorder could be documented in this case. In absence of ependymal inflammatory reactions or changes in archachnoid granulations the underlying origin of impaired absorption of cerebrospinal fluid remains undetermined.

Literature reported hydrocephalus of unknown origin was previously reported in two grey parrots from which one suspected congenital hydrocephalus and another discuss potentially familial cause in grey parrots. Hydrocephalus due to vitamin A deficiency with segmentally hypertrophied arachnoid membrane was described in a mature Goffin's cockatoo. Another report shows hydrocephalus ex vacuo with encephalomalacia yellow-headed Amazon parrot.

DIAGNOSIS OF ALLERGIC DERMATITIS IN A SPOTTED HYAENA (*CROCUTA CROCUTA*)

BRAZIS P¹, PUIGDEMONT A², RAVERA I³, ALMAGRO V⁴, FERNÁNDEZ-BELLON H⁴

¹UNIVET Servicio de Diagnostico Veterinario s.l., Avda Cerdanyola, 92, 08172 Sant Cugat, Barcelona, SPAIN; pilar.brazis@univet.es

²Universitat Autònoma de Barcelona, Dept. Pharmacology of Therapeutic and Toxicology, 08193 Barcelona, SPAIN

³Universitat Autònoma de Barcelona, Dept. Animal Medicine and Surgery, 08193 Barcelona, SPAIN

⁴Parc Zoològic de Barcelona, Parc de la Ciutadella s/n., 08003 Barcelona, SPAIN

Summary

An adult spotted hyaena (*Crocota crocuta*) was presented with dermatological lesions which were deemed suggestive of allergic dermatitis based on clinical examination and response to glucocorticoid therapy. Both intradermal skin test and IgE serology against a standard allergen panel showed strong reaction to *Lepidoglyphus destructor* mite.

Case report

A 9 year old female spotted hyaena (*Crocota crocuta*) was presented with a history of pruritus and dermatological lesions primarily located in the muzzle. The patient was housed with a mate which remained clinically healthy. Dermatological examination showed a series of clean, well circumscribed ulcers in a linear distribution located at the medial *cantum* of the right eye, right cheek, and left forelimb. Microscopic examination of hairs and skin scrapings were unremarkable, showing scarce neutrophils and extracellular coccoid bacteria. Clinical presentation was non-seasonal and lesions remitted after corticosteroid treatment (1 mg/kg twice a day for two days and decreasing doses up to ten days; Urbason, Sanofi Aventis, Barcelona, Spain). A presumptive clinical diagnosis of allergic dermatitis was based on evidence of pruritus, clinical dermatological examination and good response to glucocorticoid trials.

Intradermal and serologic (IgE) tests were performed to assess and compare allergen specific responses in the allergic dermatitis. The animal was kept without any medication during one month prior to the skin and serological tests. These tests were performed with nine allergens (LETI, Barcelona, Spain) including mites (*Dermatophagoides farinae*, *Dermatophagoides pteronissinus*, *Lepidoglyphus destructor*, *Tyrophagus putrescentiae*), and pollens of trees (*Cupressus* spp., *Olea europaea*), weed (*Parietaria officinalis*) and grasses (*Dactylis glomerata*, *Graminea* mix). Antigens selected were the most frequent allergens in the animal environment at the test time. The hyaena was anaesthetised with midazolam (0.15 mg/kg IM Midazolam B. Braun, Braun, Melsungen, Germany), detomidine (0.05 mg/kg IM Domosedan, Esteve veterinaria, Barcelona, Spain) and ketamine (3 mg/kg IM Imalgene, Merial, Barcelona, Spain) and an area of 12 cm² (square area of 4 cm long x 3 cm wide approx.) in the abdominal region was clipped to perform the intradermal skin test. Fifty microliters of each allergen were injected intradermally, using bi-distilled water, PBS and histamine (0.1 mg/ml) respectively as negative and positive controls (ORDEIX et al., 2005). Cutaneous reactions were read 20 minutes after the injections. At the same time, blood samples were taken and submitted for evaluation by ELISA for allergen-specific IgE (Unitest, UNIVET SL, Barcelona, Spain) with a commercial

assay that uses a biotinylated anti-feline IgE antibody (Greer labs, Lenoir, USA) (LEE et al., 2012). This serological test included the same allergens already used for the intradermal test.

Intradermal test evidenced by cutaneous papules formation after the intradermal injection of the allergens a strong positive reaction to *Dermatophagoides farinae* and *Lepidoglyphus destructor*, and lower positive reactions to grass pollens and the rest of selected mites. Specific serologic test for feline IgE showed high IgE levels for grass pollens and *Lepidoglyphus destructor*, and weed pollens. Results obtained for intradermal and serologic tests showed a good correlation in the majority of allergens tested.

Oral immunotherapy has been prepared given the difficulty of performing subcutaneous injections in this species. This immunotherapy is currently being given, follow up for six months is necessary to evaluate response.

Conclusion

To our knowledge, this is the first time that a consistent serologic and intradermal test has been performed on a hyaena, confirming the clinical diagnosis of allergic dermatitis.

References

- LEE KW, BLANKENSHIP KD, MCCURRY ZM, MCKINNEY B, RUFFNER R, ESCH RE, TAMBONE C, FAAS R, HERMES D, BRAZIS P, DROUET L (2012): Intra and inter-laboratory reproducibility of a monoclonal antibody cocktail based ELISA for detection of allergen specific IgE in dogs: proficiency monitoring of macELISA in six laboratories. *Vet. Immunol. Immunopathol.* **148**, 267 - 75.
- ORDEIX L, SCARAMPELLA F, PUIGDEMONT A, BRAZIS P (2005): Comparison of intradermal and serum testing for allergen-specific IgE using an FcεR1α-based assay in allergic cats. *Vet. Dermatol.* **16**, 355.

ANAESTHETIC INDUCTION PROTOCOLS IN ARABIAN LEOPARDS (*PANTHERA PARDUS NIMR*)

BUDD J¹, LEWIS J², SOILEMETZIDOU S¹, WHITEHOUSE-TEDD K¹

¹Breeding Centre for Endangered Arabian Wildlife, P.O. Box 29922, Sharjah, UNITED ARAB EMIRATES; jane.budd@bceaw.ae

²International Zoo Veterinary Group, Station House, Parkwood St., Keighley, W. Yorkshire, BD21 4NQ, UK

The Breeding Centre for Endangered Arabian Wildlife (BCEAW) was purpose built for breeding regionally endangered wildlife, and also holds the international studbook for the critically endangered Arabian leopard (*Panthera pardus nimr*). With a current collection of 30 Arabian leopards, and having successfully produced 40 cubs to date, the veterinary department has collected biological and veterinary data for this species over the past 15 years. In order to achieve the highest possible standard of veterinary care for these leopards, the BCEAW has implemented regular reviews of its protocols. Three immobilisation protocols are reported here, with the aim of identifying the most appropriate regime for anaesthetic induction and characterising physiological parameters for leopards whilst under anaesthesia.

Medetomidine (70 µg/kg body weight (BW), Kyron Prescriptions CC, Johannesburg, South Africa) and ketamine (3 mg/kg BW, Troy Laboratories Pty Ltd, Glendenning, Australia) were used in combination in Protocol A, medetomidine was given 10 to 15 minutes before ketamine in protocol B, and medetomidine, butorphanol (0.2 mg/kg BW, Troy Laboratories Pty Ltd, Glendenning, Australia) and midazolam (0.15 mg/kg BW, Kyron Prescriptions CC, Johannesburg, South Africa) were used in combination in Protocol C. All drugs were administered via remote intramuscular injection using Telinject blow darts. Once immobilised, the leopards were maintained on isoflurane (Baxter, Deerefield, USA) for the duration of the required procedure. Data was collected opportunistically during either routine general health examinations (typically conducted annually) or when animals were presented with veterinary conditions requiring anaesthesia. The time taken for induction, quality of induction and any adverse reactions during induction was recorded. Once immobilised, the leopards' vital signs were monitored regularly throughout the procedure and parameters recorded. In total, 81 events are included in this report.

Mean time to induction varied according to protocol. Medetomidine followed after ten minutes by ketamine was judged to be an inappropriate method because immobilisation was markedly prolonged compared with Protocols A and C, risking hyperthermia if used in extreme ambient temperatures. Physiological parameters under anaesthesia are currently being analysed and will be presented as part of the poster.

CORTICOSTERONE DETERMINATION IN SHED SKINS FROM LIZARDS AND SNAKES: A POTENTIAL TOOL FOR ASSESSING CHRONIC STRESS

CABAJAL A¹, FERNÁNDEZ-BELLON H², TALLÓ-PARRA O¹, ALMAGRO V²,
SABÉS-ALSINA M¹, LÓPEZ-BÉJAR M¹

¹Universitat Autònoma de Barcelona, Dept. Animal Health and Anatomy, 08193 Bellaterra, Barcelona, SPAIN; manel.lopez.bejar@uab.cat

²Parc Zoològic de Barcelona, Parc de la Ciutadella s/n. 08003, Barcelona, SPAIN

Measurement of glucocorticoid hormones as indirect indicators of stress for welfare evaluation is well documented in mammals and birds. The objective of this study was to evaluate concentration of corticosterone (CORT), the major glucocorticoid in reptiles, in shed skins from captive reptiles. Lizard scales (n = 11) and snake shed skins (n = 10) opportunistically collected over a six month period at Barcelona Zoo were included in this study. A total of 14 species (6 lizard species, 8 snake species) belonging to 9 families were represented. After methanol extraction, corticosterone and validation tests were performed using a commercial enzyme immunoassay corticosterone detection kit (Neogen[®] Corporation, Lexington KY, USA). In the validation assays, the mean rate of hormone recovery was 125.9 ± 20.6 %, serial dilutions of a sample pool showed parallelism in relation to the CORT standard curve, sensitivity of the test was 0.04 ng and the intrassay error was 7.3 %. Corticosterone was detected in all the samples analysed. Corticosterone concentrations (mean \pm SD) were 18.23 ± 14.95 pg CORT/mg in lizards and 19.58 ± 7.21 pg CORT/mg in snakes. Whereas most specimens clustered around the mean for each group, three specimens from each group showed markedly higher levels of corticosterone than their groupmates ($>$ mean + SD). These comparatively elevated levels in corticosterone accumulation in some specimens suggest this method is a potential indicator of chronic stress and of welfare (as cortisol is in mammals) in this often overlooked taxonomic group.

EFFECT OF DESLORELIN IMPLANTS ON THE TESTICULAR FUNCTION IN MALE RING-TAILED LEMURS (*LEMUR CATT*A)

CASARES M¹, GERIQUE AC¹, CARBAJAL A², TALLÓ-PARRA O², SABES-ALSINA M²,
CARBONELL MD¹, LOPEZ-BEJAR M²

¹Bioparc Valencia, Avda Pío Baroja 3, 46015 Valencia, SPAIN; miguel.casares@bioparcvalencia.es

²Universitat Autònoma de Barcelona, Dept. of Animal Health and Anatomy, 08193 Bellaterra, SPAIN

Ring-tailed lemurs (*Lemur catta*) are popular exhibit animals in zoos. They live in multimale-multifemale groups with one alpha female. Males may fight strongly during the breeding season (spring), and this may end with serious wounds and/or escapes of displaced males out of the enclosure. At Bioparc Valencia, a group of 12 ring-tailed lemurs (9 males and 3 females) is kept in a large "walk-through" enclosure. As intragroup aggression in spring produces regularly escapes of males, it was decided to castrate five adult males. Castration of immature males has already been used as a management tool in ring-tailed lemurs. However, the sudden drop of testosterone (T) levels on more than half of the adult males of the group due to the surgical castration may have an effect on group dynamics. Thus, 4.7 mg deslorelin implants (Suprelorin[®], Virbac, Carros, France) were administered 5.5 months before the castration in order to produce a gradual reduction of T concentrations. The age of the males at the time the implants were administered ranged between 24 months (1x), and 4 to 6 years (4x). The contraceptive deslorelin is a long-lasting gonadotropin releasing hormone (GnRH) analog, which has been applied in males of some species for reducing the aggressive behaviour and T concentration, but its effectiveness may vary widely between species and individuals. The goal of this study was to analyse the effect of deslorelin implants on testicular function in five male ring-tailed lemurs by (i) monitoring faecal T values in weekly samples; and (ii) histological examination of the testicles after castration. Faecal samples were stored at -20°C until steroid extraction via methanol and the subsequent use of a commercial testosterone EIA kit (Neogen Corporation, Lexington, USA). Testicles and epididyma were examined (haematoxylin and eosin stain) for assessing spermatogenesis and presence or absence of sperm cells in epididyma. Overall, all the treated males showed a reduction in testosterone metabolites in faeces one month after implant administration (0.55 ± 0.18 vs. 0.33 ± 0.14 ng/100 mg), but levels were restored two months after the implant (0.55 ± 0.26 ng/100 mg) and maintained until castration (0.61 ± 0.18 ng/100 mg). However, the decreased testosterone levels after the implant remained low over time until castration only in one 4 year old male. Histologically, the testicles of the youngest male did not show active spermatogenesis, and its seminiferous tubules were compact, without lumen, and only spermatogonias were detected. Another male, the one with testosterone levels decreased, showed moderate spermatogenesis with intermediate germ cells in the lumen but without the presence of mature spermatozoa in tubules or epididyma. The remaining three males showed normal spermatogenesis with abundant spermatozoa in tubules and epididyma. As a preliminary conclusion, 4.7 mg deslorelin implants might have some effect on the testicular physiology when applied in young adult ring-tailed males, but has little or no effect when applied in adult males over four years of age. No obvious effect on the behaviour of the animals and the group dynamics was observed during this period. To the authors' knowledge this is the first report on the use of deslorelin implants in ring-tailed lemurs.

Acknowledgements

This study is funded by Fundacion Bioparc (Investigacion Veterinaria 2013).

HEALTH ASSESSMENT OF FREE-LIVING MUTE SWANS (*CYGNUS OLOR*)

DOLKA B¹, WŁODARCZYK R², ŻBIKOWSKI A¹, SZELESZCZUK P¹, LEDNIA A¹

¹Warsaw University of Life Sciences (WULS-SGGW), Faculty of Veterinary Medicine, Dept. of Pathology and Veterinary Diagnostics, Nowoursynowska 159c St., 02-776 Warsaw, POLAND;
beata_dolka@sggw.pl

²University of Lodz, Faculty of Biology and Environmental Protection, Dept. of Teacher Training and Biodiversity Studies, Banacha 1/3 St., 90-237 Lodz, POLAND

Summary

Clinical examination was performed on free-living mute swans (*Cygnus olor*) in Poland. The health assessment included physical examinations, weighing, haematology, microbiology, parasites identification. Samples were collected for avian influenza viruses (AIV) and Newcastle disease virus (NDV) screening. We used serological tests for detection of antibodies against AIV including H5 subtype and NDV. Body mass and the results of haematology were in normal ranges for swans and appropriate for the current season. All examined swans were negative for AIV and NDV, as well as for antibodies against these viruses. In total 30 % of examined swans were affected with gastrointestinal parasites. Microbiological analyses on cloacal swabs showed mainly *E. coli*, *Streptococcus* sp., *Aeromonas hydrophila*, and *Candida* sp., *Aspergillus* sp. No *Salmonella* sp. were found in the specimens. Based on clinical findings and results of laboratory tests, the general health of these mute swans was rated as good and the carriage of zoonotic agents as low.

Introduction

Mute swans (*Cygnus olor*) are water birds, belong to order Anseriformes. Since the 20th century the population growth rate has been observed in many countries. Previously, mute swans were typically migratory, nowadays they are becoming more sedentary. In recent years, an increasing number of wintering swans has been recorded in the cities, even close to human settlements (WŁODARCZYK and WOJCIECHOWSKI, 2001; WIELOCH et al., 2004). Some of the swans were delivered to zoos, bird-sanctuaries or veterinary clinics after accidents or found in exhausted state. According to the literature, several pathogens associated with wild birds may be transmissible to humans. Wild anseriformes are considered as reservoir hosts of all AIV and NDV and may spread these viruses to poultry (TSIODRAS et al., 2008). During recent epidemics of highly pathogenic avian influenza (HPAI) in Europe (2005 - 2006) mute swan were found very susceptible to infection with H5N1 virus and provided good sentinels (FEARE, 2010). In the literature, there is a lot of data on pathology of mute swans, on the other hand there is still lack of information concerning clinical aspects of this swan species. The aim of the study was to assess the health status of wild mute swans from selected natural habitats located in the center part of Poland.

Material and methods

Ninety-five free-living mute swans were captured during moulting season and in early spring from their natural habitats in central Poland. Swans were weighed and vent-sexed. Blood samples were taken for haematology (CAMPBELL and ELLIS, 2007) and serology. Cloacal and oral swabs (n = 31) were

cultured for bacteria and fungi which were identified by API-systems (bioMérieux, Marcy-l'Étoile, France) for Enterobacteriaceae and yeasts. Cloacal and tracheal swabs (n = 22) were used for detection of AIV in Real-Time RT-PCR/M/H5 and RT-PCR/H5 (SPACKMAN et al., 2002; SLOMKA et al., 2007). Cloacal swabs (n = 11) were tested for NDV in RT-PCR (CREELAN et al., 2002). Serological tests were used for detection antibodies against AIV/H5 (AGID, HI, FlockChek AI MultiS-Screen Ab Test Kit, IDEXX Laboratories Inc., Westbrook, USA) and NDV (HI). Parasitological examination included direct faecal smears and flotation method (n = 40) as well as feathers inspection. Swans were identified by ornithological rings and immediately after processing released to their habitats.

Results and discussion

Sex ratio of the examined mute swans was balanced (46 males, 48.4 %; 49 females, 51.6 %). This was also given in the respective age groups: adults (24 males, 25 females), immature birds (14 males, 19 females), cygnets (8 males, 5 females). None of the birds showed clinical signs of diseases. In few individuals we diagnosed leg lesions and in one swan foot web and interphalangeal joints necrosis. Similarly lesions were described by YATES et al. (1969). Mean body mass of mute swans was 9.1 ± 0.2 kg. We showed statistically significant gender-differences in body mass among adult and immature swans and no differences among cygnets. Adult males were heavier than adult females by 1.7 kg, immature males were heavier than immature females by 1.6 kg. Among cygnets the difference in body mass was 1.1 kg. According to literature there are many factors that may influence the body weight (BACON and COLEMAN, 1986; RITCHIE et al., 1994). Blood parameters (RBC, Ht, Hb, WBC, leukogram) were in normal ranges for swans and appropriate for the current season (O'HALLORAN et al., 1988; TULLY et al., 2000). In our study, microbiological analyses of cloacal swabs showed mainly *E. coli*, *Streptococcus* spp., *Aeromonas hydrophila*, *Kluyvera* sp. and no *Salmonella* sp. According to the literature, a range of bacterial pathogens affecting humans has been associated with wild birds (WATABE et al., 2004; TSIODRAS et al., 2008). We isolated from cloacal swabs *Candida* sp., *Aspergillus* sp., *Saccharomyces cerevisiae*. All detected microorganisms belong to physiological flora, but may also act as pathogens (WATABE et al., 2004; DYNOWSKA et al., 2013). Our results were consistent with others authors, that wild birds living in the proximate vicinity of man may constitutes a rich reservoir of potentially-pathogenic fungi (TSIODRAS et al., 2008; DYNOWSKA et al., 2013). In the available literature there are evidences suggesting role of wild birds in transmission of AIV. There is only one confirmed case where mute swans have been implicated in direct transmission of HPAI H5N1 virus to humans (YAMAMOTO et al., 2009). However, direct transmission of infectious agents from wild birds to humans was rarely identified. On the basis of our results obtained by PCR techniques we concluded that examined swans were free from AIV including H5 subtype and NDV. No serum antibodies to the AIV (negative in AGID, ELISA S/N 0.68) and AIV/H5, NDV (HI <1/16) were found. We showed that 30 % swans were infected with gastrointestinal nematodes (*Amidostomum anseris*); 66.6 % of them belonged to cygnets and immature swans. However, the infection rate was estimated as low. We found a low degree of ectoparasite load with *Trinoton anserinum* lice (order Phthiraptera). Our results showed good health status of examined mute swans living in the wild. This work may be a source of knowledge about the normal and physiological parameters of mute swans. Further research focused mainly on zoonotic agents associated with mute swans is needed.

Acknowledgements

The work was carried out under the Ethics Committee Agreement (no. 22/2007, 46/2007) and Ministry of Environment (Poland) approval (DKFOP-ogiz-4200/III-110/ 6279,9220/08/aj). This scientific work

was co-financed by the European Social Fund (ESF) and the national budget within Integrated Regional Operational Programme (IROP), Action 2.6 “Regional Strategy for Innovation and Transfer of Knowledge”, own project Mazowieckie voivodeship “Punjab Doctoral Scholarship” (no. 0547/3).

References

- BACON PJ, COLEMAN AE (1986): *An analysis of weight changes in the Mute Swan (Cygnus olor)*. *Bird Study*. **33**, 145 - 158
- CAMPBELL TW, ELLIS CK (2007): *Avian and Exotic Animal Hematology and Cytology, 3rd Edn*. Blackwell Publishing, USA.
- CREELAN JL, GRAHAM DA, MCCULLOUGH SJ (2002): *Detection and differentiation of pathogenicity of avian paramyxovirus serotype 1 from field cases using one – step reverse transcriptase – polymerase chain reaction*. *Avian Pathol*. **31**, 493 - 499.
- DYNOWSKA M, MEISSNER W, PACYŃSKA J (2013): *Mallard duck (Anas platyrhynchos) as a potential link in the epidemiological chain mycoses originating from water reservoirs*. *Bull. Vet. Inst. Pulawy*. **57**, 323 - 328.
- FEARE CJ (2010): *Role of wild birds in the spread of highly pathogenic avian influenza virus H5N1 and implications for global surveillance*. *Avian Dis*. **54**, 201 - 212.
- O'HALLORAN J, DUGGAN PF, MYERS AA (1988): *Biochemical and haematological values for mute swans (Cygnus olor): Effects of acute lead poisoning*. *Avian Pathol*. **17**, 667 - 678.
- RITCHIE BW, HARRISON GJ, HARRISON LR (1994): *Avian Medicine: Principles and Application*. Wingers Publishing, Florida.
- SLOMKA MJ, PAVLIDIS T, BANKS J, SHELL W, MCNALLY A, ESSEN S, BROWN IH (2007): *Validated H5 Eurasian real – time reverse transcriptase – polymerase chain reaction and its application in H5N1 outbreaks in 2005 – 2006*. *Avian Dis*. **51**, 373 - 377.
- SPACKMAN E, SENNE D A, MYERS TJ, BULAGA LL, GARBER LP, PERDUE ML, LOHMAN K, DAUM LT, SUAREZ D L (2002): *Development of a real time reverse transcriptase PCR assay for type A influenza virus and the avian H5 and H7 haemagglutination subtypes*. *J. Clin. Microbiol*. **40**, 3256 – 3260.
- TSIODRAS S, KELESIDIS T, KELESIDIS I, BAUCHINGER U, FALAGAS ME (2008): *Human infections associated with wild birds*. *J. Infect*. **56**, 83 - 98.
- TULLY TN, LAWTON MPC, DORRESTEIN GM (2000): *Avian medicine*. Butterworth Heinemann, Oxford, 246 - 247.
- WATABE M, SEKIZUKA T, MILLAR BC, ROONEY PJ, MOORE JE, MATSUDA M, XIAO L, LOWERY CJ, DOOLEY JS, RAO JR (2004): *Investigation of faecal pathogens in a flock of mute swans (Cygnus olor)*. *Vet Rec*. **154**, 279 - 280.
- WŁODARCZYK R, WOJCIECHOWSKI Z (2001): *The breeding ecology of the Mute swan Cygnus olor in central Poland*. *Wildfowl*. **52**, 157 - 168.
- YAMAMOTO Y, NAKAMURA K, YAMADA M, ITO T (2009): *Zoonotic risk for influenza A (H5N1) infection in wild swan feathers*. *J. Vet. Med. Sci*. **71**, 1549 - 1551.
- YATES VJ, MILLER LT, JASTY V, WILLEY CH, HOLTZINGER M (1969): *Web necrosis in Mute swans - a report of an outbreak*. *Bull. Wildl. Dis. Ass*. **5**, 33 - 34.

PRELIMINARY INVESTIGATION OF *STAPHYLOCOCCUS AUREUS* CARRIAGE IN ZOO VETERINARIANS IN FRANCE

DOUAY G¹, TASSE J², BERTUCAT V², SIMONIN C², BES M², LAURENT F²

¹Zoo de Lyon - Mairie de Lyon, 69205 Lyon Cedex 01, FRANCE; guillaume.douay@mairie-lyon.fr

²French National Reference Centre for Staphylococci, International Centre for Infectiology Research - Inserm U1111, Hospices Civils de Lyon, 69002 Lyon, FRANCE

Staphylococcus aureus has been found to colonise a large kind of animal species. It has been well established that veterinarians have a major risk of colonisation by Livestock-Associated MRSA (LA-MRSA) due to occupational exposure. Here, we screened nasal carriage of *S.aureus* in zoo veterinarians during the annual conference of the "Association Francophone des Vétérinaires de Parc Zoologique", to evaluate the prevalence of these bacteria and a possible zoonotic transmission.

Nasal swabs were collected from 29 zoo veterinarians attending the conference and inoculated into a pre-enrichment medium containing Brain-Heart broth with 5 % NaCl to allow *Staphylococcus* spp. selection. After overnight incubation at 37°C, 100 µl of broth were streaked on SAID agar (bioMérieux, Marcy l'Etoile, France), a chromogenic media on which *S. aureus* gives blue colonies. Suspected *S. aureus* colonies were subcultured on blood agar and identification was confirmed by MALDI-TOF (Vitek MS, bioMérieux, Marcy l'Etoile, France). All *S. aureus* isolates were tested by PCR for the presence of *nuc* gene (a species-specific marker), *mecA* and *mecC* genes (encoding methicillin resistance). Genetic characterisation of strains was performed using DNA microarray (StaphyType, Alere, Jena, Germany).

S. aureus were isolated in 11 out of 29 zoo veterinarians (38 %) among which two isolates were MRSA (18 %). MSSA strains belonged to the clonal complex 8 (CC8) (n = 2), CC30 (n = 2), CC97 (n = 1), CC5 (n = 1), CC6 (n = 1), CC398 (n = 1) and CC101 (n = 1). Interestingly, this last CC has been detected in French only in turkeys in Brittany from where also the veterinarian carriers came from.

MRSA strains belonged to clonal complex CC5, a classical human hospital-acquired clone and CC398, a classical livestock-associated clone. Of note, the CC398-MRSA isolate harbored tet(M) signing CC398 animal clade but also *sak*, *chp*, and *scn* genes that are classically associated to human SA clones, which suggest an interesting and worrisome humanisation of this animal isolate.

The prevalence of nasal carriage of SA, and among them the prevalence of MRSA, in zoo veterinarians was rather higher than in French population. Characterisation of strains demonstrates possible transmission from animal to human, which should prompt hygiene and individual protection measures during animal care. Based on the interesting data from this preliminary study, a larger investigation in French veterinarians and caregivers in zoos is planned.

FACIAL MELANOCYTOMA IN AN AXOLOTL (*AMBYSTOMA MEXICANUM*)

FERNANDES TL¹, BERNARDINO RI¹, PELETEIRO C²

¹Jardim Zoológico e de Aclimação em Portugal, Estrada de Benfica, 158-160, 1549-004 Lisboa, PORTUGAL; teresalf@zoo.pt

²Faculdade de Medicina Veterinária, Universidade Técnica de Lisboa, PORTUGAL

A spontaneous neoplasia with rapid growth developed in the rostrum of a captive held axolotl (*Ambystoma mexicanum*). This report describes the surgical procedure and pathology of the reported tumour.

The axolotl mentioned in this case is an 8 year old animal, kept in the reptile house at the Lisbon Zoo. The animal was immobilised in an isoflurane bath (0.28 ml Isoflurane/10 ml bath; IsoFlo[®], Abbott Laboratories, Berkshire, UK) and undergone surgery to remove the neoplasia. The nodule was excised (1 cm in diameter) using fine surgical instruments. The debridement revealed a mild haemorrhagic procedure and haemostasis was achieved with sterile swabs and a delicate electrocauter (Jorgensen Labs, Loveland, USA). The nodule localisation was over the right mandible and the surgical excision exposed the bone. Partial apposition of the tissues was possible after undermining and approximating the edges (far-far-near-near suture pattern; 4-0 polyamide, Dafilon[®] B Braun Aesculap, Tuttlingen, Germany). Based on the high regenerative capabilities of the species the exposed tissues (i.e. part of the mandible bone) healed uneventfully. Histologically, the mass was formed by densely packed large melanin containing cells with thin cytoplasmic projections. After melanin removal it was possible to see that cell boundaries were indistinct and nuclear polymorphism very marked, varying from 20 to 60 µm in diameter. No mitotic cells were seen. The tumour was classified as a melanocytoma of the facial skin.

Skin tumours of amphibians are one or a few cases among hundreds or thousands of amphibians and have been scarcely mentioned in literature, moreover, if published, some references are more than 20 years old. Due to the lack of up to date information and of clinical and surgical outcome of similar conditions, publication of such case reports is needed.

THE IMPORTANCE OF GASTRIC CYTOLOGY IN BOTTLENOSE DOLPHINS UNDER HUMAN CARE

FIORUCCI L¹, GRANDE F¹, FLANAGAN C², SILVA J², URBANI N², SAMPAYO J³, MACRELLI R⁴

¹Zoomarine Italia, Via Casablanca n.61, 00040 Pomezia, (Rome), ITALY; veterinari@zoomarine.it

²Mundo Aquatico S.A. - Zoomarine - Est. Nacional 125, Cortelhas, Guia, 8201-864 Albufeira, PORTUGAL

³Veterinary Endoscopy Support, Madrid, SPAIN

⁴Università di Urbino, Via T. Vitti n.10, 61029 Urbino (PU), ITALY

Preventive medicine of the digestive system in dolphins is fundamental to ensure the welfare of these animals under human care. Inappropriate diet, social problems, infectious diseases and stress can play an important role in the development of digestive system pathology.

This study aimed to establish a reference baseline data for normal cytological findings (pH, epithelial cells, leucocytes) in gastric samples of healthy bottlenose dolphins (*Tursiops truncatus*), following the "Guidelines for the determination of reference intervals in veterinary species" issued by the Quality Assurance and Laboratory Standards Committee.

From 2006 to 2012, 62 endoscopies were performed and gastric samples were collected from the forestomach of 21 dolphins kept under human care. The animals were considered healthy based on physical examination, laboratory evaluation (CBC, serum chemistry, proteinogram and faecal analysis) and histological assessment of the mucosa of the first chamber (biopsy performed by endoscopy). Animals during pregnancy were not considered.

Results show that pH was moderately correlated with the epithelial cells mean values ($r_s = 0.493$, $P = 0.0272$), but no such correlation was found with WBC mean values ($r_s = 0.049$, $P = 0.8369$). The Mann-Whitney test did not find a significant difference for weight ($P = 0.1237$), pH ($P = 0.8775$), epithelial cells mean ($P = 0.1473$), WBC mean ($P = 0.1269$) between sexes.

BEAR WATCHING FOR FOOT AND SPINE OSTEOPATHOLOGY CORRELATION IN CAPTIVE BEARS (*URSIDAE*)

GALATEANU G, GÖRITZ F, SARAGUSTY J, SZENTIKS CA, WIBBELT G, HILDEBRANDT TB

Leibniz Institute for Zoo and Wildlife Research (IZW), Alfred-Kowalke-Str. 17, 10315 Berlin, GERMANY; galateanu@izw-berlin.de

Summary

Spine pathology in Ursidae is well-recognised malady that has been established using radiography and *post mortem* examinations. No information exists regarding the use of computed tomography (CT) in assessing vertebral pathologies in Ursidae. This study ascertains and describes CT imaging findings in bears with distal limb osteopathologies and correlates these findings with vertebral column pathologies. Limb lesions appear to have a significant association with spinal lesions. Thus, lameness and radiographic examination of the distal limb may point to bone lesions in the vertebral column that might otherwise go unnoticed. A greater understanding of this inter-lesion relationship and its exact aetiology in bears may suggest possible targeted preventive measures and ways to improve animal health and welfare. At any rate, future studies may seal the case if, due to their broad availability as diagnostic tool, foot radiographs can be used for initial screening in Ursidae' spondyloarthropathy.

Introduction

Previous descriptions of spondyloarthropathy identified in bears *post mortem* suggest that this disease showed the highest prevalence in Ursidae compared to other captive wild animals (27 % to 97 % of captive bears) (KITCHENER, 2004; NUNN et al., 2007). While research has focussed on spinal lesions (NUNN et al., 2007; WAGNER et al., 2005), foot arthrosis yet is considerably less described (FÖLLMI, 2005). Vertebral column pathology in Ursidae may be subclinical (BOURNE et al., 2010) and should be considered in bears showing non-specific symptoms such as apathy, diminished appetite, or sudden irritability. Non-assessed and, consequently, untreated spine afflictions may result in severe health deterioration of the animal, followed by conflicts with the den mates which often end deadly for the weakened animal. Nevertheless, due to difficulties in performing and interpreting spinal radiographs in these large animals, vertebral lesions are often under-diagnosed. This retrospective study aimed to assess a valid clinical method for the detection of spinal disease and determination whether or not there is a correlation between vertebral lesions and other skeletal osteopathologies.

Material and methods

A comparative and high resolution (128-slice) computed tomographic (CT) study was performed. The study included the following species and subspecies: Eurasian brown bear (*Ursus arctos arctos*, n = 1), Syrian brown bear (*Ursus arctos syriacus*, n = 1), American black bear (*Ursus americanus*, n = 2), polar bear (*Ursus maritimus*, n = 2), spectacled bear (*Tremarctos ornatus*, n = 1), and giant panda (*Ailuropoda melanoleuca*, n = 1). Body weight of all animals was within the normal range for their respective sex and species. Whole-body CT examinations encompassed four males and four females, with ages varying between 4 and 33 years (median: 20.6 years) and weight varying between 75 kg and 305 kg (median body weight: 171.2 kg). Settings for the CT helical scan protocol were:

120 kV, 100 - 300 mA, 0.6 s rotation time, helical pitch HP 41.0 and 0.5 mm acquisition slice thickness. It was hypothesised that a correspondence between spine and foot pathologies could be formulated, in relation to the age and weight of the specimen. Analysis of the CT images was performed with a dedicated workstation (ViTREA[®] 2 version 4.0 medical diagnostic software; Vital Images Inc., Minnetonka, USA). The following criteria were used for a 5-points rating scale of the vertebral and distal limb osteopathologies: 1- normal, without bone pathologies; 2- mild, one or two minor lesions; 3- moderate, a few pathologies of average severity; 4- severe, significant, multiple bone lesions; 5- extensive, highly spread and extremely aggressive osteopathologies.

Statistical analysis was performed using PASW Statistics 18 (IBM Inc., Chicago, IL, USA). Pearson's correlation coefficient was calculated in order to check the correlation between two quantitative variables. Mann-Whitney *U*-test was used to compare between two groups for quantitative variables. Where relevant, tests applied were exact two-tailed. A *P*-value < 0.05 was considered statistically significant for all tests.

Results

Distal limb osteopathologies were comprised of a large spectrum of lesions including: osteophytosis, enthesophytosis, new bone formation, bone remodelling, cortical sclerosis, periosteal proliferation, bone cysts, osteoarthritis, exostoses and degenerative joint disease. The most affected bony elements found in our specimens were: calcaneus, talus, accessory carpal bone, ulnar carpal bone, and first carpal bone. Surprisingly, the oldest bear included in our study (female, 33 years old, *Ursus arctos arctos*) presented only moderate foot and vertebral lesions. The most severe foot pathology was found in one polar bear, female, 32 years old and included: extensive new bone production with massive exostoses and osteophytes on the palmaro-lateral aspect of the right carpal joint (figure 1).

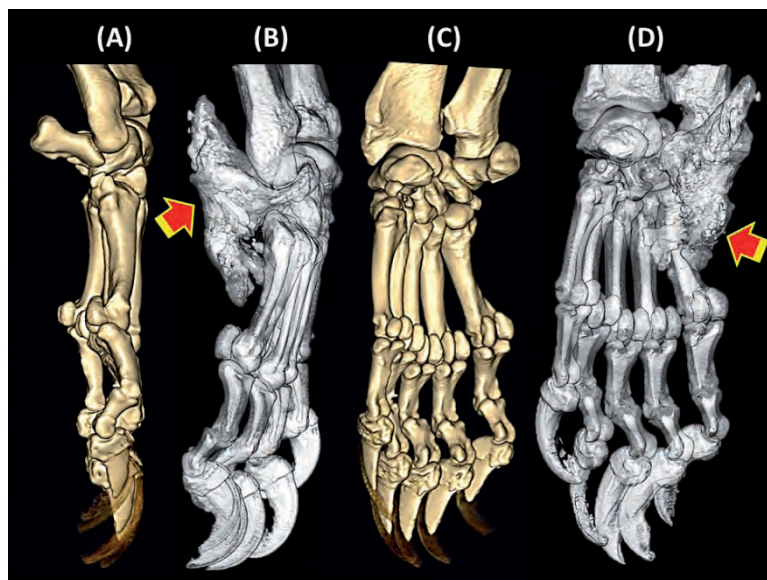


Fig. 1: Front limb autopodium in a brown bear (*Ursus arctos*), female, 33 years old (images A, C), and a polar bear (*Ursus maritimus*), female, 32 years old (images B, D), depicted by high-resolution computed tomographic images. Arrows indicate extensive pathologic bone formation on the latero-palmar aspect of the carpo-metacarpal joint in the polar bear (images B and D). For comparison, normal bone morphology is shown in the brown bear (images A and C). (Photo: Galateanu G)

Vertebral pathologies encompassed new bone production with bone spurs on vertebral bodies, vertebral articular facets ankylosis, spondylosis deformans, osteolysis, and spinal disc disease syndrome including both Hansen type I and Hansen type II lesions.

Although foot and spine lesions may not necessarily be associated to each other, they were always observed concurrently. Furthermore, a direct relationship between the severity of foot and vertebral lesions was discerned. There was no correlation between spinal and proximal limb osteopathologies. No association was found between the age of the animals and their body weight ($r = 0.591$, $P = 0.123$, $n = 8$) or between either of these and the severity of the lesions in either the distal limbs ($r = 0.539$, $P = 0.168$, $n = 8$ and $r = 0.002$, $P = 0.996$, $n = 8$ for age and weight, respectively) or the vertebral column ($r = 0.433$, $P = 0.283$, $n = 8$ and $r = 0.048$, $P = 0.909$, $n = 8$ for age and weight, respectively). From analysing the CT images we did, however, find indication for a strong association between the severity of the lesions in the distal feet and that of the vertebral column (figure 2; $r = 0.955$, $P = 0.00022$, $n = 8$). Females in our sample were older (28.19 ± 5.23 y, $n = 4$) than the males (13.56 ± 7.18 y, $n = 4$) (Mann-Whitney U-test, $U = 0$, $Z = 2.309$, $P = 0.029$).

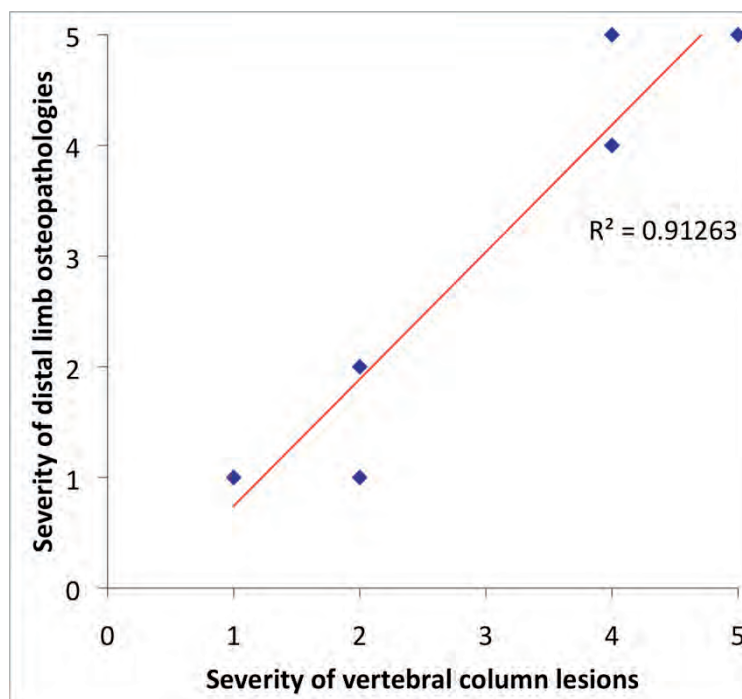


Fig. 2: Association between severity of distal limb osteopathologies and that of vertebral column lesions in bears ($n = 8$). Severity was quantified on a scale of 5: 1 = Normal, 2 = Mild, 3 = Moderate, 4 = Severe, 5 = Extensive.

Discussion

Diagnosis of vertebral pathologies in captive members of the Ursidae family is based on clinical signs and diagnostic imaging. To date, radiography is the imaging technique most widely used in wildlife medicine. Nevertheless, the success of this technique is highly dependent on the animal size and technical capability of the X-ray machine. No information exists regarding the use of computed tomography in assessing vertebral pathologies in this animal family. Yet, CT examinations are superior to radiography when evaluating certain osseous lesions, such as bone cysts, cortical sclerosis, and moderate periosteal reaction.

With this study, we provide information about a variety of distal limb osteopathologies, their occurrence and severity seem to be correlated with lesions in the vertebral column. As this correlation is between two rating scales, outcome of the statistical analysis should be taken with care despite its being highly significant. Yet we investigated only a few animals, of various species, coming from different management and housing systems (zoos, parks), and of a wide range of ages. Still, our results suggest that radiographical diagnosis for the presence of foot bone lesions may imply occurrence of concurrent vertebral pathologies and therefore warrant further investigation. Within each species, apparent difference between males and females in body weight, despite the fact that females were consistently older than the conspecific males in our sample, reinforces the notion of sex dimorphism in bears.

Foot radiography is not going to replace vertebral column imaging, but rather it represents an excellent complementary imaging technique for further investigation of skeletal conditions. Use of radiographs for the detection of early or subclinical spinal disease may allow effective preventive strategies to be adopted. Thus, distal limb radiography may act as a future screening-test for early vertebral disease detection, with high feasibility in the clinical field.

References

- BOURNE DC, CRACKNELL JM, BACON HJ (2010): *Veterinary issues related to bears (Ursidae)*. *Int. Zoo Yb.* **44**, 16 - 32.
- FÖLLMI J (2005): *Symptoms, radiographic examinations and pathologies: Development of a scoring system to evaluate physical condition and quality of life in geriatric zoo mammals*. Doctor of Veterinary Medicine, University of Bern, Bern, Switzerland.
- KITCHENER AC (2004): *The problem of old bears in zoos*. *Int. Zoo News* **51**, 282 - 293.
- NUNN CL, ROTHSCHILD B, GITTLEMAN JL (2007): *Why are some species more commonly afflicted by arthritis than others? A comparative study of spondyloarthropathy in primates and carnivores*. *J. Evol. Biol.* **20**, 460 - 470.
- WAGNER WM, HARTLEY MP, DUNCAN NM, BARROWS MG (2005): *Spinal spondylosis and acute intervertebral disc prolapse in a European brown bear (Ursus arctos arctos)*. *J. S. Afr. Vet. Assoc.* **76**, 120 - 122.

FIRST CATCH YOUR HARE: VERTEBRAL MORPHOLOGY AND PATHOLOGY IN *LEPORIDAE* AS REVEALED BY HIGH-RESOLUTION COMPUTED TOMOGRAPHY

GALATEANU G, GÖRITZ F, WIBBELT G, SZENTIKS CA, HILDEBRANDT TB

Leibniz Institute for Zoo and Wildlife Research (IZW), Alfred-Kowalke-Str. 17, 10315 Berlin, GERMANY; galateanu@izw-berlin.de

Summary

Vertebral pathology in *Leporidae* is scarcely documented; nevertheless its diagnosis can be of paramount importance for breeding programmes and animal welfare. To this end, we employed the means of the highest computed tomographic resolution available to study vertebral architecture in captive European brown hare (*Lepus europaeus europaeus*) and captive mountain hare (*Lepus timidus*). Our study demonstrates that the vertebral column in the captive individuals studied here from both species has both, conservative and highly variable morphologic features, as well as high number of spine pathologies (30 %). New evidence show that vertebral afflictions, both acquired and inherited is more widespread than thought before. This could force us to rethink the use of imaging examinations as a highly recommended screening procedure in captive breeding of *Leporidae*.

Introduction

The vertebral column in Lagomorphs is unique at both terminations. At the cranial end it articulates with the skull at nearly right angle (DUBRUL, 1950), while the lumbo-sacral region has to withstand repeated shocks resulting from the characteristic locomotion in this order of animals. While normal anatomy was exhaustively described (GERHARDT, 1909; KRAUSE, 1868), vertebral column pathology in *Lagomorpha*, however, is rarely reported in the veterinary literature. The only previous descriptions found, from the early 1960's have focused on sacralisation of the last lumbar vertebrae, found in high numbers (more than 2 %) in European hare from Western Poland (BUJALSKA, 1963; BUJALSKA, 1964).

Material and methods

In order to improve the knowledge on the vertebral morphology and pathology in hares, the authors conducted a comparative and high resolution computed tomographic study including captive bred animals, without free mate choice, of the following species and subspecies of the family *Leporidae* (n = 23): *Lepus europaeus* ssp. *europaeus* (n = 15) and *Lepus timidus* (n = 8). The objectives of this study were to study the normal anatomy in these species and to identify morphologic abnormalities of the vertebral column. We aimed to assess if specific morphologic criteria can be established and to describe any pathology found.

Results

Our results indicate that all hares conform in the following vertebral features: (1) vertebral formula consists of 7 cervical, 12 thoracic, 7 lumbar and, with one exception, 4 sacral vertebrae; (2) spinous

process of the second cervical vertebra (axis) is long, but shallow ; (3) pentagonal shape of the last cervical (C7) and first thoracic (T1) vertebral bodies; (4) spinous process of the first thoracic vertebra is significantly smaller than those of the subsequent vertebrae; (5) lumbar vertebrae (L2, L3) present a ventral process (*Processus spinosi anteriores s. ventrales*), very well developed at the level of the second lumbar vertebra; (6) transverse processes of the first lumbar vertebrae are bifurcated in coronal plane (figure 1A).

The present study also identified highly variable spinal features such as: (1) last clinal thoracic vertebra (mostly T9 but sometimes also T10); (2) spinous process of the 6th cervical vertebra is often present and small but, occasionally (n = 2), absent; (3) presence of a ventral process (*Processus spinosi anteriores s. ventrales*) on the lumbar vertebrae and sometimes also on the last thoracic vertebrae (usually on L2 and L3, but sometimes also T10, T11, T12, L1, L4, L5); (4) bifurcated lumbar transverse processes situated at L1-L3, but at times also at L4, L5; (5) The ratio (R) between the vertebral body length of the last two lumbar vertebrae ($R = L7 \text{ length} / L6 \text{ length}$) presents large variations (between 0.7 and 0.92). Perhaps not surprisingly, these highly variable features were found in both species and both genders, with no specific prevalence.

Vertebral pathologies were found in 30.4 % of the studied hares and could be divided into two major groups: congenital (thoracic, lumbar and lumbo-sacral malformations (figure 1B); 28.6 %) or acquired (spondylosis, fractures, intervertebral disc disease, osteochondromatosis, lumbo-sacral syndrome, degenerative intervertebral disc disease, lumbo-sacral stenosis, spondylosis; 71.4 %).

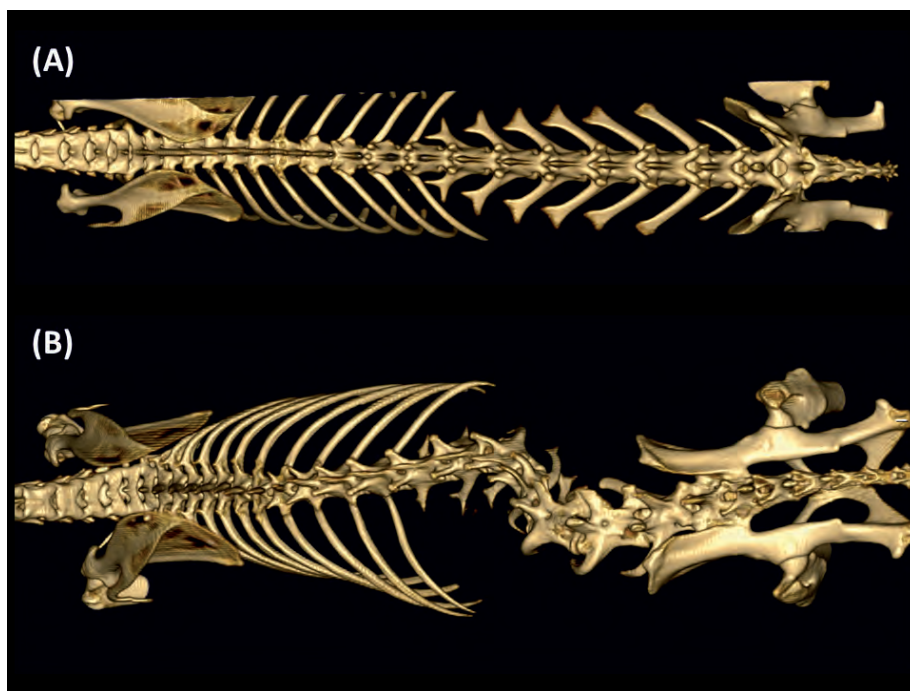


Fig. 1: Normal anatomy (A) and vertebral congenital anomaly (B) in Leporidae. Normal vertebral morphology is shown in (A) European brown hare (*Lepus europaeus europaeus*) and severe thoraco-lumbar malformation is presented in (B) mountain hare (*Lepus timidus*). (Photo: Galateanu G)

Discussion

Vertebral traits found in all specimens included in this study are consistent with the general mammalian anatomy (LIEM et al., 2001) and their number [seven cervical, twelve thoracic, seven lumbar and four sacral (GERHARDT, 1909; KRAUSE, 1868)] is tallied as constant among the two species.

The vertebral deformities found in this study are most likely associated with genetic or congenital disorders similar to those documented in companion animals (DENNIS et al., 2001). As inherited or developmental afflictions are suspected, these malformations should be taken into account when hares are evaluated for captive breeding programmes. Diseases occurring during the skeletal maturation period in small animals are conditioned by genetic and environmental factors, the later primarily associated with their diet.

Considering these findings, we conclude that the hares' vertebral column in our studied captive populations, without free mate choice, present both highly variable features and conservative morphologic criteria. Further studies are warranted to evaluate the prevalence of inherited vertebral deformities and can be of paramount importance for screening of congenital anomalies and hereditary spine diseases in captive bred *Leporidae*.

References

- BUJALSKA G (1963): *Cases of sacralisation of the final lumbar vertebra in the European hare, Lepus europaeus PALLAS, 1778. Acta Theriol.* **6**, 301 - 302.
- BUJALSKA G (1964): *A case of one-sided sacralization of the final lumbar vertebra in the European hare (Lepus europaeus PALLAS, 1778). Acta Theriol.* **9**, 381 - 383.
- DENNIS R, KIRBERGER RM, WRIGLEY RH, BARR FJ (2001): *Handbook of Small Animal Radiological Differential Diagnosis.* London: W. B. Saunders, 83 - 102.
- DUBRUL EL (1950): *Posture, locomotion and the skull in Lagomorpha. Am. J. Anat.* **87**, 277 - 313.
- GERHARDT U (1909): *Das Kaninchen: zugleich eine Einführung in die Organisation der Säugetiere* Leipzig: Verlag von Dr. Werner Klinkhardt, VI, 307.
- KRAUSE W (1868): *Die Anatomie des Kaninchens in topographischer und operativer Rücksicht.* Leipzig: Verlag von Wilhelm Engelmann, XVI, 269.
- LIEM KF, BEMIS WE, WALKER JR. WF, GRANDE L (2001): *Functional Anatomy of the Vertebrates: An Evolutionary Perspective.* Belmont, CA: Thomason Brooks/Cole, 703.

NEW CLINICAL IMAGING TOOLS: TAXA-SPECIFIC DISTAL FOOT RADIOGRAPHIC VIEWS IN RHINOCEROSSES

GALATEANU G¹, HERMES R¹, SARAGUSTY J¹, GÖRITZ F¹, POTIER R², MULOT B², MAILLOT A³, ETIENNE P⁴, BERNARDINO R⁵, FERNANDES T⁵, HILDEBRANDT TB¹

¹Leibniz Institute for Zoo and Wildlife Research (IZW), Alfred-Kowalke-Str. 17, 10315 Berlin, GERMANY; galateanu@izw-berlin.de

²ZooParc de Beauval, Route du Blanc, 41110 Saint-Aignan, FRANCE

³Parc zoologique d'Amnéville, 1 Rue du Tigre, 57360 Amnéville-les-Thermes, FRANCE

⁴Parc zoologique de La Barben (Pélissane), Route du Château, 13330 La Barben, FRANCE

⁵Jardim Zoológico de Lisboa, Praça Marechal Humberto Delgado, 1549-004 Lisbon, PORTUGAL

Summary

Currently, radiography is the only imaging technique used to diagnose bone pathology in wild animals situated under “field conditions”. However, clinicians lack the diagnostic imaging tools, namely radiographic techniques and protocols as well as reference documentation regarding radiographic interpretation of both normal anatomy and pathology. For these reasons, the authors initiated a multi-modality imaging study and established a pioneering approach of synchronised computed tomography (CT) and digital radiography (DR), based on X-ray projections derived from three-dimensional CT reconstructed images. Traditionally, it is assumed that projection angles of 45° between radiographic views will be enough for detailed foot evaluation. Nevertheless, this study shows that species-specific anatomical variations must be taken into consideration when advancing both traditional and species-related radiographic views. With this we hope to provide veterinary clinicians with concrete information on imaging techniques and substantial diagnostic tools that will facilitate straightforward attainment and interpretation of field radiographs taken worldwide.

Introduction

Currently, radiography is the only imaging technique used to diagnose bone pathology in wild animals. However, while chronic foot disease is widely reported in captive mega herbivores, foot radiographic imaging is confronted with scarcity of studies. Specifically for rhinoceroses, distal foot bone lesions were found to be more pervasive than previously thought when high-quality imaging was employed (GALATEANU et al., 2013a). Authors' previous work also showed that distal limb radiographic techniques and radiographic interpretation of both normal anatomy and pathology in domestic animals could not be extrapolated to their non-domestic relatives (GALATEANU et al., 2013b). Hitherto, clinicians lack the necessary diagnostic imaging tools, namely radiographic techniques and protocols as well as reference documentation regarding radiographic interpretation of both normal anatomy and pathology. A new imaging strategy for assessment of bone pathologies in wild animals became imperative and is thus called for.

Materials and methods

As a case in point, and of great concern for zoological institutions, we selected foot bone radiography in captive rhinoceroses. To that end, the authors initiated a computed tomographic (CT) study of ten distal limbs (five front and five hind legs) obtained *post mortem* from two Southern white rhinoceros (*Ceratotherium simum simum*) and two Indian rhinoceros (*Rhinoceros unicornis*). High-resolution CT images were obtained by employing a 128-slice CT scanner (Aquilion CX, Toshiba, Japan) with the highest resolution available worldwide in veterinary medicine, and a dedicated, multi-software workstation (ViTREA[®] 2 version 4.0 medical diagnostic software; Vital Images Inc., Minnetonka, MN, USA). For each foot, eight tri-dimensional (3D) CT images (45° apart) equivalent to eight standard radiographic views were obtained. Each such 3D CT image was transformed into a synchronised digital radiographic (Synch DR) image, in total eighty Synch DR images for all ten feet (figure 1).

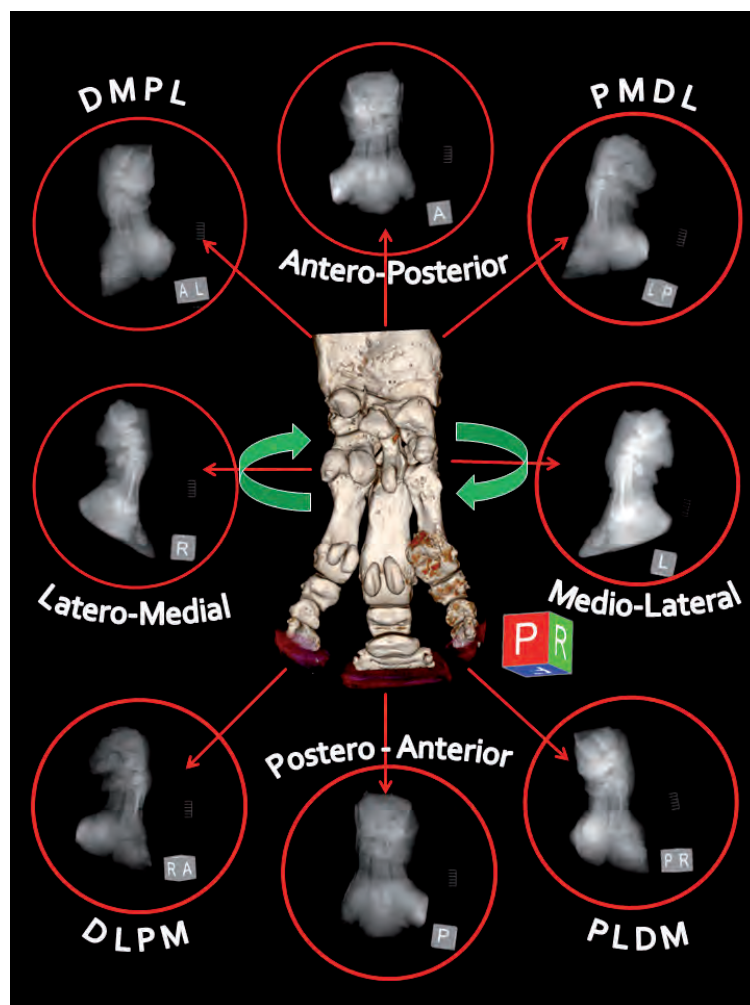


Fig. 1: Principle of method in synchronised computed tomography (CT)-digital radiography (DR). Digital radiographic images are calculated and generated from fully rendered, tri-dimensional (3D) CT images. Standard orthogonal ($n = 4$) and oblique ($n = 4$) radiographic views (45° apart) are shown here using, as an example, the left front distal limb of a Southern white rhinoceros. Abbreviations represent oblique projections characterised by the point-of-entry to point-of-exit direction of the primary X-ray beam: DMPL [dorsomedial-palmarolateral], PMDL [palmaromedial-dorso-lateral], PLDM [palmarolateral-dorsomedial], and DLPM [dorsolateral-palmaromedial]. (Photo: Galateanu G)

Additionally, 3D CT images were virtually rotated in order to achieve minimal bone superimposition on digital segments and these optimal projections were converted into Synch DR's.

Results

Due to rhinoceros' special foot anatomy, traditional positioning using, as accurate landmarks, specific anatomical structures could not be applied. The most reliable anatomical landmark found in both Indian and Southern white rhinoceros was the toenail of the third (central) digit. New radiographic views were established for a better visualisation of the rhinoceros' digits while minimising superimposition of the large sesamoids on the metapodial and phalangeal elements. Synchronised radiographic projections obtained at angles of 45°, from the reference dorsal mid-line passing through the central toenail, were compared with Synch DR images obtained at different angles. Employing synchronised computed tomography (CT) - digital radiography (DR) technique, it was noted that, due to rhinoceros' special foot anatomy, traditional positioning, using standard 45° projection (beam-object) angles, could not result in good diagnostic images. New radiographic views were established for a better visualisation of rhinoceros' digits while minimising bone superimposition. Starting with dorso-palmar view, in medial direction, the optimal angles for the front foot are: 20°—60°—70°—30°—20°—70°—60°—30°. Starting with dorso-plantar view, in medial direction, the optimal angles for the hind foot are: 20°—70°—70°—20°—20°—70°—70°—20°. Angles were identical for both species. By comparison, rhinoceroses' specific projection angles revealed a larger number of digits' osteopathologies compared to the traditional angles, in all feet.

Discussion

This study shows that species dependent anatomical variations must be taken into account when employing radiographic projections in mega vertebrates. With this we provide species-specific imaging technique, which facilitates straightforward implementation and easy interpretation of rhinoceros feet radiographic images taken in the field worldwide. Bearing in mind that future survival for some species might be in captivity only, the importance of eradicating chronic foot disease never became as important as it is now. Radiographic investigations, being highly diagnostic and non-invasive procedures, should be relied upon when developing the most appropriate wildlife management and conservation strategies. The CT-DR synchronisation technique, demonstrated here for rhinoceros feet, can be applied to any other species and any other body part, turning it into a very useful and highly important tool.

References

- GALATEANU G, HILDEBRANDT TB, MAILLOT A, ETIENNE P, POTIER R, MULOT B, SARAGUSTY J, HERMES R (2013a): *One small step for rhinos, one giant leap for wildlife management- imaging diagnosis of bone pathology in distal limb. PLoS ONE* **8**, e68493.
- GALATEANU G, HERMES R, GÖRITZ F, SZENTIKS CA, WIBBELT G, HILDEBRANDT TB (2013b): *An extensive study: Diagnostic imaging of normal anatomy and pathology in hoofed mammal's distal limb. Proc. Int. Conf. Zoo Wild Anim.*, 26.

QUANTITATIVE COMPUTED TOMOGRAPHY IN CAPTIVE GIRAFFES (*GIRAFFA CAMELOPARDALIS*)

GALATEANU G, SARAGUSTY J, GÖRITZ F, WIBBELT G, SZENTIKS CA, MEZÖ Z,
HILDEBRANDT TB

Leibniz Institute for Zoo and Wildlife Research (IZW), Alfred-Kowalke-Str. 17, 10315 Berlin,
GERMANY; galateanu@izw-berlin.de

Summary

The tallest terrestrial animal and at the same time largest ruminant, the giraffe (*Giraffa camelopardalis*; Linnaeus 1758), has unique features, such as very high vertical growth rate, a skeleton that constitutes a large proportion of its body mass, and long, slender legs to move at fast speeds (up to 60 km/h) for survival. Owing these peculiar traits, one would expect the limb bones to have high densities to provide the necessary strength to support the giraffe's huge body mass (average 1,000 kg) and strenuous activity. To investigate this hypothesis, we focused on the longest limb elements, the metapodial bones (metacarpus, metatarsus) and specifically, on cortical bone, as the compartment holding the highest mineral density. Cortical bone mineral density evaluated through quantitative computed tomography in 36 giraffe metapodials showed relative similar values at all ages, with no significant differences between males and females or between front and hind legs. The only difference found was between left and right side, with left side limbs having a slightly greater bone density. Comparison with other herbivores revealed that the relative cortical bone mineral density is analogue, with slight decrease in smaller specimens. In conclusion, giraffes' distal limbs maintain cortical bone mineral content within a physiologic range similar to that found in other herbivores.

Introduction

Among the unique features known in giraffe (*Giraffa camelopardalis*; Linnaeus 1758), the tallest living terrestrial animal, the precise limb bone architecture that allows them to support their huge mass requires further research. Previous studies (VAN SCHALKWYK et al., 2004) focused on whole bone density. Their results showed that, except for minor differences, the density of giraffe's bones is analogous to that of African buffaloes (*Syncerus caffer*), an artiodactyl of similar body weight. Absolute density was calculated by dividing the bone mass by its volume, and was recorded as g/cm³. Interestingly, it appears that changes in osseous geometry such as cortical thickness, bone diameter (VAN SCHALKWYK et al., 2004), and trabecular architecture (DOUBE et al., 2011) are preferred over increased bone mass. Nevertheless, fine-tuning assessment of the main mineral reservoir, the cortical compartment, was not performed. The current study set out to investigate cortical bone mineral density (BMD) in giraffe's metapodials (metacarpus and metatarsus), to evaluate the relationship between metapodial cortical BMD and the animal's age and gender, and to assess if specific quantitative criteria can be established.

Material and methods

For assessment of cortical BMD in metapodial bones (distal third), we conducted a quantitative computed tomographic (qCT) study employing a 128-slice CT scanner (Aquilion CX, Toshiba, Japan)

with the highest resolution available worldwide in veterinary medicine, a BMD calibration phantom (B-MAS 200) with 5 rods equivalent to different bone densities, and a dedicated, multi-software workstation (ViTREA[®] 2 version 4.0 medical diagnostic software; Vital Images Inc., Minnetonka, USA). Thirty-six limbs (18 front legs and 18 hind legs) from nine giraffes, obtained *post mortem*, were used for this study. Studied specimens included the following sub-species: Rothschild giraffe (*G. c. ssp. rothschildi*; n = 4), hybrids between Rothschild giraffe (75 %) and West African giraffe (*G. c. peralta*; 25 %; n = 3), reticulated giraffe (*G. c. reticulata*; n = 1), and giraffe of unknown subspecies (n = 1). There were three males and six females with weight varying between 35 and 1,100 kg. A wide spectrum of ages was encompassed, ranging between foetus, new born specimens (1 and 2 days old), sub-adults (3.5 years old) and adults, the oldest being 24.5 years old.

For comparison purposes, a wide variety of other hoofed-mammal species and subspecies were included in our study: Chapman's zebra (*Equus quagga chapmani*), bongo antelope (*Tragelaphus eurycerus*), Thorold's deer (*Cervus albirostris*), Rocky mountain goat (*Oreamnos americanus*), dromedary camel (*Camelus dromedarius*), Bactrian camel (*Camelus bactrianus*), alpaca (*Vicugna pacos*), Bawean deer (*Axis kuhlii*), roe deer (*Capreolus capreolus*), elk (*Cervus canadensis*), water-buck (*Kobus ellipsiprymnus*), cheetal (*Axis axis*), Mongolian gazelle (*Procapra gutturosa*), Java mouse-deer (*Tragulus javanicus*).

Statistical analysis was performed using PASW Statistics 18 (IBM Inc., Chicago, IL, USA). *T*-test and Mann-Whitney *U*-test were used to compare between two groups for quantitative variables. Where relevant, tests applied were exact. A *P*-value < 0.05 was considered statistically significant for all tests.

Results

Bone mineral density measured for metapodials' cortical distal third in foetus giraffe had mean \pm SD values of 895.07 ± 35.98 mg/cm³, while in new born specimens (1 day and 2 days old) the values were 1233.50 ± 104.13 mg/cm³ and 832.60 ± 131.84 mg/cm³. Cortical BMD mean \pm SD values were of 1311.14 ± 119.74 mg/cm³ for the juvenile giraffe and 1178.37 ± 75.27 mg/cm³ for the adults. The oldest giraffe presented relatively lower values of 1112.01 ± 44.10 mg/cm³. For statistical purposes, comparisons were done in two different modes – i) Comparing the adults to all others (foetus, one- and two-days old newborn and 3.5 year old juvenile), and ii) when the 3.5 year old giraffe was excluded from analysis. Both methods showed no differences when the young animal groups were compared to each other or when each was compared to the adults group in any of the BMD parameters studied. When the young animals group included the 3.5 year old giraffe, mean \pm SD BMD was 1068.07 ± 239.32 mg/cm³. The young animals and adult groups were compared for body weight, and for the following BMD measures: mean front legs, mean hind legs, all legs mean, mean right legs, mean left legs and each leg separately. There were no differences in any of these but there was a tendency for weight to be lower in the juvenile group (63.38 ± 44.69) compared to the adult group (953.33 ± 174.74), (Mann-Whitney *U* = 0, *Z* = 2.121, *P* = 0.057). When the 3.5 year old was excluded from analysis the weight of the foetus and newborns was marginally significantly smaller than that of the adults (Mann-Whitney *U* = 0, *Z* = 1.964, *P* = 0.04953). Furthermore, there were no significant differences for BMD in males (1215.09 ± 124.63 mg/cm³) in comparison with females of similar age (1153.90 ± 36.29 mg/cm³). When comparing front and hind legs, left and right legs, front left and right legs, hind left and right legs, front left and hind left legs, and front right and hind right legs, two of these comparisons were significant:

1. Front right legs (1072.52 ± 179.83) had lower BMD compared to front left legs (1170.49 ± 196.13), *t* = 2.345, *df* = 8, *P* = 0.047.

2. Mean right legs (1086.64 ± 172.97) had lower BMD compared to mean left legs (1165.76 ± 163.93), $t = 2.719$, $df = 8$, $P = 0.026$.

Similar relative cortical BMD values were found in all the other species of hoofed mammals included in our study for comparison, nevertheless, no right-left differences were observed.

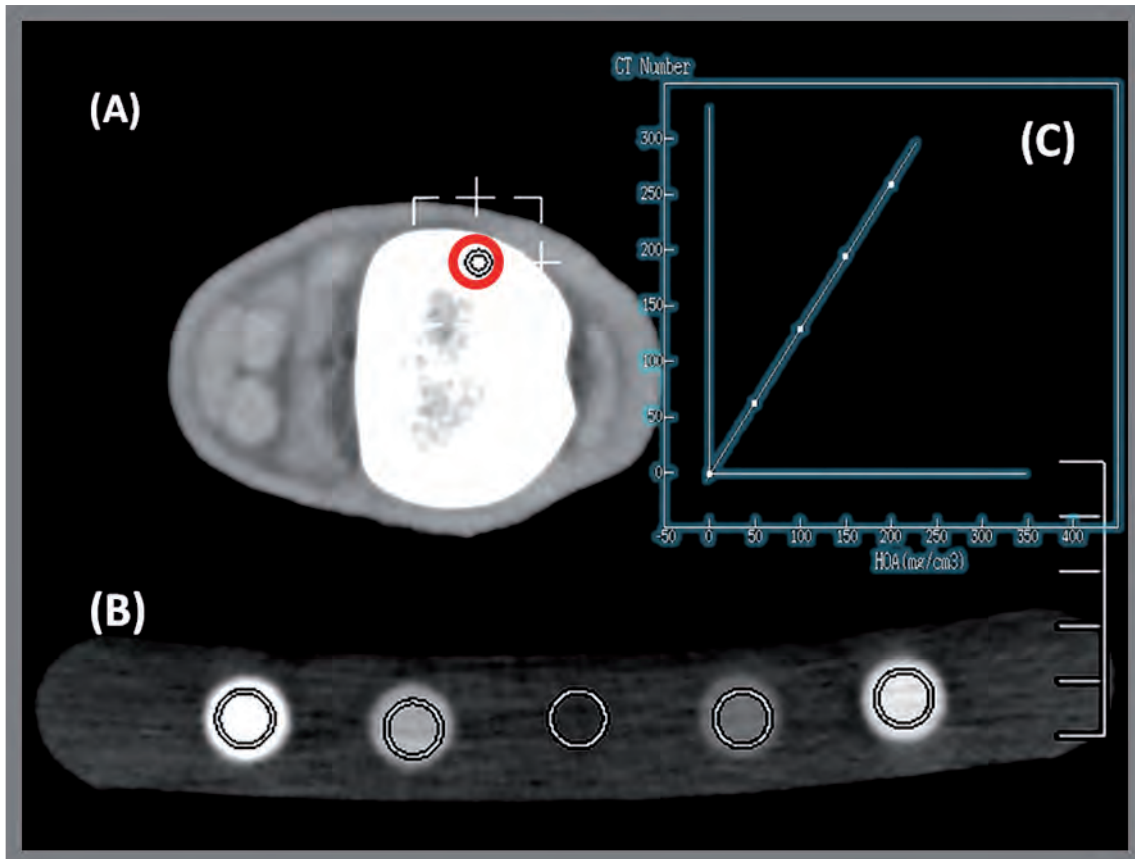


Fig. 1: Bone mineral study (BMS) in giraffe's distal limb performed by means of quantitative computed tomographic (qCT) technique. (A) Axial sectional image of distal metacarpal bone in an adult giraffe, with cortical bone region of interest (bone ROI) placed on the cortical area (red circle); (B) the calibration phantom B-MAS 200 with 5 ROIs set accurately on the rods (white circles); (C) Correct regression line chart used to convert the CT numbers of bone ROIs into BMD values. The rods are represented by regions containing bone mineral equivalent material. Bone mineral density is measured employing a dedicated software on the imaging console. In order to be able to open this BMS-Application, the specific axial image must be viewed in a preset CT bone window (named "WL/ WW: Bone"). Therefore, all phases (ROI positioning, regression chart computation and BMD measurements) are performed in identical conditions. Nevertheless, for an improved visualisation of the calibration phantom's mineral rods, the window / level of the submitted CT image were adjusted accordingly (soft tissue algorithm). The W/L adjustment was performed following BMD measurement, aiming to illustrate ROI positioning on the mineral rods in this specific image. (Photo: Galateanu G)

Discussion

The exact kinematic patterns, physiologic mechanisms, and morphologic stratagems employed by extremely large mammals for their locomotion are a conundrum, in spite of scientists' increasing interest in this subject matter. Whereas some light has been shed on the locomotion strategies employed by the largest mammal on land, the elephant (HUTCHINSON et al., 2011; WEISSENGRUBER et al., 2006), precise morphologic data on the giraffe locomotor apparatus is sparse. Among other peculiarities, giraffes' legs are extremely long and it was therefore hypothesised that they must comprise of larger bone mass in order to sustain its huge body weight. Our data show that cortical bone mineral density in giraffe metapodials (the longest limb osseous elements in this species) does not have significantly different values compared with the other ungulates studied. This may be an evolutionary adaptation that restricts energetic costs of producing, maintaining and moving more tissue, within specific physiologic limits. Additionally, increased bone mass per unit volume will augment even more the skeletal loads. It must be emphasised that cortical BMD has relative similar values in giraffes of all ages. This points out to a genotypic and not phenotypic adaptation, which may have occurred if having a specific bone mineral mass conferred an advantage to such large animals. In the wild, the new born must be able to stand up to feed on the vital milk and run to escape predators from the first moments after birth, thus requiring strong bones to sustain the associated stresses. The left-right difference found is interesting and merits further research in an attempt to try and understand its etiology.

In conclusion, giraffes' distal limbs maintain their cortical bone mineral content within a physiologic range similar to that found in other ungulates. This trait warrants further studies on morphologic and kinetic strategies employed by the tallest living animal on land to support and shift its huge body weight.

References

- DOUBE M, KŁOSOWSKI MM, WIKTOROWICZ-CONROY AM, HUTCHINSON JR, SHEFELBINE SJ (2011): *Trabecular bone scales allometrically in mammals and birds. Proc. R. Soc. B* **278**, 3067 - 3073.
- HUTCHINSON JR, DELMER C, MILLER CE, HILDEBRANDT T, PITSILLIDES AA, BOYDE A (2011): *From flat foot to fat foot: Structure, ontogeny, function, and evolution of elephant "sixth toes". Science* **334**, 1699 - 1703.
- VAN SCHALKWYK OL, SKINNER JD, MITCHELL G (2004): *A comparison of the bone density and morphology of giraffe (Giraffa camelopardalis) and buffalo (Syncerus caffer) skeletons. J. Zool.* **264**, 307 - 315.
- WEISSENGRUBER GE, EGGER GF, HUTCHINSON JR, GROENEWALD HB, ELSÄSSER L, FAMINI D, FORSTENPOINTNER G (2006): *The structure of the cushions in the feet of African elephants (Loxodonta africana). J. Anat.* **209**, 781 - 792.

HIGH-RESOLUTION COMPUTED TOMOGRAPHIC ASSESSMENT OF DENTAL MORPHOLOGY IN GERMAN WOLVES (*CANIS LUPUS*)

GALATEANU G, SZENTIKS CA, KRONE O, HILDEBRANDT TB

Leibniz Institute for Zoo and Wildlife Research (IZW), Alfred-Kowalke-Str. 17, 10315 Berlin, GERMANY; galateanu@izw-berlin.de

Inbreeding depression in natural populations is usually substantial enough to affect both individual and population performance, with severe impact on birth weight, survival, reproduction, resistance to disease, and predation as well environmental stress. More recent studies of inbreeding in wild animals use genetic procedures, but other approaches are also employed. The European wolf populations went through a bottleneck during the 1960's and 1970's resulting in loss of genetic diversity. In this respect, the increased occurrence of vertebral and dental congenital anomalies in Scandinavian wolves (*Canis lupus*), going up from 13 % to 40 % over the study period of 32 years, was associated with inbreeding or some form of genetic deterioration.

The present study attempts to address the question if the German wolf population exhibits some kinds of dental anomalies and what is its frequency in the sampled population. To this end, we performed computed tomographic (CT) examinations on 52 wild wolves, employing a 128-slice CT scanner (Aquilion CX, Toshiba, Japan) and a dedicated, multi-software workstation (ViTREA[®] 2 version 4.0 medical diagnostic software; Vital Images Inc., Minnetonka, MN, USA). Each wolf was assessed for the presence of the following dental anomalies: supernumerary dentition, hypodontia, oligodontia, microdontia, rotated teeth, persistent deciduous teeth, and deviations from the normal dental formula for wolves: I3C1Pm4M2/ I3C1Pm4M3 (I = incise, C = canine, Pm = premolar, M = molar). The final number of wolves used for data analysis was 45. Five wolves that had severe comminuted skull fractures and two juvenile wolves with deciduous dentition were excluded from analysis.

Analysis of CT images revealed: (a) thirty-seven wolves (82.2 %) had complete dental formula; (b) five wolves (11.1 %) had hypodontia (bilateral in two wolves); (c) four wolves (8.8 %) had supernumerary dentition; (d) three wolves (6.6 %) presented fractured teeth. The following anomalies were detected in one wolf (2.2 %) each: (e) microdontia (mandibular first premolar, right side); (f) dental malposition (intra-alveolar horizontal mandibular third molar); (g) dental avulsion (maxillar second incise). Congenital absent teeth included mandibular third molar (n = 4), followed by maxillar first (n = 1) and second (n = 1) premolars and maxillar second molar (n = 1). Supernumerary dentition was represented by retained deciduous teeth (mandibular first premolar, mandibular first incise) but also by an unusual first premolar, with a single dental root.

This study shows that congenital dental anomalies in German wolves have a low frequency in the wild populations, traumatic lesions being more prevalent. Nevertheless, future studies of congenital anomalies in European wolves are required for better population evaluation and conservation strategies.

OPTIMISATION OF PLATELET-RICH PLASMA CONCENTRATION PROTOCOL IN BOTTLENOSE DOLPHINS (*TURSIOPS TRUNCATUS*) AND *IN VITRO* VALIDATION TESTING

GARCÍA-PÁRRAGA D¹, GRIFFETH RJ², CRESPO-PICAZO JL¹, ÁLVARO T¹, VALLS M¹, SORIANO-NAVARRO M⁴, MARTINEZ A³, MORENO-MANZANO V²

¹Oceanográfico, Veterinary and Laboratory Services, Parques Reunidos Valencia, Ciudad de las Artes y las Ciencias, 46013 Valencia, SPAIN; dgarcia@oceanografic.org

²Centro de Investigación Príncipe Felipe. Tissue and Neuronal Regeneration Lab. Valencia, 46013, SPAIN

³Centro de Investigación Príncipe Felipe. Cytomics's Lab., 46013 Valencia, SPAIN

⁴Centro de Investigación Príncipe Felipe. Electron Microscopy Unit., 46013 Valencia, SPAIN

In wild and captive dolphins accelerated wound healing would be beneficial to minimise the risk of infections and other side effects associated with open wounds in marine animals. We proposed a concentration protocol for obtaining platelet rich plasma (PRP) from bottlenose dolphins (*Tursiops truncatus*), oriented to be used as a biological-based therapy for dolphin wound healing. Whole blood samples were collected in sodium citrate to prevent clotting and were centrifuged at various rates of turn and durations. After centrifugation, the lower half of the serum was considered PRP and collected for use in these experiments. A single centrifugation for 3 minutes at 900 rpm resulted in the best condition, whereas human or canine protocols for PRP concentration (1870 rpm or 460 g/8 min) were not applicable for dolphin platelet concentration. Furthermore, lymphocyte contamination was negligible after centrifugation for 3 minutes at 900 rpm. Analysis by electron microscopy revealed that normal platelet structure and morphology was adequately preserved under the mentioned centrifugation protocol. Dolphin platelets were larger in size and contained more granules than human platelets, potentially explaining the need to reduce the duration and speed of centrifugation compared to other terrestrial mammal concentration protocols. *In vitro* assays applying PRP on mesenchymal cell cultures from striped dolphin (*Stenella coreuleoalba*) significantly promoted cell division and proliferation demonstrating tissue-repairing induction potential. In summary, these data show a simple and well-defined protocol for efficient PRP isolation, which would constitute the basis of a practical, low cost and easy accessible biological treatment for dolphin wound-healing and tissue regeneration.

Acknowledgements

The authors would like to thank all the Oceanográfico Biology Department, for their support in animal training, dedication and commitment in providing best care to the animals. This research was funded by the Fundación García-Cugat and by the Instituto de Salud Carlos III (FISS_PI13/00319).

ADRENAL MASS AS A RETROSPECTIVE INDICATOR OF HEALTH PROBLEMS IN CAPTIVE CHEETAHS (*ACINONYX JUBATUS*) AT THE ANN VAN DYK CHEETAH CENTRE, SOUTH AFRICA

GERMITSCH N¹, VYBIRAL P-R¹, CODRON D^{1,2}, CLAUSS M¹, KOTZE A³, LANE EP³

¹University of Zurich, Vetsuisse Faculty, Clinic for Zoo Animals, Exotic Pets and Wildlife, Winterthurerstrasse 260, 8057 Zurich, SWITZERLAND; mclauss@vetclinics.uzh.ch

²Florisbad Quaternary Research, National Museum, PO Box 266, Bloemfontein 9300, SOUTH AFRICA

³National Zoological Gardens of South Africa, 232 Boom St, Pretoria, SOUTH AFRICA

The size of the adrenal gland and the ratio of adrenal cortex to medulla thickness have been used as an indicator of 'stress' in free-ranging and captive wildlife. In cheetah (*Acinonyx jubatus*), captive individuals have higher adrenal corticomedullary ratios than free-ranging ones (TERIO et al., 2004), and adrenal cortical hyperplasia has been linked to glomerulosclerosis in captive individuals (BOLTON and MUNSON, 1999). We investigated adrenal changes in relation to other pathologies reported in a necropsy sample of 57 cheetahs evaluated between 2007 and 2013. The ten most common diagnoses in the whole dataset were counted for each animal, indicating that individual's number of health problems. The number of health problems increased significantly with age (which indicated time in captivity in this study). Similarly, the adrenal mass and the adrenal corticomedullary ratio increased significantly with cheetah age, and both were also correlated to the number of health problems. In particular, animals diagnosed with gastritis had a significantly ($P < 0.05$) higher corticomedullary ratio than animals without this problem. Adrenal corticomedullary ratios reported in the necropsy reports of this study were often higher (mean \pm SD: 2.2 ± 1.4) than the ones reported previously (2.1 ± 0.2 ; TERIO et al., 2004). The results of this study show that adrenal morphology can serve as indicator of cheetah health status, and suggest that adrenal morphology should be investigated routinely in the species both at *post mortem* or during ultrasound examinations (as e.g. done in another carnivore by PAINER et al., 2013). The results also document that cheetahs – like probably any free-ranging or captive animal – accumulate health problems in captivity over time.

This study was part of the Zoo Research Camp (ZRC) 2013 organised by the National Zoological Gardens of South Africa and the Vetsuisse Faculty, University of Zurich, Switzerland.

References

- BOLTON LA, MUNSON L (1999): Glomerulosclerosis in captive cheetahs (*Acinonyx jubatus*). *Vet. Pathol.* **36**, 14 - 22.
- PAINER J, JEWGENOW K, GONÇALVES N, SERRA R, CANALES R, MUÑOZ L, MENDOZA JL, HILDEBRANDT TB, GÖRITZ F (2013): 3D adrenal ultrasound – a new approach for the evaluation of stress in the critically endangered Iberian lynx *ex situ* population. *Int. Conf. Behav. Physiol. Genet. Wildl.* **9**, 145.
- TERIO KA, MARKER L, MUNSON L (2004): Evidence for chronic stress in captive but not free-ranging cheetahs (*Acinonyx jubatus*) based on adrenal morphology and function. *J. Wildl. Dis.* **40**, 259 - 266.

ALPHA-NAPHTYL ACETATE ESTERASE ACTIVITY IN WHITE BLOOD CELLS OF WILD RUMINANTS: PRELIMINARY RESULTS

GIACOMELLI S¹, BIANCHI A¹, POLLONI A², ARCHETTI LI², BERTOLETTI I¹, ROTA NODARI S²

¹Istituto Zooprofilattico Sperimentale della Lombardia e dell'Emilia Romagna "Bruno Ubertini", Sondrio Dept., Via Bormio 30, 23100 Sondrio, ITALY; stefano.giacomelli@izsler.it

²Istituto Zooprofilattico Sperimentale della Lombardia e dell'Emilia Romagna "Bruno Ubertini", Via Bianchi, 9 - 25124 Brescia, ITALY

Summary

Alpha-naphtyl acetate esterase (ANAE) staining was performed on 22 peripheral blood smears obtained from roe deer (*Capreolus capreolus*), fallow deer (*Dama dama*), red deer (*Cervus elaphus*) and alpine ibex (*Capra ibex*), in order to study the enzyme activity in different leukocyte subtypes. The obtained leucogram was compared with the results of the classical Hemacolor staining. The analysis of the results indicated that ANAE staining provides additional information compared to Hemacolor through a better differentiation of mononuclear blood cells. In particular the presence of this esterase in T-lymphocytes seems to better characterise the health status of the individuals.

Introduction

Despite its clinical importance, literature on haematological parameters, especially on differential white blood cell counts, is scarce for almost all wild ruminants. While automated blood count techniques have not been validated yet for all these species, classical haematological techniques using different staining protocols can differentiate leukocyte subpopulations but can leave some doubts for mononuclear cells (monocytes and lymphocytes), due to the high frequencies of large atypical lymphocytes in these species (CHALEOW et al., 1998). ANAE is a lysosomal enzyme that participates in cytotoxic effects and it was detected primarily in monocytes and T-lymphocytes. Due to the differential expression of this enzyme between T- and B-lymphocytes, ANAE staining method is one of the most efficient techniques to distinguish between the two lymphocyte subtypes (HIGGY et al., 1977; KNOWLES et al., 1978). ANAE staining produces black granules in cells cytoplasm. In particular all monocytes express an intense and diffuse reaction while only a part of lymphocytes populations (T cells) presents few, perinuclear, intense and focal granulation or a more diffuse but less intense pattern (figure 1). In some species a variable presence of ANAE granules can be seen also in polymorphonucleated cells (PMN). Mononuclear cell differentiation is of high importance due to their immunological role in major pathologies affecting wild ruminants (ROBINSON et al., 2008). The number of ANAE positive lymphocytes (L+) varies in response to various stimuli like physical exercise (EDWARDS et al., 1984), immune suppression or dietary factors (YENER et al., 2011). The aim of this study thus was to evaluate the applicability of ANAE staining to wild ruminants in order to better discriminate mononuclear cells, to collect data about their immunocompetence and characterise their response to stressful stimuli.

Material and methods

Twenty-two peripheral blood samples were collected in EDTA tubes from roe deer (n = 5), red deer (n = 3), fallow deer (n = 8) and alpine ibex (n = 6). The animals were sampled in private farms and in

wildlife rescue centres or during marking captures in Stelvio National Park, Italy. Air-dried smears were stained using both Hemacolor[®] (Merck KGaA, Darmstadt, Germany) and ANAE staining (Sigma-Aldrich, Inc. Runnymede Malthouse Egham, UK) kits following the manufacturer's recommendations. A total of 100 leukocytes per smear were counted under 100X magnification and dimension of the cells, nuclear morphology, size and colouration of the granules was used for differentiation. Statistical analysis was performed using SPSS Statistics[®] for Windows (Version 17.0. Chicago: SPSS Inc). We used an analysis of concordance (Cohen's kappa) to compare the two staining techniques, while one way ANOVA was performed considering the different species and the anamnestic variables: capture (n = 11, free-living or farmed, captured by drive nets or telenarcosis), captive detention (n = 7, animals confined in little enclosure and capture cages, for a limited time), and sick animals (n = 4, presenting systemic bacterial or viral infections).

Results and discussion

Differential leukocyte counts from the two methods showed great concordance for PMN (Cohen's kappa = 0.990), lymphocytes (Cohen's kappa = 0.978) and monocytes (Cohen's kappa = 0.903). ANAE positive staining was observed in different leukocyte subtypes of the studied species. Diffused and intense granular pattern was observed in monocytes (figure 1-A), negative lymphocytes showed no granulation (figure 1-B) while L+ showed 1 to 3 big, perinuclear (figure 1-C) or many small and diffuse black granules (figure 1-D). Interpretation was easier on fallow deer where clear positive granules were present only in mononuclear cells. Roe deer had a similar, but less intense response. Positive PMN in red deer and alpine ibex could lead to some misidentification.

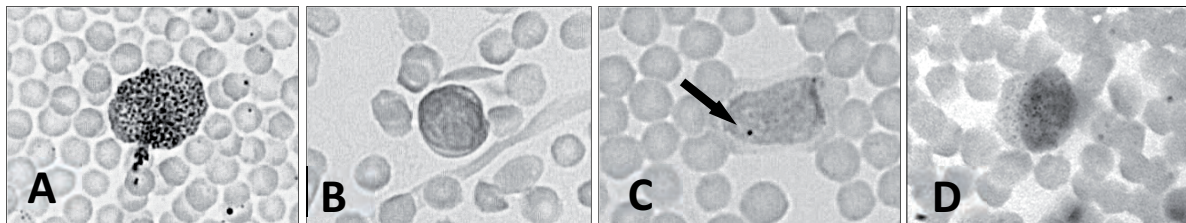


Fig. 1: ANAE staining in red deer's mononuclear blood cells.

Higher values of L+ were found in sick animals (one way ANOVA: $F = 19.532$, $P < 0.01$) showing a less intense reaction and smaller granules, indicating that they could be immature activated T cells (ALTUNAY et al., 2008) responding to pathogens. The decrease of these cells in the other two groups could be associated with the acute stress due to capture and handling (EDWARDS et al., 1984). Mean results of subpopulations per species are reported in percentage in table 1. Average L+ counts were lower than those previously reported from goat and cattle (63.6 % and 63 % respectively), and positivity in PMN cells was described only in goats (ALTUNAY et al., 2008). L+ percentage differences could be due to different staining methods and pH (7.6 in our study, 5.8 in others). Despite the limited number of samples analysed, L+ seemed to better correlate to pathological status than leucogram by Hemacolor[®], where no statistical difference on leukocytes subpopulation was found between sick and healthy animals (one way ANOVA test, neutrophils $F = 2.907$; eosinophils $F = 7.741$; basophils $F = 1.725$; lymphocytes $F = 1.070$ and monocytes $F = 0.016$, all $P > 0.05$). Although there was no difference between the two staining in monocyte and lymphocyte differentiation, ANAE provides more information by differentiating T and B cells. Moreover, the correlation between L+ percentage and severe pathology could be useful for prognosis, therapy and health status evaluation in wild ruminant populations.

Tab. 1: Mean haematological results per species (%), H = hemacolor[®]; A = ANAE[®] staining; N = neutrophils; E = eosinophils; B = basophils; L = lymphocytes; M = monocytes; + = positive ANAE pattern (percentage referred to the subpopulation considered).

	n	H PMN	A PMN	H N	H E	H B	A PMN +	H L	A L	A L+	H M	A M
ROE DEER	5	59.71	57.63	57.04	1.85	0.82	0.00	38.21	41.21	36.21	2.08	1.16
RED DEER	3	67.87	44.83	58.38	4.44	1.30	4.10	30.74	27.24	42.97	1.50	2.18
ALPINE IBEX	6	73.77	77.72	71.16	1.49	0.48	32.81	22.36	17.91	24.97	4.27	4.06
FALLOW DEER	8	64.44	66.21	56.76	7.12	0.56	0.00	33.14	32.18	25.89	2.44	1.58

Acknowledgements

We would like to thank Luca Pedrotti and Alessandro Gugiatti from Stelvio National Park, Krios Redaelli from Sondrio C.R.A.S., Piero Milani from "il pettirosso" C.R.A.S. and Alessia Chiappini from Brescia C.R.A.S. This study is a part of a project funded by the Italian Ministry of Health, Department of Veterinary Public Health, Food Safety and Collegial Bodies for Health Protection.

References

- ALTUNAY H, HAREM I, HAREM M, ASTI R, KURTDEDE N (2008): Determination of acid α -naphthyl acetate esterase enzyme activity in peripheral blood leukocytes of gazelles (*Gazella subgutturosa*). *Biotech. Histochem.* **83**, 279 - 283.
- EDWARDS A, BACON T, ELMS C, VERARDI R, FELDER M, KNIGHT S (1984): Changes in the populations of lymphoid cells in human peripheral blood following physical exercise. *Clin. Exp. Immunol.* **58**, 420 - 427.
- HIGGY K, BURNS G, HAYHOE F (1977): Discrimination of B, T and null lymphocytes by esterase cytochemistry. *Scand. J. Haematol.* **18**, 437 - 448.
- KNOWLES II D, HOFFMAN T, FERRARINI M, KUNKEL H (1978): The demonstration of acid α -naphthyl acetate esterase activity in human lymphocytes: usefulness as a T-cell marker. *Cell Immunol.* **35**, 112 - 123.
- ROBINSON M, O'BRIEN R, MACKINTOSH C. GRIFFIN F (2008): Differential immune responses of red deer (*Cervus elaphus*) following experimental challenge with *Mycobacterium avium* subsp. *paratuberculosis*. *Clin. Vaccine Immunol.* **15**, 963 - 969.
- CHALEOW S, JARERNSAK S, CHAINARONG K, NIRACHARA R, GAVIL N (1998): Blood cell morphology of Rusa Deer (*Cervus timorensis russa*). *Kasetsart J.* **32**, 485 - 494.
- TUZCU M, SUR E, CELIK I, ÖZNURLU Y, ÇİFTÇİ MK (2010): Effects of aflatoxin on the proportions of peripheral blood leukocytes and alpha-naphthyl acetate esterase (ANAE) positive lymphocytes in the mouse. *Kafkas Univ. Vet. Fak. Derg.* **16**, 337 - 341.
- YANG T, JANTZEN P, WILLIAMS L (1979): Acid alpha-naphthyl acetate esterase: presence of activity in bovine and human T and B lymphocytes. *Immunology* **38**, 85 - 93.
- YENER Y, SUR E, TELATAR T, ÖZNURLU Y (2011): The effect of acrylamide on alpha-naphthyl acetate esterase enzyme in blood circulating lymphocytes and gut associated lymphoid tissues in rats. *Exp. Toxicol. Pathol.* **65**, 143 - 146.

TREATMENT OF AN INJURED WING IN AN AUSTRALIAN PELICAN (*PELECANUS CONSPICILLATUS*) USING A NEW WOUND-HEALING STIMULANT

GRANDE F¹, FIORUCCI L¹, CROSTA L², GUERREIRO E¹

¹Zoomarine Italia SpA, Via Casablanca n.61, 00040 Pomezia (Roma), ITALY; veterinari@zoomarine.it

²ValCurone Clinica Veterinaria, Via Kennedy n.14, 23783 Missaglia (LC), ITALY

Birds under human care may undergo traumas requiring medical or surgical treatment. Most of these injuries have a traumatic origin, such as self-trauma, aggression and collision. This case report describes the medical treatment of a soft tissue wound located at the ventral surface of the right wing of a young Australian pelican (*Pelecanus conspicillatus*) female. The pelican was hosted with other conspecific birds in a lake at Zoomarine Italia, Italy. The animal was found by the keeper with the wing trapped in the fence surrounding the pond. The wound was immediately rinsed and cleaned, but not sutured, due to the significant lack of tissue and the possible tension of the skin, that a suture would probably create. A symptomatic therapy was started with 125 mg injectable enrofloxacin SID (Baytril[®], Bayer S.p.A., Milan, Italy), followed by 450 mg oral clindamycin SID (Dalacin[®] C, Pfizer Italia srl, Latina, Italy), for a long-term and better tolerated therapy. Also, 1 mg meloxicam SID (Metacam[®], Boehringer Ingelheim Vetmedica GmbH, Ingelheim, Germany) and B vitamin complex supplementation (Be-Total[®], Johnson & Johnson S.p.A., Pomezia, Italy) were administered and the bird was temporarily housed in an aviary with a small tank to allow the animal access to the water. A recently developed wound-healing stimulant in an oily form, Neem tree and *Hypericum perforatum* extract (*Hypermix Vet*[®], RI.MOS. srl, Mirandola, Italy), never used in pelicans according to literature, was applied twice a day after cleaning the wound with warm saline (0.9 %). In the first week, a "figure eight bandage" was applied after treatment, then, to avoid muscular atrophy, we decided to leave the wound without any bandage. After one month of therapy the wound was completely healed. After three months, the pelican began to fly normally again. General status of health, management and nutrition of the avian patient are very important in wound healing. Proper management of traumatic injuries in birds is important because significantly decreases complications and wound-healing time. In the presented case we achieved good results by using a wound-healing stimulant based on Neem tree and *Hypericum perforatum* extract, but more experience is needed in order to prove the general benefit of this treatment.

SEMI-FREE VERSUS WILD JAPANESE MACAQUES (*MACACA FUSCATA*) – A META-ANALYSIS OF ENDOCRINE AND DEMOGRAPHIC PARAMETERS

GUTLEB DR, PFLÜGER LS, WALLNER B

University of Vienna, Dept. of Anthropology, Althanstraße 14, 1090 Vienna, AUSTRIA;
daria@gutleb.at

Semi-free animal keeping represents an established method in the field of primate conservation. An inevitable constraint of such a conservation type is space limitations for individuals. In most primate species sexually matured males disperse from their natal group which is impossible under semi-free conditions. The aim of this study was a comparison between male Japanese macaques (*Macaca fuscata*) living under semi-free conditions in Austria and free-ranging males in Japan, concerning endocrine and demographic parameters. Due to the prevention of male dispersal, differences in group composition and male steroid excretion were expected. During the data acquisition in 2012 the Austrian population consisted of 51 adult females, 35 adult males (mean age \pm SD = 12.5 ± 4.2 years), 54 juveniles and infants. The two reference populations consisted of 88/23 adult females, 10/20 adult males (mean age \pm SD = $16.7 \pm 1.7/9.3 \pm 3.9$ years) and 70/41 immature individuals. All studies conducted faecal testosterone (fTM) and cortisol (fCM) quantifications and behavioural observations for the assessment of social rank. Compared to free-ranging Japanese macaques, the Austrian population exceeded the average group size, differed in group composition, and males had significantly higher levels of fTM and tendencies of higher fCM. In all three populations fTM and fCM were not related to age. Similar to free-ranging males, social rank was found to correlate with age in the Austrian population. However, unlike the reference populations there was no correlation of social rank and fTM or fCM in this population. These results are further discussed in this study. Physiological and behavioural data of expanding semi-free populations should be regularly monitored to assure high quality animal keeping. Thereby anomalous social dynamics and hormone-related diseases could be prevented.

EXTERNAL TEMPERATURE LOGGERS AS A NON-INVASIVE METHOD OF ESTIMATING BODY TEMPERATURE IN TWO AGAMID SPECIES

HALCK ML, BERTELSEN MF

Copenhagen Zoo, Center for Zoo and Wild Animal Health, Frederiksberg, DENMARK; mlh@zoo.dk

Intracoelomic dataloggers allowing continuous measurement of body temperature are used for physiological and biomedical research. The small size and weight (3.3 g) of implants like the iButton datalogger make them useful even in small species. However, the need for repeated coeliotomy carries inherent risks for infection and other complications.

We here describe a method of replacing the intracoelomic logger with two externally placed loggers in two agamid species, thereby being able to non-invasively measure body temperature with minimal stress to the reptile. In an attempt to validate the use of external dataloggers, animals were instrumented with three temperature loggers (iButton thermochrome datalogger DS1921G). One logger was coated with silicone and implanted intracoelomically during anaesthesia. After two weeks, a velcro-belt was placed around the thorax, with a logger placed on the dorsal and ventral surface, and body temperature fluctuations were measured for at least two days. The correlation between the average of the two external loggers and the surgically implanted intracoelomic logger was analysed by Pearson's Correlation. In the common agama (*Agama agama*) the correlation ranged between 0.967 and 0.976. In the bearded dragon (*Pogona vitticeps*) the correlation ranged between 0.853 and 0.976. The agamas displayed the same behaviour with and without the loggerbelt. The loggerbelt was therefore considered minimally stressful and without significant impact on behaviour.

The high correlation between the external and the intracoelomic logger indicates that the externally placed temperature loggers can be used as an excellent estimate of core body temperature in agamid species.



Fig. 1: iButton thermochrome DS1921G (1.6x1.7x0.6cm). (Photo: embedded data systems)



Fig. 2: A bearded dragon with external loggers. (Photo: Halck ML)

EXPERIENCES FROM *IN SITU* AND *EX SITU* TRAINING OF SUMATRAN ZOO AND WILDLIFE VETERINARIANS

HATT J-M¹, JAYA Y², ERDIANSYAH R³, FREY R⁴

¹University of Zurich, Vetsuisse Faculty, Clinic for Zoo Animals, Exotic Pets and Wildlife, Winterthurerstrasse 260, 8057 Zurich, SWITZERLAND; jmhatt@vetclinics.uzh.ch

²Sumatran Orangutan Conservation Programme, Medan, INDONESIA

³Faculty of Veterinary Medicine, University of Syiah Kuala, Province of Aceh, INDONESIA

⁴Paneco Foundation, 8415 Berg am Irchel, SWITZERLAND

Zoo and wildlife veterinarians frequently become involved in training programmes especially in developing countries. From a conservation point of view such programmes can be very important, since most hotspots of endangered species are in developing countries. Two main approaches exist – (1) onsite training, or (2) inviting the trainees to the institution which offers the training. Every training programme must consider which of these two approaches – *in situ* training versus *ex situ* training - is most efficient and most sustainable.

Here we discuss experiences made from 2009 until 2011, during a joint zoological medicine training programme carried out between the University of Zurich, the University of Syiah Kuala in Banda Aceh, Sumatra, and the Paneco Foundation, a Swiss non-governmental organisation involved in nature conservation in Sumatra. The *ex situ* training comprised visits of eight Indonesian wildlife veterinarians at the University of Zurich and the Zurich Zoo for one month. The *in situ* training was conducted by one faculty member of the University of Zurich, who spent six months on Sumatra, teaching at the University of Banda Aceh and in the field.

From a financial point of view the eight one-month visitations in Switzerland resulted in similar costs as the six-month visitation in Sumatra by one faculty. The impact for conservation of the two approaches, i.e. *in situ* and *ex situ* training was not evaluated systematically. Subjectively however *in situ* training was felt to be superior from a didactic and sustainability point of view.

Acknowledgements

The authors wish to acknowledge the outstanding support of the following persons in this project (in alphabetical order): Dr. Darmawi, Prof. Dr. Hans Lutz, Dr. Ian Singelton, and Dr. Chris Stremme.

**EVALUATION OF CHEMICAL IMMOBILISATION WITH
MEDETOMIDINE-TILETAMINE-ZOLAZEPAM-BUTORPHANOL AND
MEDETOMIDINE-KETAMINE-BUTORPHANOL IN
RED-EARED SLIDER TURTLES (*TRACHEMYS SCRIPTA ELEGANS*)**

IANNACCONI M¹, SANNA PASSINO E², CAMPOLO M³, BONO L⁴, SECCI F², COLUMBANO N²

¹Centro Veterinario il Mondo degli Animali Esotici, Via S. Martino 67R, 16131 Genova, ITALY;
veterinariaesotici@gmail.com

²Dipartimento Medicina Veterinaria, Via Vienna 2, 07100 Sassari, ITALY

³Parco Zoo Delle Maitine, Contrada delle Maitine, 82020 Pesco Sannita (BN), ITALY

⁴Parco Faunistico Cappeller, Via Marabelli, 36050 Cartigliano, Vicenza, ITALY

Aim of this study was to compare different anaesthetic combinations in healthy red-eared sliders (*Trachemys scripta elegans*) for a routine check prior to moving the animals in a different part of the zoo. Twenty-four patients were randomly divided in two groups: TZBM, receiving tiletamine-zolazepam (10 mg/kg) (Zoletil 100[®], Virbac, Carros Cedex, France), butorphanol (0.6 mg/kg) (Nargesic[®], ACME, Cavriago, Italy), medetomidine (0.2 mg/kg) (Domitor[®], Elanco Animal Health, Sesto Fiorentino, Italy); KBM, receiving ketamine (10 mg/kg) (Lobotor[®], ACME, Cavriago, Italy), butorphanol (0.6 mg/kg) and medetomidine (0.2 mg/kg). Heart-rate (HR), respiratory-rate (RR), reflexes and depth of anaesthesia were recorded. Atipamezole (1 mg/kg) (Antisedan[®], Elanco Animal Health, Sesto Fiorentino, Italy) was administered after 60 minutes and the recovery-time was recorded. Statistical analysis was performed. First signs and maximum level of sedation were achieved at 5 ± 1 and 22.50 ± 5 minutes with TZBM, 6.50 ± 1 and 21 ± 2.12 minutes with KBM respectively. All patients showed apnea. After 60 minutes HR decreased in both groups ($P < 0.05$). Corneal, vent and pinch reflexes were maintained during the whole procedure.

After atipamezole administration, spontaneous ventilation was resumed after 6 ± 2.66 minutes in TZBM, followed by incoordination and ataxia in all subjects except one, while in KBM it took 4 ± 2.12 minutes ($P < 0.05$), and three patients showed signs of incoordination with concurrent spontaneous ventilation. Recovery-time was 21 ± 9 minutes in TZBM, and 16 ± 12 minutes in KBM. With KBM all subjects were awake after 120 minutes; with TZBM the animals appeared deeply sedated even at 480 minutes ($P < 0.05$).

Both protocols provide effective and safe chemical immobilisation of patients. The TZBM protocol is associated with incoordination and ataxia. Additional analgesia for surgery may be required.

POST MORTEM INVESTIGATION OF STRANDED SEALS (*PHOCA VITULINA* AND *HALICHOERUS GRYPUS*) IN THE SOUTHERN WADDEN SEA AND NORTH HOLLAND PROVINCE, THE NETHERLANDS, 2009 - 2013

IJZER J¹, KEESLER RI¹, KIK MJL¹, BRASSEUR SMJM², VERDAAT H², GRÖNE A¹

¹Utrecht University, Faculty of Veterinary Medicine, Dept. Pathobiology, Yalelaan 1, 3584 CL Utrecht, THE NETHERLANDS; ijizer@uu.nl

²IMARES Ecology dept. Texel, P.O. Box 167, 1790 Den Burg, THE NETHERLANDS

In recent times, populations of marine top predators have grown dramatically in the southern North Sea. Long-term monitoring of seal numbers in Dutch waters proves particularly useful to describe this change. However, there is still very little knowledge on the factors driving this growth, or potentially limiting this through mortality.

Between 2009 and 2013, 169 seals were submitted for *post mortem* examination (harbour seal, *Phoca vitulina* n = 132; grey seal, *Halichoerus grypus* n = 19; unknown n = 18). All animals stranded on the Northwestern coasts of the Netherlands, including the island of Texel. The seals were found dead, or died within 24h after being taken into rehabilitation. At stranding, species, location and date of stranding were recorded.

All animals were subjected to an extensive standard necropsy protocol including measurements of biometrical data, photography, macroscopic examination, nutritive condition code (NCC), decomposition code (DCC) and scored for likelihood of bycatch. Depending on DCC, samples were taken for histopathology, parasitology, and bacteriological culture. For every individual, pathological lesions were evaluated and the most likely cause of death was determined.

Here, a first analysis of the data is presented, including an overview of the prevailing diseases, affected organ systems, and the most important causes of death. This is compared to the spatial, temporal and age distribution of the necropsied animals including local population size and recorded strandings of all seals (including those that were not presented for necropsy). Possible anthropogenic factors and importance of found diseases for the further development of the population will be discussed.

EVALUATION OF HAEMOPARASITES IN A POPULATION OF FREE-LIVING SLOTH SPECIES (*CHOLOEPUS HOFFMANNI* AND *BRADYPUS VARIEGATUS*) IN NORTHERN COSTA RICA

JIMÉNEZ M¹, HAGNAUER I¹, MENESES A², BLANCO K¹

¹Universidad Nacional, Campus Benjamín Nuñez, Escuela de Medicina Veterinaria, Hospital de Especies Menores y Silvestres, P.O. Box 83-3000, Lagunilla, Barreal, Heredia, COSTA RICA; drmjimenezsoto@hotmail.com, isahgb@gmail.com, pchacon@gmail.com, kinnvet@yahoo.es

²Universidad Nacional, Campus Benjamín Nuñez, Escuela de Medicina Veterinaria, Laboratorio de Análisis Clínicos, Apartado 83-300, Lagunilla, Barreal, Heredia, COSTA RICA; anag.meneses@gmail.com

In the last years, we conducted a multidisciplinary project on the two Costa Rican sloth species, the Hoffmann's two-toed sloth (*Choloepus hoffmanni*) and the brown-throated sloth (*Bradypus variegatus*), residents in a cocoa (*Theobroma cacao*) plantation in northern Costa Rica. As a part of the study, blood samples were collected from 45 *Choloepus hoffmanni* and 58 *Bradypus variegatus* during summer, and blood smears were prepared for each individual in order to determine the prevalence and diversity of haemoparasites in these sloth species. The animals were captured manually and placed in burlap bags for transport to the sampling place. In the case of *C. hoffmanni*, blood sampling was performed under sedation with a combination of dexmedetomidine (Dexdomitor[®], Pfizer, NY, USA; 1.0 mg/ml; 0.02 mg/kg) and ketamin (Ketamin 10 %, Bremer Pharma GMBH, Warburg, Germany; 100 mg/ml; 2.5 mg/kg) by subclavia venipuncture. Atipamezole (Antisedan[®], Orion Pharma, Espoo, Finland; 5 mg/ml) was used 30 minutes after the application of dexmedetomidine to antagonise its effect. For *B. variegates*, sampling was performed only with manual restraint also by subclavia venipuncture.

Blood smears were performed in the field, air dried and transported to the laboratory, where they were stained with May Grünwald-Giemsa dye and examined by a light microscope at 100X magnification. Contrary to studies on other sloth species, only 4.85 % of the animals (two *C. hoffmanni* and three *B. variegatus*) were positive to microfilaria, probably because the sampling was conducted during the dry season and samples were taken during the day, when vector populations could be diminished.

Further studies are needed at different times of the year in order to determine the impact of these species as reservoirs for haemoparasites in the north of Costa Rica and its implications on the health of the sloths.

GENERAL ASSESSMENT OF REINTRODUCTION PROGRAMMES OF *ARA MACAO* IN COSTA RICA

JIMÉNEZ M, TORRES AM, HAGNAUER I, BLANCO K

Universidad Nacional, Campus Benjamín Nuñez, Escuela de Medicina Veterinaria, Hospital de Especies Menores y Silvestres, P.O.Box. 83-3000, Lagunilla, Barreal, Heredia, COSTA RICA; drmjimenezsoto@hotmail.com; amtmga@gmail.com; isahgb@gmail.com; kinnvet@yahoo.es

In Costa Rica, only few releasing programmes of psittacines have a well-established health protocols. They are almost exclusively based on ethological aspects, and only in a few cases infectious diseases are monitored. In addition, the institutions which are responsible for monitoring projects normally do not handle health information properly, leaving the process to the discretion of the institutions. One of the most popular wildlife species in these programmes, the scarlet macaw (*Ara macao*), is listed in Appendix I of the Convention on International Trade in Endangered Species of Wild Fauna and Flora, and considered as threatened in the IUCN Red List. Therefore, since 1980 captive breeding programmes for reintroduction and reinforcement of these animals have been initiated in Costa Rica. The goal of this study was to evaluate the first three reintroduction projects under consideration of seven parameters: previous population studies, captive management, release protocols, health management of populations, post-release monitoring, social impact and institutional support. Evaluation of health study and post-release monitoring showed positive results, while the institutional support and implementation of previous population studies were negatively influences. Significant differences were found between the best and worst rated projects based on the parameters: captive management, release protocols and social impact.

The results obtained showed the necessity for unification of the criteria for implementation of reintroduction programmes in Costa Rica, in order to optimise available resources and the chances of success.

BLOOD VALUES OF CAPTIVE CHEETAHS (*ACINONYX JUBATUS*) IN THE UNITED ARAB EMIRATES

KAISER C¹, VARUGHESE AA², LIESEGANG A^{1,3}

¹Vetsuisse Faculty Zurich, Institute of Animal Nutrition, Winterthurerstrasse 260, 8057 Zurich, SWITZERLAND; claudiakaiser-vet@gmx.de

²Central Veterinary Research Laboratory, P.O. Box 597, Dubai, UNITED ARAB EMIRATES

³University of Zurich, Center for Applied Biotechnology and Molecular Medicine, Winterthurerstrasse 190, 8057 Zurich, SWITZERLAND

Ataxia and hind limb paresis have been reported in many cheetahs (*Acinonyx jubatus*) in the European Endangered Species Programme (EEP) as well as the United Arab Emirates within zoos, private collections and wildlife parks over the last decade. Nutritional deficiencies like copper and Vitamin A have been associated with the etiology of such cases.

Blood samples of 23 cheetahs were tested for serum Vitamin A (VA), Vitamin E (VE), copper (Cu), selenium (Se) and zinc (Zn) at the Central Veterinary Research Laboratory in Dubai, UAE. Since it was a retrospective study not all animals were tested for each parameter. Animals were split into two different groups according to the base diet they received. The food these animals received was also analysed for minerals like calcium (Ca), phosphorus (P), Se, Cu and Zn.

Cheetahs that received a pure chicken meat diet only were the only ones affected with neurological signs, like ataxia and hind limb paresis. None of the animals that received a supplemented whole carcass prey diet was affected. The mineral content, especially the calcium-phosphorus ratio in pure chicken diets was unbalanced. Cu and VA serum concentrations of animals fed a supplemented diet were higher than those that received a pure chicken meat diet only.

THE USUAL SUSPECTS: CASES OF *CLOSTRIDIUM PERFRINGENS* AND *CLOSTRIDIUM DIFFICILE* IN CAPTIVE ELEPHANTS IN EUROPEAN ZOOS

KOROKNAI V¹, MOLNÁR V^{1,3}, LAJOS Z², GÁL J³, SÓS E¹

¹Budapest Zoo and Botanical Garden, Állatkerti krt. 6-12., 1146 Budapest, HUNGARY;
drkoroknai@zoobudapest.com

²Duo-Bakt Veterinary Microbiological Laboratory, Váci út 174., 1138 Budapest, HUNGARY

³Szent István University, Faculty of Veterinary Science, Dept. of Exotic Animal and Wildlife Medicine, István u. 2., 1078 Budapest, HUNGARY

Summary

Following the death of an Asian elephant (*Elephas maximus*) cow in 2011 at the Budapest Zoo where the cause of death was confirmed to be clostridial enteric disease, we decided to perform a study through means of a questionnaire in order to gather information about the frequency and course of such cases throughout the European zoo community. We hoped to piece together the puzzle and gain insight into the causes, course and treatment of such cases. Owing to a relatively low response rate we were about to compare the cases with which we were presented, however our original questions not only remained unanswered, but further questions arose.

Introduction

Our research into the background of the clostridial enteric diseases caused by *Clostridium perfringens* and *Clostridium difficile* in captive elephants and the sudden and devastating illness they cause, was triggered by a case of this nature at the Budapest Zoo in April 2011 which resulted in the death of the individual. The animal in question, a 42 year old, Asian elephant (*Elephas maximus*) cow, succumbed to *C. difficile* caused enteric disease following a vague and general clinical picture which included diarrhea, anorexia and listlessness. Despite all our efforts, which included rigorous fluid therapy, antibiotics, spasmolytics and painkillers, the individual's condition deteriorated very rapidly until she was finally euthanised to prevent her further suffering. *Post mortem*, necrotising colitis along with haemorrhagic and edematous enteritis were found with signs of systemic involvement through haemorrhagic lesions and inflammatory cell infiltration in the liver and lungs, and follicular lymphoid hyperplasia throughout the alimentary tract. Samples taken from the digestive tract yielded a strong positive result for *C. difficile* toxin A and B through ELISA.

Materials and methods

With literature providing evidence of further cases of a similar nature over the past few years, in Switzerland (BACCIARINI et al., 2001), Denmark (BOJESSEN et al., 2006) and Germany (FLÜGGER, 2000), we decided to perform a Europe-wide questionnaire in order to gain further insight into the frequency of such cases as well as their outcome and implication in the European captive elephant population as this has not been summarised to date. This survey included all zoos keeping African elephants (*Loxodonta africana*) and Asian elephants (*E. maximus*) and was sent out through the EEP coordinators of the respective species under the guidance and approval of the vet advisors. The goal was to collect, compare and contrast available information, and attempt to reveal the underlying story behind

cases of enteric disease caused by *C. perfringens* and *C. difficile* in captive elephants in Europe between 1990 and 2012 and to devise a protocol for management of future cases.

Results and discussion

On the Asian elephant front, we received 27 out of 70 (39 %) responses and 18 out of 48 (37 %) from institutions keeping African elephants, with a total of 45 out of 118 (38 %). From these, seven cases of clostridial disease were reported in total (including the case at the Budapest Zoo), five in Asian elephants and two in their African counterparts. From these reported cases, three reported the presence of *C. perfringens post mortem*, *C. difficile* was noted in another three, and in one instance this information was not provided. It is important to note that the information presented as part of this study was only as good as the information we received as part of the questionnaire from the given institutions. In some cases detailed records were available and ample information was provided for three of the cases that were published, but the scarcity of data did make our work more difficult. Clinical signs, in the described cases where information was available, showed similar trends with diarrhea and inappetence present in most cases along with a rapid and devastating course, which in most individuals proved unresponsive to aggressive treatment protocols. However information with regards to successful treatment was described in two instances (BOJESEN et al., 2006; FLÜGGER, 2000) and the application of these could prove useful in the management of future cases. As a definitive diagnosis is rather difficult to obtain owing to the rapid course of the illness, therapeutic measures tended to involve fluid therapy, pain management and antibiotics. *Post mortem* lesions described in the various cases painted a similar picture to our case at the Budapest Zoo with ulcerative and pseudomembranous lesions present in some cases in addition to the necrotizing and haemorrhagic lesions we found. The majority of the cases involved the small intestine, particularly the ileum, and the caecum with additional signs of systemic disease described as lesions in the liver, spleen and regional lymph nodes. Histopathologically lymphocytes and heterophils were found to be the most common invaders in the alimentary tracts of the diseased elephants. Information with regards to methods of detection of the causative agent or the toxins they produce varied between cases though ELISA and PCR were primarily used. In cases where *C. perfringens* was found to be the culprit, beta-2 toxins were found in conjunction with the causative agent, whilst in those instances where *C. difficile* was responsible, toxins A and B were reported. It is important to emphasise that in all areas of our study that pertained to the questionnaire, our results were only as good as the information we received from the respective institutions across Europe, and this accounted for much of the discrepancy of data concerning details in the various cases.

One of the questions in our survey pertained to screening of the European elephant population on *C. difficile* to determine whether or not these bacteria can also be found in clinically healthy elephants. As it is stated that can sometimes be the case in healthy horses (MEDINA-TORRES et al., 2011), there is also evidence in the literature to state the opposite (BOJESEN et al., 2006) in captive elephants. Thus, this question was included owing to the fact that the case at the Budapest Zoo was caused by *C. difficile* and following the death of the individual, all of our Asian elephants were screened and positive samples were obtained. Furthermore, through our survey we found that screening for *C. difficile* is done routinely in several zoos in Europe and as a continuation of our study we were curious to see what the story was on a larger scale. Since then, we have tested the elephant populations of three zoos for both the presence of *C. difficile* and its toxins, with a 100 % negative result following testing of seven Asian and eight African individuals. This area of our study is one of the many aspects of this complex problem into which more time and energy must be placed in order to further research the role of these bacteria in the alimentary tract of captive elephants. Furthermore, not only the microbiological background of these devastating cases must be emphasised and further

investigated, but additionally, the underlying cause of why disease is presented in such cases (for example at the Budapest Zoo the individual in question had been receiving treatment for a chronic foot problem), must be looked into in attempt to prevent the occurrence of future problems.

References

- BACCIARINI LN, PAGAN O, FREY J, GRÖNE A (2001): *Clostridium perfringens* beta2-toxin in an African elephant (*Loxodonta africana*) with ulcerative enteritis. *Vet. Rec.* **149**, 618 - 620.
- BOJESSEN AM, OLSEN KEP, BERTELSEN MF (2006): Fatal enterocolitis in Asian elephants (*Elephas maximus*) caused by *Clostridium difficile*. *Vet. Microbiol.* **116**, 329 - 335.
- FLÜGGER M (2000): *Clostridium perfringens* enterotoxaemia in an Asian elephant (*Elephas maximus indicus*) – a case report. *Proc. Europ. Assoc. Zoo Wildl. Vet.* **3**, 183 - 187.
- MEDINA-TORRES CE, WEESE JS, STÄMPFLI HR (2011): Prevalence of *Clostridium difficile* in horses. *Vet. Microbiol.* **15**, 212 - 215.

BATS ROOSTING IN PREFAB HOUSES IN SLOVAKIA - A FOUR YEAR RESEARCH AND CONSERVATION EFFORT

KORYTÁR L^{1,2}, ONDREJKOVÁ A¹, ONDREJKA R¹, PROKEŠ M¹, ČECHVALA P¹

¹The University of Veterinary Medicine and Pharmacy in Košice, Komenského 73, 04181 Košice, SLOVAKIA; korytar.uvm@gmail.com

²Slovak Bat Conservation Society, Andraščíkova 1, 08501 Bardejov, SK [A]

Summary

The occurrence of bats inside prefab houses in six settlements (Košice, Sabinov, Bardejov, Moldava nad Bodvou, Ružomberok and Jasov) in the Slovak Republic was monitored during the period 2009 – 2013. Bats frequently used buildings in urban centres as roosting places. Prefab houses (blocks of flats) were critical from a human-bats conflicts view point. In total, 598 bats were removed from the inhabited interiors of buildings. Finally 592 bats were returned into the environment. Species mosaic consisting of the common pipistrelle (*Pipistrellus pipistrellus*), the soprano pipistrelle (*Pipistrellus pygmaeus*), the serotine (*Eptesicus serotinus*), the noctule (*Nyctalus noctula*) and the parti-coloured bat (*Vespertilio murinus*) were recorded. Also the public health risk in connection with potential European bat lyssavirus (EBLV) infection in bats was studied using a serological method. No serological evidence for EBLV infection was observed.

Introduction

Bats are commonly encountered in Slovakia where they use a variety of natural and seminatural habitats throughout the year. It has been proven that 28 species of bats from two families (Rhinolophidae and Vespertilionidae) occur in the Slovak Republic territory (KRIŠTOFÍK and DANKO, 2012). The chiropteroфаuna is an important component of the ecosystem in various types of landscape on the Slovak Republic territory. The process of urbanisation has an impact on bat species worldwide and the research indicates that different bat species vary in their response to urbanisation. The individual bat species show considerable ecological differences manifested by their requirements in roosting places, hunting, mating, wintering etc. (JOHNSON et al., 2008).

In Slovakia, the common pipistrelle (*Pipistrellus pipistrellus*), the serotine (*Eptesicus serotinus*), the noctule (*Nyctalus noctula*) and the parti-coloured bat (*Vespertilio murinus*) were described as the most common bat species dwelling in blocks of flats or prefab-houses (MATIS and DITTEL, 1997; LEHOTSKÁ and LEHOTSKÝ, 2000; ČLUCH et al., 2006). The presence of bats in prefab houses results in various problems. After gathering into large colonies, bats may disturb the householders by loud noises, smell, excrements etc. Pipistrelles are also known for their typical behaviour called "invasions" where temporarily up to hundreds of bats fill the buildings and "helter-skelter" on various sites (KAŇUCH et al., 2010).

Bats are known as vectors of lyssaviruses. Insectivorous bats play an important role in the epidemiology of rabies and some rabies-like viruses (MCCOLL et al., 2000). Bats are now the most prominent source of human rabies in the New World, western Europe and Australia, especially where the disease in carnivores has been controlled. At the same time, they maintain circulation of lyssaviruses, roost synanthropically and serve as a source of infection for humans and animals. Many bat species are endangered and protected by national and international legislation (KUZMIN and RUPPRECHT, 2007).

In Europe, two bat lyssaviruses referred to as European bat lyssaviruses (EBLVs) types 1 and 2 (genotypes 5 and 6 respectively) which are closely related to classical rabies virus are responsible for a zoonosis. EBLVs are host restricted to bats, but have been known to infect not only their primary hosts but also in rare circumstances, induce spillover infections to terrestrial mammals including domestic livestock, wildlife and man (FOOKS et al., 2003). This is why bats in Slovakia as well as in other countries suffer from a bad public image.

In addition, the actual threat for semisynanthropic bat species roosting in prefab houses is linked to rapid reconstruction and insulation of buildings. This process causes loss of roosting places and whole mating or wintering colonies.

Material and methods

The study was carried out in the years 2009 to 2013. The occurrence of bats inside the buildings was systematically recorded. We collected information provided by householders. Each case was investigated (reaction on public request, field investigation, catching of bats, rehabilitation of bats if needed, analysis of the problem, searching for solutions to avoid direct contact between humans and bats inside the buildings).

The public health risk in connection with potential EBLV infection in bats was studied.

All manipulation with bats was performed by experts provided with the appropriate permits issued by the Ministry of Environment of the Slovak Republic (No. 3501/2008-2.1/jam; No. 5169/2012-2.2 and No. 5376/2009-2.1/jan/2).

Capture of bats

Bats were captured directly inside the buildings using protection gloves, hand net and ultra-thin mist-nets (ECOTONE, Poland).

Processing of bats after the capture

After capture, species, sex and reproductive status of each bat was determined. Each animal was examined for signs of poor health, dehydration and injury.

Animals without health disorders were sampled and released within a few hours after capture.

According to JAHĚLKOVÁ et al. (2009), bats showing symptoms of dehydration and cachectic bats were treated with subcutaneous injection of a combination of rehydration solution *Infusio Ringeri* (IMUNA ěrw Ć" kDĚř Ć ha'an\$, KIYvr kGrřand DUPHAXYT_řA,řĉ řĆ,řř > řřPřřerř} lot, XřřĆř II De ^ Ćn\$a, Kpain),ř

The administration of 0.01 ml of DUPHALYTE per each g of bats' weight showed the best results. Bats were fed with meal worms coated with the premix Roboran H plv. (UNIVIT, Olomouc, the Czech Republic). The dosage of whole rehydration solution was 0.15 ml *pro toto* each 8 hours in small bats (Pipistrelle bats) and 0.5 ml *pro toto* each 8 hours in bigger bats (Noctule bats, parti-coloured bats).

From specimens without signs of health disorders, blood was collected for the serologic survey on EBLV.

Collecting of blood samples

The bat was fixed in dorsal recumbency with extended wing. The sampling site was disinfected with ethanol. Blood was taken by puncture of the antebrachial vein using 0.7 x 30 mm hypodermic needle. The blood (50 – 300 µl) was collected using mechanical micropipette and stored in plastic tubes. After collecting of blood, pressure was applied onto the puncture site to stop the bleeding. The blood sample was centrifuged and the serum was separated into separated tubes. The serum samples were stored at -18°C until further analysis.

After processing, the bats were offered a 10 % solution of glucose. Bats were released at dusk the following evening at the point of capture without further feeding.

Laboratory method

Rapid fluorescent focus inhibition test (RFFIT) according to SMITH et al. (1973) was used for the detection of specific rabies virus neutralising antibodies in the bats' serums. The RFFIT is a lyssavirus neutralisation test performed in cell culture to determine the rabies virus neutralising antibody level in animal sera. Immunofluorescent staining of infected cells is used as an indicator of rabies virus replication. The RFFIT takes ~20 hours and is both sensitive and specific.

The RFFIT is the serological assay recommended for diagnostics of lyssavirus infections by the World Health Organization (WHO).

We used challenge rabies virus strain CVS11/Paris (Institut Pasteur, Paris, France), adapted to replication on BHK21/C13/cell culture, titer $10^{6.0}$ TCID₅₀/0.05 cm³. Sera were titrated on Lab-Tek 8 chamber TC slides. Sera as well as the challenge virus strain were incubated at 37°C during 90 minutes subsequently BHK-21/C13 cell culture was added. The cultures were fixed after 18 hours and stained with antirabic fluorescent conjugate (Bioveta a.s., Ivanovice n. H., Czech Republic). The highest dilution of the virus was used as the challenge dose where 50 % of the cells in the examined range of view were infected (fluorescent inclusions were observed). The antirabic reference serum was used as a control in RFFIT in each examined serum.

Results

Human-bats conflicts

Data were obtained for 39 cases of undesired occurrence of bats inside inhabited buildings in the cities of Košice, Sabinov, Bardejov, Moldava nad Bodvou, Ružomberok and Jasov. During field work, we captured 598 bats belonging to five species (table 1). Finally 592 bats were returned into the environment. Six specimens died due to fatal injuries acquired during their stay inside the buildings.

Tab. 1: Captured bats in years 2009 to 2013.

	<i>E. serotinus</i>	<i>N. noctula</i>	<i>P. pipistrellus</i>	<i>P. pygmaeus</i>	<i>V. murinus</i>
2009	-	7	2	-	2
2010	2	173	195	-	1
2011	-	5	22	1	1
2012	1	58	31	4	4
2013	-	89	-	-	-

Serological survey

A total of 580 bats were systematically sampled for this study (table 2). None of the analysed bats was serologically positive for the presence of lyssavirus-specific antibodies.

Tab. 2: Numbers of serologically examined bats.

Species	No. of bats examined
<i>N. noctula</i>	325
<i>P. pipistrellus</i>	245
<i>P. pygmaeus</i>	5
<i>E. serotinus</i>	2
<i>V. murinus</i>	3

Discussion

According to the available literature (MATIS and DITTEL, 1997; LEHOTSKÁ and LEHOTSKÝ, 2000; C_ĽUCH et al., 2002; C_ĽUCH et al., 2006) the species of bats which we found during the period 2009 to 2013 are common bat species which exploit prefab houses in the Slovak Republic year round. Pipistrelle bats (*P. pipistrellus*) formed maternity colonies during the spring months in the prefab houses. Pipistrelles used the shelters in the buildings also during spring and autumn migration. Large numbers of pipistrelle bats could also be found here during hibernation. DANKO et al. (2012a) described a similar phenology of this species in Slovak conditions.

The soprano bats (*P. pygmaeus*), the sympatric and cryptic species with the pipistrelle bat, were documented in two cases only. The soprano bats were always incorporated into larger groups of pipistrelle bats trapped inside the flats. These two records of soprano pipistrelles incorporated into invasions of pipistrelle bats complement the investigation of KAŇUCH et al. (2010).

The parti-coloured bats (*V. murinus*) inside the houses were recorded always during the hibernation period. It corresponds to the information obtained by other authors (MATIS and DITTEL, 1997; DANKO et al., 2000).

In contrast to the results of other authors (LEHOTSKÁ and LEHOTSKÝ, 2000; DANKO et al., 2012b) we consider the serotine (*E. serotinus*) as the least common bat in buildings in the monitored area. Information on the occurrence of bat species in blocks of flats in Slovakia remains insufficient.

Bats used to enter the buildings through openings of ventilation, unsealed holes for antennae cables, elevator shafts, untightnesses in old windows and cracks between individual pannels. In cases of invasions into buildings intervention of trained specialists is needed. Openings in the outer shell of buildings most advantageously sealed with polyurethane foam and air shafts should be covered with small wire mesh netting. The majority of the found cases were caused by self-trapping of bats (specimens or colonies) inside of the buildings. The availability of drinking water is the most important limiting factor for the survival of trapped bats in buildings.

The serological survey did not show any infection of examined bats with EBLVs. Up to date EBLV was isolated from Slovak bats only twice (ONDREJKOVÁ et al., 2004; ŠVRČ_ŕ et al., 2007).

Acknowledgements

This work was supported by the Slovak Research and Development Agency under the grant No. APVV-0605-12 „Potentiation of vaccines against rabies and other lyssavirus infections using new type of adjuvans and investigation of selected bat pathogens in bat population“.

References

- CEL'UCH M, DANKO Š, KAŇUCH P (2006): On urbanisation of *Nyctalus noctula* and *Pipistrellus pygmaeus* in Slovakia. *Vespertilio* **9 - 10**, 219 - 221.
- CEL'UCH M, KAŇUCH P (2002): Zimný výskyt netopierov v panelových blokoch na sídlisku Sekčov v Prešove. *Vespertilio* **6**, 44. (In Slovak).
- DANKO Š, KAŇUCH P, UHRIN M, KRIŠTOFÍK J, HANZELOVÁ V, ŠPAKULOVÁ M (2012)a: Večernica hvízdavá – *Pipistrellus pipistrellus*. In: Krištofík J, Danko Š (Eds.): *Mammals of Slovakia, distribution, bionomy and protection*. Bratislava, VEDA, 378 - 383. (In Slovak with a summary in English).
- DANKO Š, LEHOTSKÁ B, LEHOTSKÝ R, KRIŠTOFÍK J, HANZELOVÁ V, ŠPAKULOVÁ M (2012)b: Večernica pozdná – *Eptesicus serotinus*. In: Krištofík J, Danko Š (Eds.): *Mammals of Slovakia*,

-
- distribution, bionomy and protection. Bratislava, VEDA, 353 - 360. (In Slovak with a summary in English).
- DANKO Š, UHRIN M, PJENČÁK P, MATIS Š (2000): Netopiere Východoslovenskej roviny, Východoslovenskej pahorkatiny a Zemplínskych vrchov. *Vespertilio* **4**, 37 - 58. (In Slovak with a summary in English).
- FOOKS AR, BROOKES SM, JOHNSON N, McELHINNEY LM, HUSTON AM (2003): European bat lyssaviruses: an emerging zoonosis. *Epidemiol. Infect.* **131**, 1029 - 1039.
- JAHELKOVÁ H, HÁJKOVÁ P, BLÁHOVÁ A (2009): Manuál péče o netopýri. ZO ČSOP 11/30, Praha, *Nyctalus*, 65. (In Czech).
- JOHNSON JB, GATES JE, FORD WM (2008): Distribution and activity of bats at local and landscape scales within a rural-urban gradient. *Urban Ecosyst.* **11**, 227 - 242.
- KAŇUCH P, FURNUSKOVA A, BARTONIČKA T, BRYJA J, ŘEHÁK Z (2010): Do two cryptic pipistrelle bat species differ in their autumn and winter roosting strategies within the range of sympatry? *Folia Zool.* **59**, 102 - 107.
- KRIŠTOFÍK J, DANKO Š (2012): Mammals of Slovakia, distribution, bionomy and protection. Bratislava, VEDA, 712. (In Slovak with a summary in English).
- KUZMIN IV, RUPPRECHT CHE (2007): Bat rabies. In: Jackson AC, Wunner WH (Eds.): *Rabies*. London, Elsevier Inc., 259 - 307.
- LEHOTSKÁ B, LEHOTSKÝ R (2000): Skúsenosti z ochrany zimnej kolónie raniaka hrdzavého (*Nyctalus noctula*) v panelovom dome na bratislavskom sídlisku Dlhé Diely. *Vespertilio* **4**, 105 - 110. (In Slovak with a summary in English).
- MATIS Š, DITTEL L (1997): Jesenné pozorovania *Vespertilio murinus* v niektorých mestách na Slovensku. *Vespertilio* **2**, 141 - 142. (In Slovak with a summary in English).
- McCOLL KA, TORDO N, AQUILAR SETIÉN AA (2000): Bat lyssavirus infections. *Rev. Sci. Tech. Off. Int. Epiz.* **19**, 177 - 196.
- ONDREJKOVÁ A, FRANKA R, ONDREJKA R, ŠVRČEK Š, SÜLI J, BENÍŠEK Z, ZUBRICKÝ P, BAJOVÁ V, BUGARSKÝ A, BOURHY H (2004): Identification of a Lyssavirus isolate from a bat (*Eptesicus serotinus*). *Bulletin of Veterinary Institute in Pulawy* **48**, 11 - 13.
- SMITH JS, YAGER PA, BAER GM. (1973): A rapid reproducible test for determining rabies neutralizing antibody. *Bull. WHO* **45**, 535 - 541.
- ŠVRČEK Š, BAJOVÁ V, ČÍŽEK M, LEVKUTOVÁ M, MOJŽIŠOVÁ J, ONDREJKA R, ONDREJKOVÁ A, SÜLIOVÁ J, VILČEK Š (2007): Súčasný stav poznania o lyssavírusoch a lyssavírusových chorobách, vypracovanie epizootologickej schémy cyklov, foriem a variantov besnoty a ďalších lyssavírusových chorôb. *Slovak Veterinary Journal* **3**, 166 - 171. (In Slovak with a summary in English).

EPIDEMIOLOGY OF *SALMONELLA* ISOLATES FROM SELECTED SPECIES OF FREE-LIVING BIRDS IN POLAND

KRAWIEC M¹, KUCZKOWSKI M¹, RUSIECKI S², WJÓDZIAK A¹, KRUSZEWICZ A³, WIELICZKO A¹

¹Wrocław University of Environmental and Life Sciences, Faculty of Veterinary Medicine, Dept. of Epizootiology and Clinic of Bird and Exotic Animals, Pl. Grunwaldzki 45, 50-366 Wrocław, Poland; alina.wieliczko@up.wroc.pl

²Museum of Natural History, Wrocław University, ul. Sienkiewicza 21, 50-335 Wrocław, Poland

³Warsaw Zoological Garden, ul. Ratuszowa 1/3, 03-461 Warsaw, POLAND

Several reports suggested that free-living birds may play an important role in the maintenance and movement of *Salmonella* spp. The aim of this study was to determine the occurrence and to characterise phenotypic and genetic profiles of *Salmonella* isolates from various species of free-living birds in Poland. A total number of 64 *Salmonella* spp. isolates were obtained from 235 cloacal swabs and 765 faecal samples from different species of wild birds in Poland from September 2011 until August 2013. Positive samples came from the Eurasian siskin (*Carduelis spinus*, n = 16) greenfinch (*Carduelis chloris*, n = 10), great tit (*Parus major*, n = 10), mallard duck (*Anas platyrhynchos*, n = 8), great cormorant (*Phalacrocorax carbo*, n = 8), common starling (*Sturnus vulgaris*, n = 3), Eurasian tree sparrow (*Passer montanus*, n = 2), blue tit (*Cyanistes caeruleus*, n = 1), redpoll (*Carduelis flammea*, n = 1), blackbird (*Turdus melura*, n = 1), rook (*Corvus frugilegus*, n = 1), common wood pigeon (*Columba palumbus*, n = 1), common swift (*Apus apus*, n = 1), Eurasian marsh harrier (*Circus aeruginosus*, n = 1). The isolates were classified to species and subspecies level of *Salmonella* genus by mean of PCR assay. Obtained data indicated that the collected *Salmonella* strains belonged to three *S. enterica* subspecies: *enterica* (52 strains (81.25 %)), *salamae* (11 strains (17.19 %)), and *houtenae* (1 strain (1.56 %)). Eighteen strains belonged to *Salmonella enterica* subsp. *enterica* serovar Typhimurium (28.13 %), one strain to serovar Infantis (1.56 %), one to serovar Virchow (1.56 %) and one to serovar Hadar (1.56 %). Our results confirm that some avian species might be a potential reservoir for different *Salmonella* serovars and suggest a zoonotic risk for humans, either by direct contact with wild birds or indirectly by transmission on poultry, carrier pigeons or other animals kept by people.

Acknowledgements

The research was financed by National Centre for Research and Development. Project No. NR 12 0126 10.

SALMONELLA ENTERICA SUBSP. ENTERICA SEROVAR TYPHIMURIUM AS A CAUSE OF MORTALITY AND CLINICAL SYMPTOMS IN TWO FREE-LIVING GARDEN BIRD SPECIES IN POLAND

KRAWIEC M¹, PIETKIEWICZ M², WIELICZKO A¹

¹ # W ?r=ŕUnŕer" Œŕ Yŕ Envirŕnmental ŕndŕ Xŕ K iences, Facultŕ Yŕ Ceterinŕŕ Medicŕe, Dept. Yŕ Epizootiology and Clinic of Bird and Exotic Animals, Pl. Grunwaldzki 45, 50-366 # W ?r=ŕP} XAND;ŕ alina.wieliczko@up.wroc.pl

² # W ?r=ŕŕ-Ringing Group „ODRA”, ul. # W ?r="kr 3, 5Œ-095 Mirkŕw, POLAND

Salmonella spp. are widespread in nature, being present also as pathogenic bacteria in intestine of domestic and wild animals, including birds. Depending on the bird species a *Salmonella* infection may occur as a clinical disease or asymptotically. Some species of garden birds are regarded to be more than other free-living bird species, sensitive for *Salmonella* spp. infections. In 2013 Poland experienced prolonged winter, with low temperatures and snow precipitations. During March and April, appearance of weak and dead individuals among two birds species, the Eurasian siskin (*Carduelis spinus*) and the greenfinch (*Carduelis chloris*), was reported. In the last week of March and the first week of April 2013, two dead siskins and four dead greenfinches were found in proximity of the bird feeder, located in Œerpŕte pŕperŒ Œ uburban # W ?r=ŕ. DuringŕthŒŒperŒ, Œ the "ŕ! eŕŕverŕ routine ringing took place. At the time of this procedure, faecal samples of all individuals belonging to these two species of birds were collected, regardless clinical symptoms. In total, the following samples were collected from twenty-two birds: thirteen siskins (two dead individuals and eleven faecal samples of alive birds) and nine greenfinches (four dead individuals and five faecal samples of alive birds). *Salmonella enterica* subsp. *enterica* serovar Typhimurium was isolated from all twenty-two examined birds. Eleven of the alive birds (six siskins and five greenfinches) showed both, signs of emaciation and diarrhoea. Necropsy of the dead birds exhibited nodular lesions in liver (four greenfinches, one siskin), spleen (two greenfinches, one siskin) and intestines (two greenfinches). One siskin showed only an enlargement of liver and spleen without nodular lesions. The visible illness among European siskins and greenfinches caused by *S. Typhimurium* might suggest that these two bird species may be potential reservoirs of *Salmonella* spp. Therefore they might play a role in transmission of zoonotic pathogens to other garden bird species or to people. Climate changes might also contribute to higher mortality rates of susceptible bird species, which should be closely monitored.

Acknowledgements

The research was financed by National Centre for Research and Development. Project No. NR 12 0126 10.

SEPTIC POLYARTHRITIS IN CHAPMAN'S ZEBRA (*EQUUS BURCHELLI CHAPMANI*) – CASE REPORT

KVAPIL P, KASTELIC M

ZOO Ljubljana, Večna pot 1, 1000 Ljubljana, SLOVENIA; pavel.kvapil@zoo.si

One week old Chapman's zebra (*Equus burchelli chapmani*) female started to limp on left hind leg. Joint swelling of both hind legs was obvious and clinical exam suggested inflammation of the joints. Septic polyarthritis was diagnosed based on horse medicine diagnostic approach and *Staphylococcus aureus* was cultivated as an etiological agent. With no evident injuries on the surface of the skin, umbilical cord was presumed to be a penetration place for infection. Haematological examination showed mild neutrophilia, biochemical parameters were all within physiological ranges. Radiographic imaging confirmed presence of fluids in tarsal and metatarsophalangeal joints and excluded bone involvement. Therapy based on therapeutical plan usually used in horses, was successful. Zebra stopped limping after four days of antibiotal treatment. Changing bandages and local treatment of necrotic wounds were performed during first month on daily basis. The wounds were cleaned every other day during second and third months of therapy. After four months of therapy the resolution of lesions was complete. Mobility of young zebra was normal, flexion and extension of previously handicapped articulations were not limited. Three years following the treatment zebra does not show any clinical signs nor disease consequences.

RETROSPECTIVE STUDY OF CASES OF AVIAN BOTULISM IN A FRENCH ZOO (2005 - 2013)

LAMGLAIT B¹, JORIS A¹, BERTHET M², KIMMEL L³, LECLERC A⁴, TRUNET E⁵

¹Réserve Africaine de Sigean, 19 Chemin du hameau du lac, 11130 Sigean, FRANCE;
benjamin.lamglait@hotmail.fr

²Muséum de Besançon – Citadelle de Besançon, 99 Rue des fusillés de la Résistance, 25000 Besançon, FRANCE

³Alliance Pastorale, 48 Avenue de l'Europe, BP 80095, 86502 Montmorillon, FRANCE

⁴ZooParc de Beauval, Route du Blanc, 41110 Saint-Aignan, FRANCE

⁵Parc zoologique de Lunaret, 50 Avenue Agropolis, 34090 Montpellier, FRANCE

A total of 196 cases of avian botulism were diagnosed from 2005 to 2013 at the Réserve Africaine de Sigean, in the southern France. The disease was suspected based on clinical signs, necropsy and histopathology results, and confirmed in 92 individuals by demonstration of botulinum toxin. The cases appeared from May to October with 2 to 60 cases per year, but epizootic events (> 10 cases in short time) were more frequent after dry and warm weather (August and September, $P < 0.05$). All cases appeared in the same area of the zoo, around a brackish water area with swampy zones. Avian botulism was diagnosed in 25 species of birds, mainly from the Anatidae family. The more affected species were ruddy shelduck (*Tadorna ferruginea*), Egyptian goose (*Alopochen aegyptiacus*), Northern pintail (*Anas acuta*), white-cheeked pintail (*A. bahamensis*), black-necked swan (*Cygnus melanocoryphus*), African sacred ibis (*Threskiornis aethiopicus*), pink-backed pelican (*Pelecanus rufescens*) ($P < 0.05$), and mallard duck (*Anas platyrhynchos*). On the opposite, no cases were diagnosed in emus (*Dromaius novaehollandiae*), flamingos (*Phoenicopterus* sp.) or greylag geese (*Anser anser*) even though they shared the same environment ($P < 0.05$). This could reveal species predisposition or difference in exposition to the botulinum toxin through different feeding habits (shallow water feeders more affected in the Anatidae family). The more common presentation was death (87 %). When diagnosed early, avian botulism consisted in acute ascending paralysis, respiratory distress and often diarrhoea. Successful treatment consisted in supportive care (rehydration, assisted nutrition) and, in order to suppress secondary infection, antimicrobial treatment (marbofloxacin (Marbocyl[®], Vétoquinol, Lure, France) 10 mg/kg IM SID). Of all 196 cases, 179 were found dead or died after care. Necropsy showed diffuse marked congestion, and histopathology could not reveal more specific lesions. Diagnosis of botulism was based on demonstration of the toxin (toxin neutralisation test in mice) in the serum or digestive contents from sick birds; in some cases, *Clostridium botulinum* was detected by PCR on cloacal swabs or organ biopsies. Type C botulism strains were the most frequent isolates in carcasses, but type D strains and mixes were also isolated in some cases. No botulinum toxin was found in the feed or environment.

FATAL ENCEPHALOMYOCARDITIS VIRUS INFECTION IN AN AFRICAN ELEPHANT (*LOXODONTA AFRICANA*) IN A FRENCH ZOO

LAMGLAIT B¹, ROMEY A³, JORIS A¹, LEMBERGER K², BAKKALI KASSIMI L³

¹Réserve Africaine de Sigean, 19 Chemin du hameau du lac, 11130 Sigean, FRANCE; benjamin.lamglait@hotmail.fr

²Vet Diagnostics, 14 Avenue Rockefeller, 69008 Lyon, FRANCE

³UMR 1161 Virologie (Anses, Inra, Envva), ANSES – Laboratoire de Santé animale, 23 Avenue du Général De Gaulle, 94700 Maisons-Alfort, FRANCE

An 18 year old African elephant (*Loxodonta africana*) was found dead without preliminary symptoms. A full necropsy was performed and the main lesions consisted of petechiae and suffusions on mucosae of numerous internal organs; marked congestion of internal organs was also noticed. Bacteriology performed on lungs, trachea and liver showed only low numbers of unspecific bacterial growth. The most significant lesions revealed by histopathology were large areas of degeneration and necrosis of ventricular cardiomyocytes associated with scarce inflammation by lymphocytes, macrophages, rare eosinophils and segmented neutrophils, surrounded by large acute haemorrhages extending into the epicardial adipose tissue; marked diffuse congestion was noticed for other organs. RT-PCR for encephalomyocarditis virus (EMCV) was positive on myocardium, liver and kidney. Viral titres were 10^5 TCID₅₀ per ml of whole blood and 10^8 , 10^5 and 10^4 TCID₅₀ per gram of myocardium, liver, and kidney respectively. Serology (VNT) was negative. Sequencing was performed (still pending).

No clinical signs were noted on the other two African elephants held in the same institution. As rodents are supposed to be the reservoir for EMCV, pest control was intensified. Analyses (VNT for antibodies, RT-PCR on tissues from dead rodents) are undergoing to investigate potential animal reservoirs on the premises.

To the authors' knowledge, this is the first EMCV case in a captive African elephant in Europe, and emphasises the necessity to consider EMCV infection in sudden death in captive elephants.

CASE REPORT: INTRAVASCULAR LYMPHOMA IN A PATAS MONKEY (*ERYTHROCEBUS PATAS*)

LAMPE K¹, RUDNICK J-C², BLEYER M¹, KAUP FJ¹, MÄTZ-RENSING K¹

¹German Primate Center, Pathology Unit, Kellnerweg 4, 37077 Göttingen, GERMANY;
klampe@dpz.eu

²Tierklinik-Tierheim GmbH Rostock, Thierfelderstraße 19, 18059 Rostock, GERMANY

Intravascular lymphoma (IVL) is a rare large cell lymphoma characterised by proliferating lymphocytes confined to blood vessels in the absence of a primary extravascular mass and has been reported in humans, dogs, cats, and a horse. In animals, T cell IVL predominate, whereas most human cases are of B cell origin. Clinical manifestation due to occlusion of vessels by neoplastic cells is unspecific and varies depending on organs affected rendering clinical diagnosis difficult.

A 9 year old female patas monkey (*Erythrocebus patas*) presented with poor general condition, inability to stand, petechiae in skin and oral mucosa, anaemia, and thrombocytopenia. PCR on a blood sample targeting *Babesia*, *Ehrlichia*, and *Anaplasma* spp. yielded negative results. Bone marrow cytology suggested lymphatic leukaemia. The animal was euthanised due to poor prognosis.

Necropsy revealed haemorrhages in several organs and bilateral cerebral infarctions. Histologically, cerebral necrosis and haemorrhages were demonstrated with prominent emboli of neoplastic lymphoblasts in cerebral and meningeal blood vessels, chiefly veins and capillaries. Additional organs (e.g. ovary, intestine) also displayed an atypical intravascular lymphoblast population. Immunohistochemically, neoplastic cells were predominantly CD3 positive, whereas only interspersed cells expressed CD20 and CD68, respectively. A strong nuclear Ki-67 signal reflected the high proliferative index of the lymphoblasts.

Clinical signs were rather unspecific while pathological findings prompted the diagnosis of a multi-systemic intravascular T cell lymphoma. To the authors' knowledge, this is the first report of this rare entity in a nonhuman primate. A potential viral oncogenic etiology (e.g. EBV, STLV), as occasionally reported in IVL in humans, is conceivable.

CONSERVATIVE MANAGEMENT OF A METACARPAL FRACTURE IN A REINDEER (*RANGIFER TARANDUS*): UPS AND DOWNS THROUGHOUT THE THERAPY

LANGER S^{*}, WIEGMANN L^{*}

Zoo Duisburg AG, Mülheimer Str. 273, 47058 Duisburg, GERMANY; langers@zoo-duisburg.de,
post@lisa-wiegmann.de

**first authorship shared*

In November 2013, a 1.5 year old castrated male reindeer (*Rangifer tarandus*) living at Zoo Duisburg, Germany, had an accident and was no longer able to bear weight on its left forelimb. Under manual restraint X-rays were performed and revealed a comminuted fracture of the left metacarpus (figure 1). A fracture line in the proximal fragment did not reach the carpal joint. The pastern joint was not involved either. Fortunately, only little displacement of the bone components could be detected and the fracture was closed. Under general anaesthesia an orthopaedic cast consisting of four layers of cellacast xtra[®] casting tape (Lohmann & Rauscher, Neuwied, Germany) was applied for immobilisation (figure 2).

The reindeer was kept in its box for restricted movement and received 0.3 mg/kg meloxicam (Metacam[®], Boehringer Ingelheim, Ingelheim am Rhein, Germany) intramuscularly per day for two weeks. Because of its calm temper it was possible to take X-rays without any restraint or sedation every two weeks and thus to monitor the healing process. The first renewal of the cast was done after six weeks. This second cast failed after two weeks – it got a kink in the front, probably due to too much padding and movement. The reindeer had to be anaesthetised again and a third cast was applied. After ten weeks and two days X-rays showed a solid callus, so we took off the cast and applied a thick suspensory dressing. A few hours after reversal of anaesthesia the reindeer was lame on its left hind leg, too. The joint was hot and swollen. Thus, the animal could not properly stand on its left front leg nor on its hind leg.

The reindeer had to rest in its stable for another two weeks and was treated with a cooling gel on the swollen joint twice a day. Finally, the hind leg was back to normal and we took off the dressing. Afterwards we gradually increased the exercise and the animal recovered well.

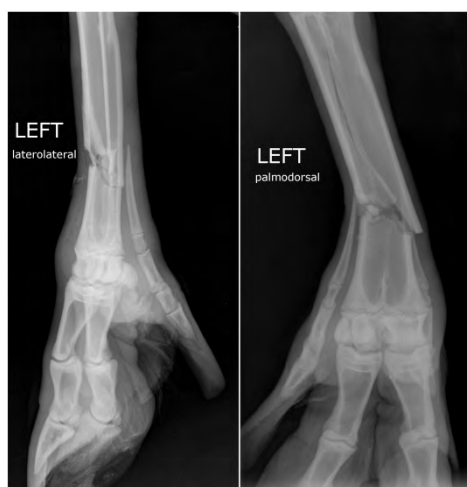

Fig. 1: X-ray photograph showing a metacarpal fracture in reindeer. (Photo: Zoo Duisburg AG)

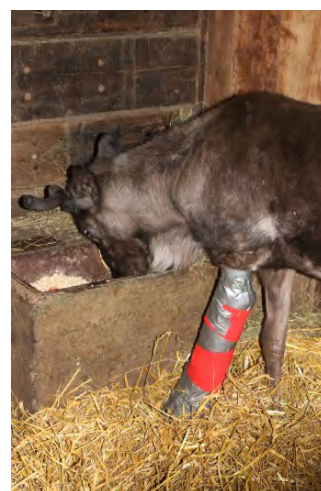

Fig. 2: Reindeer with orthopaedic cast. (Photo: Zoo Duisburg AG)

EMERGING INFECTIOUS DISEASE THREATS TO EUROPEAN BISON (*BISON BONASUS*) IN POLAND

LARSKA M¹, KRZYSIAK MK², KOKOŃ J¹, SMRECZAK M¹, DACKIEWICZ J², ŻMUDZIŃSKI JF¹

¹National Veterinary Research Institute, Dept. of Virology, al. Partyzantów 57, 24-100 Puławy, POLAND; m.larska@piwet.pulawy.pl

²European Breeding Center, Żywiec National Park, Park Prężyna 11, 17-230 Żywiec, POLAND

Until recently, tuberculosis, foot-and-mouth disease and Q fever have been considered as the most significant infections threatening European bison (*Bison bonasus*) health in Poland. Present veterinary epidemiologists face problems of the emergence of novel pathogens such as zoonotic Hepatitis E virus (HEV) and Schmallenberg virus (SBV); or re-emergence of Bluetongue virus (BTV) and Epizootic haemorrhagic disease virus (EHDV) which spread to new geographic locations. Active monitoring of European bison carried over between 2011 and 2014 allowed the determination of the dynamics of the emerging pathogen epidemics in seven free-ranging and captive bison populations including HEV, SBV, BTV and EHDV infections in over 130 selectively culled, found dead or chemically immobilised bison was performed. The distribution of the infections was estimated by serological evidence, using commercial ruminant ELISA for the detection of virus specific IgG and/or IgM antibodies.

No antibodies to HEV and EHDV were found in any of the animals. The coinciding transmission of insect-borne BTV into the bison in the European Fore tober 2012 was confirmed. Between October 2012 and February 2014, SBV antibodies were found in 89.7 % of bison in all populations, while BTV antibodies were present in 60 % of all bison tested, however only in four out of seven locations. The BTV RNA was detected in the blood samples of few animals using real-time RT-PCR, subsequently the virus was genotyped and identified as BTV-14 strain. In contrast to BTV-8 which caused the European epidemic in 2006, BTV-14 spreading in Eastern Europe is thought to be attenuated virus probably from illegally used BTV-14 live vaccine originating from unknown source. No SBV RNA was detected in any of the samples tested by real-time RT-PCR including some blood samples and medulla oblongata (obex) samples collected from suspected of SBV infection European bison.

No clinical signs of SBV and BTV infections were observed, possibly to the low pathogenicity of the circulating viruses. However the SBV acute infection has been previously diagnosed in a fallen elk in Poland (LARSKA et al., 2013), therefore the epidemics should be monitored.

References

LARSKA M, KRZYSIAK MK, SMRECZAK M, POLAK MP, ŻMUDZIŃSKI JF (2013): First detection of Schmallenberg virus in elk (*Alces alces*) indicating infection of wildlife in Białowieża National Park in Poland. *Vet. Microbiol.* **198**, 279 - 281.

MULTIDRUG THERAPY OF *MYCOBACTERIUM AVIUM* SUBSP. *AVIUM* INFECTION IN EXPERIMENTALLY INOCULATED BUDGERIGARS (*MELOPSITTACUS UNDULATUS*)

LEDWONN A¹, DOLKA I¹, DOLKA B¹, CIEŁKO KKA M¹, SZELESZCZUK P¹, CZOPOWICZ M²

¹Warsaw University of Life Sciences, Faculty of Veterinary Medicine, Dept. of Pathology and Veterinary Diagnostics, Ciszewskiego-Str. 8, 02-787 Warsaw, POLAND; aledwonn@yahoo.pl

²Warsaw University of Life Sciences, Faculty of Veterinary Medicine, Laboratory of Veterinary Epidemiology and Economics, Nowoursynowska-Str., 159, 02-776 Warsaw, POLAND

Introduction

Mycobacterium avium subsp. *avium* infection is probably most commonly diagnosed mycobacterial pathogen in various avian species (MANAROLLA et al., 2009; LENNOX, 2007). By dint of potential zoonotic risk and the need of long multidrug treatment of mycobacteriosis, euthanasia is rather recommended in animals than antibiotic therapy. Still, considering economic and/or conservation value of individual birds can be rational approach to treatment (BUUR and SAGGESE, 2012). No set of guidelines has been developed for mycobacterial diseases in companion and wildlife avian species and pharmacokinetic studies of antimycobacterial drugs are lacking. But antimycobacterial regimens suggested for birds are proposed in the bibliographical data (POLLOCK, 2006).

Materials and methods

The authors obtained a positive opinion from the Local Ethics Commission (nr 39/2008), prior to using budgerigars in the experiment. Nine budgerigars were infected with *Mycobacterium avium* subsp. *avium* strain, isolated from pheasant and with experimentally proven pathogenicity for budgerigars at a dose of 5×10^5 colony-forming units/kg body weight (LEDWONN et al., 2013). Five weeks after inoculation multidrug therapy was started. Another six birds were treated the same way without inoculation, and six additional budgerigars were kept as a control without treatment. Antibiotic regimen containing: clarithromycin (Klacid[®], Abbot Laboratories, Warsaw, Poland) 61 mg/kg b.w., moxifloxacin (Avelox[®], Bayer Schering Pharma, Berlin, Germany) 25 mg/kg b.w. and ethambutol (Ethambutol Teva, Teva Pharmaceuticals, Warsaw, Poland) 60 mg/kg b.w. in water suspension from pulverised tablets were administered orally in a volume of 0.4 - 0.5 ml every 12 h for 18 weeks. During therapy blood samples were obtained for haematology and blood chemistry. In the end of the therapy budgerigars from all three groups were euthanised and necropsied. Obtained organs were submitted for histopathology and cultured on Löwenstein-Jensen medium.

Results and conclusions

As the first clinical sign of disease green coloured ureates were noted four weeks after inoculation. Two days before the onset of the treatment one budgerigar died and necropsy revealed changes typical for advanced mycobacteriosis. A second budgerigar died in the 8th week of treatment because of a pituitary gland tumour. During therapy regurgitation was intermittently registered as a side effect in about 50 % individuals of both groups with antimicrobial treatment. Marked aspartate aminotransferase (ASPAT) elevation was detected in inoculated birds at the time of the treatment initiation,

than declined. At day 54 after onset of the treatment leukocytosis ($25.3 \times 10^3/\mu\text{l}$ and $16.9 \times 10^3/\mu\text{l}$) was noted in two budgerigars, but in the last day of treatment the values were back to $6.3 \times 10^3/\mu\text{l}$ and $9.9 \times 10^3/\mu\text{l}$ respectively. Necropsy revealed pathological changes in only two of the infected budgerigars after 18 weeks of treatment. Despite these two cases there was no mycobacterial growth on Löwenstein-Jensen medium from internal organs of the treated birds. The pectoral muscle sample (inoculation site) was positive for mycobacterial growth in the bird which died in 8th week of therapy. Acid fast bacilli were visible microscopically in only one of the budgerigar after completed therapy and in the organs of the birds which died earlier. Side effects of therapy except the regurgitations in some inoculated and non-inoculated individuals were not detected. In conclusion even an 18 week antimicrobial treatment of advanced mycobacteriosis caused by *M. avium* subsp. *avium* is not sufficient for complete therapy of the disease. Clinically the treated birds improved, but despite this in 2/7 animals we found gross pathological lesions typical for mycobacterial infection. Both were positive in histopathology while from only one of the animals acid fast bacilli were cultured from the obtained organs.

References

- BUUR J, SAGGESE MD (2012): *Taking a rational approach in the treatment of avian mycobacteriosis*. *Vet. Clin. North. Am. Exot. Anim. Pract.* **15**, 57 - 70.
- LEDWOŃ A, SAPIERZYŃSKI R, AUGUSTYNOWICZ-KOPEĆ E, KOZAK M, SZELESZCZUK P (2013): *Experimental inoculation of BFDV positive budgerigars with Mycobacterium avium subsp. avium strains*. *Proceedings of 1. Int. Conf. on Avian, Herpetological & Exotic Mammal Medicine, Germany, 20 - 26 April 2013*, 485 - 488.
- LENNOX AM (2007): *Mycobacteriosis in companion psittacine birds: a review*. *J. Avian Med. Surg.* **21**, 81 - 87.
- MANAROLLA G, LIANDRIS E, PISONI G, SASSERA D, GRILLI G, GALLAZZI D, SIRONI G, MORONI P, PICCININI R, RAMPIN T (2009): *Avian mycobacteriosis in companion birds: 20-year survey*. *Vet. Microbiol.* **133**, 323 - 327.
- POLLOCK CG (2006): *Implications of Mycobacteria in Clinical disorders*. In: Harrison G, Lightfoot L (Eds.): *Clinical Avian Medicine*, Spix publishing, 681 - 690.

A FULLY REVERSIBLE DRUG COMBINATION FOR THE DEEP SEDATION OF RED FOXES (*VULPES VULPES*)

LIPTOVSKY M¹, SZILASI A², PAPP GV¹

¹Magyar Állatorvosi Egyetem, Városliget u. 11, H2100 Újpest, HUNGARY; liptovszky@gmail.com

²Szent István University, Faculty of Veterinary Science, István u. 2., H1078 Budapest, HUNGARY

There are several different approaches to the sedation or anaesthesia of the red fox (*Vulpes vulpes*). Published drug combinations include ketamine plus different alpha2-agonists, tiletamine-zolazepam, and medetomidine-butorphanol-midazolam. We studied a modified combination of the later, using dexmedetomidine, butorphanol and midazolam for the reversible deep sedation of red foxes. Twelve healthy, young adult red foxes were treated with 0.01 mg/kg dexmedetomidine (Dexdomitor, Orion Pharma, Espoo, Finland), 0.57 mg/kg butorphanol (Alvegesic, Alwetra-Werfft, Vienna, Austria) and 0.45 mg/kg midazolam (Dormicum, Egis, Budapest, Hungary) by intramuscular injection. Average weight of the animals was 5 kg. In ten cases we castrated the animals using a prescrotal approach, in these cases 2 mg/kg lidocaine (Lidocain-Egis, Egis, Budapest, Hungary) was applied intratesticularly immediately after lateral recumbency was achieved. No oxygen supplementation was available in these cases. In two cases time consuming dental procedures were carried out, in which cases anaesthesia was maintained using isoflurane and 100 % oxygen. Time to lateral recumbency, heart rate, respiratory rate and blood oxygen saturation were measured, and ECG monitoring was also used. Animals were given 0.1 mg/kg atipamezole intramuscularly (Antisedan, Orion Pharma, Espoo, Finland) at the end of procedure.

All of the animals were deeply sedated, and intubation was possible. Average time to lateral recumbency was 12 minutes. Average heart rate was 88 beats/min, respiratory rate 24 breaths/min, while blood oxygen saturation was 90 %. No major changes of these parameters were revealed with time. No ECG abnormalities were revealed. Animals were able to stand within five minutes from the application of atipamezole.

Safe and practical sedation or anaesthesia of different wild animal species is a challenge in zoological medicine. Depending on the situation, different approaches are needed. We studied a fully reversible deep sedation protocol in red foxes using dexmedetomidine, butorphanol and midazolam. This combination has some distinct advantages compared to other drug combinations. It does not contain any controlled drug, which can be useful under field conditions. It is also fully reversible using atipamezole for the dexmedetomidine, naloxone (or other opiate antagonist) for the butorphanol, and flumazenil or sarmazenil for the midazolam. However we found, that using only atipamezole as an antagonist, animals were able to stand within five minutes, while some of the analgesic effect was still reserved. It is important to note, that this protocol was not intended for major or painful procedures. In these cases maintenance using isoflurane or sevoflurane supplemented with adequate analgesics should be used, while this drug combination can serve as induction. Intubation is possible using this protocol. Alpha2-agonists are not safe in severely ill, very young or old, debilitated animals. Side effects of dexmedetomidine include bradycardia, hypotension and hypothermia, all of which can be difficult to treat under field conditions. We did not observe bradycardia in our study, but in other species this seems to be time-related. Our procedures might be too short for inducing bradycardia. Mild hypoxia was revealed in some of those cases where oxygen supplementation was not available. Further studies are warranted to study any side effects in longer procedures. Also studies of blood pressure and ventilation changes are needed to rule out any major difficulties regarding them.

ASSISTED REPRODUCTION IN GIRAFFES

LUEDERS I¹, POOTOOLAL J², TAYA K³, WATANABE G³, YAMAMOTO Y³, NIEMULLER C⁴,
CHENIER T⁵, SCHOLTZ E⁵

¹GEOLifes- Animal Fertility and Reproductive Research, 22457 Hamburg, GERMANY;
imke.lueders@geolifes.com

²African Lion Safari, RR#1 Cambridge, ON, N1R 5S2, CANADA

³Tokyo University of Agriculture and Technology, Laboratory of Veterinary Physiology, Fuchu, Tokyo
183-8509, JAPAN

⁴Kingfisher International Inc., Conservation Biology Laboratory, Stouffville, ON, L4A 0Y2, CANADA

⁵Ontario Veterinary College, Dept. of Population Medicine, University of Guelph, Guelph, ON,
N1G 2W1, CANADA

Reproduction physiology studies were carried out on 1.8 tamer (Fauna Research Inc., Red Hook NY, USA) trained Rothschild's giraffes (*Giraffa camelopardalis rothschildii*). Regular ultrasonography was used to visualise the ovaries and uterus in both cycling and pregnant females. Blood was collected from the jugular vein every day or once a week from pregnant ones. Faecal samples were taken on alternate days directly from the rectum. In the cycling giraffe, serum samples were analysed for LH via ELISA and for inhibin and FSH via RIA. Progesterone and estrogen were measured from faecal extracts via ELISA. The combined ultrasound and hormone provided a precise picture of the estrus cycle. The average cycle length was 14.5 days, with the LH peak occurring either on the day or one day after the drop in progesterone. Ovulation followed 12 to 24 hours later. FSH and inhibin were inversely related as described in other species such as cattle and horses.

The mean gestation length was (mean \pm SD) 457 \pm 10 days (n = 13 pregnancies). In five pregnant giraffes, the proper embryo was first depicted between day 33 - 41 (mean day 38). Sexing of the fetus by ultrasound was possible in eight pregnancies between day 90 to 193 post insemination.

In the male giraffe, semen was collected by transrectal massage of the colliculus seminalis region. When the urethra was stimulated, contractions were allowed to happen before starting massages again. This was repeated until after 40 - 60 min, semen samples of 0.5 - 7.0 ml were collected as it dripped from the prepuce. The total motility ranged from 50 - 90 % (n = 5).

Fresh semen was used for artificial insemination (AI) in a four year old female. When the pre-ovulatory follicle reached a size of 1.8 cm, the fresh semen was deposited into the cervix. Pregnancy was confirmed by faecal progesterone (elevated level for more than 14 days) and the visibility of the embryo within the uterus (day 41 post insemination). The pregnancy was uneventful and followed by the birth of a healthy female calf on day 445.

Parts of the semen collected from the bull were frozen using two different bovine extenders (BIOXcell[®], IMV Technology, l'Aigles, France / Trilady[®], Minitüb, Tiefenbach, Germany). From a sample with 90 % initial total motility, 7.0 ml were frozen in 0.25 ml straws. First, the straws were slowly cooled down in the liquid nitrogen vapor for 10 mins, afterwards they were completely plunged. Post thaw motility was between 60 and 70 % for both extenders. Frozen-thawed semen was used in three AI attempts in three different females. In one attempt, the cervix was passed and semen was placed intrauterine 24 and 12 hours prior to ovulation based on ultrasound. Progesterone levels indicated that the female conceived and remained elevated for two months. However, no clear embryonic structure developed. Thus, the corpus luteum was lysed with 25 mg of dinoprostone (5 ml Lutalyse[®], Zoetis, Kirkland, Canada). Two other frozen semen AI attempts did not result in conception.

These preliminary results are helpful information to understand giraffe reproduction and for the further development of assisted reproduction techniques in giraffes.

PROTEUS ANGUINUS PROJECT – FIRST YEAR BACTERIOLOGICAL FINDINGSLUKAC M¹, HORVATEK TOMIC D¹, CIZELJ I², PRUKNER-RADOVCIC E¹

¹University of Zagreb, Faculty of Veterinary Medicine, Dept. of Avian Diseases with Clinic, Heinzelova 55, Zagreb 10000, CROATIA; maja.lukac@vef.hr

²Zagreb Zoo, Maksimirski perivoj bb, 10000 Zagreb, CROATIA

„The olm (*Proteus anguinus*) in Croatia – conservation research project“ is composed of *ex situ* and *in situ* parts. The aim of the *in situ* part is biological and veterinary research on flushed animals kept in a specially designed „cold“ room situated at the Zagreb Zoo. The aim of this study is to learn about the normal, opportunistic and pathogenic microflora in these animals, since this information is not yet known. In the period between November 2012 and June 2013, a total of 20 animals were tested, among them 14 flushed out at two localities and sampled immediately upon arrival at the rescue centre, and 6 animals sampled at their original habitat at three localities. Oral cavity, cloacal, and skin swabs, together with the water from original localities were taken and analysed by standard microbiological procedures. Samples were plated on non-selective nutrient agar and selective brilliant green agar and incubated under aerobic conditions at two different temperatures: 22° and 8°C. These temperatures were chosen to distinguish between normal microbiota, growing at 8°C, and the opportunistic microorganisms, growing at suboptimal temperature of 22°C, at which they could be found in the field. The plates were checked for five days to determine the time when the opportunistic bacteria develop. Further identification of suspected colonies were carried out using Gram staining, oxidase and catalase tests and API biochemical commercial tests. From all samples used for standard bacteriology, DNA was isolated and stored for next-generation sequencing. In total, representatives of 11 bacterial genera, i.e. *Acinetobacter*, *Aeromonas*, *Bacillus*, *Butiauxiella*, *Enterobacter*, *Escherichia*, *Janchtinobacterium*, *Micrococcus*, *Pseudomonas*, *Staphylococcus* and *Streptococcus* were identified. Significantly more bacteria were isolated from olms flushed out than in those from their original localities. Most of these bacteria are opportunistic and grow only, or grow much faster, at higher temperatures so that they probably could not compromise the olm, unless it is flushed out. Also, most are soil bacteria which take part in the natural elimination of organic pollution. However, some of them could also compromise the health of the olms under suboptimal conditions. Of particular interest could be the finding of *Janchtinobacterium lividum*, with known anti-fungal properties, which may help protect the olm against infection by the devastating chytrid fungus *Batrachochytrium dendrobatidis*.

THE ROLE OF ZOO IN COMBATING ILLEGAL WILDLIFE TRADE: THE LAST 10 YEARS AT WILDLIFE RESERVES SINGAPORE

LUZ S, LEE P, RAGHAVAN R

Wildlife Reserves Singapore, 80 Mandai Lake Road, 729826 Singapore, REPUBLIC OF SINGAPORE; sonja.luz@wrs.com.sg

Illegal trade and possession of live animals is an ongoing and serious problem throughout Asia. As enforcement agencies step up in their efforts to combat illegal wildlife trade in the region, increasing numbers of live animals are being confiscated, which leads to a whole new issue: How to appropriately manage these animals post-confiscation?

Wildlife NGOs and zoos commonly take over such confiscated wildlife, but providing adequate care for these animals can become an overwhelming task where resources are lacking.

As a modern zoo and the only fully authorised wildlife rescue centre in Singapore, Wildlife Reserves Singapore (WRS) is privileged to have adequate facilities and expertise readily on hand to address the problem. In 2013 alone, WRS received a total of 66 exotic animal confiscations through the Agri-food & Veterinary Authority (AVA) in Singapore. Of the 66 confiscations, 92 % could be absorbed into our animal collection and 8 % had to be euthanised. In some cases, especially where large numbers are confiscated, WRS works closely with the AVA to repatriate the animals to their country of origin. Aside from confiscated wildlife WRS also attends to about 400 local wildlife rescue cases yearly.

Wildlife Reserves Singapore also supports and works closely with TRAFFIC, the regional wildlife trade monitoring network. At many occasions WRS and TRAFFIC linked hands to organise conferences and public education events to highlight the issues around illegal wildlife trade.

This poster presentation will give an overview on the last 10 years of WRS supporting the fight against illegal wildlife trade through post-confiscation management of threatened species as well as education and out-reach activities targeted at creating awareness and thus the reduction of demand.

A FATAL CASE OF INTESTINAL INTUSSUSCEPTION IN A MANED WOLF (*CHRYSOCYON BRACHYURUS*)

MAGNONE W¹, SANDRI C¹, SALVELLIA A², AVESANI C¹, PASCOTTO E³

¹Parco Natura Viva – Garda Zoological Park, Veterinary Dept. Loc. Figara 40 Bussolengo (VR), ITALY; william.magnone@parconaturaviva.it

²Azienda Sanitaria Locale 22, Bussolengo (VR), ITALY

³University of Udine, DIAL-Division of Veterinary Pathology, via Sondrio 2, 33100 Udine, ITALY

Intussusception is a condition which causes a portion of the intestine to slide inside of itself, leading to severe pain, a decrease in blood supply to the area and damage to the surrounding tissues. This condition is uncommon, but can happen in dogs and other carnivores of any age even if it is more common in young animals. Intussusception may happen quickly and can become fatal if not treated immediately and correct.

Many causes of intussusception are unknown, but an infection or inflammation of the intestinal tract may be a promotor. Additionally, intestinal parasites or another indigestible mass that has formed in the area can cause the intestines to invaginate with themselves and thereby narrow the pathway considerably, leading to intussusception.

It may be difficult to differentiate the clinical signs of intussusception from other abdominal and intestinal problems, especially in wild animals, where some of the clinical signs can be hidden.

In 2010, a 6 year old breeding female maned wolf (*Chrysocyon brachyurus*), hosted at Parco Natura Viva – Garda Zoological Park in Bussolengo, Italy, was found lethargic in its outside enclosure.

The animal was so weak, that a physical examination was possible without sedation. It showed severe weight loss, an increased borborygmus and signs of severe pain during abdominal palpation. Rectal palpation showed the presence of blood. The initial diagnostic plan included a complete blood count, a biochemical profile and faecal analysis. Laboratory findings showed anaemia.

X-rays, abdominal ultrasound and endoscopy was planned for the following hours and possibilities and potential for recovery were discussed when deciding options for surgical treatment. Every effort to stabilise the animal by adding intravenous fluids, restoring electrolyte levels, antibiotics (metronidazole 25 mg/kg IV Metronidazolo Kabi, Kabi, Italy) and pain killers (meloxicam 0.3 mg/kg SC Meloxidyl Ceva Vetem, Libourne, France and tramadol 2 mg/kg IM Formevet, Milano, Italy) were used, but the animal showed signs of endotoxic shock and died within few hours.

On gross pathology a long (50 cm) tract of the ileal portion was found invaginated within itself with a fair amount of food inside the lumen (fragments of feathers, strands of grass, mucus and other components).

This case reports a fatal case of intussusception without an established cause. As reported in literature, intussusception has to be considered as severe disease in maned wolves.

POST AND CORE DENTAL RESTORATION OF PERSIAN LEOPARD'S (*PANTHERA PARDUS CISCAUCASICA*) MANDIBULAR CANINE TEETH

MEMARIAN I¹, ABARGHOUEI MJO², MOLAZEM M³, PEDRAM MS³, VALI Y³, MOHAJERI SF³,
GHAZALEH N⁴, SHAHRDARI AR⁵

¹Tehran Zoo and Pardisan Rehabilitation Centre, 1484613111 Tehran, IRAN;
zoo.vet@tehraneramzoo.ir

²Islamic Azad University, Khorasgan Branch, Esfahan, IRAN

³University of Tehran, Faculty of Veterinary Medicine, Dept. of Radiology and Surgery, 141556453 Tehran, IRAN

⁴Pardisan Rehabilitation Centre, 1484613111 Tehran, IRAN

⁵Tehran Zoo, 4th kilometer of Tehran-Karaj freeway, 1484613111 Tehran, IRAN

Introduction

The Persian leopard (*Panthera pardus ciscaucasica* syn. *Panthera pardus saxicolor*), is the largest leopard subspecies, and is native to Iran, eastern Turkey, the Caucasus Mountains, southern Turkmenistan, and parts of western Afghanistan. It is endangered throughout its range with fewer than 500 mature individuals and a declining population trend (ZIAIE, 2008). Endodontic disease refers to damage to the dental pulp. A fractured tooth with exposure of the pulp chamber, a discoloured tooth, or an intraoral or extra oral draining fistula is common clinical findings that may indicate the presence of endodontic disease. Except in the obvious case of a direct pulp exposure, a definitive diagnosis of endodontic pathology is difficult to make based only on clinical examination. Radiography is necessary for diagnosis and treatment planning (DUPONT and DEBOWES, 2009). A post and core is a type of dental restoration that is utilised when there is inadequate tooth structure remaining to support a traditional restoration (CHEUNG, 2005).

Diagnosis and treatment

Rica, a 14 year old male Persian leopard who is the only male leopard living in captivity –Tehran Zoo- in Iran, developed a fractured mandibular canine teeth with exposure of the pulp chamber. A discoloured tooth and an extra-oral draining fistula were also found, which could indicate the presence of endodontic disease (figures 1 & 2). In order to do further examinations and take radiographs to determine the severity of the lesion, the vet team decided to anaesthetise the animal. Anaesthesia was safely achieved using the combination of tiletamine, zolazepam (Zoletil 100, Virbac S.A) 1.5 mg/kg and medetomidine HCL 20 mg/ml (Kyron Laboratories (Pety) Ltd) 15 µg/kg, that administered in same 1.5 ml dart by intramuscular injection. This protocol provides effective anaesthesia and sedation which wanes in approximately one hour. In order to maintain the anaesthesia for further 45 minutes supplementary Isoflorane 1 Vol% (Forene Abbot AG, Switzerland) in O₂ and an infusion of ringer's solutions were used.

Several radiographs was taken, including open mouth left / right 20- degree, ventral right / left dorsal oblique, open mouth left/right 20 degree, dorsal right / left ventral oblique and intra oral ventrodorsal projection had been performed (THRALL, 2012) The radiographs revealed endodontic lesions in both mandibular canines and secondary periapical infection at left mandibular canine tooth that seemed to occur secondary to the fracture (figure 3), it also showed periodontitis and root retention of lower left PM3.

Feline Odontoclastic Resorption Lesion (FORL) of upper PM3 and M1, lower PM3 and M1 and/ or trauma and consequence external resorption at upper M1 and lower PM3 were suggested as differential diagnosis (figure 4).



Fig. 1: Fractured mandibular canine teeth with exposure of the pulp chamber and discoloured teeth. Photo: Alireza Shahrhiri

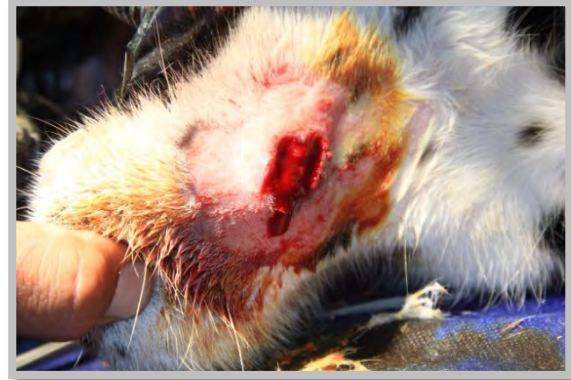

Fig. 2: Extra oral draining fistula that indicate the presence of endodontic disease. Photo: Alireza Shahrhiri

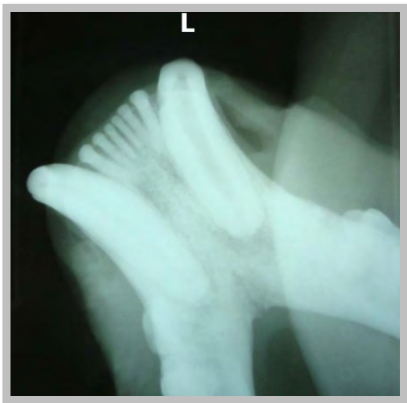

Fig. 3: Intraoral ventrodorsal projection. Widening of the pulp, asymmetric length of canine teeth and preapical abscess are detectable.

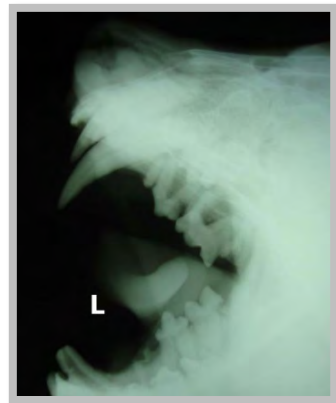
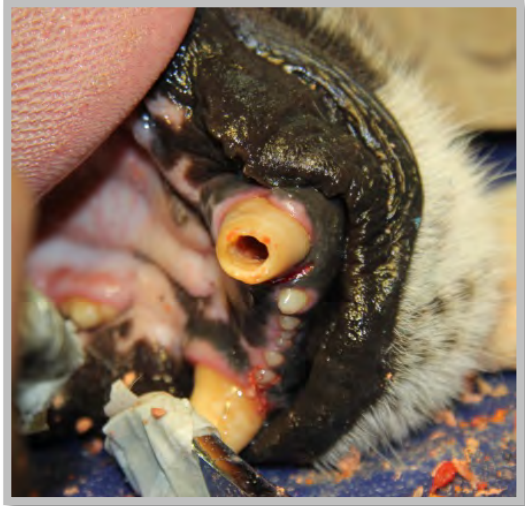
Fig. 4: Open mouth oblique projection to determine mandibular and maxillary teeth.

Based on clinical and radiographic findings, root canal therapy as a treatment of choice for management of canine teeth in addition to extraction of retained PM3 root over the course of two surgeries was suggested. During the course of root canal therapy diseased pulpal tissue was removed and the root canal was cleaned and disinfected (figure 5), then the pulp filled with an inert material to protect the tooth from any external or bacterial contamination.

During the course of endodontic procedure, further radiographs were taken to determine the working length of the root canal and also to identify any possible problems such as extension of obturating materials beyond the root apex, filling short of the root canal terminus, poor adaptation of the fill to the root canal walls, and voids in the fill or poor fill density (figure 6).



*Fig. 5: Removal of diseased pulpal tissue, cleaning and disinfecting root canal.
Photo: Alireza Shahrdari*

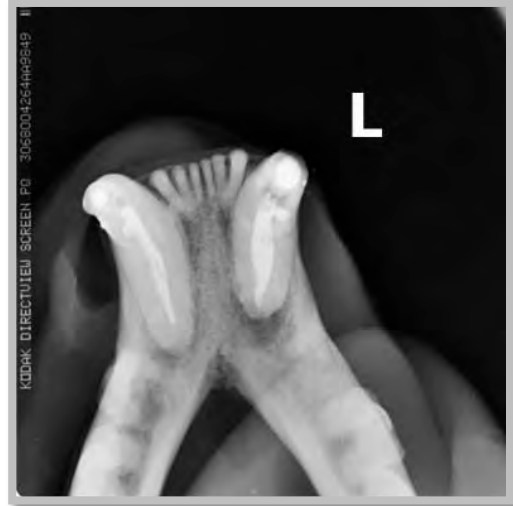

Fig. 6: Intra oral ventrodorsal projection. Radiodense obturating material enhances visualisation of the canal widths.

Following root canal therapy, both canines were repaired with cast post and core and crown. A small rod, gold, was inserted into the root space of the tooth and protruded 19 cm from the root. This rod will refer here as post. The post was used to hold the core –which also was made mainly from gold– in place (figure 7). Without this post, the remaining tooth structure would not be enough to hold the required core. And then, the post and core were covered with the crown, which was made meticulously from really strong and durable materials in order to meet the needs of this Persian leopard to have a natural mastication and prehension behaviour (figure 8).

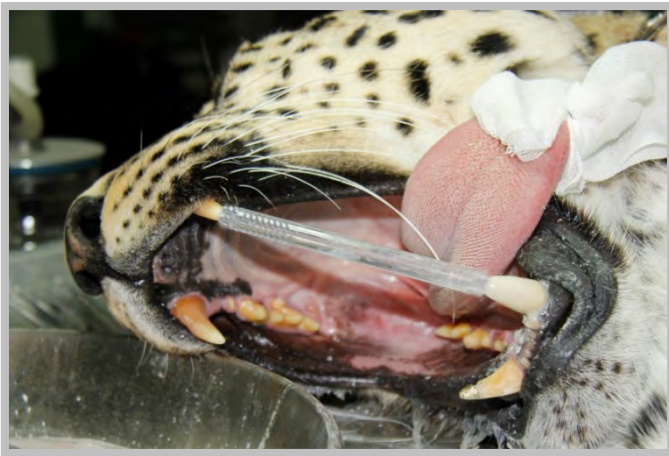

Fig. 7: A small rod, gold, was inserted into the root space of the tooth and protrudes from the root 19 cm, and the post was then used to hold a core, in place that is also made by gold and some of the other material.



*Fig. 8: The post and core is covered with a crown and five months after dental restoration the animal showed no pain and also gained weight.
Photo: Alireza Shahrdari*

Results and discussion

To the best of our knowledge it has been the first time that such a procedure has been done for a Persian leopard in the world. Five months after post and core dental restoration the animal showing no signs of pain and also it has gained weight and the crown is working really well. Rica was not only said to be recovering well after the whole procedure, but also representatives from the zoo have already found him a potential female Persian leopard. However they both have been found in their natural habitat, but they are unable to live in the nature any more (the female had right forelimb amputated due to grabbing in gin trap). In this situation, they could be considered as a truly potent gene pool for the continuation of the generation of this endangered species.

Acknowledgements

We would like to thank the Tehran University small animal hospital and all the staff how helps us in this procedure. Furthermore we thank the Eram Park and Tehran Zoo DOE for the possibility of working on this Persian leopard and using the entire instruments there. Also we thank Nasim Abdolmalekiyan for edit.

References

- CHEUNG W (2005): *A review of the management of endodontically treated teeth: Post, core and the final restoration*, *J. Am. Den. Assoc.* **136**, 611 - 619.
- DUPONT GA, DEBOWES LJ (2009): *Atlas of Dental Radiography in Dogs and Cats: A Practical Guide to Techniques and Interpretation*, Saunders, Elsevier, Missouri, 140.
- THRALL D (2012): *Textbook of Veterinary Diagnostic Radiology*, Saunders, 6th Ed. Saunders, Elsevier, 103.
- ZIAIE H (2012): *A Field Guide to the Mammals of Iran, Fourth edition*. Department of the Environment, Tehran, 312 - 316.

FIRST REPORT OF MALIGNANT CATARRHAL FEVER IN A CAPTIVE PUDU (*PUDU PUDA*)

MODESTO P¹, BIOLATTI C¹, GRATTAROLA C¹, VARELLO K¹, IULINI B¹, MANDOLA ML¹,
DONDO A¹, GORIA M¹, ROCCA F², ACUTIS P¹

¹Istituto Zooprofilattico Sperimentale del Piemonte, Liguria e Valle d'Aosta Institute, Via Bologna 148, 10154 Turin, ITALY; paola.modesto@izsto.it

²Parco Faunistico "La Torbiera", Via Borgoticino 19, 28010 Agrate Conturbia (NO), ITALY

Summary

A male, six year old, pudu (*Pudu puda*) from an Italian zoo was submitted for *post mortem* examination after sudden death. At necroscopy, non-suppurative bronchopneumonia and degeneration of the liver were observed. Haemorrhagic lesions of the thymus, pericardium and spleen were found. Microscopically, multifocal perivascular and periglomerular mononuclear cell infiltrates were observed in kidneys, lungs, spleen and in the portal triads of the liver. Histological examination of the brain revealed meningitis, vasculitis and perivascular cuffs of mononuclear inflammatory cells. A real-time PCR was run in order to amplify a region of DNA polymerase gene of malignant catarrhal fever (MCF) viruses. Tissue samples showed PCR products that were sequenced and analysed. The sequences showed a 99 % homology with a portion of Caprine herpesvirus 2 DNA polymerase gene. This is the first report of MCF in a captive pudu.

Introduction

The *Pudu puda* belong to the Odocoilinae genus and are considered a vulnerable species by the International Union for Conservation of Nature (IUCN). Only few information about infectious disease of this species are recorded in literature (TWOMEY et al., 2010; PIZARRO-LUCERO et al., 2005).

The malignant catarrhal fever (MCF) is a lymphoproliferative syndrome, an often lethal infection of certain ruminants caused by members of the group MCF virus (MCFV), in the Macavirus genus of Gammaherpesvirinae (DAVISON et al., 2009). In this group six viruses are associated with clinical diseases: ovine herpesvirus-2 (OvHV-2), alcelaphine herpesvirus-1 (AIHV-1), caprine herpesvirus-2 (CpHV-2), ibex malignant catarrhal fever virus (MCFV-ibex), alcelaphine herpes virus-2-like virus and a virus of undetermined origin that cause the same pathology in the white tailed deer (MCFV-WTD) (CUNHA et al., 2009). In 2001, the CpHV-2 was isolated from asymptomatic goats (LI et al., 2001), and in the following years it was recognised to cause disease in wild animals such as white tailed deer, sika deer, cervids and water buffalo (CRAWFORD et al., 2002; DETTWILER et al., 2011; KEEL et al., 2003; LI et al., 2003b; VIKØREN et al., 2006). In the present study we describe for the first time a case of MCF by CpHV-2 in a pudu hosted in an Italian zoological garden.

Materials and methods

A male six year old pudu (*Pudu puda*) from a zoological garden was submitted for *post mortem* examination after sudden death. The animal was examined following a complete necropsy protocol; brain, lungs, heart, spleen, tongue, liver, kidney, small/large intestine and several lymph nodes were

collected, moreover portion of organ showing macroscopic lesions were taken. All tissues were conserved, partly fixed in 10 % formalin and partly frozen at -80°C.

Several organs were tested for *Salmonella* spp., *Listeria* spp., *Clostridium* spp. (culture) and for *Rickettsia* spp., *Coxiella burnetii*, *Borrelia burgdorferi* s.1, *Leptospira* spp., BVDV, BDV, IBR, BTV, PRV, TBEV, EHDV (PCR). A real-time PCR was run to amplify a region of the DNA polymerase gene of the following MCF viruses: OvHV-2, AIHV-1, CpHV-2, MCFV-ibex, and MCFV-WTD (CUNHA et al., 2009). The assay was modified from previously described using Syber green chemistry instead of fluorescent probes to detected the products of amplification. The obtained PCR products were sequenced and analysed on an ABI 3130 Genetic Analyzer (Lifetechnologies). Blood samples, nasal and oral swabs were collected from two goats hosted in the same zoological garden as the pudu, and tested both for MCFV antibody detection by indirect fluorescent antibody test (IFI) as described by DECARO et al. (2003) and for CpHV-2 DNA detection by Real Time PCR.

Results and discussion

The animal was in general good body condition. At necropsy, non-suppurative bronchopneumonia and degeneration of the liver were observed. Haemorrhagic lesions of the thymus were found, moreover petechial to ecchymotic haemorrhages were seen on pericardium and spleen. Microscopically, severe multifocal perivascular and periglomerular mononuclear cell infiltrates were found in the kidneys and in the portal triads of the liver. Lungs and spleen showed mild to moderate perivascular mononuclear cell infiltrates while oedema, marked lymphoblastic proliferation in the parafollicular cortex and medullary sinuses and focal haemorrhages were observed in the lymph nodes. Histologic examination of the brain revealed meningitis, vasculitis and perivascular cuffs of mononuclear inflammatory cells. Moreover, neuronophagia and gliosis with rod cells were present.

The analyses for bacterial and virus pathogens were negative for all tested organs.

The Real Time PCR revealed a positive amplification for lung, kidney, spleen, brain, tongue and small intestine. The sequences obtained from the PCR products were compared with those available on GenBank using BLAST software and they showed a 99 % similarity with a portion of Caprine herpesvirus 2 DNA polymerase gene (AF283477). Samples collected from the goats of the same zoo resulted negative both at IFI and at Real Time analyses.

The CpHV-2 seems to be endemic in goats and was associated with MCF in several species of deer (CRAWFORD et al., 2002; DETTWILER et al., 2011; KEEL et al., 2003; LI et al., 2001; LI et al., 2003b; VIKØREN et al., 2006). In all the cases a clear clinical symptomatology was described, with anorexia, loss of weight, fever, skin lesions, dyspnea, diarrhea, neurologic signs, bleeding from nose, vagina and rectum (CRAWFORD et al., 2002; DETTWILER et al., 2011; KEEL et al., 2003; LI et al., 2003b). In the present report, the animal was in good body condition and showed no clinical signs. The macroscopic and histologic lesions observed in the main internal organs reflected those described in CRAWFORD et al. (2002), DETTWILER et al. (2011), KEEL et al. (2003), LI et al. (2003b), VIKØREN et al. (2006). The high variability of the lesions is a typical feature of the MCF viruses in species different from those they are adapted to and in which they cause disease (CRAWFORD et al., 2002). Nevertheless, it should be mentioned that CpHV-2-like viruses have been found in other Caprinae like ibex without overt symptoms (LI et al., 2003a) The CpHV-2 has been isolated from white-tailed deer (LI et al., 2000), moose and roe deer (VIKØREN et al., 2006), and water buffalo (DETTWILER et al., 2011). The CpHV-2 caused the death of five sika deer (*Cervus nippon*) hosted in two zoos in USA (CRAWFORD et al., 2002; KEEL et al., 2003) and in both cases the coexistence with healthy carrier goats hosted in the neighbouring enclosures was the origin of the infection.

To the authors' knowledge, this is the first report of MCF in a pudu. The pudu was owned by a zoological garden, where a goat herd was also displayed in separated enclosure. Although tested for

antibody and DNA detection, the goats hosted in the same zoo were negative for CpHV-2. We hypothesised that goat herds that sometimes graze in the meadow adjacent to the zoo, during the transhumance period, could be the origin of the infection, although only indirect interactions with the pudu occurred. Indeed the MCF transmission usually occurs by direct contact with carrier animals, some authors consider possible the virus long-distance diffusion, up to five kilometres, by aerosol, wind and mechanical vectors (Li et al., 2008).

In conclusion, in the zoological gardens, it is important to keep clear separation between possible asymptomatic carrier goats and all the MCF susceptible ruminant wild species. Moreover biosafety procedures should be in place to exclude the risk of indirect transmission and to assure the highest achievable isolation of valuable animals.

References

- CRAWFORD TB, LI H, ROSENBERG SR, NORHAUSEN RW, GARNER MM (2002): Mural folliculitis and alopecia caused by infection with goat-associated malignant catarrhal fever virus in two sika deer. *J. Am. Vet. Med. Assoc.* **221**, 843 - 847.
- CUNHA CW, OTTO L, TAUS NS, KNOWLES DP, LI H (2009): Development of a multiplex Real-Time PCR for detection and differentiation of malignant catarrhal fever viruses in clinical samples. *J. Clin. Microbiol.* **47**, 2586 - 2589.
- DAVISON AJ, EBERLE R, EHLERS B, HAYWARD GS, MCGEOCH DJ, MINSON AC, PELLETT PE, ROIZMAN B, STUDDERT MJ, THIRY E (2009): The order Herpesvirales. *Arch. Virol.* **154**, 171 - 177.
- DECARO N, TINELLI A, PRATELLI A, MARTELLA V, TEMPESTA M, BUONAVOGLIA C (2003): First two confirmed cases of malignant catarrhal fever in Italy. *New Microbiol.* **26**, 339 - 344.
- DETTWILER M, STAHEL A, KRÜGER S, GERSPACH C, BRAUN U, ENGELS M, HILBE M (2011): A possible case of caprine-associated malignant catarrhal fever in a domestic water buffalo (*Bubalus bubalis*) in Switzerland. *BMC Vet. Res.* **7**, 78.
- KEEL MK, PATTERSON JG, NOON TH, BRADLEY GA, COLLINS JK (2003): Caprine herpesvirus-2 in association with naturally occurring malignant catarrhal fever in captive sika deer (*Cervus nippon*). *J. Vet. Diagn. Invest.* **15**, 179 - 183.
- LI H, DYER N, KELLER J, CRAWFORD TB (2000): Newly recognized herpesvirus causing malignant catarrhal fever in white-tailed deer (*Odocoileus virginianus*). *J. Clin. Microbiol.* **38**, 1313 - 1318.
- LI H, KELLER J, KNOWLES DP, CRAWFORD TB (2001): Recognition of another member of the malignant catarrhal fever virus group: an endemic gammaherpesvirus in domestic goats. *J. Gen. Virol.* **8**, 227 - 232.
- LI H, GAILBREATH K, BENDER LC, WEST K, KELLER J, CRAWFORD TB (2003a): Evidence of three new members of malignant catarrhal fever virus group in Muskox (*Ovibos moschatus*), Nubian ibex (*Capra nubiana*) and Gemsbok (*Oryx gazella*). *J. Wildl. Dis.* **39**, 875 - 880.
- LI H, WUNSCHMANN A, KELLER J, HALL G, CRAWFORD TB (2003b): Caprine herpesvirus-2-associated malignant catarrhal fever in a white tailed deer (*Odocoileus virginianus*). *J. Vet. Diagn. Invest.* **15**, 46 - 49.
- LI H, KARNEY G, O'TOOLE D, CRAWFORD TB (2008): Long distance spread of malignant catarrhal fever virus from feedlot lambs to ranch bison. *Can. Vet. J.* **49**, 183 - 185.
- PIZARRO-LUCERO J, CELEDON MO, NAVARRO C, ORTEGA R, GONZALEZ D (2005): Identification of a pestivirus isolated from a free-ranging pudu (*Pudu puda*) in Chile. *Vet. Rec.* **157**, 292 - 294.
- TWOMEY DF, BOON JD, SAYERS G, SCHOCK A (2010): *Arcanobacter pyogenes* septicemia in a southern pudu (*Pudu puda*) following uterine prolapse. *J. Zoo Wildl. Med.* **41**, 158 - 160.
- VIKØREN T, LI H, LILLEHAUG A, JONASSEN MC, BOCKERMAN I, HANDELAND K (2006): Malignant catarrhal fever in free-ranging cervids associated with OvHV-2 and CpHV-2 DNA. *J. Wildl. Dis.* **42**, 797 - 807.

CONJUNCTIVITIS OF GREATER RHEA (*RHEA AMERICANA*) IN THE MIDDLE EAST

MOLNÁR L¹, MAJOR P¹, PTACEK M²

¹University of Veterinary Medicine and Pharmacy, 040 01 Košice, SLOVAKIA; ladislav.molnar@uvlf.sk

²PROFALCON, Falcon Hospital, P. O. Box 1225, Al Ain, UNITED ARAB EMIRATES

The authors describe clinical cases of unusual presentation of conjunctivitis and blepharitis in captive greater rhea (*Rhea americana*). Two adult and three one year old birds captive reared in a private wild life collection, Al Ain in United Arab Emirates, developed severe conjunctivitis with constant lacrimation within a period of two weeks. In the conjunctival sacs of the animals numerous 1 to 2 mm long parasites were found which were identified as eye flukes (*Philophthalmus gralli*). This is a first report of *Philophthalmus gralli* infection in greater rhea in the Middle East and this report extends the known geographic range of this parasite.

P. gralli was originally described from the conjunctival sac of a chicken in Indochina. It has been reported from various birds in Asia. The first report in a struthioniform host, an ostrich, is from Florida in 1980. As intermediate hosts fresh water snails *Tarebia granifera* and *Melanoides tuberculata* were identified. In the presented case greater rheas were kept and youngsters were reared in a wild-life collection in a typical desert ecosystem of 0.5 km². The birds had free access to a fresh water lakes and a small grass-land area watered by sprinklers. The three one year old greater rhea started to develop severe conjunctivitis and lacrimation with progressive symptoms within two weeks. The most affected bird had permanently closed eyes and stopped to eat. It was manually restrained for medical examination, and suddenly died for stress during the procedure. *Post mortem* examination revealed innumerable trematodes in each conjunctival sac. They were located between the nictitating membrane and the outer eyelids. Some parasites were next to the globe beneath the nictitating membrane. They were identified as *Philophthalmus gralli* in the Central Veterinary Research Laboratory in Dubai. The remaining birds were treated by praziquantel 30 mg/kg (DRONCIT inj., Bayer Vital GmbH, Leverkusen, Germany). After ten days the treatment resulted in a temporary elimination of the symptoms but one month later the symptoms reoccurred in the flock. The flock was moved to the area with no access to fresh water lake or grass-land area. The treatment with praziquantel was repeated, combined with mechanical debridement of the conjunctival sacs by swab. The condition of the four remaining greater rhea markedly improved and no reinfection and conjunctivitis was reported since. There was no sign of similar ocular disorder in any other avian species in the same wild life collection. Most likely the *P. gralli* infection in the greater rheas was related to free movement of birds and access to a fresh water lake as the birds occasionally fed on snails abundant in locality. Three different species of snails were collected from the locality. The snails were sent for identification and study of their possible role of intermediate hosts in *P. gralli* life cycle. Because suitable intermediate hosts, fresh water snails, had been introduced in locality and the creation of fresh water ponds in desert environment, the fluke has been able to complete its life cycle. It seems likely that wild migratory birds had introduced the flukes. Evidence of eye flukes infection in struthioniform host is a potential health risk for growing ostrich farming in the Middle East or arid environment. To our knowledge it is the first record of such infection in Struthioniformes species in that region.

INVESTIGATING FLAVIVIRUS INFECTIONS IN NONHUMAN PRIMATES

NIPHUIS H, FAGROUCH Z, BOGERS W, VERSCHOOR E

Primate Viral Diagnostics Lab, Molecular Virology Unit, Dept. of Virology, Biomedical Primate Research Centre (BPRC), Lange Kleiweg 161, 2288 GJ Rijswijk, THE NETHERLANDS;
niphuis@bprc.nl

Primate Viral Diagnostics provide diagnostic services to various zoos and sanctuaries with current interest in flavivirus infections. Certain flaviviruses, such as Dengue virus (DV) and West Nile virus (WNV), may cause encephalitis in different species. They are transmitted by arthropod vectors and, thus, classified as arboviruses.

In this presentation, we provide an overview of our serological flavivirus screening data, including samples from different European, Asian and African collections.

Using ELISA, most frequently serum-antibodies to WNV (prevalence 97/1103) were detected, followed by anti-DV antibodies (82/1092). Anti WNV and DV antibodies were detected in saimiri-, capuchin-, mandrill-, gorilla-, gibbon-, macaque- and bonobo species. However, in most cases, DV was ruled out as the possible cause of infection in captive-bred animals, since they were kept in a country with no suitable vector. In some cases, a cross reaction was suspected because it is known that DV can cross react with antibodies to other flaviviruses (Yellow Fever virus, Japanese Encephalitis virus), or certain bacterial infections (e.g. *Brucella*- and *E. coli* species). Therefore, additional screening for these pathogens was started in WNV and DV-positive animals.

To confirm WNV and DV infections we performed WNV-neutralisation (WNV-N) assays and DV antigen ELISA (DVAg). The preliminary results revealed animals with WNV-VN serum titers up to 11000 and one DVAg positive sample suggesting on-going WNV/DV infections in non-human primates in zoos and sanctuaries.

ANAESTHESIA PROTOCOL FOR CAPTIVE BROWN BEARS (*URSUS ARCTOS*) – QUICK INDUCTION, RELIABLE MAINTENANCE AND RAPID RECOVERY

PAINER J¹, FRITSCH G¹, HERTWIG C², GÖRITZ F¹

¹Leibniz Institute for Zoo and Wildlife Research (IZW), Alfred-Kowalke-Str. 17, 10315 Berlin, GERMANY; painer@izw-berlin.de

²Competence Centre Bears, Four Paws and Bear Park Müritzer, Schombergstraße 120, 22767 Hamburg, GERMANY

During the last three years we immobilised 38 different captive brown bears (*Ursus arctos*). The data of these anaesthesias are summarised in this study to provide a protocol with quick induction, reliable maintenance and rapid recovery for this animal species. The animals were confiscated from their original housings (private owners or animal parks in Germany, Poland, Kosovo) due to animal welfare reasons. For capture, anaesthesia was administered via three cc darts equipped with 2 x 60 mm needles and shot by a CO₂ dart-gun. A combination of ketamine (2.4 ± 0.8 mg/kg BW, ketamine 10 %; Essex GmbH, Munich, Germany, medetomidine (0.036 ± 0.01 mg/kg BW, Dr. S. Quandt, Bryanston, South Africa), midazolam (0.05 ± 0.02 mg/kg BW, Dr. S. Quandt, Bryanston, South Africa), and butorphanol (0.05 ± 0.02 mg/kg BW, Dr. S. Quandt, Bryanston, RSA) was injected as initial dose. A rapid and smooth induction time of 4 ± 1 minutes (total recumbency) after intra-muscular (preferably upper front leg or lower shoulder) dart-injection was observed. If prolonged immobilisation was required, the drugs needed to be topped up on average 40 minutes (22 – 75 minutes) after induction. Dependent on the situation and duration, either ketamin in combination with medetomidine or butorphanol, or a prolongation with inhalation anaesthesia were used. The patients got medical oxygen intra-nasal or intra-tracheal, a venous catheter (*V. jugularis*) for an isotonic infusion drip, and they were monitored for reflexes and shifts in vital parameters every 10 to 15 minutes. The heart rate was on average 46 ± 15 beats/min, respiration rate was 8 ± 3 deep breaths/min, pulse-oximetry showed on average of 97 ± 4 % oxygen saturation, at 37.6 ± 0.4 °C body temperature. Furthermore blood samples for blood gas analysis (i-stat), biochemistry, haematology and hormone analysis were taken (detailed results will be presented at the conference). The protocol was partially antagonised with 5.9 ± 1.7 mg atipamezol (Antisedan, Orion Corporation, Espoo, Finland) per 1 mg medetomidine plus 4.6 ± 3 mg naltrexon (Dr. S. Quandt, South Africa) per 1 mg butorphanol intra-muscular, earliest 30 minutes after the last ketamine injection. The bears were put into transport boxes, and after they fully awake from anaesthesia they were transported to different bear sanctuaries provided by *Four Paws* (Germany and Kosovo). The advantages of this anaesthetic protocol are a rapid induction time, without respiratory problems or spontaneous arousals, a stable and reliable maintenance for at least 40 minutes after darting, and a smooth recovery.

A UNIQUE FELID REPRODUCTIVE CYCLE - THE LONGEST CORPUS LUTEUM LIFESPAN AMONG MAMMALS LEADS TO A MONO-OESTROUS REPRODUCTION IN LYNX (*LYNX LYNX*)

PAINER J¹, JEWGENOW K¹, DEHNHARD M¹, ARNEMO JM², LINNELL JDC³, ODDEN J³,
HILDEBRANDT TB¹, GÖRITZ F¹

¹Leibniz Institute for Zoo and Wildlife Research (IZW), Alfred-Kowalke-Str. 17, 10315 Berlin, GERMANY; painer@izw-berlin.de

²Hedmark University College, Faculty of Applied Ecology and Agricultural Sciences, Dept. of Forestry and Wildlife Management, Campus Evenstad, NO-2418 Elverum, Norway and Swedish University of Agricultural Sciences, Faculty of Forest Sciences, Dept. of Wildlife, Fish and Environmental Studies, SE-901 83, Umeå, SWEDEN

³Norwegian Institute for Nature Research, Tungasletta 2, 7485 Trondheim, NORWAY

Felids generally follow a poly-oestrous reproductive strategy. Eurasian lynx (*Lynx lynx*), display a different pattern of reproductive cyclicity where physiologically persistent corpora lutea (CLs) induce a mono-oestrous condition which results in highly seasonal reproduction. The present study was based around a sono-morphological and endocrine study of captive Eurasian lynx, and a control-study on free-ranging lynx. We verified that CLs persist after pregnancy and pseudo-pregnancy for at least a two-year period. We could show that lynx are able to enter oestrus in the following year, while CLs from the previous years persisted in structure and only temporarily reduced their function for the period of oestrus onset or birth, which is unique among felids. The almost constant luteal progesterone secretion (average of 5 ng/ml serum) seems to prevent folliculogenesis outside the breeding season and has converted a poly-oestrous general felid cycle into a mono-oestrous cycle specific for lynx (PAINER et al., 2014). The hormonal regulation mechanism which causes lynx to have the longest CL lifespan amongst mammals remains unclear. The described non-felid like ovarian physiology appears to be a remarkably non-plastic system. The lynx's reproductive ability to adapt to environmental and anthropogenic changes needs further investigation.

Reference

PAINER J, JEWGENOW K, DEHNHARD M, ARNEMO JM, LINNELL JDC, ODDEN J, HILDEBRANDT TB, GOERITZ F (2014): Physiologically persistent corpora lutea in Eurasian lynx (*Lynx lynx*) – longitudinal ultrasound and endocrine examinations intra-vitam. PLOS ONE 9, e0469. DOI:10.1371/journal.pone.0090469.

WILD BIRDS AND AVIAN CHLAMYDIOSIS

PROKEŠ M¹, BENKÖ Z¹, KORYTÁR L², ONDREJKOVÁ A¹, ONDREJKA R¹, ČECHVALA P¹

¹The University of Veterinary Medicine and Pharmacy in Košice, Dept. of Epizootiology and Parasitology, Komenského 73, 041 81 Košice, SLOVAK REPUBLIC; marian.prokes@uvlf.sk

²The University of Veterinary Medicine and Pharmacy in Košice, Dept. of Pharmacology and Toxicology, Komenského 73, 041 81 Košice, SLOVAK REPUBLIC

Birds represent one of the most abundant group of vertebrate species on earth. Their extension is characteristic of cosmopolitan lifestyle, which includes the ability for long-distance migration. Birds represent important reservoir for many zoonotic agents. The most common zoonosis transmitted by birds is chlamydiosis, caused by *Chlamydophila psittaci*. In our micro-study, we used nested Polymerase Chain Reaction (for extraction DNA-sorb-AM nucleic acid extraction kit – Central Research Institute for Epidemiology, Moscow, Russia and for Amplification GenPak DNA PCR test) for detection of *Chlamydomphila* spp. We used oral and cloacal swabs obtained from 34 wild and caged birds including feral pigeons. Wild birds (*Turdus philomelos* 1 ex., *Prunella modularis* 1 ex., *Carduelis carduelis* 1 ex., *Emberiza citrinella* 2 ex., *Phoenicurus ochruros* 1 ex., *Coccothraustes coccothraustes* 1 ex., *Cyanistes caeruleus* 3 ex.) were sampled on Drienovec Bird Ringing Station (GPS: N 48,37" E 20,55"). Caged birds (*Psittacus icterotis* 2 ex., *Psittacus hollandicus* 2 ex., *Platycercus elegans* 1 ex., *Columba livia f. domestica* 1 ex.) were sampled in private breeding. Feral pigeons 18 ex. were sampled in connection to official depopulation measures in the city Moldava nad Bodvou, Slovakia. According to other authors the prevalence of *C. psittaci* performed by PCR detection of the oral and cloacal swabs from wild birds was different in various European cities: Madrid (Spain) 52.6 %; Zagreb (Croatia) 15.8 %; Amsterdam (The Netherlands) 7.9 %. In our study the detected prevalence of *Chlamydomphila* spp. was 3 %. Although low, our results show a risk for infection of human population. This is especially the case for professionals in close contact with birds. Preventive measures are most important in work with animals and in contaminated environments.

Acknowledgements

The present study was carried out within the framework of the project VEGA No. 1/0379/13 (*Research on selected etiological agents of infection diseases in free living birds, their zoonotic potential and public health exposure*), of the Ministry of Education, Science, Research and Sport of the Slovak Republic.

A NEW TECHNIQUE FOR HELICOBACTER INFECTION DIAGNOSIS IN CHEETAHS (*ACINONYX JUBATUS*)

QUINTARD B¹, APERY S², LEFAUX B¹

¹Parc zoologique et botanique de Mulhouse, 51 rue du jardin zoologique, 68100 Mulhouse, FRANCE; benoit.quintard@mulhouse-alsace.fr

²Museum de Besançon, 99 rue des Fusillés, 25000, Besançon, FRANCE

Helicobacter infection is one of the major health issues in cheetahs (*Acinonyx jubatus*). Four different *Helicobacter* species are frequently associated with gastritis and can also be found in healthy cheetahs. Though, depending on individual factors, they can be a real health concern and need to be closely monitored.

The recommended technique to get a precise diagnostic is to realise a gastric endoscopy and practice bacteriology on biopsies. The principle of the technique presented here is to bring out the typical metabolism of the bacteria.

Indeed *Helicobacter* species have an urease enzyme that can convert urea in carbon dioxide and ammonia. Giving orally the diseased cheetah a carbon marked urea solution, we can check the presence of *Helicobacter* in its stomach by detection of potential carbon marked CO₂ in his expired air. To test this, we use the human specialty Helikit[®] 75 mg (Mayoly Spindler laboratories, Chatou, France) designed for *in vivo* diagnostic of human *Helicobacter pylori* infection.

The cheetah (which should not be treated beforehand to avoid any false result) has to be sedated for a 40 minutes period in sternal recumbency, head elevated. At T0, the cheetah is given a solution of diluted citric acid (Helikit[®] solution n°1: 1.4 g citric acid diluted in 100 ml water) and two air samples are taken through the tracheal probe. Then a carbon marked urea solution (Helikit[®] solution n°2: 75 mg C13 urea diluted in 100 ml water) is given to the cheetah through an oesophageal probe. Thirty minutes later, two more air samples are taken and the animal can then be awakened. All four samples are then sent to the lab to determine the C¹³/C¹² ratio. If it is above 1/4000, then the test is positive and *Helicobacter* sp. are present in the cheetah's stomach. This finding associated to the typical clinical signs (anorexia, weight loss, vomiting) are the trigger element to the decision of beginning a tritherapy treatment, which can have big consequences on gastric microbiology if not used only when needed.

The classic and approved technique involves an endoscope, an expensive equipment that not all institutions holding cheetahs can afford. The interest of the diagnosis method presented in this case is to be less expensive and thus reachable for each zoo. This new technique is also less invasive as no biopsies have to be made. A qualitative testing associating urease testing technique and endoscopy technique would allow knowing if the urease test is able to detect all the different species of *Helicobacter*.

Our case illustrates a promising method to diagnose *Helicobacter* infections, one of the major health issues in cheetahs. This cheaper and less invasive technique could help every zoo in deciding when to treat a cheetah with the recommended tritherapy, an effective but potentially aggressive toward gastric micro fauna treatment.

ELECTROLYTES AND VENOUS BLOOD GASES IN WILD LIVING BARN SWALLOWS (*HIRUNDO RUSTICA*) CAPTURED DURING AUTUMN MIGRATION IN SLOVENIA

RAČNIK J¹, ZADRAVEC M¹, TRILAR T², ZORMAN ROJS O¹

¹University of Ljubljana, Veterinary Faculty of Ljubljana, Institute of Poultry Health, Dept. for birds, small mammals and reptiles, Cesta v Mestni log 47, 1000 Ljubljana, SLOVENIA; josko.racnik@vf.uni-lj.si

²Slovenian Museum of Natural History, Prešernova 20, p.p. 290, 1001 Ljubljana, SLOVENIA

Haematology, biochemistry, blood gases and electrolyte measurements are useful tools for assessing health status and capture stress in wild living birds. On the other hand the reference values for electrolytes and venous blood gases in free living passerine birds are rather rare or lacking. With the availability portable analysers requiring only 0.1 ml of blood for such measurements are now possible also in small passerine birds. The aim of this study was to test the I-Stat[®] clinical analyser under field conditions and to set the blood gas and electrolyte values in clinically healthy wild living barn swallows (*Hirundo rustica*) after capture by mist net, banding and venipuncture during autumn migration in Slovenia.

Wild living barn swallows were captured into mist nets. Birds were weighted, aged, sexed, banded with an aluminum ring and clinically examined. After banding, 0.15 ml of blood was collected from the right jugular vein using a 1 ml insulin syringe with the integral 29 gauge needle. Venous blood measurement was performed immediately after blood collection using an I-Stat[®] clinical analyser (Vetscan I-Stat system, Abbot Diagnostic). CG8+ cartridges were used. Analytes measured were pH, pCO₂, pO₂, TCO₂, HCO₃, Base Excess (BE), SO₂, sodium (Na), potassium (K), glucose (Glu), haematocrit (Hct) and haemoglobin (Hgb).

A total of 47 venous blood measurements were performed. Only one measure failure was noted. Measured parameters are presented as mean ± standard deviation. The pH was 7.52 ± 0.045. pCO₂ and pO₂ were respectively, 33.7 ± 2.70 mmHg and 40.61 ± 2.76 mmHg. BE was 4.7 ± 3.42 mmol/L, HCO₃ was 27.52 ± 2.79 mmol/L, TCO₂ was 28.48 ± 2.86 mmol/L. Mean sO₂ was 81.35 ± 3.33 %. Na and K were respectively, 152.73 ± 1.45 mmol/L and 3.61 ± 0.35 mmol/L. Glu was 19.19 ± 2.08 mmol/L and iCa was 1.13 ± 0.05 mmol/L. Hct and Hgb were respectively, 45 ± 4.14 % and 15.3 ± 1.41 g/dl.

The I-Stat[®] clinical analyser is a useful tool for measuring venous blood gases, electrolyte, haemoglobin, haematocrit and other values in small free living passerine birds in field conditions although values have to be interpreted carefully especially when they are measured after capture and intensive handling.

THErapy-RESISTANT ENDOPARASITOSIS IN A MALE AYE-AYE (*DAUBENTONIA MADAGASCARIENSIS*)

RISCH T¹, KERSHAW O², OCHS A¹

¹Berlin Zoo, Hardenbergplatz 8, 10787 Berlin, GERMANY; tina.risch@gmx.de

²Institut für Tierpathologie der FU Berlin, Robert-von-Ostertag-Str. 15, 14163 Berlin, GERMANY

Aye-ayes (*Daubentonia madagascariensis*) are endemic to the island of Madagascar and worldwide only a few zoos actually keep these extraordinary nocturnal lemurs. Together that might be the reason for seldom published *post mortems* and pathological findings in this species.

A 13 year old male aye-aye suddenly died in November 2013 after few days of mild clinical symptoms: moderate apathy and low food intake. The animal was born in the zoo of Antananarivo, Madagascar and arrived at Berlin Zoo, Germany in April 2007.

After eight weeks of quarantine and a single oral treatment with ivermectine (1 mg/kg, Ivomec[®], Merial GmbH, Hallbergmoos, Germany) the aye-aye has been transferred to the nocturnal animal department. Almost one year after arrival, nematodes were found in the animals faeces from time to time. Parasitological examinations revealed them to be *Spirurida* spp. (*Physaloptera* spp. and *Gongylonema pulchrum*) and/or *Strongyloides* spp. The exact species could not be described yet. Recent DNA-sequencing may expect a new species of *Spirurida*. A metaphylactic treatment has been established consisting of alternating administration of ivermectine p.o., s.c. and i.m. and a combination of fenbendazole and praziquantel (60 mg/kg and 6 mg/kg, Caniquantel Plus[®], IDT Biologika GmbH, Dessau-Roßlau and ETEVE GmbH Tiergesundheit, Unterschleißheim, Germany) p.o. every two months or whenever nematodes were detected in the faeces or in regularly examined faecal analyses. Main pathological findings and probable cause of death was a severe, multifocal cholangitis and cholangiohepatitis associated with a multifocal, high grade bile duct hyperplasia and detection of nematodes in the liver and gallbladder. Inflammation of stomach and intestines, as well as a generalised eosinophilia and plasmacytosis in the mesenteric and sternal lymph nodes and in the spleen presumably have attributed to the high grade, chronic infection with nematodes. A bacteriological examination revealed a (presumed) secondary bacterial infection of the intestine with alphatoxin (Toxovar A) producing *Clostridium perfringens*, *Proteus* sp., beta-haemolytic *E.coli* and others that may have contributed as well to these results.

Despite regular deworming there seemed to be a resistance to the used anthelmintic agents. We suggest that the animal was already a carrier of these parasites, which might also be endemic to Madagascar, when he was transferred to Germany.

A RETROSPECTIVE STUDY OF REPTILE NECROPSY REPORTS FROM 2002 TO 2012 AT ZOO BASEL

ROSSIER C¹, HOBY S², WENKER C², JERMANN T², POSTHAUS H¹

¹University of Bern, VETSUISSE Faculty, Institute of Animal Pathology, Länggassstrasse 122, 3012 Bern, SWITZERLAND; christophe.rossier@vetsuisse.unibe.ch

²Zoo Basel, Binningerstrasse 40, 4011 Basel, SWITZERLAND

Since 1876, various reptiles have been kept at Zoo Basel. In order to assess the major causes of mortality and to improve the husbandry and nutrition in the reptile collection, a retrospective study on the necropsy reports from the last ten years was conducted. Between 2002 and 2012, 141 reptiles from 30 different species were sent for necropsies to the Institute of Animal Pathology, VETSUISSE Faculty, University of Bern (Switzerland).

For each case, main findings were reported and classified in categories. The most frequent findings were infections with 44 %, divided in the subcategories: bacterial (65 %), parasitic (23 %), fungal (9 %) and viral (2 %).

The second most frequent category was metabolic disorders (metabolic bone disease and gout), which were diagnosed in 61 % of the animals. Further categories included traumatic (12 %), unknown (8 %), toxic (3 %) and neoplastic (2 %) causes.

Metabolic bone disease was diagnosed in 49 of 119 (41 %) saurians and chelonians submitted for *post mortem* examination. The results of this study corroborate earlier subjective impressions of the zoo veterinarians, which suspected a high number of metabolic disorders in Zoo Basel's reptile collection, mainly related to failures in husbandry and nutrition. In light of these results, the zoo initiated a complete health check of its collection of lizards and tortoises that includes contributions of veterinarians, curators and zookeepers in order to improve the husbandry and dietary conditions.

CHEMICAL IMMOBILISATION OF LETEA FERAL HORSES (*EQUUS CABALLUS*) USING KETAMINE AND MEDETOMIDINE

ROSU O^{1,2}, UDRESCU LA¹, BIRTOIU D³, MANU E²

¹University of Agronomic Sciences and Veterinary Medicine Bucharest, Faculty of Veterinary Medicine, Splaiul Independentei 105, 050097 Bucharest, ROMANIA; rosu.ovidiu@gmail.com

²Vier Pfofen (Four Paws) Romania, Maica Alexandra 24, 011243 Bucharest, ROMANIA

³University of Agronomic Sciences and Veterinary Medicine Cluj-Napoca, Faculty of Veterinary Medicine Cluj-Napoca, Calea Manastur 3-5, 400372 Cluj Napoca, ROMANIA

Summary

Thirty-five free-range feral horses were successfully remotely anaesthetised for immunocontraception using different combinations of ketamine/medetomidine with or without hyaluronidase. Only horses where fully discharged darts induced anaesthesia (without any top-up darts and/or previous deflected darts) were included in our study. A mean (\bar{x}) induction time of 8.85 minutes (SD = 4.76) was recorded for a group of 28/35 horses that were immobilised with ketamine (1.45 - 3.8 mg/kg, \bar{x} = 2.32 mg/kg) and medetomidine (0.05 - 0.15 mg/kg, \bar{x} = 0.09 mg/kg) and a mean induction time of 9 minutes (SD = 4.83) for another group (7/35) that received ketamine (1.25 - 2.2 mg/kg, \bar{x} = 1.74 mg/kg), medetomidine (0.08 - 0.17 mg/kg, \bar{x} = 0.119) and hyaluronidase (2.85 - 4.4 IU/kg, \bar{x} = 3.64 IU/kg). Approx. 25 minutes after induction five horses in the first study group (n = 28) and two from the second (n = 7) required additional 1.4 mg/kg ketamine I.V. to achieve a deeper anaesthesia level. The mean duration of anaesthesia was 69.56 min (SD = 12.87) for the first study group and 73.8 min (SD = 20.54) for the second study group. Heart rate, respiratory rate, temperature and SpO₂ were measured and recorded during recumbency. No specific antidote (atipamezole) was given, except for one individual due to critical clinical conditions. During reversal the horses were manually assisted to sternal position with the front limbs extended, which facilitated their raising. Once standing most of the horses preferred to remain stationary if not disturbed. Some tachypnoea and one case of a stormy awakening was reported, however, there were no post-anaesthetic complications or injuries.

Introduction

Free-ranging feral horses are commonly captured in round-ups, using horse riders, motorcycles or helicopters with which they are herded into corral traps. This stressful process may result in capture of horses of mixed sexes and ages from different herds, with a high risk of injuries for the captured individuals and the people involved in the process.

An immuno-contraception programme of overabundant Letea feral horses, requiring ear-tag identification, health check and PZP vaccination of mares, would have required the round-up of hundreds of horses to selectively contracept the targeted individuals.

The risks associated with round-ups were the reasons for the present study evaluating the feasibility of selective capture using on ground remote tranquilisation. The drug of choice for wild equids immobilisation in general, and for feral horses in particular, is considered to be the highly potent opiate ethorphine (WALZER, 2007; SEAL et al., 1985). Due to the restricted availability of ethorphine and previous positive experience with the combination of dissociatives and alpha-2 agonists in feral horses (ROSU et al., 2012) and other equids (MATTHEWS et al., 1995), different combinations of ketamine and medetomidine with or without hyaluronidase were taken into consideration.

The purpose of the study was to find a suitable ketamine/medetomidine combination, fitting into a single dart that would offer a suitable anaesthesia for free-ranging feral horses (*Equus caballus*) in the field.

Materials and methods

The studies were conducted in Grindul Letea (45°20'43"N, 29°30'45"E), Danube-Delta, Romania, between October 2013 and January 2014. Ambient temperatures ranged from +5 to +23 °C.

A total of 52 horses were successfully immobilised in this period, (49 mares and three subadult males) from which 35 anaesthetics were included in the present study. Due to the lack of sexual dimorphism the three young males were confused to be females and mistakenly darted.

Animals appeared healthy based on body weight and physical examination. The age was estimated to range from 2 to 20 years (\bar{x} = 5.8 yr) and the body weight from 200 to 400 kg (\bar{x} = 310 kg).

The working protocol included health check, ear tagging, vaccination (Porcine Zona Pellucida, The Science and Conservation Center, Billings, USA) blood and faecal sampling, age estimation from dental surface and taking pictures for future identification. This protocol took up to 40 min to finish from the time of induction.

After being located, the mares were slowly approached and darted from the car. Distances between 15 and 45 meters allowed targeting the rump while the individuals remained relaxed and not moving.

Different combinations of ketamine 100 mg/ml (Vetased[®], Romvac, Filipesti de Padure, Romania), ketamine HCL dry powder 1 g/20ml (Ketamine 1 g[®], Kyron Laboratories, Benrose, South Africa) and medetomidine 40 mg/ml (Medetomidine 40 mg/ml[®], Kyron Laboratories, Johannesburg, South Africa) were used. In seven immobilisations hyaluronidase 5000 IU (Hyaluronidase 5000 IU[®], Kyron, Johannesburg, South Africa) was added to the dart combination.

Drugs were delivered remotely using 5.0, 6.0 or 7.0 ml, Ø13 mm aluminum disposable darts (Pneudart Type 'P'[®], Pneudart, Inc., Williamsport, USA), with either 3.81 cm or 5.08 cm barbed needles, delivered by Ø13 mm compressed air rifle (X-Caliber[®] Gauged Projector, Pneudart, Inc., Williamsport, USA).

After an animal was successfully darted it was left alone and observed from afar (100 - 200 m) with binoculars. Slowing or ataxia were considered as onset of induction. Induction time (minutes from darting until the animal went down and stayed down in sternal or lateral recumbency) and total time of recumbency (duration of anaesthesia) were recorded. The duration of anaesthesia was defined from the moment of recumbency to the moment the horse was standing again without assistance. Also the time of standing was considered to be the end of the procedure.

Once recumbent the horses were blindfolded and their body positioned laterally with their necks and lower front limbs extended.

In most of the cases the vital parameters were assessed (temperature, pulse, respiration, pulse-oximetry, capillary refill time) and noted every 10 min. The temperature was taken with an oral digital laser thermometer. In some cases two different pulse-oximeters were used. During three procedures an Oxi-100 VET[®] was used, and during 15 procedures a Nonin[®] 2500 A. The pulse oximeter probes were placed on the tongues. Respiratory rate was counted by visual assessment of thoracic and abdominal distension and air movement at the nares.

Different combinations of ketamine and medetomidine were used. In seven cases (20 %), hyaluronidase was added to the anaesthesia mix. The rest of the inductions (28/35, 80 %) were performed with ketamine/medetomidine combinations only.

Only the 35 cases of fully discharged darts (without any top-up darts and/or previous deflected darts) were included in the calculations and table. They are represented by Group 1 (ketamine + medetomi-

dine) including 28 horses and Group 2 (ketamine + medetomidine + hyaluronidase) including seven horses.

Statistics consisted of mean values and standard deviations (table 1).

Results

A total of 52 feral horse immobilisations were successfully performed in 16 days of fieldwork, from which 35 were induced with only one delivered dart.

The rest of the inductions (17/52) either required a top-up dart of 500 mg ketamine (6/17) for recumbency, and/or repetition(s) of darting with full dosages (one repetition in five individuals, two repetitions in two individuals) due to deflection of the darts.

The darts were mainly projected from the car. While the animals remained relatively calm with approaching vehicles, the horses tended to become nervous and move on as soon as the car stopped for darting, allowing only about 5 seconds for taking aim.

In the first study group (28/35; Group 1) induction was achieved in 8.85 minutes (SD = 4.76) using a mean of 2.32 mg/kg ketamine (1.42 - 3.8 mg/kg) in combination with 0.09 mg/kg medetomidine (0.05 - 0.15 mg/kg) (see table 1 and figure 1). In this group, in the case of five horses (approx. 25 minutes after induction) a supplementary 1.4 mg/kg ketamine I.V. was considered necessary to acquire a deeper plane of anaesthesia. The mean overall duration of anaesthesia in Group 1 for the horses (23/28) which did not require supplementary I.V. ketamine was of 69.56 minutes (SD = 12.87).

In Group 2 (7/35, \bar{x} = 20 %), a mean of 1.74 mg/kg ketamine (1.25 - 2.2 mg/kg) in combination with 0.119 mg/kg medetomidine (0.08 - 0.17 mg/kg) and 3.64 IU hyaluronidase (2.85 - 4.4 IU/kg), resulted in induction within 9 minutes (SD = 4.83) from darting. In this group 2/7 horses received supplementary 1.4 mg/kg ketamine I.V. approx. 25 minutes after induction. The mean overall duration of anaesthesia for the horses (5/7) without supplementary I.V. ketamine was of 73.8 (SD = 20.54) minutes (table 1 and figure 1).

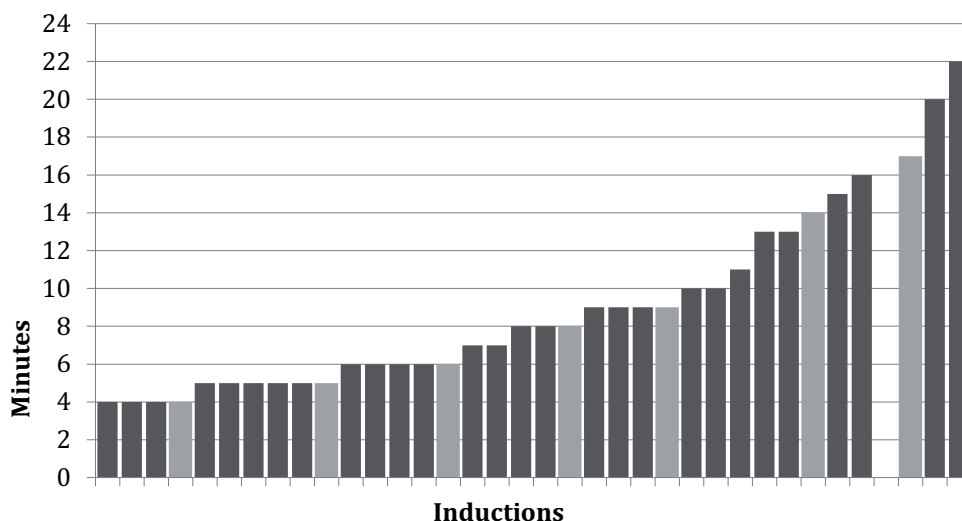


Fig. 1: Distribution of induction times for 28 horses immobilised using ketamine and medetomidine (dark grey), seven horses immobilised using ketamine, medetomidine and hyaluronidase (light grey).

Tab. 1: Descriptive statistics (mean, SD, median, min, max and n) for feral horses under two different immobilisation protocols.

	ketamine (mg/kg)	medetomi- dine (mg/kg)	hyalu- ronidase (IU/kg)	Induc- tion (min)	Time of re- cumbency (min)	Tem- perature (°C)	Respiratory rate (bpm)	Heart rate (bpm)
Group 1								
Mean	2.32	0.09	-	8.85	69.56	37.6	25.4	41.44
Standard deviation	0.56	0.02	-	4.76	12.87	1.34	9.29	8.84
Median	2.24	0.1	-	7.5	68	37.2	24	40
Minimum	1.42	0.05	-	4	60	34.1	14	26
Maximum	3.8	0.15	-	22	110	40.4	68	88
n	28	28	-	28	23	86	93	65
Group 2								
Mean	1.74	0.119	3.64	9	73.8	38.5	32.57	45.16
Standard deviation	0.32	0.02	0.54	4.83	20.54	1.22	12.10	6.30
Median	1.85	0.11	3.57	8	65	38.2	31	44
Minimum	1.25	0.08	2.85	4	48	36.3	11	36
Maximum	2.2	0.17	4.4	17	92	40.8	56	65
n	7	7	7	7	5	44	40	36

All of the above combinations offered good muscle relaxation and adequate anaesthetic depth.

Despite several moments of transitory tachypnoea, all the vital parameters, except SpO₂ were within the normal physiological range without any significant differences between the two groups. Nevertheless the mean heart rate was at the upper limit, both in Group 1 (\bar{x} = 41.11 bpm, SD = 8.84) and Group 2 (\bar{x} = 45.16 bpm, SD = 6.3) (table 1). The pulse-oximeters registered values under 90 % in all of the cases.

After 65 to 70 minutes of anaesthesia, the horses (25/28 in Group 1, and 7/7 in Group 2), were manually assisted into sternal position with their front limbs extended. The rest of the horses were able to position themselves sternally or woke up to standing position instantly. After approx. 9 minutes (\bar{x} = 8.9 min) in sternal position, the horses were given a manual stimulus on the head or back to stand up.

The majority of the horses from the study groups (91.4 %) remained on site upon standing. Several horses remained in the same area for up to three hours, however, if approached they would move away at pace or gallop. One horse (2.8 %) went back to sternal position shortly after standing to raise again after a couple of minutes.

Only in one case (2.8 %) with more than 90 min of recumbency, medetomidine antagonisation was considered necessary (atipamezole 0.1 mg/kg i.v., Alzane[®], Pfizer, León, Spain).

No post-anaesthetic morbidity or mortality was observed. The oldest mare in the study (estimated age 20 yrs) died six weeks after the anaesthesia procedure, however, this event was considered unrelated to the anaesthesia due to the lapsed time, poor body condition and the harsh weather from that period.

Discussion

The goal of this study was to find the best combination of easily available drugs with an overall quick induction, suitable anaesthetic depth for the PZP vaccination protocol and a smooth reversal in Letea feral horses.

A combination of approx. 2.32 mg/kg ketamine and 0.09 mg/kg medetomidine resulted in a satisfactory induction in 8.89 minutes and 69.56 minutes of anaesthesia. This combination is very similar with previously reported immobilisations in Przewalski's horses (2.1 mg/kg ketamine and 0.09 mg/kg medetomidine) (MATTHEWS et al., 1995).

The use of hyaluronidase (3.64 UI/kg) as an agent that increases the absorptions of other drugs offered similar results compared to the simple ketamine/medetomidine combinations: induction in 9 minutes and a duration of anaesthesia of 73.8 minutes. However, those results were achieved with lower doses of ketamine (1.74 mg/ml) and higher doses of medetomidine (0.119 mg/kg).

Nevertheless, adding hyaluronidase to the darts increased the total volume, which required the use of bigger darts (e.g. 7.0 ml) and, consequently, shorter target ranges and decreased accuracy. Associated with the fact that both combinations' results were similar, and that for ketamine/medetomidine, smaller 6.0 ml darts were used, the latter combination was preferred.

In five horses from Group 1 and two from Group 2, approx. 25 minutes after induction, a top-up of intravenous ketamine 2.1 mg/kg was considered necessary for quick return to anaesthetic depth to continue with the working protocol. Reasons for those top-ups were that slight eye and/or ear movements were seen and thus considered a light plane of anaesthesia that had to be addressed. Nevertheless, once several anaesthesias were performed it was seen that even in the presence of some cases of eye and/or ear movements our working protocol could be performed safely, without the risk of the horse to wake up, consequently no more top-ups were considered to be necessary.

Due to the fact that in the Letea region there are no direct predators and administration of reversal agents would have been beyond the financial possibilities, the authors considered recovery without medical reversal acceptable. No deaths or injuries were reported in the days following the immobilisations.

Most of the horses were able to stand up at first attempt. Once standing they seemed to prefer remaining stationary and only moved if approached, either in pace or gallop. If their herd was in vicinity the horses slowly followed the other group members. This prolonged state of lethargy is considered to be the sedative effect of the medetomidine.

The authors found out that positioning the horses sternally with their front limbs extended quickened the reversal and helped them acquire the standing position without stumbling and falling.

From the total amount of immobilisations done, in 9/52 cases the darts hit other parts of the body (five times the abdominal area, one time at the base of the tail, one time in the tibia, one time in the neck and one time in the masseter muscle) which, depending on the site injected, delayed the time of induction. From all those injections the longest period of inductions was seen to be those of the darts that hit the abdominal area (more than 20 minutes). This long period of induction might be explained either by a slower absorption of the abdominal muscles or because the anaesthetic could have been delivered and absorbed intraperitoneally. Poor dart placement and deflected (bounced) darts contributed to poor induction.

Peripheral oxygenation (SpO₂) in most of the immobilisations has been seen to have values under the normal range (< 90 %). Those low readings could be explained by the decreased peripheral oxygenation effect of medetomidine (MATTHEWS et al., 1995, SARAZAN et al., 1989) and insufficient oxygenation due to the perfusion/ventilation mismatch acquired during the horses' lateral recumbency (GREEN and KEEGAN, 2002). Although no pathology has been reported the following days, supplemental oxygenation should have been provided.

The authors conclude that using ketamine/medetomidine combinations (with or without hyaluronidase) is a reliable alternative to ethorphine for field feral horse immobilisations, offering good muscle relaxation and adequate anaesthetic depth, with few complications and smooth reversals, even without antagonisation.

Acknowledgements

We would like to thank Kuki Barbuceanu and Robert Hengl from Four Paws animal welfare NGO for creating the opportunity and providing the funds to work on the Birth Control Project in Letea, Danube Delta. We also thank Prof. Dr. Alin Birtoiu from the Faculty of Veterinary Medicine Bucharest for his patience and giving his invaluable support in the process of starting the project. Last but not least we want to thank all the volunteers without whom this project would not have been possible.

References

- GREEN SA, KEEGAN RD (2002): *Equine Anesthesia*. In: *Veterinary Anesthesia and Pain Management Secrets*, Hanley & Belfus Publishing, 245 - 252.
- MATTHEWS NS, PETRINI KR, WOLFF PL (1995): *Anesthesia of Przewalski's horses (Equus przewalskii przewalskii) with medetomidine/ketamine and antagonism with atipamezole*. *J. Zoo. Wildl. Med.* **2**, 231 - 236.
- ROSU O, UDRESCU LA, BIRTOIU A (2012): *Alternative chemical immobilisation in a group of captive feral horses using a homemade remote delivery*, *Proc. Int. Conf. Dis. Zoo. Wild. Anim.* 2012, 176 - 180.
- SARAZAN RD, STARKE WA, KRAUSE GF, GARNER HE (1989): *Cardiovascular effects of detomidine, a new α -adrenoceptor agonist, in the conscious pony*. *J. Vet. Pharmacol. Therap.* **12**, 378 - 388.
- SEAL US, SINIFF DB, TESTER JR, WILLIAMS TD (1985): *Chemical immobilization and blood analysis of feral horses*, *J. Wildl Dis.* **21**, 411 - 416.
- WALZER C (2007): *Non domestic equids*. In: West G, Heard D, Caulkett N (Eds.): *Zoo Animal & Wildlife Immobilization and Anesthesia*. Blackwell Publishing, 523 - 531.

INFECTIOUS DISEASES IN THE CONTEXT OF HUMAN-WILDLIFE CONFLICT IN AFRICA

ROŻEK A, BARSZCZ K, KUPCZYŃSKA M

Warsaw University of Life Sciences, Faculty of Veterinary Medicine, Dept. of Morphological Sciences, Nowoursynowska 159, 02-776 Warsaw, POLAND; natalia.rozniewska@poczta.fm

Human-wildlife conflicts are known worldwide since humans and wild animals have been sharing the same habitats and resources. Due to increasing pressure on scarce natural resources the more frequent contact between both groups conduces to the spread of infectious diseases. Especially the livestock of small-scale farmers is under constant risk as they graze in open areas with less bio-security measurements.

The purpose of this study was to point out major infectious diseases of African livestock which are commonly associated with wildlife, the way they are spread, the species they affect and their epizootic potential. The causes and effects are discussed as well as possible resolutions.

Ten selected diseases are shown: bovine tuberculosis, brucellosis (*Brucella abortus*), foot and mouth disease, Rift Valley fever, rabies, anthrax, canine distemper, Ebola haemorrhagic fever, African swine fever and African horse sickness.

Pathogen strain, environmental factors, type and frequency of contact determine the way of inter-species disease transmission. Pathogens can be spread directly by biting, consumption of infected meat and milk, or indirectly by a disease vector, air, water sources and pastureland.

Possible solutions for diseases eradication include: stamp out, education of local populations on the risk for infection, use of veterinary cordon fence, vaccination of animals and people, control of livestock import/export, epidemiologic surveillance and a rapid reaction system.

The poster shows the complexity and bidirectionality of the problem, which can be disastrous for both the people, domestic animals and African wildlife.

OVARIAN TERATOMA IN A FALLOW DEER (*DAMA DAMA*)

SABÉS-ALSINA M¹, FERNÁNDEZ-BELLON H², HUZMAN M², ALMAGRO V², TALLÓ-PARRA O¹,
CABAJAL A¹, LÓPEZ-BÉJAR M¹

¹Universitat Autònoma de Barcelona, Dept. Animal Health and Anatomy, 08193 Bellaterra, Barcelona, SPAIN; manel.lopez.bejar@uab.cat

²Parc Zoològic de Barcelona, Parc de la Ciutadella s/n, 08003 Barcelona, SPAIN

Teratomas are germ cell tumors in which the cells have undergone somatic differentiation, producing mature but disorganised tissues of two or more embryonic layers. Ovarian teratomas are rarely observed in animals, and this congenital abnormality has only been reported in the bitch, sow, mare and cow. A nulliparous adult (> 12 years old) female fallow deer (*Dama dama*), kept within a non-breeding group, at Barcelona Zoo was euthanatised due to a non-tractable and non-reducible femoral head dislocation in November 2013. Necropsy revealed the presence of an ovoid mass, approximately 7.5 cm in diameter, in the region of the right ovary. The mass was encapsulated and had a slightly lobulated surface. The left ovary, the uterus and the remaining abdominal organs were normal. No masses were observed in other organs. The reproductive tract was fixed in formalin. Tissue samples, including several samples of the ovarian mass were processed for routine histopathological analysis with haematoxylin-eosin stain. Histological examination of the left ovarian mass revealed a variety of tissues with origin from different embryonic germ cell layers, such as hair, epidermal epithelium, sebaceous and sweat glands, keratin, tooth, cartilage and muscle. The histological examination of the right ovary showed a physiological and functional ovary with a corpus rubrum, probably as a consequence of a recent ovulation. Based on the histopathological findings, the ovarian mass was diagnosed as an ovarian teratoma. This is the first description of a well differentiated and benign ovarian teratoma in a fallow deer, which coexisted with a cycling contralateral ovary.

MYCOBACTERIA IN GERMAN ZOOS - IS THERE A RISK OF INFECTION FROM ANIMALS TO HUMANS?

SALCHOW AM^{1,2}, GREENWOOD AD¹, HÖLZLE LE²

¹Leibniz Institute for Zoo and Wildlife Research (IZW), Dept. of Wildlife Diseases, Alfred-Kowalke-Str. 17, 10315 Berlin, GERMANY; annike.salchow@uni-hohenheim.de

²University of Hohenheim, Institute for Environmental and Animal Hygiene, Garbenstr. 30, 70599 Stuttgart, GERMANY

Tuberculosis is one of the most significant zoonoses in the world. Due to the continuous increase of immunocompromised individuals, in particular those with human immunodeficiency virus (HIV) infections, nontuberculous mycobacteria (NTM) have become a major agent of secondary infections. Even though cases of tuberculosis and mycobacteria are continuously reported in zoological gardens throughout the world, only a few comprehensive studies on this particular topic exist in Germany. Therefore, there is a lack of understanding of the source and route of transmission. The aim of this study is to identify the risk of transmission of mycobacteria from zoo animals to humans. Faced with the problem of detecting mycobacteria in living animals without invasive sampling, we focused on the two most important modes of transmission, i.e. aerosol and faeces and screened by PCR. Both aerosol and faeces have been reported to contain mycobacteria in infected animals by many authors. Therefore, we chose swabs soaked with saliva and faeces, respectively as sample types. Samples from six different zoos in Germany were taken. To compensate for intermittent shedding of mycobacteria which would lead to false negative results, it was necessary to test a large number of samples. To complement our screening effort, we included pathologic examinations and tuberculin skin test data to our results where possible. To date, approx. 600 pharyngeal and rectal swabs from mammals and birds were screened for the presence of *Mycobacterium* spp. using real-time PCR. The preliminary results suggest a very low incidence of *Mycobacterium* spp. and that zoo animals may not be a common source of infection for humans.

HELMINTHOFAUNA OF COMMON REPTILES OF ARMENIA

SARGSYAN NI, ARAKELYAN M, DANIELYAN F

Yerevan State University, Faculty of Biology, Dept. of Zoology, Alex Manoogian 1, 0025 Yerevan, ARMENIA; sargsyannelli@rambler.ru, arakelyanmarine@yahoo.com, fel1938@mail.ru

Summary

Twelve species of helminths are registered in helminthofauna of common reptiles in Armenia: *Spauligodon saxicolae* SHARPILO, 1961; *Spauligodon lacerate* SHARPILO, 1966; *Parapharyngodon skrjabini* Vakker, 1969; *Neoxysomatium* sp. Ballesteros Marquez, 1945; *Hexadontophorus ophisauri* Kreis, 1940; *Oswaldokruzia goezei* Skrjabun et Schulz, 1952; *Telorchis assula* Dujardin, 1845; *Nematotaenia tarentolae* Lopez-Neyra, 1944; *Ophiotaenia europea* Odening, 1963; *Mesocestoides lineatus* Goeze, 1782, larvae; *Spirometra erinacei europea*, Rud, 1819, larvae; *Macracanthorhynchus catulinus* Kostilew, 1927, larvae. Research on helminthic infections in various reptiles revealed comparatively high infestation rates of *Pseudopodus apodus*, *Lacerta media*, *Natrix tessellata*, *Macrovipera lebetina* and *Lacerta agilis* and low level of infestation in rock lizards of genus *Darevskia*. Snakes are usually more often infected than lizards due to their diet variety.

Introduction

The research on parasites of wild animals and particularly of reptiles is relatively scarce and fragmented. Compared to helminthological researches of fishes, birds and mammals, only little information is available on the helminth communities of reptiles (AHO et al., 1990). At the same time this knowledge would be important to study the ecology, diet and life cycle of hosts (SILVA et al., 2008). Reptiles are part of different terrestrial and water biocenoses and have an important role in the circulation of helminths as they are definitive, intermediate and/or paratenic hosts. They are also collecting in their organism numerous invasive larvae, which provide single intensive infestation of definitive hosts.

A total of 51 species of reptiles are present in Armenia, 30 of them are endangered (ARAKELYAN, 2012). To not further disturb their population, we chose only common species for our study.

As there are only a few records on parasites of reptiles from Armenia so far (SHARPILO, 1944, 1976; VARDANYAN et al., 2011), the purpose of our study was to examine and summarise helminths from reptile species widely distributed in the territory of Armenia. Thereby we hope to shed light also on the possible infection pressure for endangered reptile species in the same geographical area.

Material and methods

A total of 252 lizards and snakes belonging to 14 species were collected from various regions of Armenia during the years 2009 - 2012 (table 1). Reptiles were transported alive to the laboratory where 217 were euthanised by chloroform, dissected and their internal organs were examined for helminths. The other specimens were examined only externally and helminths were taken from the cloaca. All experiments on reptiles were done in accordance with the standards of the responsible committee on animal research and ethics.

In laboratory conditions the body cavity of each reptile was opened by a longitudinal incision from throat to vent, the gastrointestinal tract was slit longitudinally, and internal organs were removed and examined under the microscope. Helminths found in the gastrointestinal tract, lungs, or body cavity were placed in 70 % ethanol for later identification. For species identification, nematodes were initially placed in glycerin or glycerin-lactic acid mixture (1:1). Cestodes, trematodes and acanthocephales were stained with carmine, washed in water, three times dehydrated by ethanol solutions series (70 %, 80 % and 96 %), put in pink balm for brightening and mounted in balsam.

Morphology of the parasites was examined under a dissection microscope at 40x and 100x magnification. Identification of helminths was carried out according to SHARPILO (1976). Prevalence (number of infected specimens divided by the number of examined specimens, %) and intensity of infection (number of detected helminths divided by the number of infected specimens) as well as abundance (number of detected helminths divided by the number of examined specimens) were calculated.

Results and discussion

In total, 12 species of helminths were recorded: nematodes (*Spauligodon saxicolae* SHARPILO, 1961; *Spauligodon lacerate* SHARPILO, 1966; *Parapharyngodon skrjabini* Vakker, 1969; *Neoxysomatium* sp. Ballesteros Marquez, 1945; *Hexadontophorus ophisauri* Kreis, 1940; *Oswaldokruzia goezei* Skrjabun et Schulz, 1952); trematode (*Telorchis assula* Dujardin, 1845); cestodes (*Nematotaenia tarentolae* Lopez-Neyra, 1944; *Ophiotaenia europea* Odening, 1963; *Mesocestoides lineatus* Goeze, 1782, larvae; *Spirometra erinacei europea*, Rud, 1819, larvae); acanthocephala (*Macracanthorhynchus catulinus* Kostilew, 1927, larvae). Summarised these are six nematode, four cestode, one trematode and one acanthocephala species. Three of the mentioned species whose definitive hosts are dogs, cats and foxes, we found in larval stages. For one of the cestodes, namely *Spirometra erinacei europea*, humans are an intermediate host. The infection is by uptake of with cyclops contaminated water or meat of infected reptiles and amphibians which was not thermal processed. Seven of the mentioned parasite species were for the first time registered as part of the helminthofauna of reptiles of Armenia.

A detailed overview on the infestation of different reptile species by helminths in our study is given in the table 1 and figure 1.

Comparison of the various reptiles showed, that *Pseudopodus apodus* (66.7 %), *Lacerta media* (60 %), *Natrix tessellata* (56.25 %), *Macrovipera lebetina* (33.3 %) and *Lacerta agilis* (33.3 %) are more frequently infected, while rock lizards of genus *Darevskia*: *D. armeniaca* (17.2 %), *D. dahli* (20 %), *D. rostombekovi* (20 %), *D. unisexualis* (14.3 %) are generally less frequently infected.

The fact that snakes were more often infested with helminths than lizards ($F_{1,224} = 2.5$, $P = 0.11$) may be explained by their different diet. In contrast to lizards, snakes have bigger varieties in their diet, as they prey e.g. small mammals, frogs, lizards and birds. Many of these vertebrates are intermediate and paratenic hosts for helminths and can be invasive for definitive host snakes.

The results of our research show that helminth infections in Armenian reptiles are more diverse than so far known and revealed the desirability of further studies, which will complete this picture.

Tab. 1: Infection parameters of helminths parasitising in common reptiles of Armenia.

Reptile species (n=217)	Prevalence of infection, % (n)	Intensity of infection	Abundance	Number of identified helminth species
Suborder Sauria				
<i>Darevskia armeniaca</i> (n = 29)	17.2 (n = 5)	2.6	0.45	2
<i>Darevskia raddei</i> (n = 78)	29.4 (n = 23)	3.7	1.1	1
<i>Darevskia portschinskii</i> (n = 7)	28.5 (n = 2)	1	0.28	1
<i>Darevskia unisexualis</i> (n = 14)	14.3 (n = 2)	3.5	0.5	1
<i>Darevskia dahlia</i> (n = 5)	20 (n = 1)	5	1	1
<i>Darevskia rostombekovi</i> (n = 5)	20 (n = 1)	5	1	1
<i>Darevskia valentini</i> (n = 18)	27.7 (n = 5)	6	1.6	3
<i>Lacerta media</i> (n = 5)	60 (n = 3)	15.6	9.4	2
<i>Lacerta strigata</i> (n = 5)	20 (n = 1)	5	1	1
<i>Lacerta agilis</i> (n = 15)	33.3 (n = 5)	27.2	9	2
<i>Ophisops elegans</i> (n = 7)	28.5 (n = 2)	17.3	7.4	1
<i>Pseudopodus apodus</i> (n = 7)	71.4 (n = 5)	65.5	43.7	3
Suborder Serpentes				
<i>Natrix tessellata</i> (n = 16)	56.25 (n = 9)	10.70	6	3
<i>Macrovipera lebetina</i> (n = 6)	33.3 (n = 2)	11	3.6	2

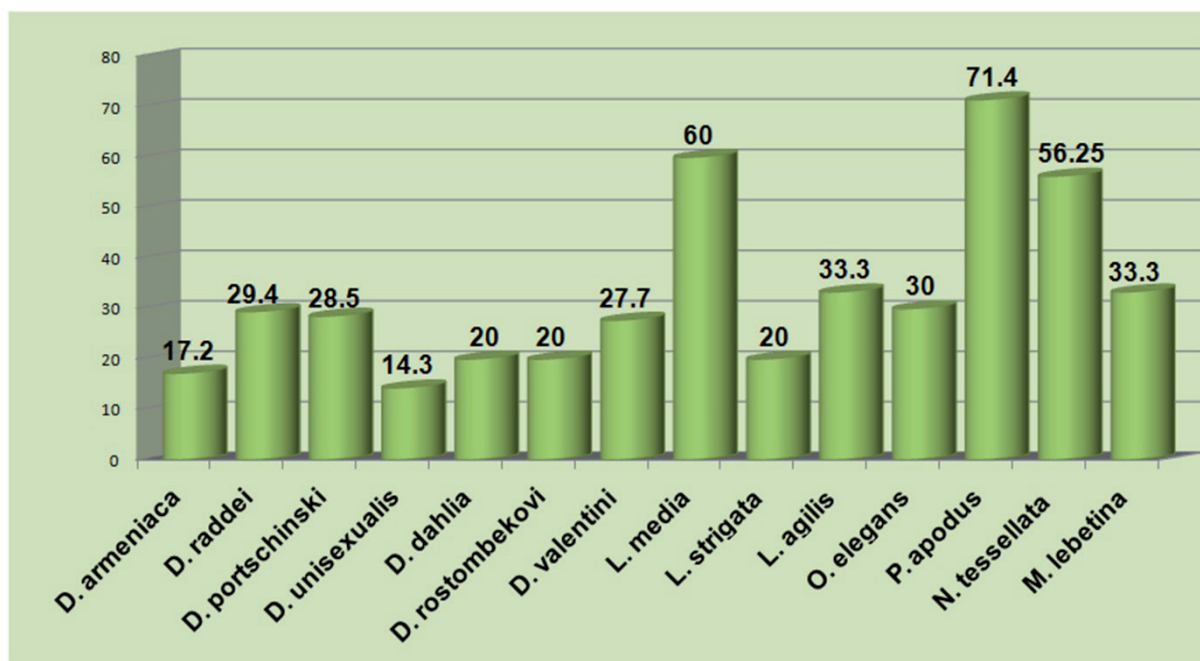


Fig. 1: Prevalence of infection of different reptiles by helminths.

References

- AHO JM, ESCH GW, BUSH AO (1990): *Helminth communities of amphibians and reptiles: Comparative approaches to understanding patterns and processes. Parasite communities: patterns and processes*, 157 - 195.
- ARAKELYAN MS, DANIELYAN FD, CORTI C, SINDACO RA, LEVITON AE (2012): *The Herpetofauna of Armenia and Nagorno-Karabakh*. SSAR, Ithaca, 2011, 154.
- SHARPILO VP (1944): *Nematotaeniatarentolae Lopez-Neyra (Cestoda, Nematotaeniidae), a cyclophyllidean cestode new for the USSR*. *Zbirnik Prats' Zoologichnogo Muzeyu, Akademiya Nauk, Ukrainskogo RSR* 1973, 35, 3 - 5.
- SHARPILO VP (1976): *Parasitic worms of the reptilian fauna of the USSR: Systematic, chorology, biology*. *Naukova Dumka, Moscow, Russia*, 287.
- SILVA AS, ZANETTE RA, TOCHETTO C, OILIVEIRA CB, SOARES JF, OTTO MA, MONTEIRO SG (2008): *Parasitismopor Physaloptera sp., Kalicephalus sp., Cryptosporidium sp. Emlagarto Tupinambisteguixin no Rio Grande do Sul, Brasil*. *Revista Brasileira de Zootecnia* 10, 269 - 272.
- VARTANYAN LK, SARGSYAN NH, ARUTYUNYAN TK (2011): *State of knowledge about parasitofauna of reptiles of Armenia. Materials of international scientific conference "Biological diversity and problems of conservation of fauna of Caucasus"*, Yerevan, 96 - 98.

CORONARY ARTERY LESIONS IN THE SWORDFISH (*XIPHIAS GLADIUS*)

SCAGLIONE FE¹, BOLLO E¹, CHIAPPINO L¹, SERENO A¹, MIGNONE W², MOSCHI R³,
GARIBALDI F⁴, TITTARELLI C², GUARDA F⁵

¹Università degli Studi di Torino, Dipartimento di Scienze Veterinarie, via L. da Vinci 44, 10098 Grugliasco (To), ITALIA; frineeleonora.scaglione@unito.it

²Istituto Zooprofilattico del Piemonte, Liguria e Valle d'Aosta, Sezione di Imperia, via Nizza 4, 18100 Imperia, ITALIA

³ASL 1 imperiese, via Aurelia Ponente 97, 18038 Bussana di Sanremo (Im), ITALIA

⁴Università degli Studi di Genova, Dipartimento di Scienze della Terra, dell'Ambiente e della Vita, Corso Europa 26, 16132 Genova, ITALIA

⁵Centro di Referenza di Patologia Comparata Bruno Maria Zaini, via L. da Vinci 44, 10098 Grugliasco (To), ITALIA

Twelve hearts of swordfish (*Xiphias gladius*) caught in the Ligurian Sea of Italy in 2012 were submitted to gross and histologic investigations. The age of the fish ranged from few months to ten years (average age: six years). Particular attention was paid to the blood vessels, which were stained with Haematoxylin-Eosin, Periodic Acid Schiff and Alcian blu.

At gross examination blood vessels of the atrium, ventriculum and bulb appeared normal, while histopathological evaluation of extramural and intramural coronary arteries showed various lesions.

Both intramural and extramural coronary arteries were affected by intimal proliferations often associated with modifications of the inner elastic fibres. The severity of lesions varied from discrete protrusions to stenosis of the vessels.

Alterations of the inner elastic fibres were the most frequent lesions in the artery of swordfish and showed different degrees of severity, from partial to total thickening of the elastic membrane, duplication and fragmentation, or loss of the elastic membrane.

Lesions of the tunica media were observed only in the extramural arteries, and were represented by proliferation of smooth muscle cells, partial or total loss of elastic fibres, extracellular vacuoles and reduction of smooth muscle cells. In one case an intimal fibrous proliferation and a necrotic area were detected.

No correlation between lesions and their severity, animal age or gender has been observed.

Investigations in comparative pathology of the degenerative alterations of the coronary arteries are important tools to evaluate common factors responsible for the onset of coronary artery lesions in different species.

PATHOLOGY OF FREE-LIVING LOGGERHEAD TURTLE (*CARETTA CARETTA*) EMBRYOS ON THE ISLAND OF LINOSA, ITALY

SCAGLIONE FE¹, LONGATO E¹, PREGEL P¹, PIRIA M², CAPOBIANCO DONDONA A³,
NANNARELLI S⁴, APPINO S², BOLLO E¹

¹Università degli Studi di Torino, Dipartimento di Scienze Veterinarie, via L. da Vinci 44, 10098 Grugliasco (To), ITALIA; frineeleonora.scaglione@unito.it

²Università degli Studi di Sassari, Dipartimento di Medicina Veterinaria, via Vienna 2, 07100 Sassari, ITALIA

³Istituto Zooprofilattico Sperimentale dell'Abruzzo e del Molise "G. Caporale", via Campo Boario 0, 64100 Teramo, ITALIA

⁴Centro Recupero Tartarughe Marine - Hydrosphera, Via Pozzolana di Ponente 13, 92010 Linosa (AG), ITALIA

In summer 2006 on Linosa Island beach (Italy) five loggerhead sea turtles (*Caretta caretta*) nests were monitored during nesting period. At the end of incubation period, eggs were manually recovered from nests and opened. Forty-seven dead sea turtles were found, formalin fixed and sent to the Department of Veterinary Sciences of the University of Turin (Italy). Necropsies were performed, and tissue samples were stained with Haematoxylin-Eosin (HE), Grocott, von Kossa and PAS. Histologically, vacuolar degeneration associated with a non-suppurative inflammatory infiltrates (27.6 %) and increased numbers of melanomacrophages (19.1 %) in the liver, as well as non-suppurative inflammation (8 cases, 17.0 %) in the lungs were observed. Twenty-six kidneys (59 %) showed deposition of blue amorphous glomerular and tubular material with HE staining that also appeared PAS-positive and black with von Kossa staining, allowing a diagnosis of calcium oxalate causing partial or total obstruction and degeneration of the glomerular and tubular cells. Lesions were classified as follows:

Stage 1: tubular/glomerular involvement < 50 %

Stage 2: tubular/glomerular involvement > 50 %

Eight cases out of 26 (30.7 %) were graded stage 1, and 18 cases stage 2 (69.3 %). The increase in melanomacrophages in the liver may be indicative of toxicosis, infectious agents, or a defense mechanism. A statistically significant association between the nest position and the presence of calculosis was observed.

While the temperature of the sand was constantly monitored during egg deposition and hatching, it is likely that the vacuolar degeneration in the liver may be caused by toxicosis or infectious pathogens, and that renal calculosis was probably due to the exceptionally high summer temperatures which tested statistically different compared to the temperatures recorded in the previous and past two years.

LETHAL HERPESVIRUS SIMPLEX INFECTION IN TWO COMMON MARMOSETS (*CALLITHRIX JACCHUS*)

SCHMITT A¹, LAMPE K¹, BAYRHOF G², GRUBER-DUJARDIN E¹, MÄTZ-RENSING K, KAUP F-J¹, BLEYER M¹

¹German Primate Center, Pathology Unit, Kellnerweg 4, 37077 Göttingen, GERMANY; aschmitt@dpz.eu

²Veterinary Group Practice, Bahnhofstraße 12, 86983 Lechbruck am See, GERMANY

Human herpesvirus 1 (HHV1) infections of the natural host (human primates) or closely related apes (gibbon, orang-utan) are asymptomatic or associated with mild vesicular oral lesions (EMMONS and LENETTE, 1970; KIK et al., 2005). Conversely, infection of New World monkeys often results in lethal disseminated disease (HUEMER et al., 2002; MÄTZ-RENSING et al., 2003; SCHRENZEL et al., 2003). In the present case, two juvenile common marmosets (*Callithrix jacchus*) from a private owner were presented to the veterinarian because of depression, fever, and skin lesions. Both animals did not respond to antibiotic and analgesic treatment and developed severe neurological signs before they died within few days after disease onset. During necropsy, both monkeys revealed multifocal ulcerations of the facial skin and tongue. Histologically, this was characterised by multifocal severe, acute ulcerative dermatitis and glossitis. In addition, the monkeys showed severe multifocal to coalescing lymphocytic and partly suppurative meningoencephalitis. Distinct intralésional viral inclusions could not be detected by routine histology but immunohistochemical staining with antibodies against HHV1 clearly demonstrated HHV1-antigen within all lesions (skin, tongue and central nervous system), particularly in degenerate keratinocytes and central neurons.

As described before, common marmosets represent a highly susceptible species to HHV1 (MÄTZ-RENSING et al., 2003). In our case the owner of the monkeys was known to be latently infected with HHV1, although no acute vesicular lesions were present at the time of disease outbreak in the monkeys. However, an anthrozoönotic route of infection is most likely. In summary, HHV1 infection has to be considered as a differential diagnosis in case of ulcerative changes of skin and mucosa together with fatal disease in New World monkey species.

References

- EMMONS RW, LENETTE EH (1970): *Natural Herpesvirus hominis infection of a gibbon (Hylobates lar.)* Arch. Gesamte Virusforsch. **31**, 215 - 218.
- HUEMER HP, LARCHER C, CZEDIK-EYSENBERG T, NOWOTNY N, REIFINGER M (2002): *Fatal infection of a pet monkey with Human Herpesvirus.* Emerg. Infect. Dis. **8**, 639 - 642.
- KIK M, BOS JH, GROEN J, DORRESTEIN GM (2005): *Herpes simplex infection in a juvenile orang-utan (Pongo pygmaeus pygmaeus).* J. Zoo Wildl. Med. **36**, 131 - 134.
- MÄTZ-RENSING K, JENTSCH KD, RENSING S, LANGENHUYSEN S, VERSCHOOR E, NIPHUIS H, KAUP FJ (2003): *Fatal Herpes simplex infection in a group of common marmosets (Callithrix jacchus).* Vet Pathol. **4**, 405 - 411.
- SCHRENZEL MD, OSBORN KG, SHIMA A, KLIEFORTH RB, MAALOUF GA (2003): *Naturally occurring fatal herpes simplex virus 1 infection in a family of white-faced saki monkeys (Pithecia pithecia).* J. Med. Primatol. **32**, 7 - 14.

TOXOPLASMA GONDII IN ZOO ANIMALS

SLEZAKOVÁ R¹, BARTOVA E¹, VODIČKA R², SEDLAK K³

¹University of Veterinary and Pharmaceutical Sciences, Faculty of Veterinary Hygiene and Ecology, Dept. of Biology and Wildlife Diseases, Palackeho tř. 1/3, 612 42 Brno, CZECH REPUBLIC; H13391@vfu.cz

²Zoological Garden in Prague, U Trojského zámku 3/120, 171 00 Prague, CZECH REPUBLIC

³State Veterinary Institute Prague, Dept. of Virology and Serology, Sídlíštní 136/24, 165 03 Prague 6, CZECH REPUBLIC

Summary

There are many reports on toxoplasmosis in zoo animals. In the Czech Republic, fatal toxoplasmosis was recorded in Saiga and Nilgais antelope and also in manuls. Several groups of zoo animals were tested for *T. gondii* antibodies during years 1995 and 2005 by indirect fluorescence antibody test (IFAT). However there are some other animal groups that have not been tested yet or method of IFAT was not suitable. Sera of 747 animals, including 59 birds and 688 mammals, from eight Czech and Slovakian zoos were tested for antibodies to *Toxoplasma gondii* by latex agglutination test. *T. gondii* antibodies were detected in 33.5 % (250/747) of the animals, concretely in 8.5 % (5/59) of the birds and 35.6 % (245/688) of the mammals. In case of birds, *T. gondii* antibodies were detected in birds belonging to the anseriformes, falconiformes and psitaciformes. In case of mammals, *T. gondii* antibodies were found in animals from the following orders: 59.3 % (54/91) carnivores, 35.3 % (6/17) proboscidea, 34.7 % (34/98) perissodactyla, 33.6 % (143/426) artiodactyla, 10.5 % (2/19) primates, 7.7 % (2/26) rodentia and in two animals of marsupialia and two of tubulidentata. *T. gondii* antibodies were not detected in insectivora, chiroptera and xenarthra. There were also differences in individual families: 63.5 % in felidae, 62.5 % in canidae and 14.3 % in other carnivores, 55.6 % in elephantidae and 12.5 % in other proboscidae, 37.5 % in equidae and 22.2 % in rhinocerotidae, 61.1 % in cervidae, 50 % in camelidae, 30 % in giraffidae, 29.1 % in bovidae and 12.5 % in suidae.

Introduction

Toxoplasma gondii is one of the most well studied parasites because of its medical and veterinary importance. *T. gondii* is a coccidian parasite with cats and other felids as the definitive host, and warm-blooded animals as intermediate hosts. Only cats and other felids may shed oocyst, which are essential in the life cycle of *T. gondii*. Natural infection is acquired by ingestion of oocyst from food and water contaminated with cat faeces or by ingestion of tissue cysts in meat of infected animals. *T. gondii* infection is usually asymptomatic, but it can lead to severe clinical manifestation in sensitive animals (DUBEY, 2010).

There are many reports on toxoplasmosis in zoo and captive animals. Clinical cases of toxoplasmosis (encephalomyelitis) were recorded for example in a captive fossa (*Cryptoprocta ferox*) from a Spanish zoo (CORPA et al., 2013), in Tamar wallabies (*Macropus eugenii*) in the Budapest Zoo and Botanical Garden (SÓS et al., 2012), or in Eastern grey kangaroos (*Macropus giganteus*) in Mexico (CRUZ-HERNANDEZ et al., 2012). In the Czech Republic, the clinical manifestation of *T. gondii* infection was found in zoo kept Nilgais (*Boselaphus tragocamelus*) and Saiga antelopes (*Saiga tatarica*) (SEDLÁK et al., 2004). LUKEŠOVÁ AND LITERÁK (1997) monitored shedding of *T. gondii* oocysts in the faeces of felidae in six zoos in the Czech Republic.

It is important to know prevalence of *T. gondii* in different groups of zoo animals to know which of them are more or less sensitive to *T. gondii* infection, and thus to know if there is lower or higher risk of possible infection from mother to offspring during transplacental infection. There can be problems with abortions, mild or more complicated clinical symptoms that could be even fatal for the animals. In case of felids positive to *T. gondii* infection, there is a risk of shedding *T. gondii* oocysts and contamination of zoo environment. There are differences in susceptibility to *T. gondii* infection among species. Antibodies to *T. gondii* were found for example in 63.4 % (102 of 161) wild felids and in 50.5 % (49 of 97) wild canids from the zoos in Brazil (ANDRE et al., 2010), and in 53.3 % (89 of 167) exotic mammals from zoos in Mexico (ALVARADO-ESQUIVEL et al., 2013). There is also one study from the Czech Republic (SEDLÁK and BÁRTOVÁ, 2006). Sera of zoo animals (556 animals of 114 species) were collected during years 1995 – 2005 and *T. gondii* antibodies were detected by indirect immunofluorescence (IFAT) in 193 (34.7 %) animals. The highest prevalence 100 % was found in families: Hyaenidae, Mustelidae, Ursidae and Viveridae of the order Carnivora.

The aim of this study was to determine the prevalence of antibodies to *T. gondii* in groups of zoo animals from the Czech and Slovakian zoos that were not included in previous study.

Material and methods

Sera of 747 clinically healthy animals (59 birds and 688 mammals) were collected in eight Czech and Slovakian zoos. The sera were centrifuged and frozen at -20°C until they were examined. The serum samples were tested for antibodies against *T. gondii* by latex agglutination test (LAT, Pastorex toxo, Bio-Rad Laboratories s .r.o., CR). According to the instructions, the specificity and sensitivity of LAT is 100 % and 94.3 %, however species-related difference could have been observed due to species-specific differences in sensitivity and specificity.

Results and discussion

Antibodies against *T. gondii* were detected in 33.5 % (250 of 747) of all tested animals. In case of birds, it was 8.5 % (5/59) with 20 % prevalence in psittaciformes. *T. gondii* antibodies were detected also in anseriformes (2/4) and falconiformes (2/4); other tested birds of eight orders were negative for *T. gondii* antibodies (table 1).

Tab.1: Prevalence of *T. gondii* antibodies in birds from zoo.

Order/family	Positive/n (%)	<i>T. gondii</i> positive species
Anseriformes	2/4 (50 %)	Paradise shelduck (<i>Tadorna variegata</i>), coscoroba swan (<i>Coscoroba coscoroba</i>)
Falconiformes	2/4 (50 %)	Steppe eagle (<i>Aquila nipalensis</i>), bald eagle (<i>Haliaeetus leucocephalus</i>)
Psittaciformes	1/5 (20 %)	Rainbow lorikeet (<i>Trichoglossus haematodus</i>)
Birds of other 8 orders	0/46 (0 %)	
Total	5/59 (8.5 %)	

Seroprevalence of *T. gondii* among all mammal species was 35.6 % (245 of 688). *T. gondii* antibodies were detected in mammals from the following orders: Carnivora in 59.3 % (54/91), Proboscidea in

55.6 % (5/9), Artiodactyla in 33.6 % (143/426), Perissodactyla in 34.7 % (34/98), Hyracoidea in 12.5 % (1/8), Primates in 10.5 % (2/19), Rodentia in 7.7 % (2/26) and in two animals of Tubelidentata and two of Diprotodontia. *T. gondii* antibodies were not detected in Eulipotyphla, Chiroptera and Xenarthra. There were differences in individual families. Antibodies to *T. gondii* were found in 63.5 % in felidae, 62.5 % in canidae and 14.3 % in other carnivores, 55.6 % in elephantidae and 12.5 % in other proboscidae, 37.5 % in equidae and 22.2% in rhinocerotidae, 61.1 % in cervidae, 50 % in camelidae, 30 % in giraffidae, 29.1 % in bovidae and 12.5 % in suidae. The results are summarised in table 2.

Differences in the seroprevalence of *T. gondii* among species or higher zoological taxons could be explained by different sensitivity, different lifestyles (carnivorous, herbivorous) and by possibility to be in contact with the sources of *T. gondii* infection. We found the highest prevalence (59.3 %) in Carnivora since their representatives (Felidae) could be definitive host of *T. gondii* infection. The most common way of infection for carnivores is consumption of meat contaminated with *T. gondii* tissue cysts. Relative high prevalence was found in animals of orders Proboscidea (55.6 %), Artiodactyla (33.6 %) and Perissodactyla (34.7 %), Herbivores could be infected especially by drinking water and feeding grass contaminated with *T. gondii* oocysts. In some groups of animals, transplacental transmission of *T. gondii* infection is also very important.

Tab. 2: Prevalence of *T. gondii* antibodies in mammals from zoo.

Order	Family	Positive/total (%)	<i>T. gondii</i> positive species
Carnivora	Felidae	33/52 (63.5 %)	Tiger (<i>Panthera tigris</i>), lion (<i>P. leo</i>), leopard (<i>P. pardus</i>), ocelot (<i>Leopardus pardalis</i>)
	Canidae	20/32 (62.5 %)	Gray wolf (<i>Canis lupus lupus</i>), fennec (<i>Vulpes zerda</i>), maned wolf (<i>Chrysocyon brachyurus</i>)
	other families	1/7 (14.3 %)	Red panda (<i>Ailurus fulgens</i>)
Artiodactyla	Cervidae	33/54 (61.1 %)	Moose (<i>Alces alces</i>), milu (<i>Elaphurus davidianus</i>), wapity (<i>Cervus elaphus</i>)....
	Camelidae	9/18 (50 %)	Bactran camel (<i>Camelus ferus</i>), alpaca (<i>Lama guanicoe f. pacos</i>)
	Giraffidae	3/10 (30 %)	Giraffe (<i>Giraffa camelopardalis</i>)
	Bovidae	97/333 (29.1 %)	West Caucasian tur (<i>Capra caucasica</i>), Himalayan tahr (<i>Hemitragus jemlahicus</i>), American bison (<i>Bison bison</i>), sitatunga (<i>Tragelaphus spekei</i>), sable antelope (<i>Hippotragus niger</i>)
	Suidae	1/8 (12.5 %)	Eurasian wild boar (<i>Sus scrofa</i>)
	Hippopotamidae	0/2	
	Tragulidae	0/1	
Proboscidea	Elephantidae	5/9 (55.6 %)	African elephant (<i>Elephas africanus</i>), Indian elephant (<i>E. maximus</i>)
Perissodactyla	Equidae	30/80 (37.5 %)	Kiang (<i>Equus kiang</i>), Asian wild ass (<i>Equus hemionus</i>), Przewalski's horse (<i>Equus przewalskii</i>), zebra
	Rhinocerotidae	4/18 (22.2 %)	Indian rhinoceros (<i>Rhinoceros unicornis</i>), white rhinoceros (<i>Ceratotherium simium</i>)
Hyracoidea	Procaviidae	1/8 (12.5 %)	Rock hyrax (<i>Procavia capensis</i>)

Continuation tab. 2

Order	Family	Positive/total (%)	<i>T. gondii</i> positive species
Primates		2/19 (10.5 %)	Orangutan (<i>Pongo abelii</i>)
Rodentia		2/26 (7.7 %)	South African springhare (<i>Pedetes capensis</i>), Patagonian mara (<i>Dolichotis patagonum</i>)
Tubulidentata	Orycteropidae	2/4	Aardvark (<i>Orycteropus afer</i>)
Diprotodontia	Diprotodontia	2/2	Red kangaroo (<i>Macropus rufus</i>), red-necked wallaby (<i>Macropus rufogriseus</i>)
Eulipotyphla		0/2	
Chiroptera		0/1	
Xenarthra	Myrmecophagidae	0/2	
Total		245/688 (35.6 %)	

Antibodies against *T. gondii* were detected in different groups of zoo animals. The results of this study indicate that *T. gondii* is fairly common in zoo animals in the Czech Republic and Slovakia. Based on these results, we can recommend some prevention rules such as to ensure frequent cleaning of felids' cages and to remove their faeces, to prevent contact of zoo animals with wild birds and rodents that could transfer *T. gondii* infection. From the infection side of view it would be best not to feed raw meat to the carnivores, which of course is hard to realise. It is highly suggested to continue with prevalence studies to know actual situation, to monitor possible shedding oocysts by felids and also to isolate DNA of *T. gondii* from tissues of animals with clinical symptoms or in fatal cases for genotyping *T. gondii* strains. Based on genotypes, we can compare these strains with genotypes isolated from domestic or wild animals, from animals of different zoos or different countries and it could help us to find the source of infection and explain possible ways of its transfer.

Acknowledgements

This study was funded by the grant no. MSM6215712402 from the Ministry of Education, Youth and Sports of the Czech Republic.

References

- ALVARADO-ESQUIVEL C, GAYOSSO-DOMINGUEZ EA, VILLENA I, DUBEY JP (2013): Seroprevalence of *Toxoplasma gondii* infection in captive mammals in three zoos in Mexico city, Mexico. *J. Zoo Wildlife Med.* **44**, 803 - 806.
- ANDRÉ MR, ADANIA CH, TEIXEIRA RHF, SILVA KF, JUSI MMG, MACHADO STZ, DE BORTOLLI CP, FALCADE M, SOUSA L, ALEGRETTI SM, FELIPPE PAN, MACHADO RZ (2010): Antibodies to *Toxoplasma gondii* and *Neospora caninum* in captive neotropical and exotic wild canids and felids. *J. Parasitol.* **96**, 1007 - 1009.
- CORPA JM, GARCIA-QUIRÓS A, CASARES M, GERIQUE AC, CARBONELL MD, GÓMEZ-MUNOZ MT, UZAL FA, ORTEGA J (2013): Encephalomyelitis by *Toxoplasma gondii* in a captive fossa (*Cryptoprocta ferox*). *Vet. Parasitol.* **193**, 281 - 283.

-
- CRUZ-HERNANDEZ NI, CARVAJAL-DE LA FUENTE V, FLORES-GUTIERREZ GH (2012): Toxoplasmosis in captive Eastern grey Kangaroos (*Macropus giganteus*). *J. Anim. Vet. Advanced.* **11**, 1780 - 1783.
- DUBEY JP (2010): *Toxoplasmosis of animals and humans, second edition*. CRC Press, Taylor and Francis Group, Boca Raton, Florida, 5 - 66.
- LUKESOVA D, LITERAK I (1997): Shedding of *Toxoplasma gondii* oocysts by felidae in zoos in the Czech Republic. *Vet. Parasitol.* **74**, 1 - 7.
- SEDLÁK K, BÁRTOVÁ E (2006): Seroprevalences of antibodies to *Neospora caninum* and *Toxoplasma gondii* in zoo animals. *Vet. Parasitol.* **136**, 223 - 231.
- SEDLÁK K, BÁRTOVÁ E, LITERÁK I, VODIČKA R, DUBEY JP (2004): Toxoplasmosis in Nilgais (*Boselaphus tragocamelus*) and Saiga antelope (*Saiga tatarica*). *J. Zoo Wildlife Med.* **35**, 530 - 533.
- SÓS E, SZIGETI A, FOK E, MOLNÁR V, ERDELYI K, PERGE E, BIKSI I, GÁL J (2012): Toxoplasmosis in Tammar wallabies (*Macropus eugenii*) in the Budapest Zoo and Botanical Garden. *Acta Vet. Hung.* **60**, 361 - 370.

EVALUATION OF ARABIAN UNGULATE PATHOLOGY AT THE BREEDING CENTRE FOR ENDANGERED ARABIAN WILDLIFE, SHARJAH, UNITED ARAB EMIRATES

SOILEMETZIDOU S¹, BUDD J¹, DORRESTEIN G², WHITEHOUSE-TEDD K¹

¹Breeding Centre for Endangered Arabian Wildlife (BCEAW), P.O.Box 29922, Sharjah, UNITED ARAB EMIRATES; ssanatana@hotmail.com

²Pathology Laboratory NOIVBD, Wintelresedijk 51, 5507PP Veldhoven, THE NETHERLANDS

The Breeding Centre for Endangered Arabian Wildlife focuses on the captive breeding of endangered species, with the ultimate aim of contributing to reintroduction projects and participating in international or regional breeding programmes. A large proportion of the centre's inventory is comprised of endemic ungulate species, including some classified by the IUCN as Endangered (Arabian tahr, *Arabitragus jayakari*) and Vulnerable (Arabian oryx, *Oryx leucoryx*; Nubian ibex, *Capra nubiana*; Arabian mountain gazelle, *Gazella g. cora*; Arabian sand gazelle, *G. subgutturosa marica*) and, as such, the breeding of this captive population has important conservation implications. An important element of the veterinary care and management of the hoofstock at the centre is its preventative medicine programme, which requires an understanding of the types of disease processes that pose a risk to the collection. Therefore, a review of historical pathological findings was conducted to evaluate the incidence of infectious and non-infectious disease as well as other causes of mortality.

Post mortem records have been kept by the veterinary department for the past 14 years, and included 531 ungulate pathology records for the five ungulate species of interest. Two hundred and three cases of Arabian mountain gazelle (101 females, 70 males, 32 unrecorded), 63 cases of Arabian oryx (33 males, 28 females, 2 unrecorded), 98 cases of Nubian ibex (50 males, 42 females, 6 unrecorded), 158 reports on sand gazelles (60 males, 81 females, 17 unrecorded sex), and 9 cases of Arabian tahr (7 males, 2 females) were evaluated. Pathology data were categorised according to presentation at *post mortem* (found dead, stillborn, died under treatment, or euthanised) and pathological findings (cause of death and secondary disease processes). Animals that were culled for management purposes were excluded from the analysis.

The majority of Arabian gazelle deaths were due to trauma (29 %), followed by bacterial infection (26 %), non-bacterial pathology (13 %), starvation (5 %) and premature or still birth (3 %). However, a large number of cases were of unknown causes (25 %). One quarter of Arabian oryx were determined to have died due to trauma, while 21 % died from bacterial infections. The remaining deaths in this species were due to non-bacterial pathology (16 %), starvation (13 %), and premature or still birth (2 %), although 24 % of cases were of undetermined cause. The majority of deaths in Nubian ibex were due to bacterial infection (30 %), followed by trauma (19 %), premature or still births (12 %), non-bacterial pathology (6 %), and starvation (5 %). No pregnancy-related deaths were recorded but 28 % of *post mortems* failed to determine cause of death. Sand gazelle deaths were predominantly due to bacterial infections (29 %) and trauma (24 %), with 10 % of deaths due to starvation, and 9 % due to premature or still birth, 9 % due to non-bacterial pathology, 4 % due to pregnancy-related pathology, and 15 % of unknown causes. Arabian tahr deaths were predominantly due to non-bacterial pathology (44 %), with fewer cases of trauma (11 %) and bacterial infection (11 %), however a third (33 %) of cases were of unknown cause and the sample size was small for this species.

Inter-specific differences in prevalence of each type of pathological finding are explored and the findings of this research used to inform current veterinary management strategies for these species in captivity. Additionally, these findings will assist in guiding veterinary surveillance and prophylactic treatments, where feasible.

MULTIPLE MYCOBACTERIAL INFECTIONS IN A ZOO AQUARIUM

TAHAS S¹, TIMOFTE D², CHANTREY J², LOPEZ J³

¹University of Nottingham, School of Veterinary Medicine and Science, Pride Veterinary Centre, Derby, DE24 8HX, UK; svxst@nottingham.ac.uk

²University of Liverpool, School of Veterinary Science, Leahurst Campus, Neston, Wirral, CH64 2TE, UK

³Chester Zoo, Conservation Medicine Dept., Caughall Road, Upton by Chester, Chester, CH2 1LH, UK

Piscine mycobacteriosis ("wasting disease") is a common cause of morbidity and mortality for ornamental fish. The chronic nature of the disease is a particular problem for zoos due to the persistence of infection in their collection. However, the presence and distribution of *Mycobacterium* spp. infections in zoo aquaria is poorly documented. Following historical evidence of fish deaths due to wasting disease at a major Zoo Aquarium in the North West of England, a pilot study was undertaken to determine the extent of infection and species involved. Over an 8 month period, tissues of formalin-stored, fresh and autolysed marine and freshwater fish were analysed by histopathology, PCR and ZN direct impression smears. Eighty-seven fish from 35 different species were included in the study. Sixty-eight percent of individual fish and 91 % of species tested positive for the disease by any method used. Based on sequencing results of the 16S rRNA gene, preliminary results suggests the existence of at least four different species of mycobacteria present in the collection. The continual importation of new fish populations is assumed to have played a major role in the multiple and complex nature of mycobacterial infection of the zoo aquarium. Continued surveillance for this disease will contribute to a more accurate picture of mycobacterial epidemiology within zoological collections, especially for tanks and fish species not represented in this study. Preliminary results also suggest that this study is likely to report the first identification of *Mycobacterium stomatepiae* in a killiefish (*Pachypanchax sakaramyi*) and ricefish (*Oryzias sarasinorum*).

MULTIDRUG RESISTANT ENTEROBACTERIACEAE IN IMPORTED REPTILES

UNGER F¹, EISENBERG T², PRENGER-BERNINGHOFF E¹, LUDWIG M-L³, ROTHE M³,
EWERS C¹

¹Justus-Liebig-University Giessen, Institute of Hygiene and Infectious Diseases of Animals, Frankfurter Str. 85 - 89, 35392 Giessen, GERMANY; franziska.unger@vetmed.uni-giessen.de

²Hessian State Laboratory, Dept. Veterinary Medicine, Schubertstr. 60, House 13, 35392 Giessen, GERMANY

³Hessian State Laboratory, Border Inspection Post Frankfurt Airport, CCN Building 463, 60549 Frankfurt/Main, GERMANY

The global emergence of Enterobacteriaceae producing extended-spectrum β -lactamases (ESBLs) and AmpC- β -lactamases is a major concern in human and veterinary medicine, as infections due to these multidrug-resistant bacteria often leave only limited therapeutic options. To which extent reptiles are affected from infections with such bacteria or maybe involved in their spread, i.e. due to asymptomatic colonisation and transient shedding, is currently unknown.

Therefore, we took faecal samples during routine border controls at the Frankfurt Airport, where more than 670,000 reptiles that are imported yearly into the EU, are routinely assessed by veterinarians. Standard laboratory methods were applied for sample cultivation, and species differentiation was performed by Maldi-TOF analysis. So far, 90 samples from various reptile species and countries have been collected and 23 ESBL- and 19 putative AmpC-producing species, including *Escherichia coli*, *Klebsiella pneumoniae*, and *Enterobacter cloacae*, were identified by combination disc test. High MIC-values suggested the presence of additional resistances against non-beta-lactams, e.g. enrofloxacin. By PCR and sequence analyses various β -lactamase-genes, including *bla*_{CTX-M-15}, *bla*_{SHV-12} and *bla*_{CMY-2}, were detected. Multilocus sequence types (STs) differed among isolates but STs frequently appearing in human isolates, such as the highly virulent CTX-M-ST131 *E. coli* clone in an agama from Vietnam, were also present.

Our data show that reptiles frequently carry multidrug-resistant bacteria and that their transport may contribute to bacterial dissemination across borders. The finding of shared STs with human strains might support previous findings of infections in reptiles with human-like pathogens. Most importantly, the finding of an intestinal source of multidrug-resistant bacteria in our study suggests that reptiles might likely develop therapy-resistant infections, as these are often endogenous in nature.

A SURVEY ON *FRANCISELLA TULARENSIS* IN SONDRIO PROVINCE AFTER IMPORTATION OF INFECTED HARES

VICARI N¹, BIANCHI A², MANFREDINI A¹, GIACOMELLI S², GENCHI M¹,
BERTOLETTI I², FABBI M¹

¹Istituto Zooprofilattico Sperimentale della Lombardia e dell'Emilia Romagna, Sezione di Pavia, National Reference Laboratory for Tularaemia, Strada Campeggi 59/61 27100 Pavia, ITALY; nadia.vicari@izsler.it

²Istituto Zooprofilattico Sperimentale della Lombardia e dell'Emilia Romagna, Sezione di Sondrio, Via Bormio 30, 2230 Sondrio, ITALY

Tularemia is a rare zoonotic disease caused by *Francisella tularensis*. This bacterium has been recovered from numerous animal species and can be transmitted to humans through different routes of infections. In Europe, only *F. tularensis* subsp. *holarctica* (type B) was reported. In Italy, most human infections are caused by ingestion of contaminated drinking water and more rarely after contacts with infected animals such as hares or arthropod bites. In Italy, infected hares are found in different regions in particular in Northern and Central Italy representing a potential risk for exposed humans such as hunters. In Sondrio Province (Italian Alps), the emergence of tularemia started in 2005 due to imported infected European brown hares (*Lepus europaeus*). Since that year, a survey on susceptible species (lagomorphs, ungulates, foxes and arthropods) was carried out in the area. We report the results of the survey. Over the past decade a total of 803 samples collected from mammals (n = 747) and ticks (n = 56) have been tested (535 by PCR and 273 by serum agglutination). No positive results were found except for two ticks (*Ixodes ricinus*) collected in spring 2013 from the carcass of a dead roe deer. The ticks were found *F. tularensis* (type B) positive by PCR. The genotyping performed by MLVA analyses shows a genotype typical for Eastern Europe. These preliminary results suggest to continue in monitoring the spread of *F. tularensis* in Sondrio Province focusing the investigation on arthropod-vectors rather than on susceptible animals to clarify if this genotype has been settled in the area.

NEONATAL MORTALITY IN CAPTIVE CHEETAHS (*ACINONYX JUBATUS*) AT THE ANN VAN DYK CHEETAH RESEARCH CENTRE, SOUTH AFRICA

VYBIRAL P-R¹, GERMITSCH N¹, CODRON D^{1,2}, CLAUSS M¹, KOTZE A³, LANE EP³

¹University of Zurich, Vetsuisse Faculty, Clinic for Zoo Animals, Exotic Pets and Wildlife, Winterthurerstrasse 260, 8057 Zurich, SWITZERLAND; mclauss@vetclinics.uzh.ch

²Florisbad Quaternary Research, National Museum, PO Box 266, Bloemfontein 9300, SOUTH AFRICA

³National Zoological Gardens of South Africa, 232 Boom St, Pretoria, SOUTH AFRICA

Cheetahs (*Acinonyx jubatus*) are notoriously difficult to breed successfully in captivity. The majority of mortalities occur when cheetahs are below one month of age. Identifying causes of neonate mortality could possibly contribute to improving the husbandry of this species. We analysed necropsy reports and stocklist data of the Ann van Dyk Cheetah Centre between 1975 and 2012 for causes of neonatal (< 30 days) mortality. Neonate mortality appeared to decrease over time, but the effect was only significant if the first two years after centre opened were included. The category 'mismothering' as cause of death decreased over time, suggesting that management changes made mothers feel more comfortable with raising young. The major finding of this study was that, across years, there were significant correlations between the age of the dam at the time of giving birth and the mean number of cubs per litter (decreased with age of dam) and with neonate mortality (increased with age of dam), leading to a pattern where a lower number of cubs born per litter was correlated to a higher neonate mortality. Most importantly, although dams had a lower neonate mortality in their second than their first litter, as might be explained by a gain in experience, neonate mortality increased constantly with each subsequent litter, with more experienced dams losing higher proportions of their cubs. The results suggest that cheetahs in this setting should be bred early on, and that husbandry efforts should aim at preventing accumulating health problems over time in breeding females that could be linked to increased newborn losses.

This study was part of the Zoo Research Camp (ZRC) 2013 organised by the National Zoological Gardens of South Africa and the Vetsuisse Faculty, University of Zurich, Switzerland.

PREVALENCE OF *SALMONELLA* SEROVARS IN GAME ANIMALS FROM POLAND

WASYL D¹, HOSZOWSKI A¹, ZAJĄC M¹, JABŁOŃSKI A², SKARŻYŃSKA M¹, SAMCIK I¹,
LALAK A, SZULOWSKI K¹

¹National Veterinary Research Institute, Dept. of Microbiology, Partyzantów 57, 24-100 Puławy, POLAND; wasyld@piwet.pulawy.pl

²National Veterinary Research Institute, Dept. of Swine Diseases, Partyzantów 57, 24-100 Puławy, POLAND

Since wildlife is considered a reservoir of *Salmonella* spp. the current survey aimed at assessment of its carriage in game animals (n = 660). Standardised detection method (ISO 6579:2002) was used to test faeces collected from hunted red deer (*Cervus elaphus*, n = 225), roe deer (*Capreolus capreolus*, n = 76), fallow deer (*Dama dama*, n = 24), European bison (*Bison bonasus*, n = 3, sanitary shot), and wild boar (*Sus scrofa*, n = 332). The samples were collected during 46 hunting events within two seasons (2012/2013, n = 7 and 2013/2014, n = 39) in 37 regional forests scattered over the whole territory of Poland. No *Salmonella* was found in wild ruminants. However, 20 wild boars (6.0 %; CI95 % 3.46 % ÷ 8.58 %) carried *Salmonella*. *S. Choleraesuis* var. Kunzendorf (n = 7) was identified in samples originated from North-western Poland and from three hunts (November 2012, December 2013, January 2014). *S. Enteritidis* (n = 3) and *S. Abony* (n = 3) were observed in western part of the country, each serovar in samples from two hunts in autumn 2013. *S. Typhimurium* (n = 3) was noted in animals originated from diverse regions over the whole study period. Similar time and space distribution was observed in the single isolates of *S. Thompson* and *S. Tripoli* and autoagglutinating isolates (n = 2). The results confirm the role of wild boars in *Salmonella* epidemiology. It might be considered a reservoir of swine-specific *S. Choleraesuis* var. Kunzendorf and few rare serovars. Surprisingly, finding of serovars common in farm animals (*S. Enteritidis*, *S. Typhimurium*) indicates the possible role of wild boars in infection cycle that needs further epidemiological studies focused on comparison of isolates from wildlife with those from farm animals.

INTESTINAL DISPLACEMENTS IN PHOCIDS FROM GERMAN WATERS

WEHRMEISTER E¹, WOHLSEIN P², PRENGER-BERNINGHOFF E³, SIEBERT U¹

¹University of Veterinary Medicine Hannover, Foundation, Institute of Terrestrial and Aquatic Wildlife Research (ITAW), Werftstraße 6, 25761 Büsum, GERMANY; eva.wehrmeister@tiho-hannover.de

²University of Veterinary Medicine Hannover, Foundation, Dept. of Pathology, Bünteweg 17, 30559 Hannover, GERMANY

³Justus-Liebig-University Gießen, Institute of Hygiene and Infectious Diseases of Animals, Frankfurter Straße 85 - 89, 35392 Gießen, GERMANY

Intestinal displacements including volvulus and invagination have been reported for harbour seals (*Phoca vitulina*) and grey seals (*Halichoerus grypus*) in Dutch waters recently. Intestinal volvulus comprised about 7 % of deaths in stranded harbour seals and 2 % in grey seals.

Since 1997, pathological examinations have been performed on about 1000 free ranging harbour and grey seals from the North and Baltic Sea coasts.

During this period (1997 – 2013), 32 phocids found at the coasts of Schleswig-Holstein, 13 (41 %) male and 17 (53 %) female harbour seals and two male grey seals (6 %) died due to intestinal volvulus and/or intestinal invagination. Moreover, six harbour seals from sealariums or a rehabilitation centre showed intestinal displacements. Ninety-two percent of the affected seals were older than 18 months. Pathological findings associated with intestinal displacements were serohaemorrhagic effusions in the abdominal cavity. In volvulus the intestine was twisted along the mesenteric axis (180° – 3 x 180°) resulting in vascular obstruction and haemorrhagic infarction. Moreover, in some cases diffuse or focal enteritis and diffuse parasitic infestations were observed in the intestine. In five cases a concurrent intestinal invagination occurred. Histology revealed evidence of reactive neutrophilic infiltrations of the affected intestinal segment in some cases indicating probable disease duration of several hours.

Ongoing investigations aim to determine the aetiological impact of different present bacterial species that were isolated along with the pathological examinations, including the development of intestinal displacements.

Intestinal displacement seems to be a cause of death in adult harbour and grey seals. The aetiology will be discussed in further depth.

HEPATOZOONOSIS IN A STONE MARTEN (*MARTES FOINA*) IN VIENNA, AUSTRIA

WEINBERGER H¹, DUSCHER G²

¹Pathology Centre East Mödling, AGES, Institute for Veterinary Disease Control, Robert Koch-Gasse 17, 2340 Mödling, AUSTRIA; hubert.weinberger@ages.at

²University of Veterinary Medicine, Dept. of Pathobiology, Institute of Parasitology, 1210 Vienna, AUSTRIA

Hepatozoon spp. are apicomplexan protozoan blood parasites, that infect rodents, squirrels, canids, felids, racoons, mink, martens and other carnivores, but also birds and reptiles. Transmission of *Hepatozoon* spp. occurs by ticks, mites, lice, mosquitos and other blood-sucking arthropods. Sucking on mammalians these become infected by ingestion of leucocytes containing mature gamonts, from which oocysts are developing. Part of the exceptional developing cycle is the ingestion of an infected blood-sucker by a vertebrate, where out of the sporocysts sporozoites are released in its guts. These sporozoites enter the bloodstream and infect the bone marrow, where they develop to meronts, containing macro- or micromerozoites. These can be found in organs like heart, skeletal muscle, liver or spleen. Free merozoites reenter leukocytes in the bone marrow and transform to gamonts. These are released to the blood again, ready to be taken up by blood sucking arthropods and start the next cycle. *Hepatozoon canis* and *Hepatozoon americanum* are the causative pathogens of canine hepatozoonosis in the Old World and America. Transmission of *Hepatozoon canis* occurs by the brown dog tick (*Rhipicephalus sanguineus*), *Hepatozoon americanum* by the Gulf Coast tick (*Amblyomma maculatum*). In Scotland, Japan and Bavaria (Germany) hepatozoonosis is described in mustelides. Stone martens (*Martes foina*) are widespread in great parts of Europe and Central Asia, apart from the northern parts as UK, Scandinavia or Siberia. Besides their native habitat in areas of deciduous forest, forest edge and open rocky hillsides stone martens are common inhabitants of urban regions. A juvenile male was found within one of the inner city districts of Vienna and kept in the local pound. Within four days the animal showed inappetence, incontinence, painful abdomen and problems with defecation, increasing dyspnoea and died in spite of treatment. Necropsy revealed a good body condition, a multifocal granulomatous pneumonia, hyperplastic spleen and good filled urine bladder. Histopathology showed granulomatous lesions in heart, spleen, lung, liver, kidney and perilienal, perirenal and especially periadrenal fat tissue. The granulomas consisted either of meronts with mild inflammatory infiltration or herds of phagocytes with engulfed merozoites as well as some lymphocytic infiltration. Some of the granulomas were surrounded by a thin capsule of fibrous tissue. The morphology of the parasite stages was typical for *Hepatozoon* spp.. DNA extracts from heart and liver tissue samples were investigated for the occurrence of hepatozoon by using PCR. Specific primers amplifying a 651 bp fragment of the 18S rRNA gene sequences were chosen and the products were sent for sequencing. Blasting of the obtained sequences in GenBank[®] delivered 99 % similarity to *Hepatozoon* spp. found in pine martens. Species determination still waits being elucidated. *Hepatozoon canis* was detected in a golden jackal near Vienna. This is the first description of hepatozoonosis in a stone marten in Austria.

TREATMENT OF HYPERCORTISOLISM WITH TRILOSTANE (VETORYL®) IN TWO GOLDEN HAMSTERS (*MESOCRICETUS AURATUS*)

ZADRAVEC M, RAČNIK J

University of Ljubljana, Veterinary Faculty, Institute of Poultry Health, Dept. for Birds, Small Mammals and Reptiles, Gerbičeva 60, 1000 Ljubljana, SLOVENIA; marko.zadavec@vf.uni-lj.si

Summary

High incidence of adrenocortical hyperplasia and adenoma has been reported in a survey of spontaneous lesions in laboratory hamsters, but to the author's knowledge there are only few data available on hypercortisolism (Cushing's syndrome) in domestic hamsters. Moreover most attempted treatments were unrewarding.

In two older intact female hamsters (*Mesocricetus auratus*) with typical signs of Cushing's syndrome and confirmed hypercortisolism, treatment with trilostane (Vetoryl®) was attempted. The dose 2.5 mg/kg q24h p. o. efficiently reduced cortisol levels, improved general condition and enable hair regrowth within eight weeks in treated hamsters. No adverse clinical signs were noted during the course of therapy. Based on these experiences the authors would recommend trilostane in treatment of hypercortisolism (Cushing's syndrome) in golden hamsters at initial dose 2.5 mg/kg q24h p. o. In cases when high plasma cortisol levels would persist, gradually increase of the dose should be considered.

Introduction

High incidence of adrenocortical hyperplasia and adenoma has been reported in a survey of spontaneous lesions in laboratory hamsters (BROWN and DONNELLY, 2012). To the author's knowledge there are only few data available on hypercortisolism (Cushing's disease) in domestic hamsters (BAUCK et al., 1984; MARTINHO, 2006). Diagnosis is based on clinical signs (polyuria, polydipsia, polyphagia, alopecia, hyperpigmentation) along with concurrent high plasma cortisol (normal values 13.8 to 27.6 nmol/l) and serum alkaline phosphatase (AP) (normal values 8 to 18 IU/l) concentrations (KEEBLE, 2001; ORR, 2009; BROWN and DONNELLY, 2012). However, the exact cause of hypercortisolism in this species could be difficult to determine since patient's size and consequently blood volume limitations for further diagnostics (MARTINHO, 2006; ORR, 2009). Different approaches in treatment of Cushing's syndrome have been attempted. Ketoconazole (5 mg/kg q12h p. o.) (MARTINHO, 2006) and mitotane (5 mg q24h p. o.) (BAUCK et al., 1984) treatments were ineffective and did not improve clinical signs in one month of treatment. Treatment with metyrapone (8 mg q24h p. o. for one month) worked in one hamster out of two. In this case complete hair regrowth was achieved after 12 weeks of therapy (BAUCK et al., 1984).

Materials and methods/Cases

At Department for Birds, Small Mammals and Reptiles, Veterinary Faculty of Ljubljana, two hamsters were diagnosed Cushing's syndrome based on clinical signs, elevated plasma cortisol and serum AP and treated with trilostane (Vetoryl[®], Vetoquinol, Lure, France).

Case 1:

A 30 months old intact female golden hamster (*Mesocricetus auratus*) was presented with polyuria, polydipsia, bilateral symmetric nonpruritic alopecia, thinning and hyperpigmentation of the skin. Plasma cortisol was 165 nmol/l and serum AP was 77.8 IU/l, respectively. She was initially treated with trilostane (Vetoryl[®]) 5 mg/kg q24h p. o., but after three days of treatment she became inactive and anorexic. Due to signs of hypoadrenocorticism therapy stopped until resolution of clinical signs. After two days her general condition improved and trilostane was reintroduced in dose 2.5 mg/kg q24h. Clinical signs of Cushing's syndrome slowly regressed and in eight weeks her hair completely regrew. Blood samples were collected two and four months after the treatment started. Plasma cortisol levels in both samples were below level of detection (< 27.6 nmol/l). The hamster was on trilostane therapy for five months without adverse clinical signs of Cushing's disease and was humanly euthanised at the age of 35 months.

Case 2:

An 18 months old intact female golden hamster was presented with progressive symmetric nonpruritic alopecia and smelly urine. Her skin was thickened and had an area of hyperpigmentation. Plasma cortisol was 30.3 nmol/l and serum AP was 96 IU/l, respectively. Cystitis was treated with trimethoprim-sulfamethoxazole (Primotren[®], Lek, Ljubljana, Slovenia) 20 mg/kg/12h p. o. for ten days. Moreover trilostane (Vetoryl[®]) in dose 2.5 mg/kg q24h p. o. was introduced due to elevated plasma cortisol level.

Two months later the hamster's general health status improved and regrowth of hair could be observed in areas of former alopecia. Blood samples were collected with plasma cortisol values being below the level of detection (< 27.6 nmol/l). Further investigations were not possible. The hamster died one month later aged 21 months.

Results and discussion

We describe an approach to treatment of hypercortisolism with trilostane (Vetoryl[®]) in golden hamsters. Based on our results trilostane successfully lowers elevated plasma cortisol levels, but due to higher minimum measurement range exact levels after treatment could not be determined (> 27.6 nmol/l) by the method used. Trilostane in dose of 2.5 mg/kg q24h p. o. improved general condition and enable hair regrowth in eight weeks in treated hamsters. Unwanted side effects during treatment were not noted, however initial dose of trilostane 5 mg/kg q24h in case 1 resulted in signs of hypoadrenocorticism (debilitation, anorexia). Therapy was stopped and reintroduced after two days, lowering the dose to 2.5 mg/kg q24h. Based on these experiences the authors would recommend trilostane in treatment of hypercortisolism (Cushing's syndrome) in golden hamsters at initial dose 2.5 mg/kg q24h p. o. In cases when high plasma cortisol levels would persist, gradually increasing of the dose should be considered.

References

- BAUCK L, ORR JP, LAWRENCE KH (1984): Hyperadrenocorticism in three teddy bear hamsters: a case report. *Canadian Vet. J.* **25**, 247 - 250.
- BROWN C, DONELLY TM (2012): Disease problems of small rodents. In: Quesenberry KE, Carpenter JW (Eds.): *Ferrets, Rabbits and Rodents; Clinical Medicine and Surgery*. St. Louis: Elsevier, Saunders, 354 - 372.
- KEEBLE E (2001): Endocrine diseases in small mammals. In *Practice* **23**, 570 - 585.
- MARTINHO F (2006): Suspected case of hyperadrenocorticism in a golden hamster (*Mesocricetus auratus*). *Vet. Clin. Exot. Anim.* **9**, 717 - 721.
- ORR H (2009): Rodents: neoplastic and endocrine diseases. In: Keeble E, Meredith A (Eds.): *BSAVA Manual of Rodents and Ferrets*. Gloucester: British Small Animal Veterinary Association, 181 - 192.

PREVALENCE OF *SALMONELLA* SPP. IN SUBCUTANEOUS ABSCESES IN LEOPARD GECKOS (*EUBLEPHARIS MACULARIUS*)

ZAJĄC M¹, MALUTA A², WASYL D¹, HOSZOWSKI A¹, SZULOWSKI K¹

¹National Veterinary Research Institute, Dept. of Microbiology, Partyzantów 57, 24-100 Puławy, POLAND; magdalena.zajac@piwet.pulawy.pl

²Exotic Animals Hospital, ul. Potocka 4, 01-652 Warsaw, POLAND

Cutaneous and subcutaneous abscesses are a common dermatological problem in reptiles. They also can be an outward manifestation of a more serious internal problem and is frequently associated with underlying disease or stress-related factors. Responsible for abscesses formation might be opportunistic bacteria found on and in the body of healthy reptiles. Our research describe the occurrence of *Salmonella* spp. in subcutaneous abscesses in Polish colour morphs gecko breeding farm, consisting of 480 females and 170 males. Lesions from the head area of two live and three dead leopard geckos were removed and checked for growth of *Salmonella* spp. Detected isolates (n = 8) were compared with those (n = 8) found in internal organs (liver, guts, lungs) of the dead ones. *Salmonella* were identified in all tested abscesses. Our studies showed occurrence of different *Salmonella* serovars (*S. Hadar*, *S. Fluntern*, *S. Tennessee*, *S. enterica* subsp. *salamae* 55:k:z39, and *S. Kentucky*). *S. Hadar* was dominant in abscesses and found in internal organs of two geckos followed by *S. Fluntern* found mainly in abscesses and guts. In three abscesses two different *Salmonella* serovars per sample were detected. All isolates were susceptible on tested antimicrobials except streptomycin. PFGE typing showed high similarity of profiles of the same serovars and proved involving of opportunistic bacteria in development of infection were multiple *Salmonella* serovars might participate. Primary reason of abscesses formation seems to be overexploitation of female geckos and lack of supplementation with vitamin A. Proper diagnosis is crucial for successful treatment of animals and avoiding of financial costs.

CHARACTERISATION OF *SALMONELLA* ISOLATED FROM ZOO AND PET SNAKES IN POLAND

ZAJĄC M, WASYL D, HOSZOWSKI A, SKARŻYŃSKA M, LALAK A, SAMCIK I, SZULOWSKI K

National Veterinary Research Institute, Dept. of Microbiology, Partyzantów 57, 24-100 Puławy, POLAND; [magdalena.zajac@piwet.pulawy.pl](mailto:magdalenazajac@piwet.pulawy.pl)

Reptiles are considered as a potential reservoir of *Salmonella*. In the last few years, snakes, especially from the Colubridae and Pythonidae families, have become popular pet animals in Poland. The aim of the study was to investigate the occurrence of *Salmonella* and serovar distribution in exotic snakes from zoological gardens and private owners in Poland. Between 2010 and 2012, 357 faecal samples were taken from reptile farms, zoological shops, zoological gardens, reptile shelter and also from private owners or reptile exhibitions. The testing was run according to PN EN ISO 6579:2003/A1:2007 standard and up to six suspected colonies per sample were checked. *Salmonella* was detected in 92 % (330/357) of tested samples, and in 38 % of positive cases two (30 %) or more (8 %) different serovars were found in the same sample. A total of 486 isolates belonging to 141 different serovars of *Salmonella enterica* were identified as subspecies *enterica* (67 %), *diarizonae* (17 %), *arizonae* (7.5 %), *salamae* (5 %), or *houtenae* (3.5 %). The most prevalent serovar was Agona (n = 43), followed by Oranienburg (n = 38) and Muenchen (n = 30). Interestingly, serovars common in food, other animal species and humans, like Kentucky ST 198 or Infantis, Typhimurium and Enteritidis were also found. The high prevalence of *Salmonella* in the faecal ophidian samples stresses the role of reptiles as *Salmonella* reservoirs.

AUTHOR INDEX

A

Almagro V, Huzman M, Fernández-Bellon H, Novellas R, Casanova I, Ramis T.....	99
Alonso-Farré JM, Gonzalo-Orden M, Llarena-Reino M, Degollada E.....	100
Avni-Magen N, Eshar D, King R, Shilo-Benjamini Y, Gancz AY.....	28

B

Bahr J.....	101
Bailey T.....	27
Bakker J, Klomp R, te Poele EEM, Langermans JAM, van Geijlswijk IM.....	19
Balsiger A, Keller S, Espie I, Lane EP, Kotze A, Clauss M, Codron D.....	102
Baqir S, Orabah A, Al-Rasbi K, Al-Shakaili Y, Gartley C, Mastromonaco G.....	34
Barbon AR, Fountain K, Routh A.....	103
Barszcz K, Olbrych K, Roźniewska N, Kupczyńska M, Warchulska K.....	104
Bartova E, Sedlak K, Nagl I, Vodička R, Ajzenberg D, Slezaková R.....	14
Baumgartner K, Abdelgawad A, Azab W, Damiani AM, Will H, Osterrieder N, Greenwood AD.....	36
Bernardino RI, Fernandes TL.....	105
Bertelsen MF.....	65
Bertocchi M, Spiezio C, Di Ianni F, Macchi E, Parmigiani E, Quintavalla F.....	108
Biagi G, Pinna C, Rigoni G, Spiezio C, Sandri C.....	109
Braun V, Wüst E, Kramer M, Schmidt M.....	110
Brazis P, Puigdemont A, Ravera I, Almagro V, Fernández-Bellon H.....	111
Budd J, Lewis J, Soilemetzidou S, Whitehouse-Tedd K.....	113

C

Cabajal A, Fernández-Bellon H, Talló-Parra O, Almagro V, Sabés-Alsina M, López-Béjar M.....	114
Carnimeo A, Andreani V, Capasso M, Silvestre P, Nocerino M, Guandalini A, Selleri P, Di Girolamo N.....	82
Carvalho MPN, Sant'Anna SS, Grego KF, Gogone ICVP, Catão-Dias JL.....	93

Casares M, Gerique AC, Carbajal A, Talló-Parra O, Sabes-Alsina M, Carbonell MD, Lopez-Bejar M	115
Chai N, Petit P, Kohl M, Bourgeois A, Gouni V, Trehiou-Sechi E, Misbach C, Petit A, Garrigou A, Guépin R, Pouchelon JL, Chetboul V.....	75
Clauss M, Hatt J-M	83
Crespo-Picazo JL, García-Párraga D, Bernaldo de Quirós Y, Díaz-Delgado J, Cervera V, Martí-Bonmatí L, Arbelo M, Fernández A.....	9
Czujkowska A, Kruszewicz A, Arciszewski MB	91

D

Da Silva MO, Bertelsen MF, Heegaard S, Garner MM	97
Delaski K, Ramsay E, Gamble K.....	71
Dolka B, Włodarczyk R, Żbikowski A, Szeleszczuk P, Ledwoń A.....	116
Douay G, Tasse J, Bertucat V, Simonin C, Bes M, Laurent F	119

F

Feltre Y, Dodds J, Masters N, Niblett R, Somauroo J, Modi S, Shave R.....	69
Fernandes TL, Bernardino RI, Peleteiro C	120
Fiorucci L, Grande F, Flanagan C, Silva J, Urbani N, Sampayo J, Macrelli R.....	121
Fiorucci L, Grande F, Pilenga C, Henriques A, Manfrini V, Flanagan C	68

G

Galateanu G, Göritz F, Saragusty J, Szentiks CA, Wibbelt G, Hildebrandt TB	122
Galateanu G, Göritz F, Wibbelt G, Szentiks CA, Hildebrandt TB	126
Galateanu G, Hermes R, Saragusty J, Göritz F, Potier R, Mulot B, Maillot A, Etienne P, Bernardino R, Fernandes T, Hildebrandt TB.....	129
Galateanu G, Saragusty J, Göritz F, Wibbelt G, Szentiks CA, Mezö Z, Hildebrandt TB	132
Galateanu G, Szentiks CA, Krone O, Hildebrandt TB.....	136
García-Párraga D, Griffeth RJ, Crespo-Picazo JL, Álvaro T, Valls M, Soriano-Navarro M, Martinez A, Moreno-Manzano V.....	137
Gattiker C, Espie I, Lane EP, Kotze A, Codron D, Clauss M	89
Germitsch N, Vybiral P-R, Codron D, Clauss M, Kotze A, Lane EP	138

Gerritsmann H, Stalder GL, Spergser J, Hoelzl F, Deutz A, Kuebber-Heiss A, Walzer C, Smith S ...	38
Giacomelli S, Bianchi A, Polloni A, Archetti LI, Bertoletti I, Rota Nodari S	139
Grande F, Fiorucci L, Crosta L, Guerreiro E	142
Gruetzmacher KS, Leendertz FH	35
Gutleb DR, Pflüger LS, Wallner B	143

H

Hagen K, Espie I, Lane EP, Kotze A, Wyss F, Clauss M, Codron D	57
Halck ML, Bertelsen MF	92, 144
Hatt J-M, Bauert M, Wenger S	55
Hatt J-M, Jaya Y, Erdiansyah R, Frey R	145
Hoby S, Wenker C, Zenker W, Lawrenz A, Keller R	79
Holtze S, Lukac M, Cizelj I, Hildebrandt TB	98

I

Iannaccone M, Sanna Passino E, Campolo M, Bono L, Secci F, Columbano N	146
IJzer J, Keesler RI, Kik MJL, Brasseur SMJM, Verdaat H, Gröne A	147

J

Jiménez M, Hagnauer I, Meneses A, Blanco K	148
Jiménez M, Torres AM, Hagnauer I, Blanco K	149

K

Kaiser C, Varughese AA, Liesegang A	150
Keller S, Balsiger A, Espie I, Lane EP, Kotze A, Clauss M, Codron D	56
Kelly A	1
Kilgallon C, Kinne J, Moittie S	90
Kiupel M, Hollinger C, Curtis B, Riegl B, Bruckner A	39
Knauf-Witzens T, Krengel A	43

Kneisl T, Karbe F, Stagegaard J, Will H, Baumgartner K, Liesegang A	88
Koroknai V, Molnár V, Lajos Z, Gál J, Sós E	151
Korytár L, Ondrejková A, Ondrejka R, Prokeš M, Čechvala P	154
Krawiec M, Kuczkowski M, Rusiecki S, Woźniak A, Kruszewicz A, Wieliczko A	159
Krawiec M, Pietkiewicz M, Wieliczko A	160
Krengel A, Knaut-Witzens T, Süß-Dombrowski C, Schwabe I, Schares G	18
Kvapil P, Kastelic M	161

L

Lamglait B, Joris A, Berthet M, Kimmel L, Leclerc A, Trunet E	162
Lamglait B, Romey A, Joris A, Lemberger K, Bakkali Kassimi L	163
Lampe K, Rudnick J-C, Bleyer M, Kaup F-J, Mätz-Rensing K	164
Langan JN, Kleinschmidt LM, Warneke M, Allender MC	77
Langer S, Wiegmann L	165
Larska M, Krzysiak MK, Kęsik J, Smreczak M, Dackiewicz J, Żmudziński JF	166
Leclerc A, Trehiou-Sechi E, Greunz EM, Damoiseaux C, Bouvard J, Chetboul V	76
Ledwoń A, Dolka I, Dolka B, Cegiełkowska M, Szeleszczuk P, Czopowicz M	167
Liptovszky M, Szilasi A, Papp GV	169
Loth K, Reiners JK	81
Lueders I, Pootoolal J, Taya K, Watanabe G, Yamamoto Y, Niemuller C, Chenier T, Scholtz E	170
Lueders I, Young D, Botha S, Gray C, Luther I, Maree L, van der Horst G, Tindall B, Bertschinger HJ	10
Lukac M, Horvatek Tomic D, Cizelj I, Prukner-Radovic E	171
Luz S, Lee P, Raghavan R	172

M

Magnone W, Sandri C, Salvellia A, Avesani C, Pascotto E	173
Masters N, Franklinos L, Feltrer Y, Pocknell A, Bolt D, Smith S, Molenaar FM	78
Memarian I, Abarghouei MJO, Molazem M, Pedram MS, Vali Y, Mohajeri SF, Ghazaleh N, Shahrđari AR	174

Memarian I, Dehghan MM, Molazem M, Pedram MS, Rostami A, Vali Y, Farzad S, Zehtabvar O, Shahrdari AR, Hamidi AHK, Abdolmalekiyan N	2
Modesto P, Biolatti C, Grattarola C, Varello K, Iulini B, Mandola ML, Dondo A, Gorla M, Rocca F, Acutis P	178
Molnár L, Beregi A, Major P, Kuzyšinová K, Molnárová M	33
Molnár L, Major P, Ptacek M	181

N

Naidenko S, Pavlova E, Kirilyuk V	13
Napier JE	40
Niphuis H, Fagrouch Z, Bogers W, Verschoor E	182

O

Orłowska B, Anusz K, Krajewska M, Augustynowicz-Kopeć E, Zabost A	37
---	----

P

Painer J, Fritsch G, Hertwig C, Göritz F	183
Painer J, Jewgenow K, Dehnhard M, Arnemo JM, Linnell JDC, Odden J, Hildebrandt TB, Göritz F	184
Perrin K, Grøndahl C, Nissen P, Bertelsen MF	80
Prokeš M, Benkő Z, Korytár L, Ondrejková A, Ondrejka R, Čechvala P	185

Q

Quintard B, Apery S, Lefaux B	186
-------------------------------------	-----

R

Račnik J, Zadavec M, Trilar T, Zorman Rojs O	187
Risch T, Kershaw O, Ochs A	188
Rossier C, Hoby S, Wenker C, Jermann T, Posthaus H	189
Rosu O, Udrescu LA, Birtoiu D, Manu E	190
Roźniewska N, Barszcz K, Kupczyńska M	196

S

Sabés-Alsina M, Fernández-Bellon H, Huzman M, Almagro V, Talló-Parra O, Cabajal A, López-Béjar M	197
Salchow AM, Greenwood AD, Hölzle LE	198
Sargsyan NI, Arakelyan M, Danielyan F	199
Scaglione FE, Bollo E, Chiappino L, Sereno A, Mignone W, Moschi R, Garibaldi F, Tittarelli C, Guarda F	203
Scaglione FE, Longato E, Pregel P, Piria M, Capobianco Dondona A, Nannarelli S, Appino S, Bollo E	204
Schmitt A, Lampe K, Bayrhof G, Gruber-Dujardin E, Mätz-Rensing K, Kaup F-J, Bleyer M	205
Slezaková R, Bartova E, Vodička R, Sedlak K	206
Smith DA, Stasiak IM, Hafeez MA, Delnatte P, Barta JR	12
Soares JF, Shiferaw FD, Al-Hanoosh N, Macasero W	29
Soilemetzidou S, Budd J, Dorrestein G, Whitehouse-Tedd K	211
Springer A, Fichtel C, Leendertz F, Calvignac-Spencer S, Mellmann A, Nunn CL, Kappeler PM	26
Steinmetz HW	70

T

Tahas S, Timofte D, Chantrey J, Lopez J	212
Teare JA	72

U

Unger F, Eisenberg T, Prenger-Berninghoff E, Ludwig M-L, Rothe M, Ewers C	213
---	-----

V

Vicari N, Bianchi A, Manfredini A, Giacomelli S, Genchi M, Bertoletti I, Fabbi M	214
Vybiral P-R, Germitsch N, Codron D, Clauss M, Kotze A, Lane EP	215

W

Wasył D, Hoszowski A, Zajac M, Jabłoński A, Skarżyńska M, Samcik I, Lalak A, Szulowski K	216
--	-----

Wasył D, Zając M, Hoszowski A, Jabłoński A, Lalak A, Samcik I, Skarżyńska M, Szulowski K.....	11
Wehrmeister E, Wohlsein P, Prenger-Berninghoff E, Siebert U	217
Weinberger H, Duscher G	218

Z

Zadravec M, Račnik J	219
Zając M, Maluta A, Wasył D, Hoszowski A, Szulowski K.....	222
Zając M, Wasył D, Hoszowski A, Skarżyńska M, Lalak A, Samcik I, Szulowski K	223