

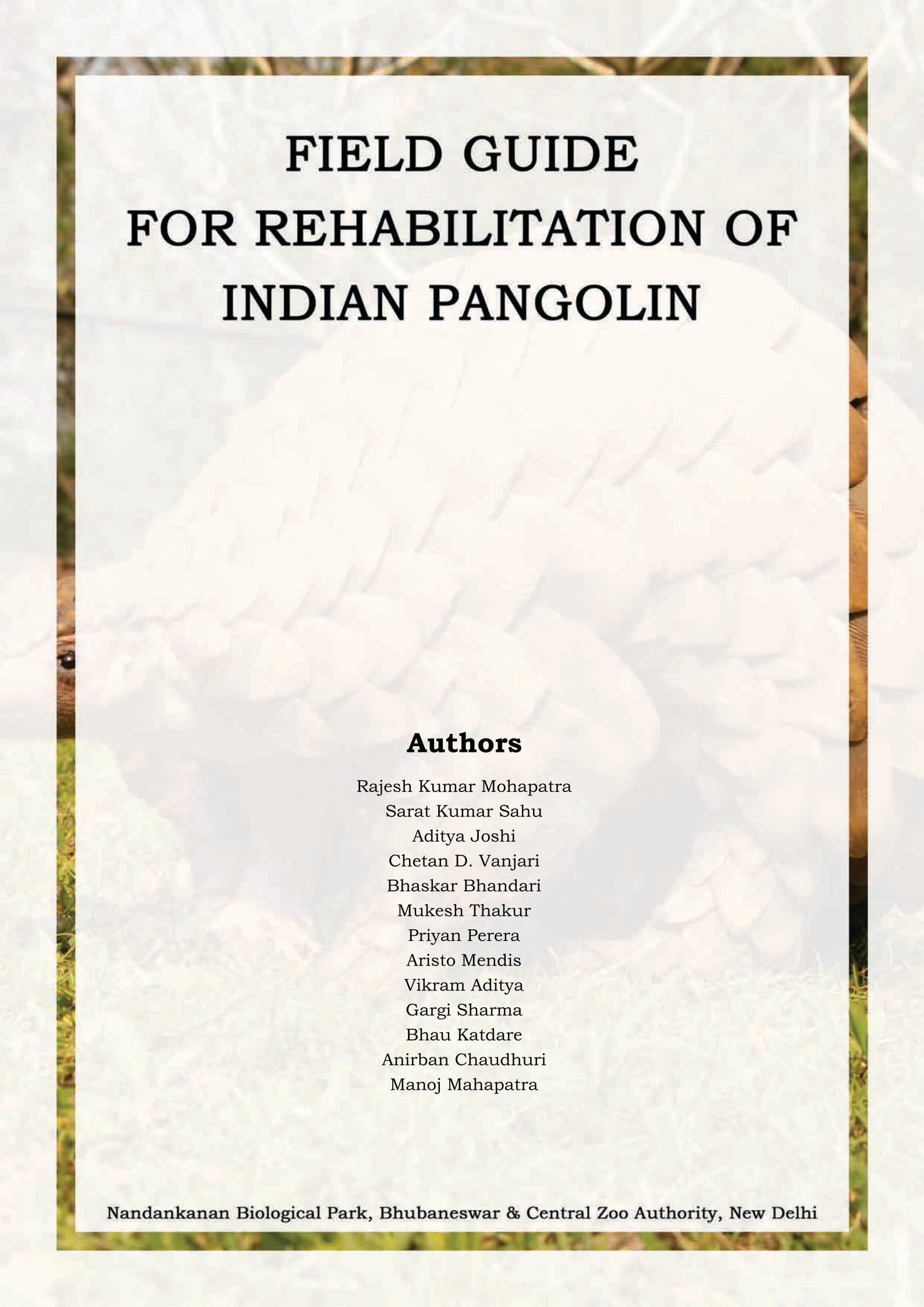


आजादी  
का  
अमृत महोत्सव

NANDANKANAN

**FIELD GUIDE  
FOR REHABILITATION OF  
INDIAN PANGOLIN  
2021**





# FIELD GUIDE FOR REHABILITATION OF INDIAN PANGOLIN

## **Authors**

Rajesh Kumar Mohapatra

Sarat Kumar Sahu

Aditya Joshi

Chetan D. Vanjari

Bhaskar Bhandari

Mukesh Thakur

Priyan Perera

Aristo Mendis

Vikram Aditya

Gargi Sharma

Bhau Katdare

Anirban Chaudhuri

Manoj Mahapatra



All rights reserved. Reproduction and dissemination of the publication for non-commercial purpose is authorized without written permission from the copyright holder, provided the source is fully acknowledged. Reproduction of the publication for resale or other commercial purpose is prohibited without written permission from the copyright holder.

**Disclaimer:** This publication is meant for authorized use by the personnel of zoos and rescue centers, forest officials and veterinarians involved in wildlife crime control, rehabilitation and pangolin conservation activities *in-situ* and *ex-situ*. The information and statements contained in this document referring to any specific product, trade name, trademark, manufacturer, or otherwise does not necessarily imply its endorsement or recommendation by the authors or publishers.

**Published by:** Nandankanan Biological Park, Bhubaneswar and Central Zoo Authority, New Delhi

Released on the occasion of “Azadi ka Amrit Mahotsav” celebration highlighting Indian Pangolin (*Manis crassicaudata*) from 12<sup>th</sup>-18<sup>th</sup> July 2021

**Photo credits:**

Rajesh Kumar Mohapatra: Front cover, Fig. 1.a., 5, 6.c, 9a-13b, 14a-16; Dulu Borah: Fig. 1.b; Bhau Katdare: Back cover, Fig. 3.a, 4, 23a; Himanshu Lad: Fig. 3.b.; Sharath Babu, R.: Fig. 6.a,b; Chetan D. Vanjari: Fig. 17.a-c, 18a,c; Sarat Kumar Sahu: Fig. 18.b; Mukesh Thakur: Fig. 19-20.e; Bhaskar Bhandari: Fig. 21.a-d; Aditya Joshi: Fig. 13c, 22.b, 23.b.

**Illustration credits:**

R.K.Mohapatra and S. Panda (2014): Fig. 2; Priyan Perera et al. (2020): Fig. 7, 8; Nick Ching-Min Sun et al. (2019): Fig. 22.a.

**Layout and design by:** Ar. Sruthy Boopathy

**Suggested citation:** Mohapatra, R.K., Sahu, S. K., Joshi, A., Vanjari, C. D., Bhandari, B., Thakur, M., Perera, P., Mendis, A., Aditya, V., Sharma, G., Katdare, B., Chaudhuri, A. and Mahapatra, M. (2021) Field guide for rehabilitation of Indian pangolin. Nandankanan Biological Park, Bhubaneswar and Central Zoo Authority, New Delhi. pp : 1-39.



GOVERNMENT OF INDIA  
भारत सरकार

MINISTRY OF ENVIRONMENT, FOREST & CLIMATE CHANGE

पर्यावरण, वन एवं जलवायु परिवर्तन मंत्रालय

**Central Zoo Authority**

केंद्रीय चिड़ियाघर प्राधिकरण



**Dr. S P Yadav, IFS**  
**Member Secretary**

## Foreword

The Central Zoo Authority (CZA) is a statutory body of Ministry of Environment, Forest and Climate Change, Government of India and is responsible for overseeing establishment & scientific management of zoos in the country. The CZA facilitates and supports zoos in the improvement of zoo management practices like, animal welfare measures, species-specific husbandry and veterinary care.

The Indian pangolin (*Manis crassicaudata*) is cryptic and has a complex biology. The Indian pangolin has been accorded the highest protection in the Indian Wild life (Protection) Act 1972 as it faces major threats leading to serious declines in their numbers. Inadequate information on population and distribution further accentuates the threats arising from hunting and poaching. The remarkable number of seizure reports from the country suggest that even in a short time span of 4-5 years (2009-13), over 3,000 pangolins were hunted. Media reports state that during the period, approximately 5,000 kg of pangolin scales were confiscated in 25 seizures.

CZA has initiated planned Conservation Breeding Programme for 73 species including Indian pangolins (*Manis crassicaudata*). Nandankanan Biological Park, Bhubaneswar is the coordinating zoo for the planned conservation breeding of this species. There is limited information available on the Indian Pangolin related to husbandry care and even protocols related to rehabilitation. The Nandankanan Biological has developed a protocol for successful housing, husbandry and conservation breeding.

I wish to congratulate the authors who have put together the publication; "Field Guide for Rehabilitation of Indian Pangolin" based on their experience, and research. The field guide will serve as a reference document for work related to rehabilitation of rescued or confiscated pangolins, occasionally received in different Indian zoos.

**Dr. S.P. Yadav IFS**  
**Member Secretary**  
**Central Zoo Authority**

## **PREFACE**

Pangolins are nocturnal and toothless mammals, body covered with scales. Population of these small mammals has declined in the wild due to indiscriminate poaching, illegal trade of live pangolins and their body parts, habitat loss to certain extent. In addition, as the pangolins are habitat generalists, they are found in diverse habitats including those in protected areas, fringe forests and at times near human habitations. There has been a sustained increase in rescue and seizure of live Indian pangolins in recent years. Since there is no SOP available for rehabilitation of these Indian pangolins, the healthy animals are generally released to nature without any post-release monitoring. The seized pangolins are often recovered in poor health conditions with injury, dehydration, debility and are sent to nearby zoo or rescue centre for treatment. Owing to limited knowledge on management, health care and rehabilitation, these pangolins have a slim chance of survival. In the above circumstances, there is a need for a field guide with proper protocol for handling the confiscated pangolin cases providing a better chance of survival.

The field guide has information on key steps that first responders should follow for initial care of rescued/seized Indian pangolins. Information on various aspects of Indian pangolin biology, their handling, transportation, housing, nursing, health care, genetic sampling and release protocols are also discussed. The authors hope this book will be an important tool for wildlife rehabilitation professionals, zoo managers, biologists and veterinarians.

This publication is a compilation of information from wildlife veterinarians, biologists and professionals working on the biology, captive management, health care, counter wildlife trafficking, genetics, ecology and rehabilitation of rescued/seized Indian pangolins.

The authors have given their best possible efforts to bring out details correctly. Opinions and suggestions from readers may be sent to the copyright holders for improvement of the field guide in future edition.

We are thankful to Dr Dan Challender, former Chair, IUCN- Pangolin Specialist Group and Mr. Bimal Prasanna Acharya, Deputy Director and Prof. S. Maharana, Ex-Research Officer, Nandankanan Zoological Park for valuable technical advice and inputs. Thanks are due to Dr. Sonali Ghosh, DIG and Dr S. P. Yadav, Member Secretary, Central Zoo Authority, New Delhi for their kind patronage that made publication of the field guide possible.

**Authors**



10 July 2021

India is one of the mega-biodiversity countries of the world, and home to two of the world's 8 pangolin species - the Indian pangolin (*Manis crassicaudata*) and the Chinese pangolin (*Manis pentadactyla*). These species are experiencing significant population declines due to a synergy of threats – from habitat loss to illegal exploitation for commercial markets – and, as a result, are today considered Endangered and Critically Endangered, respectively, under IUCN Red List criteria. Like many pangolin species around the globe, one conservation intervention regularly employed for pangolins in India is rehabilitation and reintroduction of individuals rescued from wildlife trafficking. Unfortunately, the success of these interventions is often thwarted by poor health of animals at the time of seizure and the highly specialized care needed to ensure their rehabilitation.

The *Field Guide for Rehabilitation of Indian Pangolin*, produced by the Central Zoo Authority, New Delhi and the Nandankanan Biological Park, Bhubaneswar, is a pioneering effort that will undoubtedly be a useful resource guiding the rehabilitation and reintroduction of pangolins in India. We congratulate the contributing authors and the publishers for releasing this guide on the August occasion of Azadi ka Amrit Mahotsav in celebration of 75 years of Indian independence. Aligning the release with such an important day in India only serves to highlight the dedication of the Indian authorities and all its people to the conservation of Indian pangolins.

The IUCN SSC Pangolin Specialist Group is committed to securing a future for wild pangolins through advancing knowledge on pangolin status, threats, and conservation priorities. And, by working with and supporting stakeholders in all range countries, we catalyze and support action for their conservation. We look forward to continuing our successful relationship with the Indian pangolin conservation community into the future!

Best wishes,



Dr. Matthew H. Shirley  
Co-Chair, IUCN SSC Pangolin  
Specialist Group



Mr Shashi Paul, IFS  
Principal CCF (Wildlife) &  
Chief Wildlife Warden, Odisha

Government of Odisha  
Principal Chief Conservator of Forests  
(Wildlife) & Chief Wildlife Warden, Odisha  
Prakruti Bhawan, Saheed Nagar,  
Bhubaneswar-751007  
Email: [odishawildlife@gmail.com](mailto:odishawildlife@gmail.com)

Nandankanan Biological Park is one of the large premier zoos of the country in the state of Odisha. Since its inception on 29th December 1960, it has been progressively emerging as prominent centre for ex-situ conservation, education and research. As a part of support to in-situ conservation, Nandankanan has undertaken Conservation Breeding of Indian pangolin. It is unique and the only centre of its kind in India as well as in the world. It has immensely contributed to the knowledge on biology of the least known endangered Indian pangolin. The Park is also serving as a centre for rehabilitation for many orphaned/injured wild mammals of the state including rescued, seized and orphaned Indian pangolins.

The publication titled “Field Guide for Rehabilitation of Indian Pangolin” being released on the occasion of the National celebration of “Azadi ka Amrit Mahotsav” to emphasize conservation of Indian pangolins on 12th July 2021 is an attempt to bridge the information gap in managing this innocent and enigmatic species.

The authors have taken pains to document efforts and experiences in their respective field of expertise lead by Nandankanan Biological Park which is commendable. I am sure the field guide would provide valuable information to all wildlife managers enabling them to address Indian pangolin rehabilitation issues in a much more effective and scientific manner.

(S. Paul)  
Principal CCF (Wildlife) &  
Chief Wildlife Warden, Odisha

# Contents

---

<b>1. Introduction</b> .....	2
<b>2. Biology</b> .....	3
<b>3. Threats</b> .....	6
<b>4. Morphometry</b> .....	7
<b>5. Initial care</b> .....	9
<b>6. Personal hygiene and safety</b> .....	13
<b>7. Handling</b> .....	14
<b>8. Transportation</b> .....	15
<b>9. Housing</b> .....	16
<b>10. Nursing</b> .....	16
<b>11. Health care</b> .....	17
<b>12. Genetic sampling</b> .....	28
<b>13. Release requirements</b> .....	32
<b>14. Suggested reading</b> .....	37



# 1. Introduction

---

Pangolins are toothless mammals, body covered with overlapping scales except the ventral surface. They roll up into a ball when threatened. This is a unique self-defense against predators. Though pangolins appear dangerous, they are innocent and shy creatures. They feed on ants and termites using their long protrusible tongue. They have a prehensile tail.

Globally, eight species of pangolin are found in continents of Asia (*Manis crassicaudata*, *Manis pentadactyla*, *Manis javanica* and *Manis culionensis*) and Africa (*Phataginus tricuspis*, *Phataginus tetradactyla*, *Smutsia gigantea* and *Smutsia temminckii*). Out of them, only two species occur in India i.e., Indian pangolin (*Manis crassicaudata*) and Chinese pangolin (*Manis pentadactyla*). Indian pangolin is found throughout India except upper Himalayas, extreme Northeast and some part of Thar desert, Nepal, Bhutan, Bangladesh, Pakistan, and Sri Lanka. The distribution of Indian and Chinese pangolin intersects at Eastern Uttar Pradesh, Northern Bihar and some parts of North Eastern states. Both species are protected in India as Schedule I species under the Wildlife (Protection) Act, 1972 and included in Appendix I of CITES. Indian pangolins are stated Endangered in IUCN Red list of threatened species.

The key morphological differences between Indian and Chinese pangolins are, (i) Indian pangolin exhibits relatively large scales, which are broad, rhombic shape and pale brownish to yellowish in color whereas Chinese pangolin scales are relatively smaller and darker in coloration, (ii) Indian pangolins have 11–13 longitudinal rows of scales along their back compared to 15–18 rows seen in Chinese pangolin, (iii) A terminal scale is present only on the ventral tail tip of Indian pangolin, but absent in Chinese pangolin.



Fig 1. Pangolins found in India, a. Indian pangolin (left), b. Chinese pangolin (right).

Pangolins are ecologically important species as they help in regulating ant and termite populations and thereby control disease in forest trees. They are considered as habitat engineers as they dig soil to live and feed helping soil aeration and mineral fixation. The abandoned burrows act as shelter for many fossorial animals.

Pangolins are most trafficked mammals in the world. Their illegal trade are due to high demand of their scales, skin and meat in the local and international market. They are also poached for traditional medicines due to superstitious beliefs.

## 2. Biology

---

### **Systematic position:**

Kingdom: Animalia

Class: Mammalia

Order: Pholidota

Family: Manidae

Genus: *Manis*

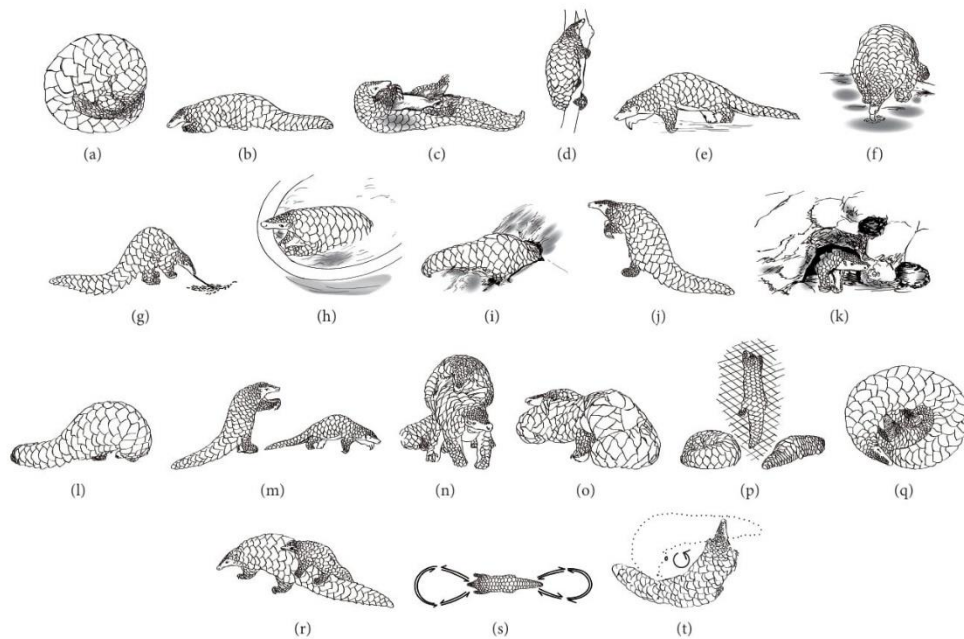
Species: *crassicaudata*

Common English name: Indian pangolin, thick-tailed pangolin.

Scientific name: *Manis crassicaudata*

Local/vernacular names: Khavale Manjar (खवल्या मांजर) in Marathi, saal khapri (साल खापरी) in Chhattisgarhi, bon-rou (বন-রৌ) in Assamese: Alugu (అలుగు) in Telugu, eenampechi ("ഇന്റനാంപേച്ചി") in Malayalam, alangu ('அலங்கு') in Tamil, bajrakapta ('ବଜ୍ରକାପ୍ତା') in Odia, Erumbu thinni (எறும்பு தின்னி) in Tamil and chippu handi (ಚಿಪ್ಪು ಹಂದಿ) in Kannada.

**Behaviour:** Indian pangolins are solitary animals, except during mating and rearing their young. They curled up to a ball like posture in self-defence. They are predominantly nocturnal i.e., mostly active during night and rest inside burrows during daytime. They are fossorial, excavate their own burrows. Their abandoned burrow are used by many other fossorial animals including porcupine and pythons. Pangolins do not vocalise, but they do make considerable noise while digging soil or tearing apart ant nests and termitaria. They produced a hissing sound when disturbed. They have a distinct odour. They are myrmecophagous, predated on selective species of ants and termites. This contributes for regulating social insect populations.



(a) Resting in coiled posture, (b) resting in a straight posture, (c) laying on back, (d) climbing, (e) walking, (f) drinking, (g) feeding, (h) bathing, (i) digging, (j) bipedal stand, (k) secretive look, (l) head bend towards ventral surface in defence, (m) bipedal chase, (n) mounting, (o) copulation, (p) retreat, (q) baby pangolin suckling, (r) baby pangolin on her mother's back, (s) pacing in "8" shape, and (t) pacing in "O" shape.

Fig. 2. Different behavioural activities of Indian pangolin.

**Habitat:** They occur in a diverse habitat range, in tropical and sub-tropical forests, coniferous, broadleaf forests, arid thorn forests, swamp forests, woodland, bamboo, grasslands and artificial landscapes including gardens and man-made plantations. Their presence is largely determined by the availability of prey species, water source and nevertheless hunting and poaching pressures. Their natural predators are large cats (e.g., lion, tiger and leopard), bears, pythons, hyenas and crocodiles. Human poachers are the main enemy.




Fig. 3. Nocturnal activity of Indian pangolins in two different habitats, a. in Chiplun, Maharashtra (left), b. in Sahyadri Tiger Reserve, Maharashtra (right).





Fig. 4. Indian pangolin near human habitat.

**Reproduction:** They breed throughout the year. Usually one and rarely two young are born in a litter with a gestation period of 8-9 months. Indian pangolin neonates weigh 160-235g and measure 25-30cm in length that includes 10.5-12.5cm tail. Young Indian pangolins become independent at 5-8 months of age. Their longevity in the wild is not known and in captivity they live more than 21 years.



Fig. 5. Mother and baby Indian pangolin.



### 3. Threats

---

All pangolin species are heavily trafficked mammals in illegal wildlife trade in the world, Indian pangolins are no exception. They are extensively hunted for their meat which is consumed as a delicacy by various communities. Their scales and skins are traded for profit. Much of the demand for pangolins arises because of false beliefs of their scales having medicinal properties. These beliefs are completely unfounded and have no scientific basis. Pangolin scales are made of keratin, the same material found in human fingernails and hair, in rhino horns and in the feathers, claws, hooves and horns of different animals and birds.

While most earlier pangolin trades used to happen through local middlemen facilitating purchase of live pangolins or their body parts from local hunters, recent studies have found an increase in the pangolin trade in larger scales; moving across state and even across national borders through organized networks that prefer to sell live animals for substantial sums of money. Online platforms in recent years are also contributing to the escalation of the trade. Unfortunately, such illegal pangolin trades are only contributing to further decline of their population in the wild. The seized pangolins often recovered with poor health including injury, dehydration and debility. Yet, hunting and wildlife trade bring humans and wildlife into close contact and increases the risks of transmission of pathogens causing zoonotic diseases like recent COVID-19. Besides, because of weird appearance of pangolin and lack of awareness among people, at times people kill them considering them as dangerous animal.



Fig 6. Threats, (left to right) a. seizure of pangolin body parts, b. killing a pangolin by locals, c. use of pangolin scales as ring.



## 4. Morphometry

There are significant intra-specific variations in morphometrics of Indian Pangolin across its range. Based on the body weight and total body length, Indian pangolins can be categorized as juvenile ( $\leq 4.3$  kg,  $\leq 56.0$  cm), sub-adult (4.3–7.3 kg, 56–101 cm), and adult ( $\geq 7.3$  kg,  $\geq 101$  cm). In general, an adult Indian pangolin weighs 8–16 kg and measures 100–148 cm in length from tip to tip. However, there are some exceptional cases of fully grown males measuring (i) 176.8 cm and weighing 48.76 kg from Sri Lanka, (ii) measuring 170 cm and weighing 32 kg from India and (iii) measuring 147.3 cm and weighing 20 kg from Pakistan.

Body scales of Indian pangolins are arranged along 11–13 longitudinal rows. They possess 444–532 scales. These body scales are of three shapes: folded, elongated kite and broad rhombic shaped consisting 6%, 13.5% and 80.5% of the total number of scales and have mean dry weight of 6.2 g, 4.9 g and 7.5 g, respectively. On average the scales of an adult Indian pangolin weigh 34% of total body weight and is about 3.5–3.6 kg.

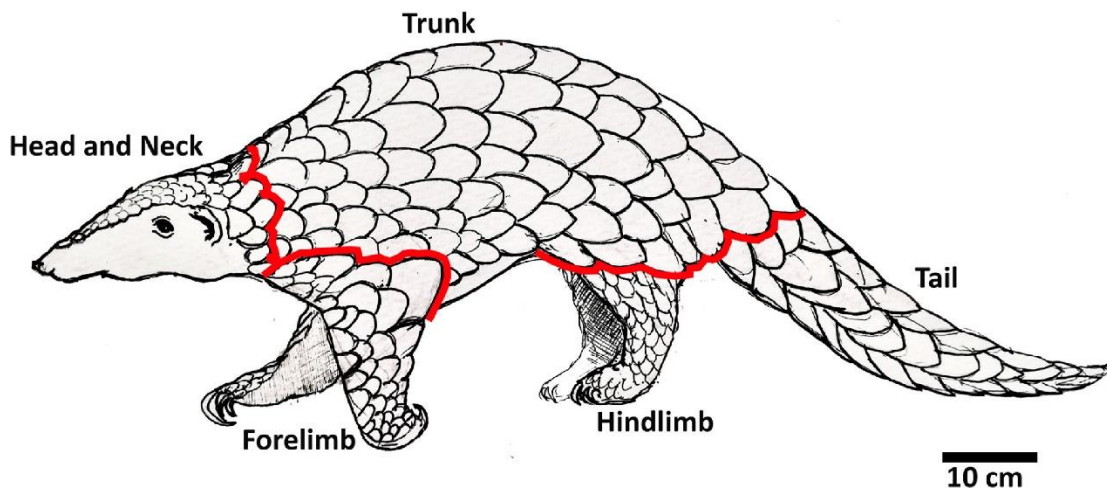


Fig. 7. Indian pangolin body parts (lateral view).

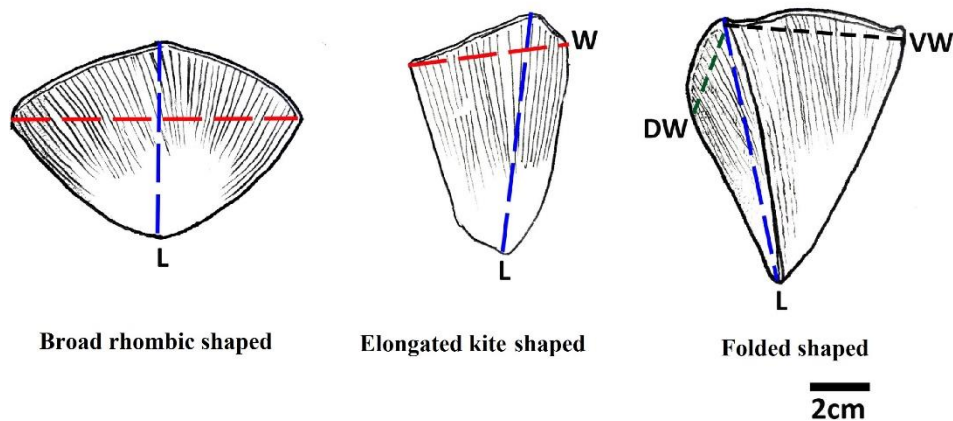


Fig. 8. Three different scale shapes of Indian pangolin.

#### 4.1. Measuring a live Indian Pangolin

The Indian pangolin often remains coiled up to a threat or disturbance making it difficult for measurement. There is a need to weigh the pangolin at the time of arrival and at intervals in subsequent days. The weight gives an idea about gradual weight loss or weight gain. Weight loss is usually associated with ill health. Generally healthy young pangolins exhibit slow and steady increase in weight.

To weigh a pangolin, it is carefully placed inside a gunny sack and then hooked into a hand-held spring balance (preferably digital) to record the body weight. Juvenile and sub-adult pangolins (< 5 kg) which are easy to handle may be weighed using a table spring balance.

Body length measurements should be taken along the mid-dorsal vertebral line using a flexible/cloth measuring tape. The Indian pangolin should be in an uncurled position or in a physiologically reclined position to take proper body measurements, which is not always possible. Alternatively, the tail length (TL) can be measured on the ventral side by gently holding its tail at its end to chest height for making the pangolin uncoil, followed by measuring the length from tail tip to tail base/anus. The total body length (TBL) can be approximated using the formula  $TBL = 2.03 \times TL$ , i.e., if the tail length (TL) is 50cm, the total body length (TBL) will be  $50 \times 2.03 = 101.5\text{cm}$ .

Sexing the pangolin is difficult when they are in curled position. Therefore, while measuring uncurled pangolins, their external genitalia could be examined to determine their sex. Males have short and conical genitalia, testes are internal but bulges out in the skin fold when uncurled. In females, the vulva is a transverse opening in front of the anus.



Fig. 9. Measurement of body weight, (left to right) a. using hand held spring balance for adults, b. using table spring balance for juveniles, c. measurement of body length.

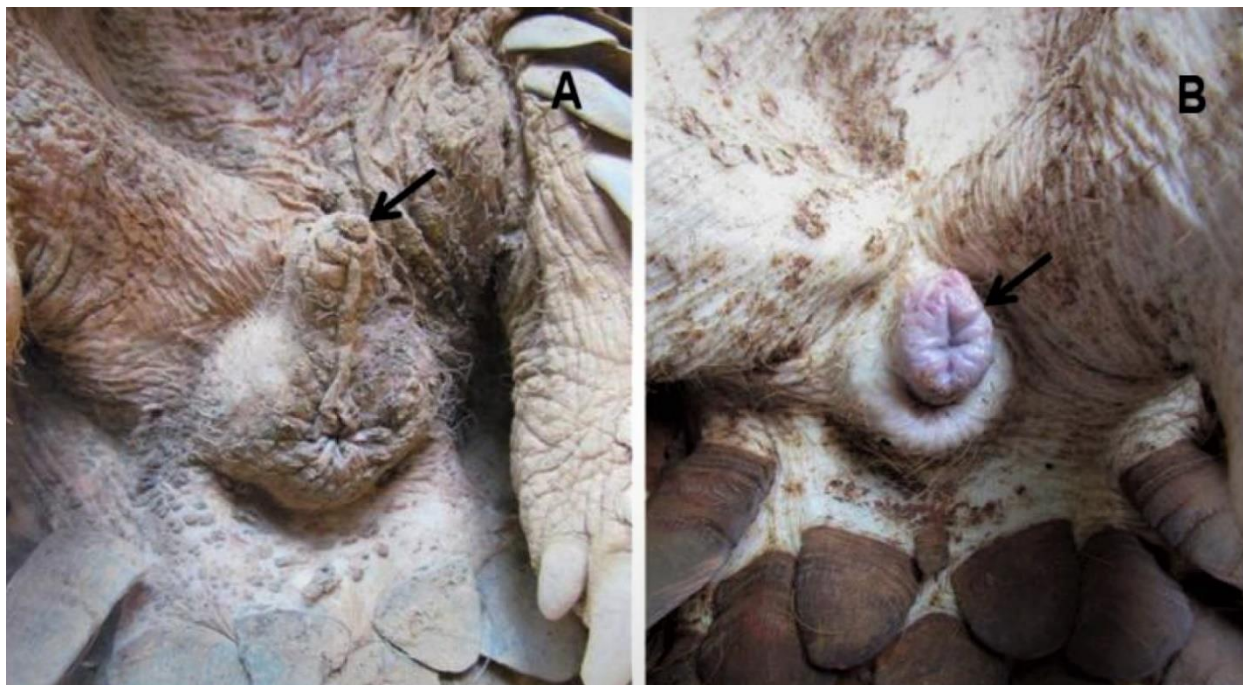

Fig. 10. Genitalia of Indian pangolin male (A) and female (B).

## 5. Initial care

---

Often pangolins come near to human habitations. In such situations, local Forest department may be informed to rescue the animal to avoid the risk of trafficking, feral/domestic dog attack and opportunistic illegal possession or trade by local people. If the pangolin is healthy, releasing it back to the nearby protected forest area is recommended.

Pangolins seized from illegal trade, are usually dehydrated, malnourished and in poor health. They are typically in state of shock due to stress of handling, injury from hunting and transportation. Rapid breathing, low pulse rate and abnormal body temperature are the indicators of shock. The first thing to do is to free the pangolin from all constraints (sack, bag, net, wire etc.) to reduce stress. As soon as possible the pangolin is to be shifted to a quiet place preferably a well-ventilated room free from furniture away from crowd and bright light. A wooden box with blanket inside can be placed in a corner. A bowl full of water can be provided near to it.

Once the pangolin is settled, it needs to be checked for the following parameters to assess its health condition.

Table 1. Signs of normal and poor health in pangolin.

<b>Parameters</b>	<b>Normal</b>	<b>Signs of poor health</b>
Behavioural response	Pangolins in good health curl-up to make a tight ball	Slow response to human touch, sleeping uncoiled
	Walks and sniffs the surrounding	Less/no interest in sniffing and exploring the environment
	It is difficult to uncurl a healthy stressed pangolin	Unable to make a tight curl and little resistance shown when attempted to uncurl
Gait	Quadripedal movement with tail not touching the ground	Limping, staggering, dragging of tail on the ground
Physical injury	No cut, laceration, wound on body	Palmar surface of foot/foot pads, limbs and below the scales usually have cuts, lacerations, wounds, ulcers
Discharges from nares, eyes, genitalia	Nostrils and eyes are usually moist and no discharge from genitalia	Watery/ mucopurulent discharge from nostrils; dry/ sunken eyes; reddish/ mucopurulent discharges from genitalia
Hydration status (Difficult to assess)	Active movement, moist nostrils and eyes	Lethargic, dry nostrils, sunken eyes
Parasites	Below the scales are free from ecto-parasites, faecal sample is free from ova/larvae	Below the scales contain ecto-parasites, faecal sample examination reveal presence of parasitic ova/larvae
Body temperature	Usually the skin is warm and dry to touch	Too hot and cold, moist is sign of ill health
Smell	Pangolins have a characteristic odour	Pangolin in ill health usually have a foul smell, soiled tail base with wet faeces and foul smell is indicative of diarrhoea



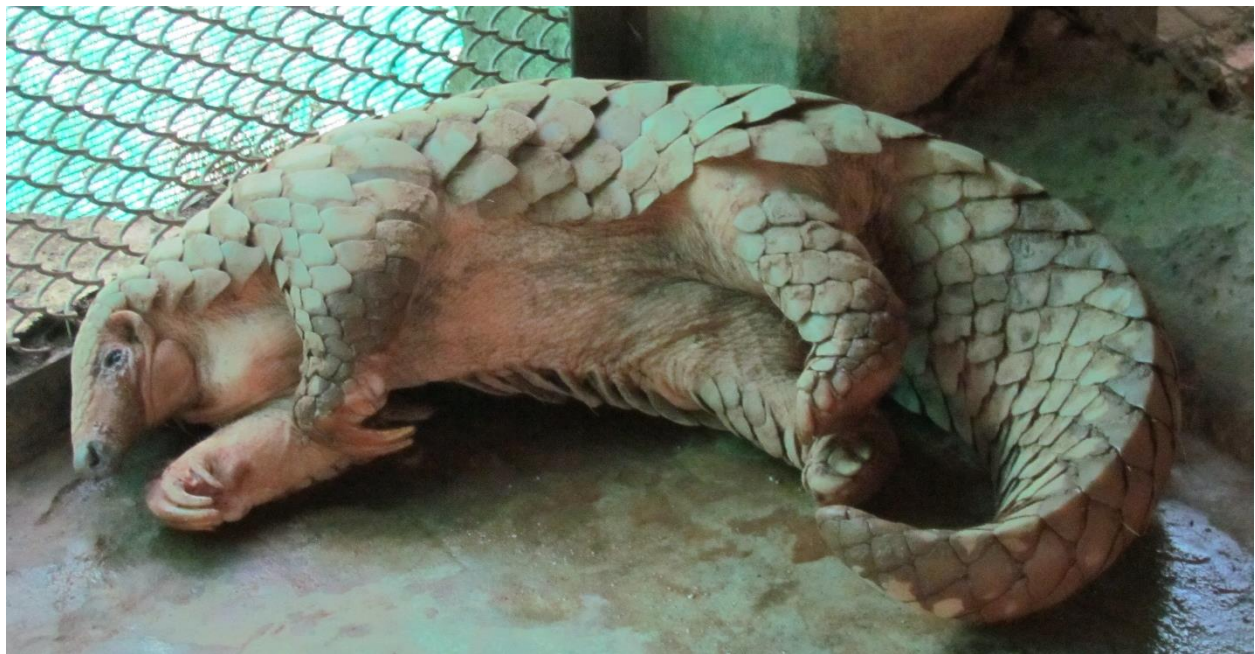
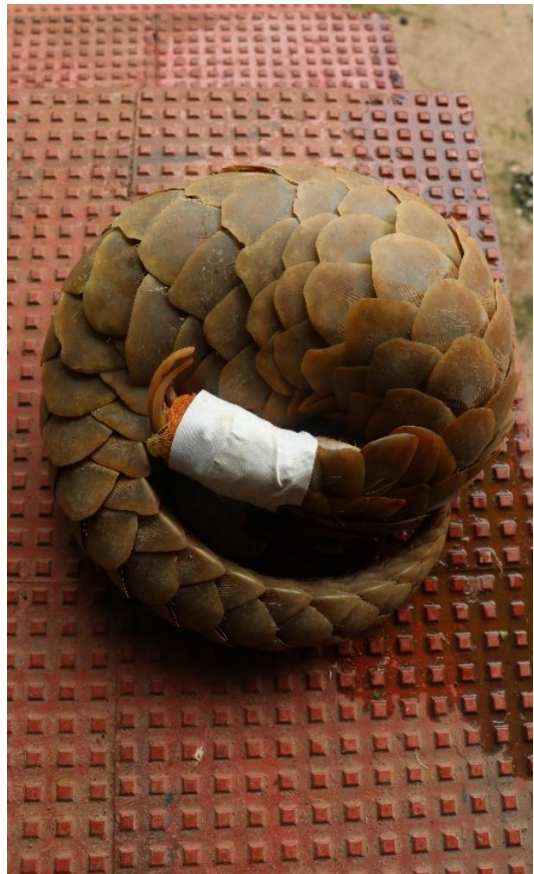
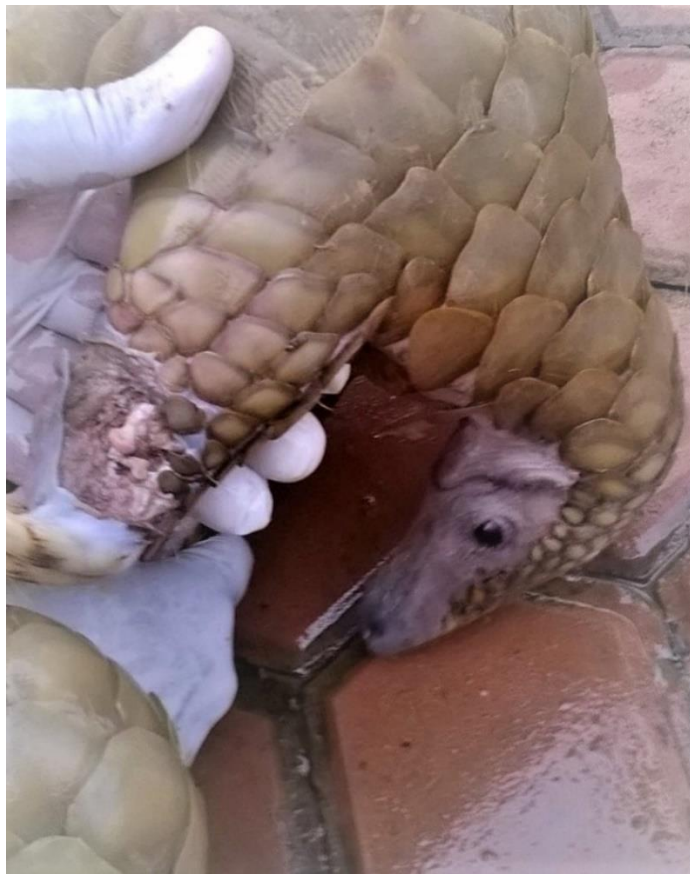Fig. 11. Indian pangolin, a. with ulceration (top left), b. treatment of wound (top right), uncoiled sick pangolins (below).



### 5.1. Documentation of case history

Detailed documentation of case history is important as it is necessary for further management decisions and legal requirements. Collection of the following information is recommended.

Table 2. Pangolin history card for rescued/seized Indian pangolin.

Rescued/seized by	
Date and time	
Location of recovery (Forest Division, beat and geo-coordinate)	
Species	
Location of collection/poaching	
Date of collection by poacher	
Method of capture	
No. of days held by poacher	
Food / water given	
Type of constraint (box, sac, cage etc.)	
Weight in gram	
Length in centimetre	
Sex (Male/Female)	
Condition (Hot, cold, injured, dehydrated, healthy)	
Strength (loosely curled, tightly curled, uncurled, collapsed)	
Walking (Yes/No)	
Parasite (Yes/No)	

NB: Separate card to be used for each individual if more than one pangolin confiscated. Photograph of the individual to be attached to the card.

## 5.2. Preparation for first aid

In order to provide first aid, a first aid kit is required containing the following articles.

### a) For wound dressing

- Kidney shaped tray (Stainless steel)
- Sterile gauze roll
- Cotton swabs
- Iodine solution (5%)
- Normal saline solution (for wound washing)
- Antiseptic powder
- Swab holding forceps
- A pair of scissors
- Latex gloves
- Antiseptic wipes

### b) For general use

- Rubber heavy duty gloves (for holding)
- A pair of scissors
- Large size forceps
- Measuring tape
- Torch light
- 70ml sterile sampling bottle
- Pen, pencil and markers
- Drinking bowls

## 6. Personal hygiene and safety

---

Pangolin in good health is usually strong. An alarmed/shocked Indian pangolin curls up into an armoured ball with tail covering its head. The edges of pangolin scales are very sharp. It can twitch its tail very fast in defense. Hence, there is every chance for the handler of getting incised injury. Rescue and seized pangolins carry a variety of pathogens, therefore, use of surgical gloves is recommended to minimize the risk of spreading infectious disease. Hence for safe handling following articles are required.

- Rubber heavy duty gloves
- Sterile surgical gloves
- Aprons, face mask and coveralls
- Towels/ gunny bags
- Transportation box

## 7. Handling

---

- 1) Pangolins are sensitive and get easily stressed. Thus, should be handled with care and only when absolutely necessary.
- 2) They should not be forcefully uncurled. The tail end should be gently held at chest height to make the pangolin uncurl. Patience and gentle handling make the pangolin uncurl by itself. While handling ensure that there is plenty of room and no objects for the pangolin to grab onto.
- 3) Putting hands under the belly or tail base should be avoided. Their tail scales may cause injury to the handler.
- 4) Caution must also be exercised as sometimes claws of the pangolin may cause injuries to the handler.
- 5) To catch a curled-up pangolin, reach in and hold it with two hands like you would hold a ball.
- 6) The mother pangolin and its baby should be kept together.
- 7) Two persons are required to carry out the physical examination and measurement of a pangolin: one person as the pangolin handler and the other to perform the visual assessment and taking measurement.
- 8) Pangolin should not be dropped while handling.
- 9) The pangolin should not be left unattended on the examination table as it's difficult for them to climb down and can fall and get injured.



Fig. 12. Handling Indian pangolin.

## 8. Transportation

---

- 1) Pangolins can only be shifted/ transported to a rescue centre/zoo with required permission from the appropriate authority (local Forest Department and Chief Wildlife Warden).
- 2) Pangolins are active during the night time, transporting them during the day is suitable and easier as they remain asleep.
- 3) Well ventilated wooden box or commercially available plastic crates can be used for transporting pangolins.
- 4) A box of an appropriate size should be selected for pangolin transportation. The length of the box should be a little larger than the length of pangolin, the width of the box should be larger than the diameter of the uncoiled pangolin and the height of the box should be higher than that of the standing height of pangolin.
- 5) Pangolins need to be transported individually, i.e., one animal per box except in the case of mother and baby. The mother and her baby should be transported in the same transportation box.
- 6) During transportation to the rescue facility, the pangolin should be kept away from direct sunlight or extreme temperature.
- 7) Provision of feed and water in fixed bowl should be made inside the box for long-distance transportation. There is also a need to check the pangolins health at regular intervals.



Fig. 13. Transportation boxes for Indian pangolins, (left to right) a. wooden crate with chain link mesh top, b. commercially available plastic crates, c. wooden box.



## 9. Housing

---

The housing facility should be of 15sqm floor area, bigger is better. The enclosure should be top covered and with 3m high smooth boundary walls and/or chain-linked mesh fence. The pangolin could be kept both in soil substrate enclosure with concrete base or in concrete substrate enclosure for a temporary period based on availability in the field. The enclosure should be made secure and escape-proof as pangolins are escape artists and can dig, climb and squeeze through small spaces. The top of the enclosure should be well covered and secured. It should have a provision of proper ventilation, proper drainage and shelter. A hollow wooden log or a wooden crate of appropriate size can be provided as shelter to hide, rest and sleep. Gunny bags and paddy straw could be given as winter substrate for adults. Gunny bags are not recommended for a mother with neonate, rather a hollow wooden log with some paddy straw works well.

Care should be taken to house each pangolin in a separate cell, as pangolins are solitary animals. However, NEVER separate the mother and her baby. They should be kept in moderately warm temperatures, ideally in the temperature range of 25°-33°C.



Fig. 14. Housing requirements for Indian pangolin, a. soil substrate enclosure (left), b. concrete substrate enclosure (right).

## 10. Nursing

---

**Natural feed:** Red-weaver ants with their eggs and/or termites to be provided as feed. These ants make leaf nests in Eucalyptus, Mahua, Jamun, Mango, Orange, Sal, Acacia, Citron, lemon and Litchi tree. Their nest should be collected carefully to avoid their painful bites. For giving live ant feeding to pangolins, a special feeding bowl which prevents live food from escaping (a small bowl with live feed fixed on a larger bowl containing water) is required. Dead ant feed can be served on marbled platforms on the ground or on feeding bowls fixed on tree branches to enhance natural foraging



/feeding behaviour. Termite combs can be given placing in a partially opened gunny bag to avoid their escape.

**Supplementary feed:** Boiled poultry eggs minced and mixed with milk powder can be given, when ants/termites are not available.

**Hand rearing diet:** The baby pangolin can be successfully reared using canine baby milk formula. Mohapatra et al. (2013) reported the successful rearing of a 4-week-old baby pangolin feeding with reconstituted 'Royal Canin baby dog milk' powder till it accepted ant feed at 29th week of age. The powder was reconstituted @ 1.5g in 20ml of water on the 1st week of rearing which was gradually increased to 4g in 20ml of water in 15th week that continued till 29th week. Initially, it was provided 5-6 feeding/day which was gradually reduced to 2 feedings/day from 23rd week onwards and stopped after 29<sup>th</sup> week.



Fig. 15. Feeding Indian pangolin, a. on red weaver ant (left), a. on reconstituted milk formula (right).

**Provision of Water:** Provision of clean water for pangolin to drink to be made in heavy concrete bowl or inverted dog bowl to avoid spill over. While drinking their sticky saliva creates bubbles that remain till few hours. In absence of CCTV, by observing the presence of bubble it could be known whether the pangolin has accepted water or not. During winters it is advised to provide lukewarm water. Pangolins like to take bath, therefore additional water pool is to be provided. Bathing is prevented during cold weather and pangolin with nasal discharge.

## 11. Health care

---

Once the animal is settled, general physical check-up and medical examination of Indian pangolins should be carried out by veterinarian considering the following parameters.

**Temperature:** Normal rectal body temperature of Indian pangolins is between 91-94°F (32.8 to 34.4°C). Juvenile and sick pangolins are more susceptible to catch cold. If the body temperature of a pangolin is below normal, then it should be covered with

blankets or suitably warm water filled gloves/bags can be placed below their abdomen to increase body temperature back to normal. It should not be too hot to avoid skin burns.

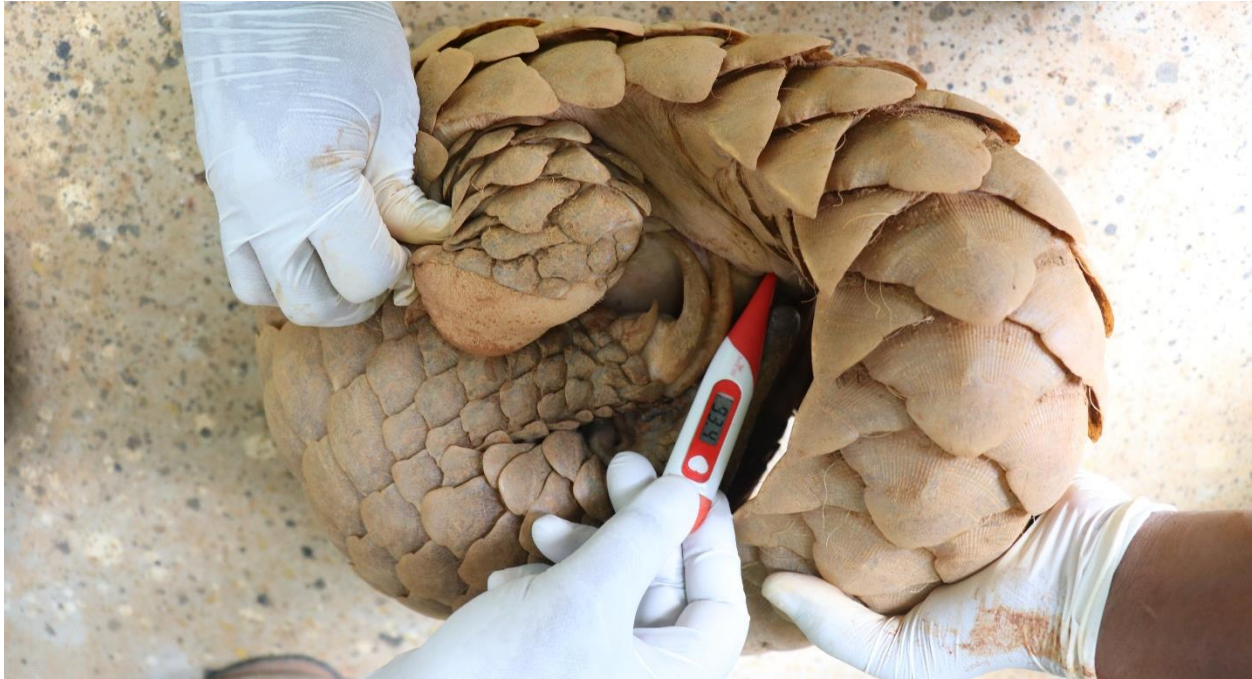

Fig. 16. Measuring rectal temperature of Indian pangolin.

**Mucous membrane:** Healthy pangolins have moist and pink mucous membranes. Dry or sticky mucous membranes are suggestive of severe dehydration. Pale or light pink mucous membranes are indicative of anaemia. Cyanotic or greyish mucous membrane is indication of serious respiratory dysfunction which should be immediately treated with emergency oxygen therapy.

**Parasites and bacteria:** Rescued/seized Indian pangolins are usually infested with ticks (species *Amblyomma javanense* and *Aponimma gerviasi*). They are also frequently found to carry gastrointestinal parasites e.g. strongyles and strongyloides. Several species of bacteria are found associated with Indian pangolins and some of them are pathogenic (see Mohapatra et al.; 2016, 2020 for details). There is a high possibility of disease transmission if rescued/seized pangolins interact with existing captive animals of zoo or rescue centre. Therefore, it is recommended to follow proper quarantine protocols in order to avoid disease transmission. Suitable healthcare management practices are described in following sections.

**Anaesthesia:** The first response of Indian pangolin to handling, is to curl-up into a tight ball. Forceful uncoiling of the coiled pangolins can result in injury to them. Sedation is required before further examination and to reduce the stress of handling. Inhalation anaesthesia using an 'anaesthesia induction chamber' is preferred for



sedation, induction and maintenance. Mild sedation can be achieved using Isoflurane @2.5-3.5% in 'anaesthesia induction chamber' for 3-4 minutes. Then, it can be taken out of the chamber and anaesthesia can be maintained delivering isoflurane @ 1.5-2% employing a face mask. Regular monitoring of SPO<sub>2</sub> level is required as the pangolin goes to deep place of anaesthesia. Heart rate should be monitored regularly when pangolins are anaesthetised. Normal heart rate for Indian pangolin is 75-85 beats per minute. This rate can go down when pangolins are in a deep plane of anaesthesia. If the pangolin is very weak and not resisting further examination, then sedation should be avoided.

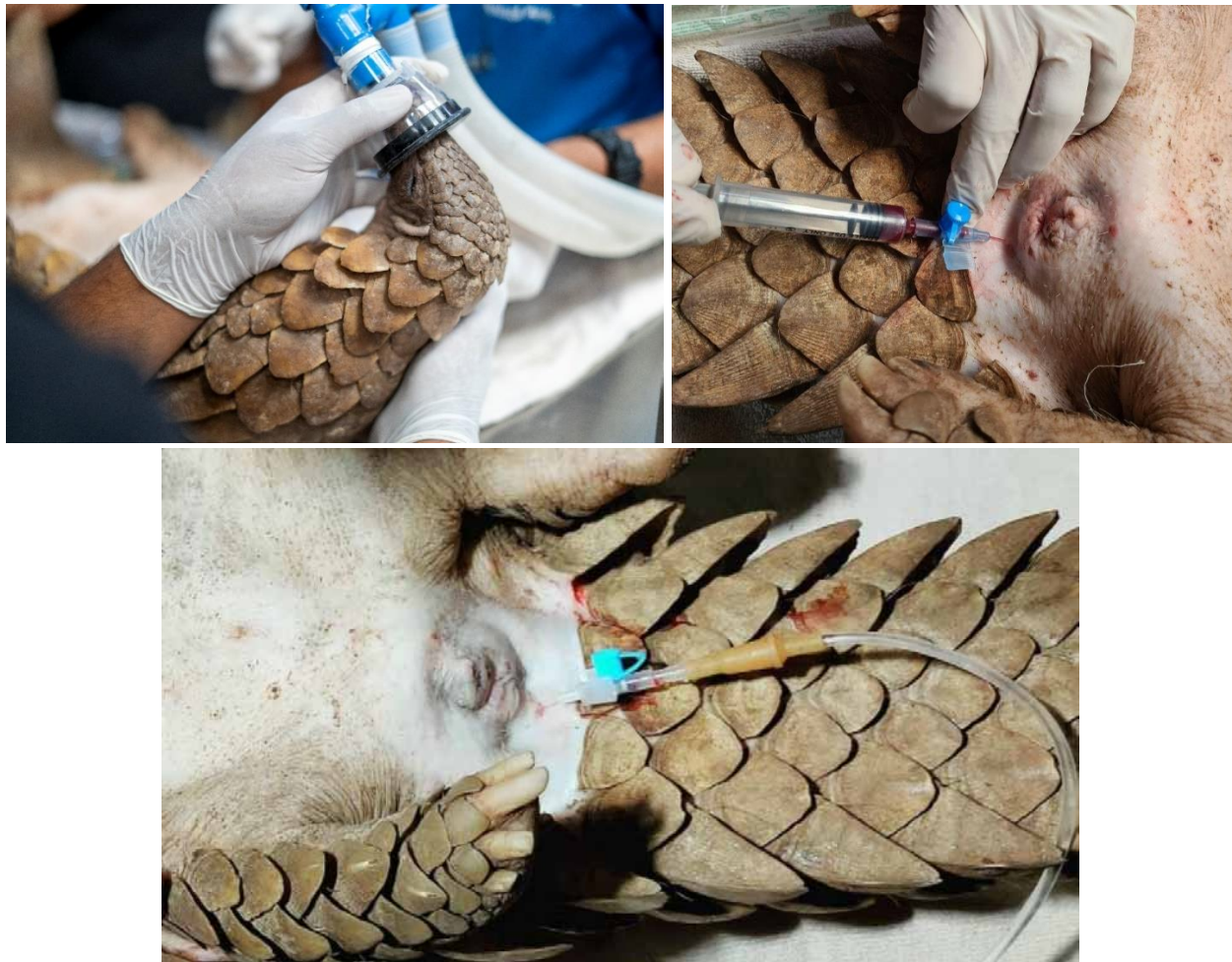

Fig. 17. a. Sedation using inhalation anaesthesia (left), b. blood sampling (right), c. fluid therapy (below).

**Blood sample collection:** Once they are anaesthetised, their coccygeal vein on the ventral midline of the tail can be accessed for venipuncture for collection of blood samples. Based on the body weight, 20-24G IV catheters / needles inserted at 45-degree angle to collect blood samples. Blood parameter of the Indian pangolins are given below.

Table 3. Haematological parameter of two confiscated Indian pangolins before and after treatment.

Specimens	Juvenile male Indian pangolin of body weight 2.1kg		Adult female Indian pangolin of body weight 10kg	
	On the day of confiscation	After 2 days of treatment	On the day of confiscation	After 2 days of treatment
Weight (kg)	2.1	2.1	10	10
Temperature (°F)	93.2	93.2	89.6	91.7
Haematocrit (%)	24.8	26.7	28.4	35.6
Haemoglobin (g/dL)	7.8	8.6	10.5	10.2
Total WBC Count (per $\mu$ L)	3.4	7.1	4.2	9.2
Total Lymphocyte Count (per $\mu$ L)	0.5	2.9	3.6	4.8
Blood Urea Nitrogen (mg/dL)	16	20	16	14
Creatinine (mg/dL)	0.6	0.5	0.4	0.6
Albumin (g/dL) (A)	3	3	2.2	2.6
Globulin (g/dL) (G)	3.2	3.3	3.3	3.2
A/G	0.9	0.9	0.6	0.8
Total Protein (g/dL)	6.2	6.3	5.5	5.8
ALT (U/L)	56	45	220	254
AST (U/L)	42	65	100	136
Alkaline Phosphatase (U/L)	68	110	921	114
Total Bilirubin (mg/dL)	0.1	0.1	0.1	0.3
Uric Acid (mg/dL)	0.4	0.4	0.2	0.3
Glucose (mg/dL)	110	94	70	108

**Radiography:** When pangolins are sedated it is recommended to do chest and abdomen auscultation and radiography. Radiography of chest is very important as pangolins are very susceptible to respiratory tract infections like pneumonia, when they go under stress. Abdominal radiographs are helpful in understanding gastrointestinal problems e.g. constipation etc. which is common due to dehydration and lack of movement. A minimum of two views i.e., ventro-dorsal view and lateral view are required to identify the problem.

**Fluid therapy:** Veterinarians can assess dehydration status by checking mucous membranes, eyes and muzzle of Indian pangolins. When pangolins are clinically dehydrated, following signs are observed.

- a. Their muzzle gets super dry and become crusty.
- b. Their eyelids stick together and they half-open their eyes or cannot open eyes at all.
- c. Their oral mucous membrane becomes dry or sticky with stringy saliva.

So, fluid therapy is essential in pangolins showing above clinical signs. After collection of blood samples, the same site can be used to administer fluids employing same IV catheter. The amount of fluid required, is calculated based on the level of dehydration at the time of arrival, usually Crystalloid bolus fluids @ 5-7ml per kg body weight can be given.

**Tube feeding:** Pangolins which have been kept in captivity by poachers generally show inappetence and weakness. So, for the first couple of days until they start eating by themselves, liquid food formula can be administered by tube feeding. In this procedure a feeding tube is advanced into the stomach through the oral cavity of the sedated pangolin and liquid food/milk formula is administered with the help of a syringe. A plain cat/puppy milk formula can be used for baby pangolins and cat/puppy milk formula added with crushed termites or ants for sub-adult and adult pangolins. Generally, in Indian pangolins, liquid food or milk formula @0.5% of their body weight (i.e., 4-5ml/kg body weight) is recommended and can be given without any complications through stomach tubes.

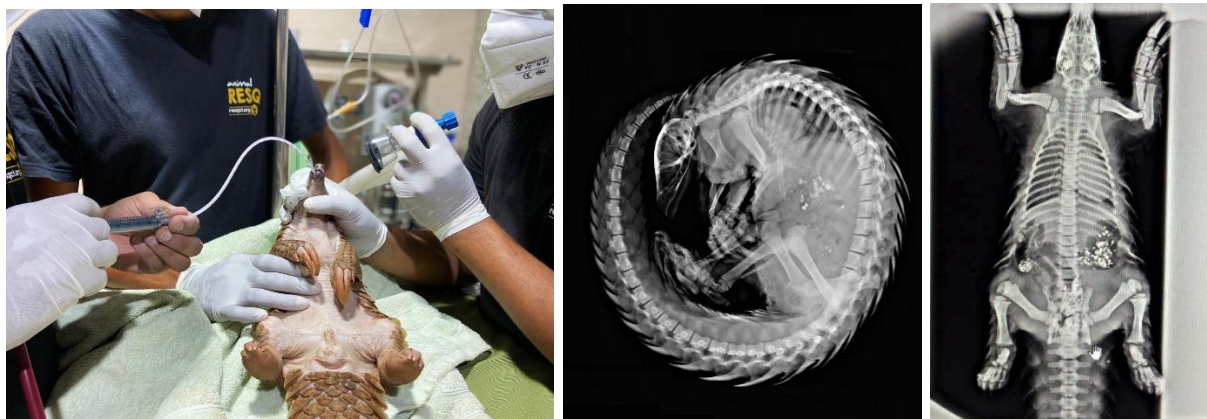

Fig. 18. (left to right) a. Tube feeding, b. radiography-lateral view, c. radiography- dorso-ventral view.



**Normal/ assisted feeding:** Once baby Indian pangolins start self-feeding through syringes with some assistance, tube feeding should be stopped. Also, in case of adult Indian pangolins those start self-feeding on termites, tube feeding has to be discontinued. They can be taken for walks to the nearby ant-hills. Water should be kept available *ad libitum* to pangolins those are eating on their own. When pangolins are showing a steady increase in weight and appetite, blood tests should be done again to confirm if they are healthy, and the parameters are in the normal range. Once they are all by themselves, they could be considered for release to nature.

### 11.1. Reported health issues

The following health issues was reported in captive Indian pangolins. Pneumonia was found to be the major cause of morbidity and mortality. A summary of ailments reported in Indian pangolins are listed.

Table 4. Reported health issues in Indian pangolin and its suggested therapy.

<b>Clinical sign</b>	<b>Possible aetiology</b>	<b>Suggested therapy</b>
1. Ectoparasite infestation		
Weakness and debility	Presence of tick underneath the scales and in skin folds	Local dusting/ spraying of ectoparasiticide or parenteral administration of ectoparasiticide
2. Endoparasite infestation		
Diarrhoea and reduced appetite	Bacteria or endoparasitic infection of gastrointestinal tract	Administration of appropriate endoparasiticide drug after faecal sample/ rectal swab examination. Maintenance of proper sanitation measures, while providing feed and water. Discontinuation of artificial / supplementary feed
3. Constipation/impaction		
Absence of stool, reduced appetite, occasional lethargy, straining	GI tract obstruction, lack of fiber in diet, lack of water intake (especially in the winter months).	Provision of feed moistened with water, addition of warm water in pool, provision for more enrichment items in enclosure to increase behavioural diversity and encourage defecation, addition of laxative drugs in diet
4. Melena/blood in stool		
Stools are darker than usual, tarrier in appearance, loss of appetite, lethargy	GI tract infection, Vitamin K deficiency.	GI tract infection suitable antibiotic therapy with haemostatic drug, if diagnosed as Vitamin K deficiency – supplementation of Vitamin K

5. Epistaxis/nose bleeds		
Bleeding from nose, reddish tinge around the nares.	Trauma to nasal region due to infighting, injury by dropping down to the floor from a height, while climbing, Vitamin K deficiency	Local dressing with Betadine for trauma, Vitamin K supplementation in the diet in either powder (K-SOL) or liquid form on a daily basis, parenteral haemostatic agent
6. Blood in urine		
Urine has a reddish-brown tinge.	Vitamin K deficiency, urinary tract infection, possible blood protozoan parasite	If diagnosed as Vitamin K deficiency – supplementation of Vitamin K, urinary tract infection – suitable antibiotic and haemostatic therapy, appropriate anti-protozoal therapy
7. Tongue problems		
Anorexia – animal shows interest in food but does not actually eat it and unable to throw its tongue, excessive salivation – mouth held open with tip of the tongue hanging out, tongue discoloration – tongue turns lighter in appearance due to a lack of circulation, reddishness of throat.	dietary contamination/ bacterial infection	Treatment with appropriate antibiotic and analgesic drug, feeding through stomach tube may be considered
8. Stress		
Off-fed, dull, exhibition of stereotypic pacing	Change in environment, excessive handling	Minimal handling of the animal, provision of species appropriate enclosure which can fulfil their biological and behavioural needs, supplementation of oral anti-stress drug.
9. Nasal discharge, upper respiratory infection, pneumonia		
Nasal discharge/ upper respiratory infection – visible discharge from nose,	Nasal discharge/ upper respiratory infection, consistent exposure to	Administration of broad spectrum antibiotics with other supportive therapy, increase holding temperature, provision of warm and

abnormal/strained breathing sounds, occasional reports of lethargy, pneumonia – anorexia, lethargy, abnormal/strained breathing sounds. The majority of these clinical signs are masked and difficult to detect	cold/humid environment, b) pneumonia – bacterial/viral infection / septicaemia or untreated upper respiratory infection,	dry environment.
10. Eye discharge/ lacrimation		
Persistent lacrimation from eyes	Stress, allergic reaction, cold air	Allergic reaction – parenteral administration of antibiotic/ anti allergic drug and local instillation of eye drop, stress/cold air– symptoms commonly reported to fade in one week upon correction of management practice
11. Ear infection		
Bloody discharge from ears, unstable while walking, scratching of ear, reddening of ear.	Not listed	Instillation of appropriate ear drops.
12. Heat stroke		
Lethargic, unable to stand, unresponsive to stimuli, blood in stool	High ambient temperature with high humidity.	Increased aeration, administration of sub-cutaneous fluid, administration of cold enema, administration of steroids and antibiotics.
13. Kidney disease		
Anorexia, extreme lethargy, whole-body edema.	Bacterial contamination of diet or drinking water.	Antibiotic therapy, liver tonic supplementation.
14. Hypothermia		
Anorexia – individual in a state of torpor and unresponsive to external stimuli. Onset of symptoms is rapid.	Exposure to low environmental temperatures or cold water (pangolin may remain submerged in pool for long period when it is sick).	Provision of warm and dry environment, supplemental heating may prove effective in some cases, water may be removed from large pools to refrain the pangolin from long-period submergence in pool when sick.

15. Trauma due to aggression/ mating attempts		
Visible lacerations/ puncture wounds over body.	Aggression among adult individuals leading to physical injury (reported in situations involving breeding or introductions)	Wound was cleaned with normal saline, Tetracycline dichloride. Betadine or Lorexane ointment can be applied on it. For septic wound additional broad spectrum antibiotic can be administered intra muscularly on the thigh muscle under veterinary prescription. Regular monitoring of the paired housed pangolins through CCTV cameras.

### 11.2. Routine health care

To improve appetite, digestion and assimilation process in individuals showing partial anorexia, oral liver stimulant drugs/syrups are administered with feed for 15 consecutive days. Multivitamin syrups are also provided as feed supplement periodically. During pregnancy and lactation, the mother is provided with an additional 10% diet along with supplementation of Calcium Vitamin B12 syrup in the feed.

Routine deworming of pangolins has to be carried out with administration of broad spectrum anthelmintic drug e.g. Albendazole @ 20 mg/kg body weight in feed at three months interval. Microscopic examination of faecal samples at the time of arrival and every week afterwards is helpful to find out parasitic infestation to be followed by treatment in positive cases.

Table 5. Therapeutic drugs used in Indian pangolins.

Sl. No.	Drugs	Dose rates	Indications
<b>Anti-microbials</b>			
1	Amikacin	@10mg/kg IM q 12hr for 3 days	Used to treat infections caused by Gram negative bacteria
2	Amoxycillin Clavulanate	@15mg/kg PO, IV q12h	Severe respiratory infections, External wounds, Skin infections
3	Amoxycillin Sulbactam	@10mg/kg IM q 24hr for 3-5days	Used to treat skin, soft tissue infections and mixed bacterial infections
4	Amoxycillin and	@10mg/kg IM q 24hr	Used to treat skin, soft tissue

	Cloxacillin	for 3-5days	infections and mixed bacterial infections
5	Cefotaxime	@10-20 mg/kg PO, SC, IV q12h @50mg/kg IM q24h	Used as a broad spectrum antibiotic to treat a range of bacterial infection
6	Ceftriaxone	@25 mg/kg IM q24h	Used as a broad spectrum antibiotic to treat a range of bacterial infection
7	Ceftriaxone Tazobactam	@25mg/kg IM q24h	Used in upper respiratory tract infections and other bacterial infections
8	Cephalexin	@15mg/kg PO, @10mg/kg IV q12h	Severe respiratory infection, Eye infections, Wounds, Skin infections
9	Enrofloxacin	@5mg/kg SC, 5mg/kg PO q24h @7.5mg-10mg/kg IM q24h	Upper respiratory infection, Wounds, Skin infections
10	Gentamicin	@4mg/kg IM q12hr	Used to treat infections caused by Gram negative bacteria
<b>Topical antimicrobials</b>			
1	Mupirocin ointment	Daily applied locally after cleaning the wound	Used to treat bacterial infections
2	Chloramphenicol powder	Daily applied locally after cleaning the wound	Used to treat bacterial infections
<b>Antiparasitic agents</b>			
1	Albendazole 2.5% liquid	@20mg/kg PO	Used to treat broad range of gastro-intestinal nematode infections
2	Ivermectin 1% injection	@0.2-0.4mg/kg SC	Used to treat both ecto- and endoparasitic infections
3	Fipronil spray	@10mg/kg	Topical treatment against ticks infestation
<b>Gastrointestinal agents</b>			
1	Omeprazole	@1mg/kg IV, PO q24h	Used to treat gastro-intestinal ulcers, Indigestion, gastric acidity as Gastro-protectant
2	Sucralfate	@250-500mg/ pangolin PO q12h before main meal	Used to treat gastro-intestinal ulcers, Indigestion, gastric acidity as gastro-protectant



<b>Anti-allergic drugs</b>			
1	Pheniramine maleate injection	1-2mg /kg IM q12h	Used to treat allergic disorders
<b>Emergency drugs</b>			
1	Prednisolone	@1mg/kg PO q24h	Lung infection, Generalised body edema or inflammation
2	Aminophylline	@2-5mg/kg IV, PO q24h	Respiratory dysfunction, Pneumonia, Emergency bronchodilation
3	Dexamethasone	@0.5mg/kg IV q24h	Anaphylactic reactions, Shock
4	Meloxicam	@0.15 mg/kg SC, PO q24h	Pain, inflammation, hyperthermia, to be used with care
5	Buprenorphine	@0.02 mg/kg IV, SC q6h	Opiate analgesia, acute pain or before painful procedures
6	Ethamsylate	@12-24mg/kg IV, SC q24h	Active bleeding
7	Nebulisation	0.9% NS for 10-15 minutes	Nasal passage congestion, Respiratory difficulty, Pneumonia
<b>Topical ophthalmic drugs</b>			
1	Gentamicin eye drops	One drop TOP q12h	Used to treat bacterial infections of eye
2	Moxifloxacin eye drops	One drop TOP q12h	Used to treat bacterial infections of eye
<b>Vitamins and Minerals</b>			
1	Calcium with Vitamin D3 syrup	0.5ml/kg daily mixed in feed	Supplemented in pregnant and nursing mother's diet
2	B-complex Vitamins with Vitamin C syrup	As per prescription	Used in weakness, debility and as immune-modulator
3	Vitamin K	1.5mg/kg IM q24h	Used in bleeding cases
4	Multivitamin syrup	As per prescription	In case of stress, weakness and debility

## 12. Genetic sampling

Genetic analysis of tissue samples is vital for forensic examination, including species identification and assigning the confiscated samples/animal to the source of origin/most possible geographical locality or habitat. Proper sampling, preservation, packaging and shipping are important to ensure the sample eligible for analysis to produce desirable results. By providing scientific evidences e.g. determining species, geographic origin, relatedness, individual identity and age of samples, the crime cases are prosecuted in court of law for implementation of the Wildlife (Protection) Act, 1972. During legal prosecution of cases in court of law, many times the wildlife cases become weak due to the improper collection, labelling and storing the evidences. Therefore, following the standard procedure for collection of evidences and proper storage of sampled material is pre-requisite and the first step towards legal prosecutions.

### Wildlife forensic sample collection kit

It is advisable to carry an advanced wildlife forensic sample collection kit for proper collection and storage of biological samples/evidences. The kit should contain: sterile disposable gloves, magnifying glass, compass, mask, small note book, sterile plastic vials, ethanol/spirit, forceps, scissors, glass slides, measuring tape/scale, silica, envelopes, white cloth, inkpadd, cello tape, surgical blade, swab, cooling box and FTA card etc.

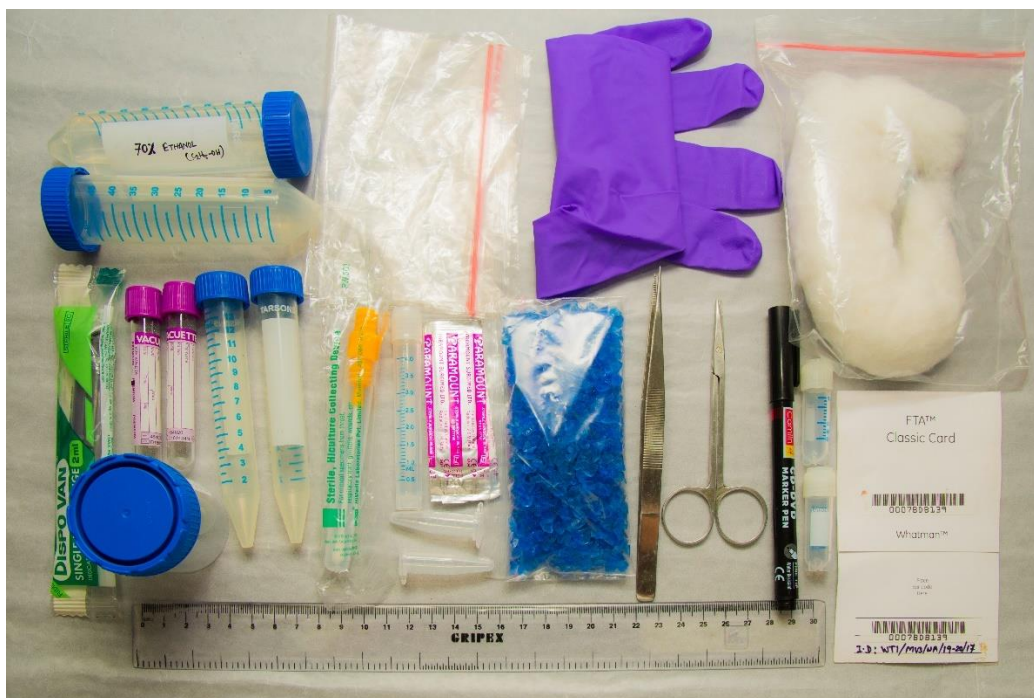

Fig. 19. Wildlife forensic sample collection kit.

### **Collection of tissue and faecal samples**

1. A screw capped and sterile small container of about 100 ml capacity can be used.
2. The container should be filled 1/3<sup>rd</sup> with silica gel/crystal. An absorbent paper or a filter paper should be placed on the top of silica to facilitate absorption of excess moisture from sample.
3. A small piece of tissue (approx. 3-5g) or skin piece (3x3cm) or fresh scat (approx. 15-20 g) then placed on the filter paper (alternatively directly dipped in the ethanol).
4. For collection of wet samples, 2/3<sup>rd</sup> volume of the containers should be filled with ethanol (70% or higher) following dipping the sample in it.
5. To prevent spill over during transportation it should be closed properly to make it airtight. The sample details should be pasted on the container.

### **Collection of blood samples**

1. Uncoagulated blood should be collected in an EDTA vacutainer by a trained veterinarian (refer Health care protocol section) and should be stored at 4°C until handing over to the investigating laboratory. Simultaneously, blood smear for haematological analysis should be prepared on glass slide in field conditions.
2. Alternatively, if fresh blood is not available, coagulated blood spots or stains should be lifted on commercially available FTA (Flinders Technology Associates) classic cards suitable for isolation, purification and staining of nucleic acids. FTA cards are impregnated with the mixture of required reagents which immobilize nucleic acids in the card. They can be used for long term storage at room temperature.
3. FTA cards can be used for collection of any type of biological fluids like semen, blood spots and fluids from dead tissues.

### **Collection of hair and scale samples**

Indian pangolin do not shed hair or scales. Hair should be plucked using tweezers with gloved hand. About 20-30 hairs with follicles should be plucked. Hairs should be handled by their tip, not from root to be put into airtight collection tube in an evidence bag to be sealed and labelled before being sent to laboratory. About 2-5 scales as samples can be directly collected into an airtight container from seized scales and sent for forensic examination following similar process mentioned above.

### **Representative sampling of miscellaneous seizures**

At times, law enforcement agencies confiscate large volumes of mixed wildlife articles including pangolin body parts. Such seizures need to be evaluated carefully in consultation with experts by separating and weighing every type of pangolin articles (scales, carcass and body parts) to know the number of individuals killed.

Representative genetic sampling are of help, in identification of pangolin body parts, species and in detecting number of individuals.



Fig. 20. Collection of genetic sample, (top-left to right) a. faecal, b. blood in vial, c. blood in FTA card, (bottom-left to right) d. hair and e. scales.

### Packaging and dispatch

Packaging, sealing and dispatching of samples are important tasks which should be carried out following the standard procedures. All types of collected samples should have details of seizure/samples as per the Table below along with a copy of FIR in case of legal case. These samples need to be sealed with a departmental seal at all four corners of the packet, vials or container. Seizures then may be sent for species and individual identification to a certified and designated Wildlife Forensics laboratory.

Table 6. Minimum sampling details for labelling on the container.

Date	
Field ID	
Place (Beat, Forest Division, Forest type and GPS coordinate)	
Sample type	
Species/Sex/Body weight (for whole body seizure)	
Name of collector, designation	



## **Address of designated laboratories for genetic analysis**

### 1. Director

Zoological Survey of India,  
Prani Vigyan Bhawan M-Block,  
New Alipore Kolkata-700053;  
Fax: 91-33-24008595  
Email: [director@zsi.gov.in](mailto:director@zsi.gov.in)

### 2. Director

Botanical Survey of India  
CGO Complex, 3rd MSO Building,  
Block F (5th and 6th Floor), DF Block,  
Sector I, Salt Lake City, Kolkata - 700 064  
Office: +91-33- 23344963/23346040  
Email: [hq@bsi.gov.in](mailto:hq@bsi.gov.in)

### 3. Director

Wildlife Institute of India, Post Box 18,  
Dehradun 248001, Uttarakhand  
Email: [dwii@wii.gov.in](mailto:dwii@wii.gov.in)  
Tel: +91 135-2640910(D),  
Office: +91 135-2640114 - 15.  
Fax: +91 135-2640117

### 4. Scientist-in-charge

Laboratory for the Conservation of Endangered Species (LaCONES)  
Centre for Cellular and Molecular Biology  
162 Pillar, PVNR Expressway, Attapur Ring Road,  
Hyderguda, Hyderabad 500 048  
Office: +91-40-24006441/43/40  
Fax: +91-40-24006441  
Email: [lacones@ccmb.res.in](mailto:lacones@ccmb.res.in)

### 5. Forest Research Institute

Deemed to be University,  
Dehradun, Kaulagarh Road,  
PO. I.P.E. 248195  
Uttarakhand - Dehradun  
Office: +91-135-2224439  
Email: [enquires@fridu.edu.in](mailto:enquires@fridu.edu.in)

## 13. Release requirements

---

Several Indian pangolins are rescued/confiscated every year. But in most of the cases, the capture locations of these pangolins are not known as these individuals are transported over long distances and change several hands. Almost all of these rescued/ confiscated Indian pangolins are released back to the wild without any post-release monitoring.

Pangolins leave several field signs including burrows (feeding and resting), footprints and tracks, tail drags, claw marks, and feeding signs (e.g., disturbed ant nests and termitaria). However, distinguishing these signs from that of other species and/or sympatric pangolin species is difficult and in many cases impossible based on visual signs only. Post-release monitoring of pangolin is very challenging and monitoring solely based on indirect signs is not reliable.



Fig. 21. Field signs of Indian pangolin, a. living burrows (top-left), b. trial burrow (top right), c. feeding burrow (bottom left), d. scale print (bottom right).

Telemetry is an important tool to gather crucial information about the released pangolin such as site selection, dispersal and survival. Telemetry combined with monitoring of burrows with the help of infrared (IR) flash camera traps provides key information on the activity and health of the released pangolin. Telemetry is an important tool to increase the survival rates of the rescued/confiscated pangolins released into the wild.

### **13.1. Selection of site for release**

1. In the case of a confiscated pangolin with known origin (caught from the known forest area), the captured animal should be released deeper part of nearby protected forest avoiding road, railways and human settlements with additional protection measures like increased patrolling and intensive monitoring.

For pangolins with unknown capture locations, the following points are important for selecting a release site:

2. Site selection for release should be done after discussion with Forest officials and local experts.
3. Awareness level among locals, hunting/poaching incidences in past and other factors should be considered for selection of release site.
4. Indian pangolin is a 'habitat generalist' species and it can live in many terrestrial ecosystems, but with few important habitat requirements. The selected habitat must have loose soil substratum with rocks and boulders, perennial water source and abundant ants and termite's availability. Without these habitat requirements, the released pangolin has a limited chance of survival. Sites with known abandoned pangolin burrows can be preferred.
5. Release spots should be kept confidential and should preferably in a protected area like a wildlife sanctuary, tiger reserve, national park or similar. Release should be done in the deepest part of that sanctuary or reserved forest land and away from any major roads, railway tracks and human settlement.

### **13.2. Documentation for release:**

Obtaining written permission from the concerned Divisional Forest Officer/Chief Wildlife Warden and from the concerned court in case of pangolins confiscated from illegal trade is required before releasing the pangolin. The release must be done after health certification by a veterinarian and in presence of senior forest officials of the concerned area. Required legal documentation, health certification, measurements of weight and length, photo and video documentation of the pangolin should be meticulously maintained for future reference.



### **13.3. Release recommendations:**

#### **Option 1 (With known origin):**

In the case of a confiscated healthy pangolin with known origin from a determined forest, it should be released back to wild without any quarantine or rehabilitation process after completing a health check up by veterinarian and required documentation with additional protection measures like increased patrolling and intensive monitoring.

#### **Option 2 (Without known origin, release without tagging)**

1. In case of confiscated pangolin without any identified origin, the species of the rescued/confiscated pangolin should be identified in consultation with experts and only considered for release in their existing distribution range. Exotic pangolin species should never be released, rather they may be handed over to Zoos having experience with pangolin keeping.
2. The pangolin should be considered for release only when it is fit for the same, with proper feeding and hydration and after examined by a veterinarian.
3. In cases where the pangolin is NOT fitted with transmitters, the pangolin must be marked for individual identification to facilitate post-release monitoring. For individual marking, dorso-lateral scales can be coloured, making a unique pattern. This pattern should be identical for both the flanks. Black colour should be used for the purpose as it is easily detected by both monochromatic (black and white) and colour images produced by different types of camera traps during post- release monitoring.

#### **Option 3 (Without known origin; release with transmitter tagging)**

1. If the resources are available for telemetry, tagging the pangolin with unknown origin with transmitter is recommended to facilitate post release monitoring.
2. The individuals weighing more than 5 kg are suitable for tagging. This is crucial as with smaller individuals the size/weight of the tag can interfere with their natural activities.
3. The transmitter (tag) should weigh less than 4% of the pangolin's body weight.
4. The tag should be fitted on the non-vascular part of the dorsal scales of the tail base. The form factor (shape, size and thickness) of the tag and the placement must be such that it does not interfere with the pangolin's movement while entering/exiting the burrow.
5. In case of a female pangolin, as mother carries the young on her back, the tag should be placed such that the young one can latch securely on the mothers back. Mother and baby should be released together. The attachment for the tag should not be rigid and should allow the tag to move (sideways) freely.
6. For pangolins that are treated for injuries/disease, it is advisable to tag such individuals before releasing them.

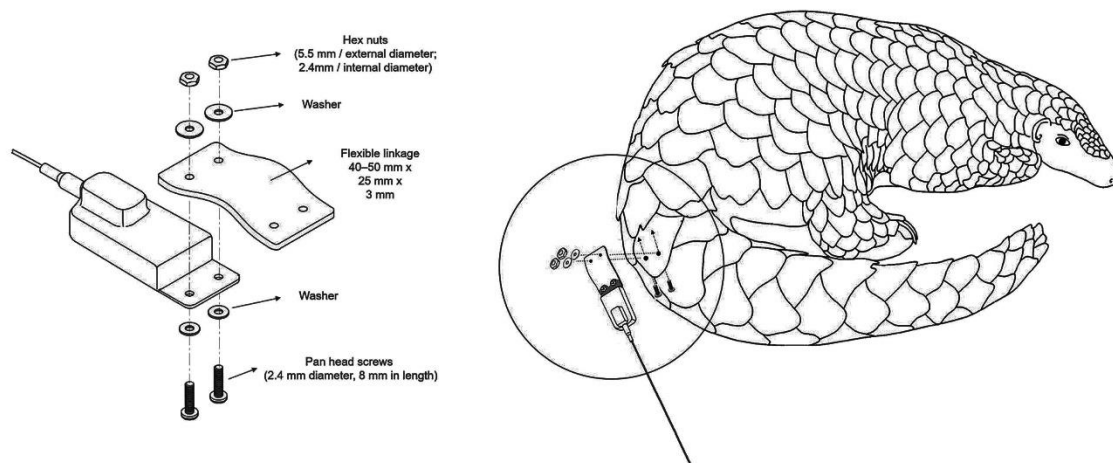


Fig. 22. a. Method of attaching transmitter to pangolin (top), b. transmitter tagged Indian pangolin (bottom).

### 13.4. Post-release monitoring

After releasing the rescued pangolin into its natural habitat, post-release monitoring must be done to determine its health and survival.

1. They can be monitored by searching their sign such as living burrow, feeding sign and trail marks. Their living and feeding burrows are almost circular, smoothly surfaced and claw marks can be seen on its surface. Their burrows can be confirmed by the presence of faecal material or scale/footprint marks outside of the burrow.

2. Camera traps must be placed about 6-8 feet away from the entrance of the active burrow. As pangolins are nocturnal and can get disturbed by camera flash, Infra-Red (IR) camera traps should be used for monitoring the burrows.
3. Images and videos from camera traps allow us to monitor the health of the pangolin, activity patterns, behaviour and interactions with other pangolins.

In the case of transmitter tagged pangolin, it should be monitored intensively with the help of radio receivers.

1. The tagged pangolin is tracked every day for the first two to three months. This is important, as initially, these individuals can cover large distances and regularly move out of the radio receiver's range.
2. By triangulating the radio signals, the pangolin is located and the GPS location of the burrow is marked. A timeline is maintained to track their movement over time.
3. In case of a young/sub-adult individual, it should be weighed and examined once a week for three months post-release. In case of an adult pangolin, it should be weighed and examined once a week for the initial one month and then once a month for the rest of the duration. This helps in the early detection of weakness and injuries in the released pangolin which may need veterinary interventions.




Fig. 23. Post-release monitoring, a. monitoring by camera trap (left), b. monitoring by radio receivers (right).



## 14. Suggested reading

---

1. Aditya, V., Goswami, R., Mendis, A. and Roopa, R. (2021) Scale of the issue: Mapping the impact of the COVID-19 lockdown on pangolin trade across India. *Biological Conservation*, 257, p.109136.
2. Algewatta, H. R., Perera, P., Karawita, H., Dayawansa, N., Manawadu, D., and Liyanage, M. (2021) Updates on the Morphometric Characterization of Indian Pangolin (*Manis crassicaudata*) in Sri Lanka. *Animals*, 11(1): 25.
3. Anonymous (2017) Procedure for handling and the placement of confiscated pangolins (V1). Save Vietnam's Wildlife and Cuc Phuong National Park. [http://svw.vn/wp-content/uploads/2017/05/NotesOnPangolinHandling E. pdf](http://svw.vn/wp-content/uploads/2017/05/NotesOnPangolinHandling_E.pdf) [Accessed online 31 Jun. 2021].
4. Anonymous (2018) First Responders Manual, African ground pangolin *Smutsia temmenckii*. NARREC and HumaneLABS. pp-1-21.
5. Gaur A., Umapathy, G., Vasudevan, K., Sontakke, S., Rao, S., Goel, S., Kumar, D., Gupta, B.K., Singh D.N. and Kumar, T.A. (2017) Manual for Biological Sample Collection and Preservation for Genetic, Reproductive and Disease Analyses. Central Zoo Authority and Laboratory for the Conservation of Endangered Species (LaCONES) CSIR- Centre for Cellular and Molecular Biology. pp 1-58.
6. Kumar, V.P., Rajpoot, A. and Rasaily, S.S. (2020) Peril for pangolins: An evaluation of the status of the last decade in India. *Forensic Science International: Reports*, 2, p.100058.
7. Mahmood, T., Mohapatra, R. K., Perera, P., Irshad, N., Akrim, F., Andleeb, S., Waseem, M., Sharma, S. and Panda, S. (2020) Indian Pangolin *Manis crassicaudata* (Geoffroy, 1803). In: Challender, D.W.S., Nash, H.C., Waterman, C. (Eds) *Pangolins, Science, Society and Conservation*. Academic Press. London, UK. pp. 71-88.
8. Mohapatra, R.K. and Mishra, A. K. (2014) Indian pangolin rescued and released at Athagarh forest division, Cuttack, Odisha. *Indian Forester*, 140(10): 1048.
9. Mohapatra, R.K. and Panda, S. (2014) Behavioural descriptions of Indian pangolins (*Manis crassicaudata*) in captivity. *International Journal of Zoology*, Volume 2014, Article ID 795062: 1-7.
10. Mohapatra, R.K. and Panda, S. (2014a) Husbandry, behaviour and conservation breeding of Indian pangolin. *Folia Zoologica*, 63(2): 73-80.
11. Mohapatra, R.K., Banik, A., Sahu, S.K., Panda, S. and Dangar, T.K. (2020) Parasites and bacteria associated with Indian pangolins *Manis crassicaudata*

- (Mammalia: Manidae). *Global Ecology and Conservation*. 23:p.e01042: 1-9.
12. Mohapatra, R.K., Panda, S. and Nair, M. V. (2015) On mating behaviour of captive Indian pangolin (*Manis crassicaudata*). *Taprobanica*. 7(1): 57-59.
  13. Mohapatra, R.K., Panda, S. and Sahu, S.K. (2018) On the gestation period of Indian pangolins *Manis crassicaudata* in captivity. *Biodiversity International Journal*, 2(6).559-560.
  14. Mohapatra, R.K., Panda, S., Acharjyo, L.N., Nair, M.V. and Challender, D.W.S. (2015) A note on the illegal trade and use of pangolin body parts in India. *Traffic Bulletin*, 27(1): 33-40.
  15. Mohapatra, R.K., Panda, S., Nair, M.V. and Acharjyo, L.N. (2016) Check list of parasites and bacteria recorded from pangolins (*Manis* sp.). *Journal of Parasitic Diseases*. 40(4): 1109-1115.
  16. Mohapatra, R.K., Panda, S., Sahu, S.K., Roy, P.K., Purohit K.L. and Mishra, C.R. (2013) Hand-rearing of rescued Indian pangolin (*Manis crassicaudata*) at Nandankanan Zoological Park, Odisha. In: Acharjyo, L. N. and Panda, S. (Eds.) *Indian Zoo Year Book*. Vol. VII. pp. 17-25.
  17. Perera, P., Algewatta, H. R. and Karawita, H. (2020). Protocols for recording morphometric measurement of Indian Pangolin (*Manis crassicaudata*). *MethodsX*, 7, 101020.
  18. Priyambada, P., Jabin, G., Singh, A., Ghosh, A., Singh, S.K., Chatterjee, M., Venkatraman, C., Chandra, K., Sharma, L.K. and Thakur, M. (2021) Digging out the keys in the heap of seized pangolin scales: up scaling pangolin conservation using wildlife forensics. *Forensic Science International*, 323, p.110780.
  19. Singh, A., Priyambada, P., Jabin, G., Singh, S.K., Joshi, B.D., Venkatraman, C., Chandra, K., Sharma, L.K. and Thakur, M., 2020. Pangolin Indexing System: implications in forensic surveillance of large seizures. *International Journal of Legal Medicine*, 134(5):1613-1618.
  20. Sun, N.C.M., Pei, K.J.C. and Lin, J.S. (2019) Attaching tracking devices to pangolins: A comprehensive case study of Chinese pangolin *Manis pentadactyla* from South-eastern Taiwan. *Global Ecology and Conservation*, 20, p.e00700.
  21. Wicker, L.V., Cabana, F., Chin, J.S., Jimerson, J., Lo, F.H., Lourens, K., Mohapatra, R.K., Roberts, A., and Wu S. Captive husbandry of pangolins: lessons and challenges (2019) In: Challender, D.W.S., Nash, H.C., Waterman, C. (Eds) *Pangolins, Science, Society and Conservation*. Academic Press. London, UK. pp 443-459.

## LIST OF CONTRIBUTORS

Dr. Rajesh Kumar Mohapatra  
Biologist, Nandankanan Zoological Park  
Bhubaneswar, India  
Email: [biologist.nkzp@gmail.com](mailto:biologist.nkzp@gmail.com)  
Phone: +91-9937563742

Dr. Sarat Kumar Sahu  
Veterinary Officer,  
Nandankanan Zoological Park  
Bhubaneswar, India  
Email: [sahu.sarat77@gmail.com](mailto:sahu.sarat77@gmail.com)  
Phone: +91-9861180680

Mr. Aditya Joshi  
Head-Conservation Research  
Wildlife Conservation Trust  
Nagpur, India  
Email: [aditya@wctindia.org](mailto:aditya@wctindia.org)  
Phone: +91 9923206713

Dr. Chetan D. Vanjari,  
Wildlife Veterinarian  
RESQ Wildlife Treatment Transit Center,  
Pune, India  
Email: [vanjarichetan18@gmail.com](mailto:vanjarichetan18@gmail.com)  
Phone: +91 77090 82011

Mr Bhaskar Bhandari  
Wildlife Biologist  
Wildlife Institute of India  
Dehradun, India  
Email: [bhandari.bhaskar123@gmail.com](mailto:bhandari.bhaskar123@gmail.com)  
Phone: +91-88781 81806

Dr. Mukesh Thakur  
Scientist C, Zoological Survey of India  
Kolkata, India  
Email: [thamukesh@gmail.com](mailto:thamukesh@gmail.com)  
Phone: +91-8171051282

Dr. Priyan Perera  
Director, Center for Sustainability  
Department of Forestry and Environmental  
Science  
University of Sri Jayewardenepura, Sri Lanka  
E-mail: [priyan@sjp.ac.lk](mailto:priyan@sjp.ac.lk)  
Phone: +94-718656457

Mr Aristo Mendis  
Analyst Lead, Counter Wildlife Trafficking  
Program,  
Wildlife Conservation Society,  
Bangalore, India  
Email: [aristo@wcsindia.org](mailto:aristo@wcsindia.org)  
Mobile: +91 8454050914

Dr. Vikram Aditya  
Postdoctoral research associate  
Ashoka trust for research in ecology and the  
environment (ATREE)  
Bangalore, India  
Email: [vikram.aditya@atree.org](mailto:vikram.aditya@atree.org)  
Phone: +91 9663188484

Ms Gargi Sharma  
Deputy Programme Manager, Counter Wildlife  
Trafficking  
Wildlife Conservation Society,  
Bangalore, India  
Email: [gargi.sharma@wcsindia.org](mailto:gargi.sharma@wcsindia.org)  
Phone: +91-7701819461

Mr Bhau Katdare  
President, Sahyadri Nisarga Mitra  
Chiplun, Maharashtra, India  
Email: [sahyadricpn@gmail.com](mailto:sahyadricpn@gmail.com)  
Phone: +91 9423831700

Mr Anirban Chaudhuri  
Regional Manager - East  
Counter Wildlife Trafficking Program  
Wildlife Conservation Society,  
Bangalore, India  
Email: [anirbanc@wcsindia.org](mailto:anirbanc@wcsindia.org)  
Phone: +91-9674665602

Mr Manoj Mahapatra  
Director, Nandankanan Biological Park  
Bhubaneswar, India  
Email: [nandankananzoo@yahoo.com](mailto:nandankananzoo@yahoo.com)  
Phone: +91 9437050310





PRODUCED ON THE OCCASION OF “AZADI KA AMRIT MAHOTSAV -2021”

### **CENTRAL ZOO AUTHORITY**

B-1 Wing, 6th Floor,  
Pt. Deen Dayal Antyodaya Bhawan,  
CGO Complex, Pragati Vihar,  
New Delhi, Delhi 110003  
Phone: +91-011-24367851/52  
Fax: +91-011-24367849  
Email: [cza@nic.in](mailto:cza@nic.in)  
Website: [www.cza.nic.in](http://www.cza.nic.in)

### **NANDANKANAN BIOLOGICAL PARK**

Mayur Bhawan Saheed Nagar,  
Bhubaneswar-751007, (Odisha), India  
Phone: +91-674-2547850  
Fax: +91-674-2547840  
E-mail: [director@nandankanan.org](mailto:director@nandankanan.org)  
Website: [www.nandankanan.org](http://www.nandankanan.org)

