

# IN A WORLD OF ITS OWN



## Aleira®

## Researched Respiratory Support

Researched and Proven as an aid in controlling IAD and RAO<sup>[1]</sup>

Recommended in the ACVIM Consensus Statement on Respiratory Disease<sup>[2]</sup>

Not all Omega 3's are the same; use the Researched and Recommended 1500mg Purified DHA formulation.  
Your Clients Deserve The Best in a Non-Pharmaceutical Solution.

### Aleira – Using the Best Matters

References:  
[1] Nogradi N, Couetil LL, Messick J, Stochelski MA, Burgess JA. Evaluation of an Omega-3 Fatty Acid Containing Feed Supplement in the Management of Horses with Chronic Lower Airway Inflammatory Diseases. J Vet Intern Med 2015; 29:299-306.  
[2] Couetil LL, Cardwell J.M, Gerber V, Lavoie J.-P, Leguillette R, Richard E.A. Inflammatory Airway Disease of Horses. ACVIM Consensus Statement J of Vet Intern Med 2016; 30:503-515 p. 508-510.



Arenus Animal Health | 866-791-3344 | www.arenus.com

Check with Arenus on how Aleira can help your equine patients effectively cope with respiratory and immune function disorders. See how Aleira can help you to reduce or eliminate pharmaceutical interventions.



# EQUINE VETERINARY EDUCATION

American Edition | March 2023

EQUINE VETERINARY EDUCATION/AMERICAN EDITION

VOLUME 35 NUMBER 3

MARCH 2023



The official journal of the American Association of Equine Practitioners, produced in partnership with BEVA.

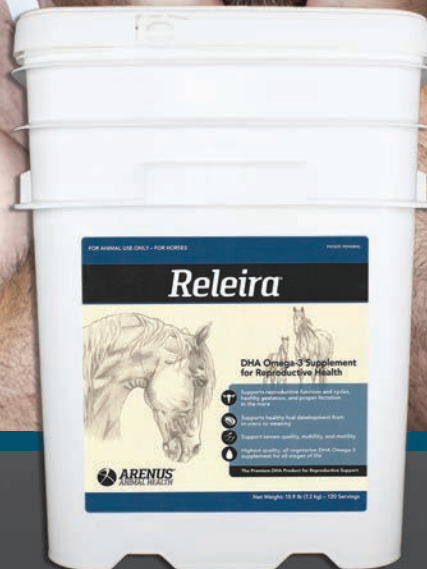### IN THIS ISSUE:

- A Q&A with the president: Equine veterinary sustainability
- Genipin treatment of equine palatal dysfunction: A preliminary study of safety and efficacy
- What is the most effective treatment in horses with chorioptic mange?



# DON'T LEAVE YOUR BREEDING PROGRAM UP TO CUPID

REDUCE  
THE  
STRUGGLE.



## Releira®

The only product researched to improve conception rates in difficult to breed mares.

Take your breeding program to the next level with this research-backed Omega-3 formula providing reproductive health benefits for mares, stallions, and foals. Releira addresses common fertility issues with a readily absorbed, vegetarian algae source.

Not only reduce the cycles to conception for your difficult mares but improve semen quality in those stallions with morphology and motility issues. Research proven to improve cognitive abilities in the newborn foal.

References:

[1] Brendemuehl JP, Kopp K, Altman J. Uterine Inflammatory Response to Frozen Semen is attenuated by Oral Supplementation of a Blend of Omega-3 Fatty Acids (Algal DHA and Flax Seed) in Susceptible and Resistant Mares. Submitted to Theriogenology. [2] Brendemuehl JP, Altman J, Kopp K. Influence of dietary algal N-3 fatty acids on breeding induced inflammation and endometrial cytokine expression in mares bred with frozen semen. J Equine Vet Sci. 2014; 34(1): 123-124. [3] A.M. Adkin, A.V. Muniz, C.J. Mortensen, L.K. Warren. Maternal fatty acid supplementation influences memory and learning ability in yearling and 2-year-old horses. J Equine Vet Sci. 2015; 35: 418-436. [4] A.M. Adkin, L.K. Warren, C.J. Mortensen, J. Kivipelto. Maternal supplementation of docosahexaenoic acid and its effect on fatty acid transfer to the foal (longitudinal study). Equine Vet Sci. 2013; 33: 321-329. [5] A.M. Adkin, L.K. Warren, and C.A. McCall. Effect of maternal docosahexaenoic acid supplementation on behavior and cognitive development in nursing foals. J Equine Vet Sci. 2013; 33: 321-399.

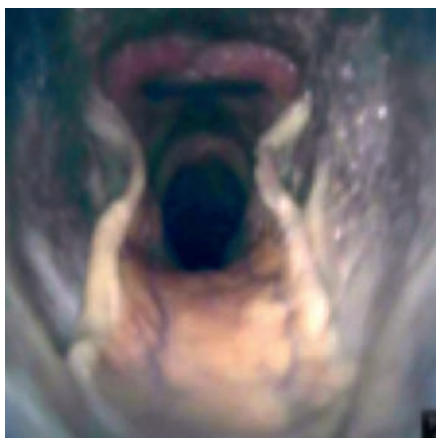
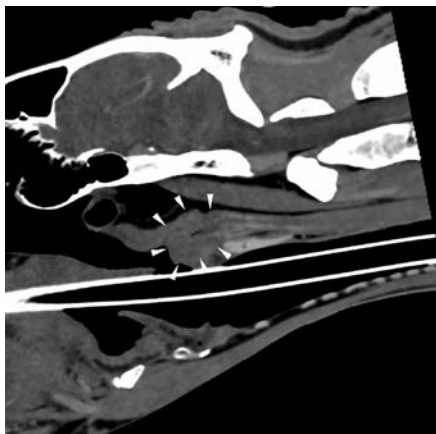


Arenus Animal Health | 866-791-3344 | www.arenus.com

Ask your Veterinary Solution Specialist how Releira can take your patient's breeding program to the next level.



CONTENTS



**AAEP NEWS** In this issue

A Q&A with the president: Equine veterinary sustainability ..... III  
 Acquire expert insights during 2023 Virtual Wednesday Round Tables ..... IV  
 Conquer foot lameness with hands-on training at Focus on Podiatry ..... IX

**Highlights of Recent Clinically Relevant Papers** – S. WRIGHT ..... 114

**Editorial** – Advances in imaging of the equine distal limb: 2017–2022  
 EVJ, EVE and VRU updates – T. MAIR ..... 116

**Case Reports**

Spontaneous bilateral superficial digital flexor tendon rupture in a horse with guttural pouch empyema and suspected purpura hemorrhagica  
 K. J. MACKINNON, J.-Y. TAN, S. W. SCHAAL and J. L. DAVIES ..... 117

Leiomyoma of the proximal cervical oesophagus in a horse – J. FAULKNER,  
 L. VLAMINCK, L. GEERINCKX, E. RAES and K. VANDERPERREN ..... 118

Acquired large colon strangulating inguinal herniation in two Arabian foals  
 O. HAION, A. J. TATZ, R. DAHAN and G. KELMER ..... 119

Duodenoduodenal intussusception in a 16-year-old German Warmblood mare  
 R. MATHYS, C. GRAUBNER, T. KAIPONEN, L. GRAU-ROMA,  
 E. VAN DER VEKENS, C. KOCH and H. BRÜNISHOLZ ..... 120

Standing jejunal enterotomy for resolution of an ileal impaction  
 S. BOORMAN and F. CALDWELL ..... 121

Use of barbed suture for thoracoscopic repair of diaphragmatic hernias: Three cases  
 L. KAMUS, P. RUZICKOVA, P. PIAT, P. TRENCART and A. A. BONILLA ..... 124

Ultrasonographic identification of mesenteric lipomatosis in a Shetland mare with recurrent colic episodes – H. LESCA, A. FAIRBURN, L. E. FITZHARRIS and T. S. MAIR ..... 128

Three cases of olecranon fracture repair in the standing horse  
 P. JIMENEZ-RIHUETE and B. O'MEARA ..... 131

**Clinical Commentaries**

Ileal impactions: How to proceed when a ventral midline celiotomy is not an option?  
 J. WILLIAMS ..... 122

Benefits of equine thoracoscopy – K. MARCHANT and D. A. HENDRICKSON ..... 125

Colic horse: A diagnostic challenge – M. MAGRI ..... 129

Management of ulna fractures in adult horses – J. A. AUER, A. E. FÜRST,  
 R. BETTSCHART-WOLFENBERGER and M. HAAB ..... 132

**Original Articles**

Ultrasonography can be used to predict the location of manica flexoria tears in horses  
 M. HIBNER-SZALTY, F. CAVALLIER, F. CANTATORE, J. M. WITHERS  
 and M. MARCATILI ..... 139

Measurement of ANP, BNP and endothelin-1 concentrations in jumping horses with heart valvular regurgitation and their correlation with the dimensions of heart structures  
 S. SADEGHIAN CHALESHTORI, M. R. MOKHBER DEZFOULI,  
 M. H. NAJIZADEH and G. R. NIKBAKHT BORUJENI ..... 140

Genipin treatment of equine palatal dysfunction: A preliminary study of safety and efficacy  
 H. M. DILLON, E. J. O. O'BRIEN and C. FEENEY ..... 141

Blinded comparison of mirror and endoscopic oral examination in the horse: Sensitivity, specificity and observer agreement – N. E. CHIERO, J. D. REISWIG, C. E. GRIFFIN,  
 K. J. PANIGRAHI and A. K. GARDNER ..... 142

**Review Articles**

Postoperative exercising endoscopy of the equine upper respiratory tract  
 S. Z. BARAKZAI ..... 143

Melanocortin-1 receptor influence in equine opioid sensitivity  
 E. K. BACON, C. G. DONNELLY, R. R. BELLONE, C. J. FINNO and B. D. VELIE ..... 152

**Critically Appraised Topic**

What is the most effective treatment in horses with chorioretinal mangel?  
 J. KONDRATJEVA, D. COMBARROS, C. PRESSANTI and M. C. CADIERGUES ..... 163

**Advertisers' Index** ..... 123

## American Association of Equine Practitioners

4033 Iron Works Parkway  
Lexington, KY 40511  
TEL (800) 443-0177 • (859) 233-0147  
FAX (859) 233-1968  
EMAIL [aaepoffice@aaep.org](mailto:aaepoffice@aaep.org)  
[aaep.org](http://aaep.org)

To access our website, go to [aaep.org](http://aaep.org), select LOGIN, then enter your email and password. If you have difficulty logging in or have forgotten your password, please call or email the office.

### AAEP Officers

Rob Franklin, DVM, *President*  
Katherine Garrett, DVM, *President-Elect*  
Tracy Turner, DVM, *Vice President*  
Amy Grice, VMD, *Treasurer*  
Emma Read, DVM, *Immediate Past-President*

### AAEP Staff

David Foley, CAE, *Executive Director*  
[dfoley@aaep.org](mailto:dfoley@aaep.org)  
Lori Rawls, *Director of Meetings & Operations*  
[lrawls@aaep.org](mailto:lrawls@aaep.org)  
Sally J. Baker, APR, *Director of Marketing & Public Relations* • [sbaker@aaep.org](mailto:sbaker@aaep.org)  
Keith Kleine, *Director of Industry Relations*  
[kkleine@aaep.org](mailto:kkleine@aaep.org)  
Nick Altvies, *Director of Membership*  
[naltvies@aaep.org](mailto:naltvies@aaep.org)  
Kevin Hinchman, *Director of Information Technology*  
[khinchman@aaep.org](mailto:khinchman@aaep.org)  
Karen Pautz, *Director of Education*  
[kpautz@aaep.org](mailto:kpautz@aaep.org)  
John Cooney, *Publications Coordinator*  
[jcooney@aaep.org](mailto:jcooney@aaep.org)  
Giulia Garcia, *Communications Coordinator*  
[ggarcia@aaep.org](mailto:ggarcia@aaep.org)  
Megan Gray, *Member Concierge*  
[mgray@aaep.org](mailto:mgray@aaep.org)  
Dana Kirkland, *Sponsorship & Advertising Coordinator* • [dkirkland@aaep.org](mailto:dkirkland@aaep.org)  
Deborah Miles, *Trade Show Coordinator*  
[dmiles@aaep.org](mailto:dmiles@aaep.org)  
Shelby Mosley, *Student Programs Coordinator*  
[smosley@aaep.org](mailto:smosley@aaep.org)  
Jayson Page, *Office Manager*  
[jpage@aaep.org](mailto:jpage@aaep.org)  
Katie Porter, *EDCC Communication Manager*  
[kporter@aaep.org](mailto:kporter@aaep.org)  
Paul Ransdell, *Senior Development Officer*  
[pransdell@foundationforthehorse.org](mailto:pransdell@foundationforthehorse.org)  
Carey Ross, *Scientific Publications Coordinator*  
[cross@aaep.org](mailto:cross@aaep.org)  
Sue Stivers, *Executive Assistant*  
[sstivers@aaep.org](mailto:sstivers@aaep.org)  
Amity Wahl, *Communications & Technology Coordinator*  
[awahl@aaep.org](mailto:awahl@aaep.org)  
Kristin Walker, *Membership & Event Services Coordinator*  
[kwalker@aaep.org](mailto:kwalker@aaep.org)  
Summer Wyatt, *Development Officer*  
[swyatt@foundationforthehorse.org](mailto:swyatt@foundationforthehorse.org)  
Elaine Young, *Development & Communications Coordinator*  
[eyoung@foundationforthehorse.org](mailto:eyoung@foundationforthehorse.org)

### Published monthly. Deadlines are the seventh of the preceding month.

Address advertising inquiries to Dana Kirkland  
(859) 233-0147 / [dkirkland@aaep.org](mailto:dkirkland@aaep.org)

**AAEP Mission Statement:** To improve the health and welfare of the horse, to further the professional development of its members, and to provide resources and leadership for the benefit of the equine industry.

# EQUINE VETERINARY EDUCATION

## AMERICAN EDITION

### MARCH 2023 • VOLUME 35 • NUMBER 3

#### Editor (UK)

T. S. Mair, BVSc, PhD, DEIM, DESTS,  
DipECEIM, MRCVS

#### Editors (USA)

N. A. White II, DVM  
W. D. Wilson, MRCVS

#### Deputy Editors

Y. Elce  
P.R. Morresey  
A.G. Raftery  
C. Riggs  
P.A. Wilkins

#### Management Group

D. Foley  
T. S. Mair  
N. A. White  
W. D. Wilson  
J. L. N. Wood

#### Management Board

A. R. S. Barr      S. E. Palmer  
E. Contino      N. A. White (*US Editor*)  
D. Foley      S. White  
D. Mountford      W. D. Wilson (*US Editor*)  
T. S. Mair (*Editor*)      J. L. N. Wood (*Chairman*)

#### Assistant Editors

F. Andrews      S. Love  
D. Archer      M.L. Macpherson  
F.T. Bain      M.J. Martinelli  
A.R.S. Barr      I.G. Mayhew  
A. Blikslager      M. Mazan  
M. Bowen      C.W. McIlwraith  
M. Campbell      B. McKenzie  
V. Coudry      R. Moore  
A. Dart      M. Oosterlinck  
J.-M. Denoix      A. Parks  
T. Divers      S. Puchalski  
P. Dixon      H. Schott  
W. Duckett      J. Schumacher  
B. Dunkel      S. Semevelos  
S. Dyson      J. Slater  
T. Fischer      B. Sponseller  
D. Freeman      C. Sweeney  
T. Greet      H. Tremaine  
R. Hanson      K. Wareham  
P. Harris      J. S. Weese  
M. Hillyer      R. Weller  
M. Holmes      C. Yao  
N. Hudson  
P. Johnson      **Ex-officio**  
P.T. Khambatta      J. Cooney  
J.-P. Lavoie

*Equine Veterinary Education* is a refereed educational journal designed to keep the practicing veterinarian up to date with developments in equine medicine and surgery. Submitted case reports are accompanied by invited reviews of the subject (satellite articles) and clinical quizzes. Tutorial articles, both invited and submitted, provide in-depth coverage of issues in equine practice.

*Equine Veterinary Education* (American Edition ISSN 1525-8769) is published monthly by the American Association of Equine Practitioners, an international membership organization of equine veterinarians. Office of publication is 4033 Iron Works Parkway, Lexington, KY 40511. Periodicals Postage paid at Lexington, KY and additional mailing office. POSTMASTER: Send address changes to: *Equine Veterinary Education*, 4033 Iron Works Parkway, Lexington, KY 40511.

Communications regarding editorial matters should be addressed to: The Editor, *Equine Veterinary Education*, Mulberry House, 31 Market Street, Fordham, Ely, Cambridgeshire CB7 5LQ, UK. Telephone: 44 (0) 1638 720250, Fax: 44 (0) 1638 721868, Email: [sue@evj.co.uk](mailto:sue@evj.co.uk).

All manuscript submissions for the journal should be submitted online at <http://mc.manuscriptcentral.com/eve>. Full instructions and support are available on the site and a user ID and password can be obtained on the first visit. If you require assistance, click the Get Help Now link that appears at the top right of every ScholarOne Manuscripts page.

All subscription inquiries should be addressed to: Subscriptions Department, AAEP, 4033 Iron Works Parkway, Lexington, KY 40511, Telephone: (859) 233-0147, Email: [jcooney@aaep.org](mailto:jcooney@aaep.org). Subscription rates: AAEP annual membership dues include \$40 for a subscription to *Equine Veterinary Education*. Other subscriptions at \$151.80. Single copies \$37.50.

Canadian Subscriptions: Canada Post Corporation Number 40965005. Send change address information and blocks of undeliverable copies to AAEP, 1415 Janette Avenue, Windsor, ON N8X 1Z1, Canada.

© World copyright by Equine Veterinary Journal Ltd 2023.

The authors, editors and publishers do not accept responsibility for any loss or damage arising from actions or decisions based on or relying on information contained in this publication. Responsibility for the treatment of horses under medical or surgical care and interpretation of published material lies with the veterinarian. This is an academic publication and should not be used or interpreted as a source of practical advice or instruction.

The American Association of Equine Practitioners cannot accept responsibility for the quality of products or services advertised in this journal or any claim made in relation thereto. Every reasonable precaution is taken before advertisements are accepted, but such acceptance does not imply any form of recommendation or approval.

All companies wishing to advertise in *Equine Veterinary Education*, American edition, must be current AAEP exhibitors. AAEP retains the right, in its sole discretion, to determine the circumstances under which an exhibitor may advertise in this journal. While all advertisers must comply with applicable legal guidelines, Compounding Pharmacies are specifically directed to limit themselves to pharmacy practices as dictated by the FDA Center for Veterinary Medicine, Compliance Policy Guideline ([www.fda.gov/ora/compliance\\_ref/cpg/cpgvet/cpg608-400.html](http://www.fda.gov/ora/compliance_ref/cpg/cpgvet/cpg608-400.html)). Advertising any complete or partial mimicry of drugs and dosage forms of FDA approved formulations will not be accepted. Compounding Pharmacies, or any other exhibitors/advertisers who violate this rule in any fashion, will render their advertising contract null and void.

As a private organization, the AAEP reserves the right to exclude any company from advertising in *Equine Veterinary Education*, American edition, for any reason. The signing and delivery of the advertising contract shall constitute an offer subject to acceptance by the AAEP. In its sole and absolute discretion, the AAEP may revoke its acceptance of the advertising contract or may terminate any contract by delivery of written notice, in which event the AAEP shall have no liability to the advertiser for damages for any other remedy.

Printed by: Sheridan, Hanover, PA.



## A Q&A with the president: Equine veterinary sustainability



Dr. Rob Franklin

In July 2022, the AAEP Commission on Equine Veterinary Sustainability launched to develop strategies to retain and recruit more veterinarians to equine practice. In the ensuing months, more than 50 members volunteered and were assigned to one of five subcommittees focused on developing resources in key areas affecting sustainability of equine practice.

We caught up with AAEP President Dr. Rob Franklin in early February to see how the commission is progressing.

**Q: Can you provide our members with an overview and purview of the Commission on Equine Veterinary Sustainability?**

**Dr. Franklin:** The commission is our No. 1 strategic initiative for 2023, as it was last year. Sustainability is the most pressing problem we're dealing with in equine practice, so it's top of mind for everyone from the universities to private practices to industry.

The commission has five pillars: compensation, emergency coverage, practice culture, internships and veterinary students. These represent the most important categories related to equine veterinary sustainability based on a comprehensive survey of practitioners and students conducted by Drs. Carol Clark and Jim Zeliff in 2021. Their interviews helped us understand where the pain points existed and provided us with the data to prioritize the five pillars.

A subcommittee devoted to each pillar has two co-chairs and an officer liaison who collectively act as the commission's steering committee. The steering committee provides oversight for a very complex problem-solving initiative in order to make sure the subcommittees are supporting each other and collectively accomplishing goals instead of individually attacking their own goals.

**Q: While identifying pain points for our members, has the process identified any misconceptions about equine practice?**

**Dr. Franklin:** One of the first objectives of the Compensation subcommittee was to conduct a broad survey of equine veterinarians, ranging from practice owners to new graduates, in order to get an accurate representation of what people are being paid based off their W-2. More than 1,300 colleagues participated. Based on those responses, the average salary for a veterinarian in their first five years in equine practice is close to \$90,000

per annum, which is quite a bit higher than AVMA data has suggested and is not that far off some of the other disciplines. Do we have room to grow? Absolutely. But this is encouraging and quite different from what has been reported.

**Q: Some have blamed universities for downplaying the prospects of a career in equine practice but at the same time there are ample stories of private practitioners discouraging students and others from equine practice during ride-alongs. How do we get cut through unproductive rhetoric to focus on the ultimate goal?**

**Dr. Franklin:** Although negative sentiments have been heard at both the university level and in private practice, [2022 AAEP President] Dr. Emma Read really was able to change the focus from who's saying what to let's change the reputation of equine practice by making it a very desirable profession. So how do we do that? We make the compensation fair. We make the practice culture better. We make work-life balance a priority so that people can thrive personally and professionally in equine practice. We work on our emergency coverage to try to avoid burnout. When we go in and do the work of these subcommittees, we'll ultimately change the reputation of equine practice and make it the desirable profession that it really is and should be. In turn, that will change how equine practice is discussed at the university level and by private practitioners who are thriving in equine practice and are excited to share that with younger people who are interested.

**Q: Many new graduates enter internships to hone skills and gain practical experience but there seems to be anecdotal evidence of a dichotomy between intern and practice expectations. Is that fair to say?**

**Dr. Franklin:** The equine internship is a valuable way to gain skills, knowledge and experience in a condensed period of time. It's been valuable in both human and veterinary medicine for decades. The problem is that internships aren't the same and the experiences can vary greatly, including types of horses seen, exposure to certain specialties within equine practice, the hours worked and the level of after-hours care.

It all goes back to expectations and setting those expectations so that the veterinary practice is very clear and authentic about the experience they have to offer and so the intern can also make sure they realize what their expectations are and assure alignment. When there's alignment in those expectations, the intern thrives. When either party has not been clear in setting those expectations, then the internship is more likely to be a negative experience and potentially jeopardize the young veterinarian's long-term career in equine veterinary medicine.

*continued on next page*

## Acquire expert insights during 2023 Virtual Wednesday Round Tables

Season 3 of the AAEP's Virtual Wednesday Round Tables premiered in March, offering members a double dose of online education and engagement each month with subject matter experts on important aspects of equine practice.

Available as a complimentary benefit of your membership on the second and fourth Wednesday of each month through October, the Round Tables are 90-minute virtual discussions similar to convention Table Topics. To participate in a particular session, simply register in advance through AAEP Anywhere at [aaepanywhere.org](http://aaepanywhere.org).

Each month's Round Tables feature one clinical and one non-clinical topic. Following is the tentative schedule of upcoming sessions:

- March 22 How to Get the Most Out of an Equine Internship
- April 12 Chronic Management of Gastric Ulcers
- April 26 Emergency Coverage



The 2023 season began March 8 with Lameness Cases Where Imaging and Blocking Don't Make Sense. You can watch a recording of the session as well as sessions from 2021 and 2022 on-demand through AAEP Anywhere. On-demand sessions are available approximately 48 hours following the live session and include mentioned resources such as PowerPoint slides, images and more. CE credit is not offered for the Round Tables.

*The AAEP thanks its Virtual Wednesday Round Table sponsors:*



**Boehringer  
Ingelheim**



## A Q&A with the president, continued

The Internship subcommittee is first and foremost looking to solidify what those expectations are from the practice standpoint and encourage the students to honestly consider what are the most important aspects of an internship to them. The good news is we have a wide array of internship experiences available to students throughout the country so I'm sure there's the right internship available for everyone who is interested in equine veterinary medicine if we can make the decision-making process a bit more clear for all parties.

### **Q: What are the expected outcomes you're looking for in 2023 from the commission and its subcommittees?**

**Dr. Franklin:** We're in the transition from discovery to implementation. That's the goal of the subcommittees' work this year—producing deliverables to our members that can help them actively deal with the problems related to veterinary sustainability. These will be composed of case studies highlighting some practices that are setting examples that people can mirror in their own practice, either in whole or in part. Tool kits will be developed featuring tangible things people can implement in their day-to-day practice that we know are going to improve things like practice culture, emergency duty, compensation

and such. The third leg of the stool is establishing some best practices or benchmarks that we can all key off of. I see this information coming out throughout the year in written and oral form. And of course, we'll have more recap on the progress of the commission at the annual convention in San Diego.

### **Q: What's your advice for AAEP members who want to be a part of the change in the profession?**

**Dr. Franklin:** Talking about it with your colleagues, recognizing where the pain points are that we've been able to identify and working toward making changes in those areas in your own personal practice. I believe all change really occurs organically at the ground level. So if someone is interested in helping with the commission, the best thing they can do is to improve the environment in their own practice. We're trying to change the reputation of equine practice by actually changing equine practice, and that change has to start with individuals. Whether it's a practice owner, an academic, an associate, an intern, or someone in industry, there are areas where we can all change and improve our personal situation that will ultimately result in the grassroots change that we're hoping will occur.



## Sustainability, other priorities in focus at winter board meeting

By David Foley, AAEP Executive Director

The AAEP board convened Jan. 22 for its winter board meeting with all directors present. Following is a synopsis of the meeting.

After introductory remarks by AAEP President Dr. Rob Franklin, the board discussed its strategic plan goals, beginning with an overview of the recently formed Commission on Equine Veterinary Sustainability and updates from the respective officer liaison to each of the commission's five subcommittees. The board provided suggestions to each liaison to communicate back to their subcommittee members.

To keep directors and officers apprised of commission activities and ensure created documents and resources align with AAEP policies, it was determined that the executive director will solicit briefings from the subcommittees and provide a monthly update to the board. The board then passed a motion that any public-facing materials developed by a commission subcommittee must be reviewed and approved by the board of directors with the time allotted for review commensurate with the degree of urgency.

Discussion of The Profession goal of the strategic plan concluded with (1) a stated need for more frequent Zoom meetings of the steering committee to ensure satisfactory communication of the initiatives and resources developed by the various subcommittees, and (2) clarification of how board liaisons should interact with their respective committees.

Conversation then shifted to The Education and The Horse goals, the initial supporting strategies for which have been mostly completed as this plan was developed in 2019. The board approved a staff request to conduct further market research on the annual convention attendee outcomes to ensure the meeting remains relevant for a changing demographic.

Following strategic plan deliberations, the meeting's focus transitioned to discussion and updates on the work of AAEP's various committees. Specific actions taken were:

- Approval of a recommendation from the DEI Committee to approve funding for DEI consultant/facilitator Kim D'Abreu to present a training session at the 2023 Annual Convention.
- Creation and approval, during review of the Welfare and Public Policy Advisory Council's work, of the following stakeholder comment to the AVMA concerning the latest FDA action toward making xylazine a Schedule III drug:

*The AAEP's position is that xylazine and other alpha-2 agonists should remain unscheduled substances. If theft from veterinary practices becomes a significant source of diverted xylazine, the AAEP will review this position.*



Board members Dr. Erin Denney-Jones, left, and Dr. Tegan Easton, right.

Although there were no formal recommendations within the other committees' reports, discussion ensued relative to unsanctioned horse racing, an issue being addressed collaboratively by the Racing Committee and Welfare and Public Policy Advisory Council. The AVMA recently passed a resolution condemning this activity and the board, in solidarity, endorsed the AVMA resolution.

In other committee-related discussion, the board:

- Suggested that periodic review of the association's various working groups occur as part of the strategic planning cycle in the future.
- Elected Dr. Tegan Easton as a representative on the Nominating Committee, which is conducting an audit of the AAEP Awards program in the coming year and may have forthcoming recommendations.
- Recommended that potential ethical challenges in the owner-trainer-veterinarian dynamic that arose from an issue in the past year be conveyed back to the Professional Conduct and Ethics Committee for consideration on further member education.

The AAEP board meeting concluded with general discussion of (1) the budgets for the AAEP and The Foundation for the Horse, (2) the Equine Disease Communication Center, and (3) the minutes from the November board meeting and from online voting since then.

The Foundation for the Horse board meeting then convened. Specific actions taken included:

- Approval of a motion to establish funding parameters for mission areas including Research, Horses at Risk and Disaster Medicine, with the amendment to further edit the Horses at Risk parameters to include opportunities for domestic horses in transition.
- Appointment of the following board liaisons to these working groups: Research – Drs. Emma Adam and Betsy Charles; Horses at Risk – Dr. Erin Denney-Jones; and Disaster Medicine – Drs. Jackie Christakos and Jim Zelif.

The Foundation board meeting then adjourned.

## 5 things to know about AAEP this month

1. Expand your ability to diagnose, treat and manage foot-related lameness by registering for AAEP's Focus on Podiatry, June 22–24 in Lexington, Ky., at [aaep.org/meetings](http://aaep.org/meetings).
2. Log on for education and engagement with the return of the twice-monthly Virtual Wednesday Round Tables. Learn more and register for upcoming sessions at [aaepanywhere.org](http://aaepanywhere.org).
3. Excellence will be rewarded when the AAEP's annual awards are announced at the 2023 annual convention. Download the nomination form at [aaep.org/about-aaep/annual-awards](http://aaep.org/about-aaep/annual-awards).
4. Seek advice on a difficult case or share your wisdom by joining the more than 1,500 members of AAEP Member Vet Talk on Facebook. Search for the private group on Facebook to join.
5. AAEP Virtual Convention participants are reminded that CE from on-demand viewing of educational sessions must be claimed by March 31.

## Reward excellence with an AAEP award nomination

Deadline to nominate is June 1



Give a richly deserving colleague the recognition they've earned by nominating the individual for an AAEP annual award. The presentation of annual awards is a highlight of each year's President's Luncheon at the annual convention as those serving the horse and profession in outstanding ways are celebrated in front of hundreds of their peers.

The AAEP is accepting nominations in the following categories until June 1:

**The Distinguished Educator – Academic Award** honors an individual educator who by his or her actions and commitment has demonstrated a significant impact on the development and training of equine practitioners.

**The Distinguished Educator – Mentor Award** honors an individual who by his or her actions and commitment has demonstrated a significant impact on the development and training of equine practitioners through mentoring.

**The Distinguished Life Member Award** recognizes a member who has demonstrated outstanding or extraordinary service to the AAEP over the course of their career.

**The Distinguished Service Award** recognizes an individual who has provided exemplary service to the AAEP or a similar organization to the benefit of the horse, horse industry or the profession of equine veterinary medicine.

**The George Stubbs Award** recognizes the contributions made to equine veterinary medicine by individuals other than veterinarians.

**The Sage Kester Beyond the Call Award** is named in honor of its first recipient, the late General Wayne O. "Sage" Kester, DVM, and represents the highest honor bestowed by the AAEP upon a current or former member. The award is presented to an individual who has made significant and long-lasting contributions to equine veterinary medicine and the community.



*Dr. Harold Schott accepts the Distinguished Educator – Academic Award from 2022 AAEP President Dr. Emma Read during the 68th Annual Convention in San Antonio, Texas.*

**The Lavin Cup (The Equine Welfare Award)** recognizes a non-veterinary organization or individual that has demonstrated exceptional compassion or developed and enforced rules and guidelines for the welfare of horses.

**The AAEP Research Award** recognizes an individual who has recently completed research that has or will make a significant impact on the diagnosis, treatment or prevention of equine disease. Nominations are open to all individuals whose research is acknowledged by presentation or publication and by peer review as a significant advancement in equine medicine or innovation in equine science. Nominees must have had their research presented or published during the two years prior to when nominations are submitted to the AAEP.

Visit [aaep.org/about-aaep/annual-awards](http://aaep.org/about-aaep/annual-awards) for nomination forms as well as additional information about the awards and selection process. Nomination forms are also available from Sue Stivers at (859) 233-0147 or [stivers@aaep.org](mailto:stivers@aaep.org).

**Award recipients will be honored at the AAEP's 69th Annual Convention in San Diego, Calif., Nov. 29–Dec. 3, 2023.**





# MEMBER ASSISTANCE PROGRAM

Services provided by



The member assistance program is an AAEP-sponsored benefit that offers the support and resources you need to address personal or work-related challenges and concerns. It's confidential and free to you and your household family members. Two types of services are provided: counseling and consultation sessions and online resources.

## Accessing Services

**Call 800-633-3353 to speak to a qualified clinician, 24 hours a day, 7 days a week.** No password or special access information is required to utilize this service.

**To access online resources,** visit [mygroup.com](http://mygroup.com) \* Click on My Portal Login \* Select Work-Life option \* Enter Username: aep & Password: guest

## Download MYgroup App

**You can also conveniently access services through the MYgroup app,** available for download in the Apple and Google Play stores. The login credentials are the same as they are for the [mygroup.com](http://mygroup.com) website.

## Assessment and Counseling

Reasons to use the member assistance program include relationship difficulties, depression or anxiety, stress, grief and loss, parenting concerns, and alcohol and drug abuse and addiction. The program provides short-term, solution-focused therapy.

When an AAEP member or family member calls, you will be offered face-to-face, telephonic, or virtual counseling sessions in which a thorough assessment can be conducted by a licensed, experienced clinician in your area. AAEP members and immediate family can utilize the member assistance program for an unlimited number of issues per year, with up to three counseling sessions offered per issue. There is no cost to you.

## Legal Services

- Free telephonic legal advice
- Free 30-minute appointment for legal consultation with a local attorney
- In most cases, 25% discount on ongoing legal services
- Legal forms available to download on [mygroup.com](http://mygroup.com), such as wills, request for death certificate, etc.
- Please note: Legal services through this program do not cover disputes or actions involving the member's employer or issues related to business.

## Financial Services

- Free financial counseling appointments
- Issues addressed include bankruptcy, buying a home, loan repayment and retirement planning.
- 40 financial calculators available online at [mygroup.com](http://mygroup.com).

## Online Services

- 7 content divisions: Parenting, Aging, Balancing, Thriving, Living, Working, and International
- Monthly online seminars with certificates of completion
- Over 100 streaming audio files and 100 video files covering a range of health topics.
- Savings Center and Relocation Center

## ACCESSING SERVICES

**Toll-free: 800-633-3353**

**Website: [www.mygroup.com](http://www.mygroup.com) >**  
My Portal Login > Work-Life

**Username: aep**  
**Password: guest**

*The Member Assistance Program is offered to U.S. and Canadian members only at this time due to variances in available providers outside of North America.*

## New *EVE* podcast looks at non-orthopaedic causes of poor performance



In the latest episode of the *Equine Veterinary Education* podcast, Dr. Yvette Nout-Lomas discusses her review article, “Poor performance in the horse: Diagnosing the non-orthopaedic causes.”

Dr. Nout-Lomas is an associate professor of equine internal medicine at Colorado State University College of Veterinary Medicine and Biomedical Sciences. Download or listen to the 38-minute episode at [equineveterinaryeducation.podbean.com](http://equineveterinaryeducation.podbean.com) or on iTunes.

## AAEP leaders outline priorities on new *Practice Life* podcast

During the January episode of the AAEP *Practice Life* podcast, co-hosts Dr. Mike Pownall and Dr. Jessica Dunbar discuss association priorities and the state of equine practice with AAEP President Dr. Rob Franklin, President-elect Dr. Katie Garrett and Executive Director David Foley.



While addressing the link between effective mentorship and a rewarding career in equine practice, it was announced that the AAEP and The Foundation for the Horse are providing scholarships to early-career veterinarians to cover half the tuition for participation in either Decade One or MentorVet. These programs have achieved robust retention among graduates and, according to Dr. Franklin, help newer practitioners feel part of the professional community of their peers.

“We all need a sense of belonging in our personal and professional lives, and you feel like for so much of your early career you’re on the outside looking in,” said Dr. Franklin. “There are a lot of skills taught in MentorVet and Decade One about personal wellness and business and how to be a successful equine veterinarian, but one of the real big intangibles is just that sense of community and sense of belonging that they both deliver.”

Among other topics discussed are the importance of volunteering, recap of the annual convention, preview of AAEP’s 2023 CE offerings and an update on the Commission on Equine Veterinary Sustainability and the work of its five subcommittees. Download or listen to the 34-minute episode at [podcast.aaep.org](http://podcast.aaep.org) or on iTunes.

*The AAEP Practice Life podcast is sponsored by Boehringer Ingelheim.*



## Horse Owner Education Committee created



The AAEP has established a Horse Owner Education Committee whose responsibilities in part include developing strategies for client communication relative to the sustainability issue facing the equine veterinary profession.

Chaired by Dr. Sarah Reuss, the committee comprises Drs. Sarah Gold, Elizabeth Gorrell, Casey Gruber, Jessica Millwood, Jenna Moline, Valerie Moorman, Brittany Newsham, Christopher Newton, Elsbeth Swain O’Fallon, Nicole Scherrer, Thomas Timmons and Nathan Voris.

Additional responsibilities of the committee include reviewing and updating existing AAEP horse owner education resource materials to ensure both relevancy and accuracy; and establishing an ongoing process for new content development. AAEP Director of Education Karen Pautz serves as staff liaison to the committee.

For more information, including how to get involved with future volunteer service on a council or committee, visit [aaep.org/about-aaep/committees-and-councils](http://aaep.org/about-aaep/committees-and-councils).



## Conquer foot lameness with hands-on training at Focus on Podiatry

From the show ring and racetrack to the cross country course and pleasure trail, a healthy foot is critical to soundness and performance. Unfortunately, foot-related lameness is an all-too-common frustration for owners and a unique challenge for equine veterinarians. Successful management of the various causes and conditions requires navigating the knowledge gap in equine podiatry in which much of the information remains subjective, controversial or unclear.

Led by an elite team of veterinary podiatrists and farriers, the AAEP's Focus on Podiatry will cut through the information clutter and instill a strong foundation of podiatry principles and techniques to help you diagnose, treat and prevent common to complicated foot diseases faced by your patients.

The immersive meeting is limited to 60 participants for optimal instruction and skills acquisition. Small-group labs will reinforce pertinent lectures, providing the hands-on opportunity to expand your working knowledge of the foot, boost understanding of anatomy and biomechanics of podiatry issues, and develop skills to interpret degree of damage and devise mechanical solutions that facilitate healing and restoration of function.

During **hands-on sessions**, you will:

- Perform and interpret digital venograms
- Radiograph the foot and learn to simplify communication with the farrier
- Use radiographs for therapeutic shoeing
- Apply surgical approaches for diseases of the distal limb and foot
- Administer therapeutic applications with different materials and gluing techniques
- Observe dissected limbs and feet

Following daily sessions, evening social events will facilitate further discussions with instructors and fellow attendees, creating opportunities to forge enduring professional relationships.


Just a few of the meeting's many **practical takeaways** include:

- Improving interpretive skills, planning and execution of the podiatry plan
- Approaching common to traumatic injuries such as deep puncture wounds, traumatic avulsions and cracks
- Performing a DDF tenotomy at the level of the mid-canon and pastern
- Determining when and how to use different therapeutic shoes
- Connecting the ill effects of compromised blood supply with hoof distortions

### Presenters:

<i>Veterinarian Podiatrists:</i>	Dr. Ric Redden
Dr. Brian Beasley	Dr. Daria Stöcker
Dr. Raul Bras	
Dr. Teresa Burns	<i>Farriers:</i>
Dr. Scott Morrison	Ronald Aalders
Dr. Jaret Pullen	Mitch Taylor

CE Hours: 20+ hours



Attendance is limited so register early!

Focus on Podiatry will be held June 22–24 at Spy Coast Farm in Lexington, Ky. Attendance is capped at 60 participants, and all spots will be filled on a first-come basis. The AAEP-member registration rate is \$945.

Register for the meeting, view the program and book your hotel room at [aaep.org/meetings](http://aaep.org/meetings).



Focus on Podiatry is sponsored by:



## Nearly 100 soak up sun and science at Resort Symposium

Sunshine and 80-degree warmth blanketed the 97 practitioners who ventured from as far away as Switzerland to the coral sands of Grand Cayman for the AAEP's 24th Annual Resort Symposium, Jan. 23–25.

Three half-day educational sessions equipped attendees with new knowledge and valuable tips for preventing, recognizing and treating different ocular diseases; diagnosing musculoskeletal injuries using various imaging modalities; and improving the bottom line of their practices. After sessions, practitioners relaxed beachfront or poolside, making memories and friendships with colleagues.

If starting the new year at a laid back, tropical CE event sounds enticing, mark your calendar for the 25th Annual Resort Symposium, which will be held Jan. 22–24, 2024, at the oceanfront J.W. Marriott Guanacaste Resort in majestic Costa Rica. Additional information about the meeting will be announced later this year.



*Attendees enjoy the camaraderie of colleagues at the beachfront Welcome Reception.*

*The AAEP thanks Zoetis for its ongoing sponsorship of the annual Resort Symposium.*

## MEMBERSHIP

### Member in the News



*Dr. Gregory Ferraro*

#### Dr. Gregory Ferraro reappointed to CHRB

California Gov. Gavin Newsom has reappointed Dr. Gregory Ferraro to the California Horse Racing Board, on which he currently serves as chair.

Dr. Ferraro, who earned his veterinary degree from UC Davis and spent over 25 years in racetrack veterinary practice, served as director of the UC Davis Center for Equine Health from 1997-2011 and associate director of the UC Davis Veterinary Medical Teaching Hospital from 2011-2014. His AAEP service includes previous terms on the Educational Programs, Racing and Research committees, among others.

### Benefit: Offset inflationary pressures with The Veterinary Club

Boost your purchasing power and save money on many of the products and services used in everyday practice by enrolling in the AAEP's group purchasing program known as The Veterinary Club.

A complimentary benefit of your AAEP membership, The Veterinary Club offers pre-negotiated discounts on a robust catalog of more than 450 contracted suppliers in Diagnostic Imaging, Facilities Management, Office Solutions, Pharmacy, Surgical and Medical Supplies, Laboratory, Computers and IT Solutions, etc.

More than 800 AAEP members/practices are spending a combined \$4 million annually through The Veterinary Club, accruing \$750,000 in annual savings. This works out to average savings of \$937 per participant, far exceeding the cost of their AAEP membership.



“I was pleasantly surprised to find out we were eligible for a savings of 54% on radiation badges from Radiation Detection Company,” said Valley Equine Hospital’s Dr. Lori Kayashima. “We look forward to exploring other cost saving contracts on The Veterinary Club’s website.”

Start saving today by registering at [TheVeterinaryClub.com](http://TheVeterinaryClub.com). If you have questions about this or other membership benefits, contact Megan Gray, member concierge, at [mgray@aaep.org](mailto:mgray@aaep.org) or (859) 233-0147.

## How to decrease accounts receivable in an ambulatory practice

By Linda Hagerman, DVM

*Editor's note: This paper appears in the 2022 AAEP Annual Convention Proceedings and is being reprinted here due to the timeliness and relevance of the topic for many of our members.*

### 1. Introduction

Equine veterinary practice is highly rewarding, but it is not an easy career and equine ambulatory practice can be a hard way to make a living. Managing the business while juggling the challenges of daily appointments in addition to emergencies is difficult. Consequently, the overall success of any practice is sometimes determined more by business skills than veterinary skills. This paper will discuss some processes that may help facilitate collecting money at time of service and therefore keeping accounts receivable low.

### 2. Materials and Methods

#### *Develop a Culture of Collection*

It's important to develop the culture of collecting payment at time of service early in your career. This is a philosophy that should be in place at the start of your business. Both solo practitioners and group practices can establish this culture. Young veterinarians, due to their high debt load, are often better at thinking about being paid, so harness their motivation and that energy. In a group practice, foster a team approach by talking about accounts receivable and strategizing easy ways to get paid, but have one person leading the collections strategy.

#### *Take Time to Work on Your Business*

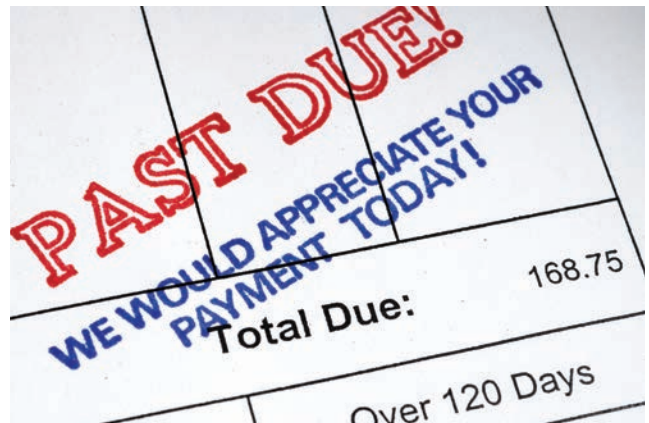It's hard to say no to a horse in need, and sometimes you won't be able to, but taking time to develop and maintain your business and carry out an accounts receivable strategy should also be treated as an emergency. Set aside a day to work on the business (i.e., no appointments). Set that expectation with yourself and your clients.

#### *Manage Expectations*

During the appointment scheduling call or text, have the receptionist give the client an estimate and get a verbal approval that the estimate is agreed to. During the appointment, keep the client informed of the charges, and when recommending other treatments, make sure they know how that will affect the bill and get verbal approval to continue.

#### *Logistics*

- Have the statement billing period from the previous 16th to the current 15th of the month. When clients pay their bills near the end of the month, your practice's statement is sitting there waiting.
- Offer Care Credit, cash, debit/credit card options, as well as PayPal and other online options.
- Be prepared to text or call clients who owe money relentlessly (in some areas, it's legal to contact clients in arrears once per day).



- Go to small claims court or send clients to a collection agent if they don't pay. The news will travel that your practice expects to get paid and this will naturally, eventually, weed out those who don't intend to pay.
- The COVID touchless protocol has made getting credit cards on file the norm for people, so take advantage of this.
- Use card readers in the field to get credit or debit card payments.
- Do not accept checks from first-time clients.
- Do payment plans only for clients who have established credit with the business, half down and half in 2 weeks, and have them sign a legal document promising to pay with the terms specifically outlined. Follow up with small claims court if they don't fulfill their promise to pay.
- Some clients will send a small amount of money to put on their account every month and then schedule their services when they have accumulated enough.

#### *Be Selective*

Say no or be especially suspicious about a new client calling with an emergency that has you driving past 2 or 3 other veterinarians.

#### *Be Known as "Expensive"*

Clients expect to pay "a lot" when they see you and are often overprepared for their bill, even though in reality it's not much more than other clinics. The reputation has created the value.

#### *Get Business Consulting Help*

Join a Veterinary Management Group (VMG) or hire a private equine veterinary consulting firm to help analyze your practice, keep you engaged with the process of bettering the business, hold you accountable to work on the practice, and give you different ideas of how to do business.

*continued on next page*



## AAEP Educational Partner Profile: Merck Animal Health



Our passion is simple: do what's right for the horse. It's our Unconditional commitment to work tirelessly toward that goal by continually innovating and improving the products and programs that impact the health and wellbeing of horses. We stand arm in arm with all of you who share our devotion to the horse through our Unconditional dedication:

### Passion for People Who Care for Horses.

The unique trust between horses and people fuels our commitment to creating premium equine health solutions, backed by a team of knowledgeable equine professionals.

- Partnership with the EquiTrace® app enables our Bio-Thermo® microchips to provide instant temperature monitoring and health records management
- Merck Equine Research Fellowship through the Gluck Equine Research Center supports advanced study of equine disease

### Commitment to the Equine Industry.

We champion programs that strengthen the bond between human and horse.

- Ongoing infectious disease tracking and sequencing through our Equine Respiratory Biosurveillance Program shapes disease response and enables us to update vaccines to account for current circulating strains
- \$1 million+ in vaccine donations through the Unwanted Horse Veterinary Relief Campaign, a 15-year (ongoing) non-profit partnership with AAEP
- Annual Merck Animal Health Foundation for the Horse Scholarship

### Commitment to Sustainability.

We're making critical investments in the health and longevity of the equine veterinary profession through multiple initiatives.

- The Merck Animal Health Veterinary Wellbeing Study III was expanded to include veterinary technicians
- A founding sponsor of MentorVet, an evidence-based approach to empowering healthy veterinary professionals
- A founding partner with Sustainability in Equine Practice Seminars to help veterinarians achieve greater wellbeing, productivity and peer collaboration

Learn more at [merck-animal-health-usa.com/species/equine/equine-unconditional](https://merck-animal-health-usa.com/species/equine/equine-unconditional).

## CONTINUING EDUCATION

### How to decrease accounts receivable, continued

#### 3. Results

At this stage, performance can be measured and you have a way to periodically monitor it for continuous improvement. One easy calculation is that accounts receivable total should be less than 9% of revenue. Another is to know the days outstanding or the days to collection number that your practice has and challenge yourself to get it as low as possible. The formula for that is as follows: Amount of accounts receivable (A/R) at the beginning of the period + Amount of A/R at the end of the period/2 = Average A/R. Take Total Sales divided by Average A/R = % of A/R to sales. Take that percent X 365 = Days outstanding or days to collection.

#### 4. Discussion

Veterinarians have been trained to excel in medicine but not as well in business. Decreasing accounts receivable by collecting payment at time of service and having a low A/R will create a profitable practice that offers good work/life balance.

*Dr. Hagerman is owner and managing veterinarian at Tacoma Equine Hospital, a six-doctor predominantly ambulatory practice in Tacoma, Wash.*

# LubriSyn® | HA

## JOIN THE LEADING NAME IN JOINT HEALTH

Maximize results & performance and increase revenue with the TOP joint supplement on the market.



"Investing in LubriSynHA is the best insurance policy you can buy. Nothing supports healthy joint function like high-molecular weight hyaluronic acid."

### DR. STEVEN ALLDAY

LubriSynHA Developer and CEO

## REVENUE GENERATING

LubriSynHA doesn't just offer exceptional results for your customers, it provides dealers with increased revenue and return business.



### HIGH-MOLECULAR WEIGHT HYALURONIC ACID

Hyaluronic acid is the only element that supports healthy synovial fluid reducing pain and inflammation



### HIGHEST QUALITY HA AVAILABLE

Our trusted formula uses the highest quality HA on the market ensuring fast, non-testing results.



### LIQUID IS KEY

LubriSynHA's liquid formulation is absorbed in the upper GI providing faster results than powders or pellets.



### COST-EFFECTIVE

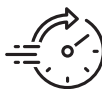Joint care doesn't have to break the bank. Investing in LubriSynHA costs as little as \$1 per day.



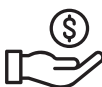### GREAT MARGINS



### PREVENTATIVE & RESTORATIVE



### FAST RESULTS



### RETURN CUSTOMERS

**RESEARCH HIGHLIGHTS**

## Highlights of recent clinically relevant papers

### ANTIMICROBIAL USE

*This retrospective study by Sarah Allen and UK-based co-workers aimed to describe systemic antimicrobial use (AMU) in UK equine practice and identify factors associated with systemic and Category B AMU.*

Anonymised electronic patient records (EPRs) for all equids attended by 39 UK veterinary practices in 2018 were collected via the VetCompass programme. Systemic antimicrobial prescriptions were identified and indications for AMU were determined through manual review of a subset of EPRs. The types and frequency of systemic antimicrobials prescribed, and indications were summarised. Practice- and horse-related risk factors were evaluated.

Systemic antimicrobials were prescribed to 12,538 (19.5%) of 64,322 attended equids. Category B antimicrobials (third- and fourth-generation cephalosporins, fluoroquinolones and polymyxins) were prescribed to 1.9% of attended equids and in 8.9% of antimicrobial courses. Category B antimicrobials were used as first-line therapy in 947 cases (71.7%). Bacteriological culture was performed in 19.1% of Category B antimicrobial courses. The most prescribed antimicrobial classes were potentiated sulphonamides and tetracyclines. Integumentary disorders were the most common reason for systemic AMU. Urogenital disorders were the most common reason for Category B AMU. Increased odds of systemic and Category B AMU were observed in equids <1 year compared with those aged 5–14 years. Breed was associated with AMU, with odds of systemic and Category B AMU highest in Thoroughbreds and Thoroughbred crosses.

### ACUTE DIARRHOEA

*This multicentre study by Diego Gomez and co-workers in Canada and the United States describes the clinicopathological findings, diagnostic approach, treatment and factors associated with non-survival of diarrhoeic horses.*

A total of 300 horses, ≥1-year-old, with acute diarrhoea were included and represented 1.6% (300/18,481) of admissions to four Canadian university teaching hospitals between 2015 and 2019. Seventy per cent of the horses survived to discharge. Testing for enteropathogens was limited to a single faecal culture for *Salmonella* spp. in most cases. An enteropathogen was identified in 14% (42/300) of the horses; but, in the hospital with higher testing rates, enteropathogens were detected in 29% (16/55) of cases. *Neorickettsia risticii* was the pathogen most frequently detected

(31%, 32/102). Antimicrobial drugs and plasma were administered to 57 and 8% of the cases respectively. Laminitis occurred in 8% (24/298) of the horses. A multivariable regression model identified an association between non-survival of diarrhoeic horses and colic signs, increased heart rate, packed cell volume, creatinine concentration and decreased total protein concentration.

These results indicated that a standardised approach for pathogen detection in diarrhoeic horses is not consistent among Canadian veterinary teaching hospitals, and testing for known pathogens is limited. Signs of colic, severe dehydration, endotoxaemia and hypoproteinaemia are associated with non-survival of diarrhoeic horses.

### EQUINE CORONAVIRUS

*This report by Nathalie Fouché and co-workers in Switzerland described clinical signs, diagnostic work-up and outcome of the first documented outbreak of equine coronavirus (ECoV) in Switzerland.*

The outbreak occurred on a farm with 26 horses. Of these, seven horses developed clinical disease ranging from mild signs such as fever and anorexia to severe signs of acute colitis. One horse died due to severe endotoxaemia and circulatory shock secondary to severe acute necrotising enteritis and colitis. Five of the 26 horses tested positive for ECoV, including two ponies without any clinical signs of infection. Testing was only performed on one occasion, over a month after the onset of clinical signs in the first suspected case, so the low number of positive cases should be interpreted with caution. This report highlights the importance of diagnostic testing and early implementation of biosecurity measures on a farm with an ECoV outbreak. It should also raise the awareness for unspecific and mild clinical signs such as fever and anorexia in affected animals that are potentially able to spread the disease.

### RESIDUAL EFFECTS OF IA CORTICOSTEROIDS

*In this cross-over randomised trial US-based Emma Partridge and co-workers utilised an acute synovitis inflammation model to determine the residual effects of intra-articular (IA) betamethasone and triamcinolone acetonide on inflammatory parameters and lameness.*

Five mixed-breed 2-year-old horses were randomly allocated to an IA treatment of the radiocarpal joint with 9 mg of either betamethasone or triamcinolone acetonide. Two weeks after treatment, the horses



were injected with 1 µg of lipopolysaccharide (LPS) diluted in 1 ml of saline. Following LPS injection, horses were crossed over and both sets of injections repeated. Blood samples were collected at multiple time points for mRNA analysis, as well as serum amyloid A (SAA) and cortisol concentration determination. Lameness was subjectively scored at each time point. Additional injections with saline-only or LPS-only (twice) were conducted as negative and positive controls respectively.

Corticosteroid-only treatment resulted in significant mRNA expression differences, as well as significant and prolonged cortisol suppression. Following LPS injection, there was a residual treatment effect with triamcinolone evidenced by a significant treatment effect on *IL-6* and *PTGS1* (cyclooxygenase-1), lameness, SAA and cortisol concentrations, while only *IL-6* expression was affected by betamethasone.

Triamcinolone acetonide has residual anti-inflammatory effects 2 weeks after administration. If these effects include enhanced performance then the current 14 day period required for racing and competition may not be sufficient. The significant suppression of serum cortisol shows that administration of IA corticosteroids is not without risk.

## MANAGEMENT OF PPID

*This clinical audit by N. Steel and co-workers in the UK compared treatment and monitoring of pituitary pars intermedia dysfunction (PPID) cases in veterinary practice against the published recommendations of pergolide mesylate treatment, with monitoring of therapeutic response.*

Case data and basal plasma adrenocorticotrophic hormone (ACTH) concentrations from equids tested for PPID were obtained from a veterinary practice in the UK. Treatment and monitoring data over the subsequent 2–6 years was compared with published recommendations. After exclusions, the audit population was 480 animals (median age 20 years). The most common presenting signs were laminitis and/or historical laminitis (51.2%) and hypertrichosis and/or delayed coat shedding (24.5%). Based on seasonally adjusted reference intervals for basal ACTH concentration, 51.7% of animals were classified as positive, 37.1% as negative and 11.3% as equivocal for PPID.

Records were available for 459 animals; of which pergolide treatment was initiated in 78.7% (185/235) of positive cases, 19.2% (10/52) of equivocal cases and 6.4% (11/172) of negative cases. Overall, 87.2% (129/148) of cases commenced treatment as per recommendations. Only 77.7% (160/206) of pergolide-treated animals had documented PPID monitoring and of these, only 48.1% (77/160) had follow-up basal ACTH testing 1–3 months following diagnosis. Management of PPID in veterinary practice fell below existing recommendations, especially for monitoring.

## INSECT BITE HYPERSENSITIVITY

*The aim of this study by Sarah Bjork Stefansdottir and co-workers in Iceland and Switzerland was to establish a protocol for preventive vaccination against insect bite hypersensitivity (IBH).*

Insect bite hypersensitivity is caused by IgE-mediated reactions to bites of *Culicoides* midges characterised by an imbalance of T cell subsets. Intralymphatic (i.l.) vaccination with r-*Culicoides* allergens in aluminium hydroxide (alum) and monophosphoryl lipid A (MPLA) adjuvants has been shown to induce a desired Th1/regulatory T cell response. This study compared i.l. to subcutaneous (s.c.) injection.

Twelve healthy Icelandic horses were injected, i.l. or s.c., three times at 4-week intervals, using purified r-*Culicoides* allergens in alum/MPLA. Serum antibody levels and cytokine profile following *in vitro* re-stimulation of PBMC were analysed. Comparable allergen-specific IgG antibodies were induced following both routes of vaccinations. The antibodies showed similar capacity to block binding of IgE from IBH-affected horses to the allergens. Upon re-stimulation of PBMC, IL-10 was induced. Horses vaccinated i.l. produced more IFN-γ and less IL-4 compared to the horses injected s.c., but the difference did not reach significance. Applying the simpler s.c. injection instead of i.l. to obtain an immune response could be effective in IBH immunotherapy.

Sue Wright 

EVE Editorial Office  
Email: sue@evj.co.uk

## ORCID

Sue Wright  <https://orcid.org/0000-0002-5513-8571>

## REFERENCES

- Allen, S.E., Verheyen, K.L.P., O'Neill, D.G. & Brodbelt, D.C. (2022) Use of antimicrobials licensed for systemic administration in UK equine practice. *Equine Veterinary Journal*. <https://beva.onlinelibrary.wiley.com/doi/full/10.1111/evj.13878>. Epub ahead of print.
- Fouché, N., Remy-Wohlfender, F., Blau, D., Franzen, J., Gurtner, C., Seuberlich, T. et al. (2022) Characterization of an outbreak of equine coronavirus infection in adult horses in Switzerland. *Schweizer Archiv für Tierheilkunde*, 164, 733–739.
- Gomez, D.E., Leclere, M., Arroyo, L.G., Li, L., John, E., Afonso, T. et al. (2022) Acute diarrhea in horses: A multicenter Canadian retrospective study (2015 to 2019). *The Canadian Veterinary Journal*, 63, 1033–1042.
- Partridge, E., Adam, E., Wood, C., Parker, J., Johnson, M., Horohov Horohov, D. et al. (2022) Residual effects of intra-articular beta-methasone and triamcinolone acetonide in an equine acute synovitis model. *Equine Veterinary Journal*. <https://beva.onlinelibrary.wiley.com/doi/10.1111/evj.13899>. Epub ahead of print.
- Steel, N.L., Ireland, J.L. & McGowan, C.M. (2022) Management of pituitary pars intermedia dysfunction in practice: A clinical audit. *Veterinary Journal*, 289, 105899. Available from: <https://doi.org/10.1016/j.tvjl.2022.105899> Online ahead of print.
- Stefansdottir, S.B., Jonsdottir, S., Kristjansdottir, H., Svansson, V., Marti, E. & Torsteinsdottir, S. (2022) Establishment of a protocol for preventive vaccination against insect bite hypersensitivity. *Veterinary Immunology and Immunopathology*, 253, 110502. Available from: <https://doi.org/10.1016/j.vetimm.2022.110502>

**EDITORIAL**

# Advances in imaging of the equine distal limb: 2017–2022 EVJ, EVE and VRU updates

Injuries and diseases of the distal limb constitute the commonest causes of lameness in horses, and diagnostic imaging plays a central role in their diagnosis. There have been tremendous advances in the development and application of diagnostic imaging techniques used to evaluate the distal limbs in the past 15–20 years, with advanced cross-sectional imaging modalities, such as magnetic resonance imaging (MRI) and computed tomography (CT), being increasingly utilised to provide diagnostic information, in combination with the more 'traditional' techniques of radiography and ultrasonography. These new imaging techniques do not replace radiography and ultrasonography but complement them – indeed each technique has its own advantages and limitations. Like many advances in veterinary medicine, these imaging modalities have transferred from their use in other areas, including human medicine, to use in animals. The initial reliance on MRI and CT scanners designed for use in people (which generally require the equine patient to be imaged whilst under general anaesthesia) has now evolved into scanners that can be used to image the distal limb in standing horses, thereby increasing their practicality and availability in equine practice. The advanced imaging 'stable' of MRI and CT has recently been strengthened by the introduction of positron emission tomography (PET), which will undoubtedly add to and further refine our diagnostic capabilities for conditions of the distal limb in the next 5 years.

*Equine Veterinary Education* (EVJ), *Equine Veterinary Journal* (EVJ) and *Veterinary Radiology and Ultrasound* (VRU) have joined forces to publish a virtual issue on advances in diagnostic imaging of the distal limb, highlighting a selection of some of the more interesting

and important article published in these three journals over the past 5 years. This is the second joint issue that we have published, following on from the issue that we published in 2016, which reviewed articles focused on imaging of the head and neck. The three guest editors for the current virtual issue were Mathieu Spriet (on behalf of EVJ), Ann Carstens (on behalf of VRU) and Tim Mair (on behalf of EVE). Their challenge was to select 'articles that give novel important information that is clinically relevant and applicable to the limb of the horse from the metacarpo/tarso-phalangeal joint and distally'.

We hope that this virtual issue will provide a useful and informative review of some of the exciting developments in diagnostic imaging of the distal limb that have occurred recently. With the ever-increasing technological improvements and availability of diagnostic imaging equipment, we can look forward to further advances in the coming years, which will continue to contribute to improved equine welfare by assisting in the prevention and treatment of diseases of the distal limbs.

Tim Mair *Equine Veterinary Education, Mulberry House, Ely, UK***Correspondence**

Tim Mair

Email: [tim.mair@btinternet.com](mailto:tim.mair@btinternet.com)**ORCID**Tim Mair  <https://orcid.org/0000-0002-9744-9909>

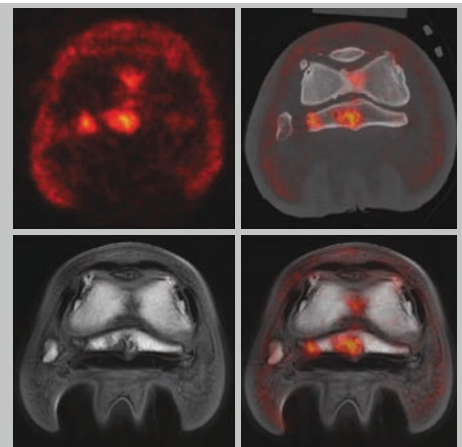
## Advances in Imaging of the Equine Distal Limb

Joint Virtual Issue from *Equine Veterinary Journal*, *Equine Veterinary Education* and *Veterinary Radiology & Ultrasound*

Selected articles from three journals highlighting important developments in imaging of the equine distal limb

Access the issue here:

<https://bit.ly/3H5KrT8>





Bryant W. Craig, DVM

# It's just who we are.

We know horse people because we're horse people. And like you, the love and respect we have for horses is unconditional. Everything we do is for their benefit. If we do right by the horse, we'll never do wrong.



Copyright © 2022 Merck & Co., Inc., Rahway, NJ, USA and its affiliates.  
All rights reserved. US-NON-220900029



#BeUnconditional





Demands of exercise are a stressor for the performance horse. Reactive oxygen species (ROS) such as free radicals are produced in the muscles during exercise. Heavy work can overwhelm the body's natural ability to deal with ROS resulting in oxidative stress which can damage muscle proteins, lipids, and DNA, release pro-inflammatory cytokines leading to muscle pain, and damage the mitochondrial membrane thus decreasing energy production.



# Cellarator<sup>®</sup> Advantage

NUTRITION YOU CAN SEE

**Cellarator<sup>®</sup> Advantage RECOVERY+** is designed specifically to help the performance horse combat the stress of exercise. Its exclusive formula contains unique ingredients proven to combat oxidative damage of muscle cells, improve energy utilization, and support muscle recovery and repair.

**Available exclusively from your Veterinarian.**



AN.EquineHelp@adm.com  
800-680-8254



## CASE REPORT

# Spontaneous bilateral superficial digital flexor tendon rupture in a horse with guttural pouch empyema and suspected purpura hemorrhagica

Kimberly J. MacKinnon<sup>1</sup> | Jean-Yin Tan<sup>2</sup> | Suzon W. Schaal<sup>1</sup> | Jennifer L. Davies<sup>3</sup><sup>1</sup>TD Equine Veterinary Group, Calgary, Alberta, Canada<sup>2</sup>Department of Veterinary Clinical and Diagnostic Sciences, University of Calgary Faculty of Veterinary Medicine, Calgary, Alberta, Canada<sup>3</sup>Diagnostic Services Unit and Department of Veterinary Clinical and Diagnostic Sciences, University of Calgary Faculty of Veterinary Medicine, Calgary, Alberta, Canada

Correspondence: K. J. MacKinnon Email: kimmackinnon@upe.ca

## Present address

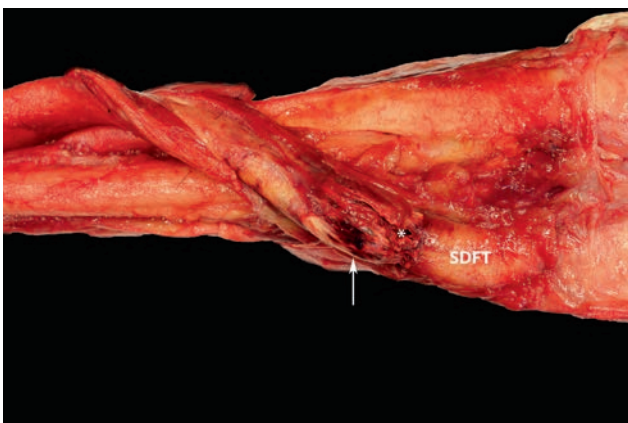
Kimberly J. MacKinnon, Miller &amp; Associates Equine Veterinarians, Brewster, New York, USA

## SUMMARY

An 11-year-old Quarter Horse gelding was evaluated for urticaria, generalised discomfort, distal limb oedema, spontaneous dropped fetlocks and progressive hindlimb lameness. Prior infection status with *Streptococcus equi* subspecies *equi* was unknown. The horse had bilateral hindlimb oedema, generalised wheals, progressive hindlimb lameness, and dropped fetlocks of the right and left hindlimbs. The horse was intermittently pyrexia. The horse was treated with a combination of antibiotic therapy (enrofloxacin, penicillin), nonsteroidal anti-inflammatory drugs (phenylbutazone) and corticosteroids (dexamethasone), with no improvement in clinical status. The horse was subjected to euthanasia due to the poor prognosis and unfavourable response to therapy. Post-mortem examination revealed unilateral guttural pouch empyema, multifocal cutaneous infarction and

bilateral rupture of the superficial digital flexor tendons (Figure 1). *Streptococcus equi* subspecies *equi* was isolated in pure culture from the guttural pouch. Microscopically, leukocytoclastic vasculitis typical of purpura haemorrhagica was documented in the skin. Unexpectedly, similar vasculitis was also observed in the superficial digital flexor tendons. This report documents the first reported equine case of suspected purpura haemorrhagica associated with leukocytoclastic vasculitis of the superficial digital flexor tendons and spontaneous tendon rupture. Spontaneous tendon rupture should be considered a potential sequela to infection with *Streptococcus equi* subspecies *equi* in horses due to immune-mediated vasculitis.

## KEYWORDS

horse, purpura haemorrhagica, *Streptococcus equi*, tendon rupture, vasculitis

**FIGURE 1** SDFT of the left hindlimb. At site of rupture (\*), the tendon is discontinuous with haemorrhage in tendon and tendon sheath

## Key points

- Spontaneous tendon rupture should be considered a potential sequela to infection with *Streptococcus equi* subspecies *equi* in horses due to immune-mediated vasculitis.
- The under-reported nature of this disease process further confirms the need to consider PH as a differential diagnosis for tendon rupture and for continued submission of cases for necropsy and ancillary testing when PH is suspected.
- The differential diagnosis of PH for tendon rupture is important not only for the treatment and prognosis of the affected horse, but also for infectious disease control of *S. equi*, which is a highly contagious disease of equids and has zoonotic potential.



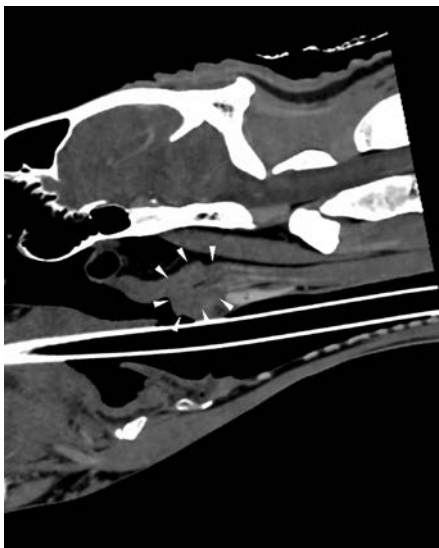
**CASE REPORT**

# Leiomyoma of the proximal cervical oesophagus in a horse

Josephine Faulkner<sup>1</sup> | Lieven Vlaminck<sup>2</sup> | Lise Geerinckx<sup>3</sup> | Els Raes<sup>1</sup> |  
Katrien Vanderperren<sup>1</sup><sup>1</sup>Department of Morphology, Imaging, Orthopedics, Rehabilitation and Nutrition, Faculty of Veterinary Medicine, Ghent University, Ghent, Belgium<sup>2</sup>Department of Large Animal Surgery, Anaesthesia and Orthopaedics, Faculty of Veterinary Medicine, Ghent University, Ghent, Belgium<sup>3</sup>Department of Pathology, Bacteriology and Poultry Disease, Faculty of Veterinary Medicine, Ghent University, Ghent, Belgium**Correspondence:** Josie Faulkner  
Email: josie.faulkner@ugent.be**SUMMARY**

An 18-year-old female Fjord horse presented with a history of recent progressive dysphagia, coughing and increased respiratory effort during exercise, which had not improved with administration of systemic antimicrobials. During upper airway endoscopic examination, feed material was seen within the nasal cavity, pharynx and trachea. A soft tissue swelling was present at the dorsolateral aspect of the palatopharyngeal arch and caudal to the corniculate process of the right arytenoid cartilage, causing medial compression of the dorsal aspects of the arytenoids. A soft tissue mass at the dorsal aspect of the rima glottis and caudal to the right arytenoid appeared to protrude from the roof of the right side of the larynx/trachea causing partial obstruction of the rima glottis. On radiography, a large well-defined rounded soft tissue opacity mass was present at the dorsal aspect of the larynx, superimposed on the palatopharyngeal arch in the region

of the cricopharyngeal sphincter of the oesophagus and cranial part of the oesophagus. Computed tomography was performed under general anaesthesia and showed that the most cranial aspect of the oesophageal wall and/or surrounding tissues were markedly thickened with mildly heterogeneous mixed soft tissue attenuation (30–40 HU) (Figure 1). A small amount of hypoattenuating heterogeneous soft tissue protruded ventrally in between the arytenoid cartilages at the dorsal aspect of the larynx. In post-contrast images, there was minimal heterogeneous contrast enhancement of the thickened soft tissues circumferentially (50–55 HU). Humane euthanasia was opted for due to the poor prognosis and lack of suitable surgical treatment options. Post mortem, histological and immunohistochemical examination provided a definitive diagnosis of leiomyoma of the proximal oesophagus. Neoplasia and more specifically a smooth muscle neoplasm, of the proximal cervical oesophagus has not previously been reported in horses.



**FIGURE 1** Sagittal post-contrast MPR CT image (soft tissue filters) showing thickened cranial aspect of the oesophageal wall and/or surrounding tissues (arrowheads)

**KEYWORDS**

horse, leiomyoma, oesophagus, larynx, neoplasia

**Key points**

- Neoplasia of the oesophagus occurs infrequently in the horse, and the majority of reported cases are squamous cell carcinoma located in the thoracic portion.
- Although leiomyoma in the cranial aspect of the oesophagus is considered a rare diagnosis due to the striated nature of the muscularis layer in the proximal portion of the equine oesophagus, it should be included as a differential diagnosis for cases presenting with similar complaints and showing similar clinical findings.
- CT was extremely valuable for ascertaining a probable diagnosis of neoplasia and determining the extent of the lesion and the prognosis ante-mortem.



## CASE REPORT

# Acquired large colon strangulating inguinal herniation in two Arabian foals

Orr Haion | Amos J. Tatz | Roe Dahan | Gal Kelmer

Department of Large Animal Medicine and Surgery, Koret School of Veterinary Medicine – Veterinary Teaching Hospital, The Hebrew University of Jerusalem, Jerusalem, Israel

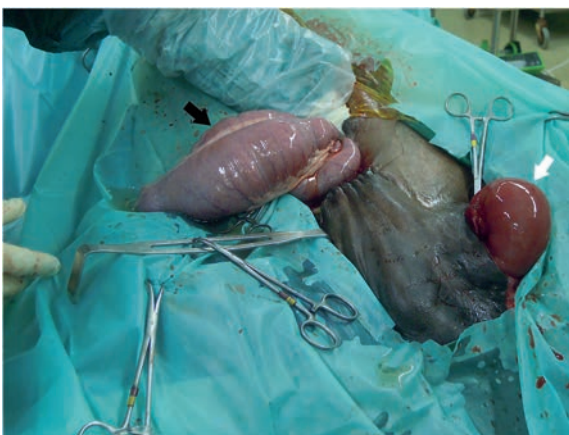Correspondence: Gal Kelmer  
Email: gal.kelmer@mail.huji.ac.il

## SUMMARY

Case 1, a 6-week-old Arabian foal was presented with signs of colic. Upon arrival, the foal was severely painful and in acute distress. A severely distended, firm and painful swelling was present in the right inguinal area. Clinical findings supported the diagnosis of a nonreducible right inguinal hernia. The foal was admitted for surgery. Celiotomy through ventral midline approach revealed right indirect pelvic flexure herniation. An incision was made over the right inguinal canal; intra-abdominal traction was applied on the large colon from the ventral midline approach, while external pressure was applied on the pelvic flexure from the inguinal incision. The hernia was reduced and colonic viability assessed. Following several minutes, it was found grossly viable. The testis was spared by partially closing the inguinal canal. The foal was discharged from

the hospital 5 days postoperatively. Follow-up confirmed he was healthy and was sold 2 years later, as a breeding stallion.

Case 2, an 8-week-old Arabian foal was presented with signs of acute colic. Upon arrival, the foal was painful. The left inguinal area was swollen, firm and painful on palpation. Thickened intestine, suggestive of a large colon, was noted upon ultrasonography. A presumptive diagnosis of nonreducible left inguinal hernia was made. The foal was admitted for surgery, and the surgical approach was similar to Case 1. The left inguinal incision exposed the pelvic flexure, herniated through a rent adjacent to the left vaginal ring (Figure 1). A diagnosis of direct left inguinal hernia of the ascending colon was confirmed. The reduction was facilitated by intra-abdominal traction and enlargement of the left inguinal canal. The inguinal canal was partially closed, sparing the intact vaginal tunic. The foal was discharged from the hospital 5 days postoperatively. At home, he recovered well and was sold 3 years later as a breeding stallion.



**FIGURE 1** Intraoperative image, Case 2: The pelvic flexure is herniated (white arrow), and the caecum (black arrow) exteriorised through the ventral midline

## KEYWORDS

horse, colic, direct, inguinal hernia, large colon



## Key points

- Strangulating large colon inguinal herniation is a rare condition in the horse but should be included in the differential diagnoses.
- Large colon inguinal herniation may be successfully treated surgically, using a combined ventral midline celiotomy and inguinal approach.
- Partially closing the inguinal ring enables decreasing its size, thus reducing the chances for recurrence, while preserving the involved testis.

This is an open access article under the terms of the Creative Commons Attribution-NonCommercial-NoDerivs License, which permits use and distribution in any medium, provided the original work is properly cited, the use is non-commercial and no modifications or adaptations are made.

© 2022 The Authors. *Equine Veterinary Education* published by John Wiley & Sons Ltd on behalf of EVJ Ltd.

## CASE REPORT

# Duodenoduodenal intussusception in a 16-year-old German Warmblood mare

Rebecca Mathys<sup>1</sup> | Claudia Graubner<sup>1</sup> | Taina Kaiponen<sup>2</sup> | Llorenç Grau-Roma<sup>2</sup> |  
Elke Van der Vekens<sup>3</sup> | Christoph Koch<sup>1</sup> | Hervé Brünisholz<sup>1</sup>

<sup>1</sup>Swiss Institute of Equine Medicine, Department of Clinical Veterinary Medicine, Vetsuisse Faculty, University of Berne, Bern, Switzerland

<sup>2</sup>Institute of Animal Pathology, University of Bern, Bern, Switzerland

<sup>3</sup>Division of Clinical Radiology, Department of Clinical Veterinary Medicine, Vetsuisse Faculty, University of Berne, Bern, Switzerland

Correspondence: Rebecca Mathys

Email: rmathys@vetclinics.uzh.ch

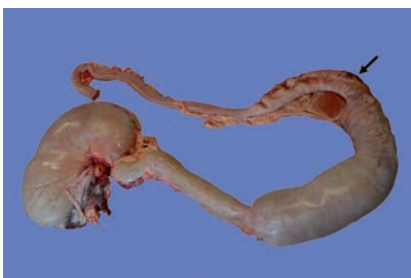## SUMMARY

A 16-year-old German Warmblood mare was presented with an acute history of abdominal pain that failed to respond to medical treatment. On transrectal palpation, a mass with a diameter of 10–15 cm was palpated to the right and dorsal in the abdomen. The mass could not be delineated cranially. Transcutaneous and transrectal ultrasound of the mass showed a so-called ring sign, which led to the suspicion of the presence of an intussusception involving the small intestine. Upon exploratory celiotomy, an intussusception of the duodenum was identified. As the affected part of the duodenum could not be exteriorised and reduced, controlled resection and anastomosis of the affected segment of duodenum were deemed technically impossible, the mare was subjected to euthanasia in anaesthesia. In the post-mortem examination, the intussusception was located 50 cm aboral to the stomach (Figure 1). The mucosa of the intussusceptum showed changes consistent with venous infarction. Immediately oral to the intussusception, a diverticulum measuring 5 cm in diameter

was found on the antimesenteric side of the intestinal wall. As histology showed a lack of the tunica muscularis in the diverticulum, the diagnosis of a pseudodiverticulum was made. The serosal surface of the duodenum immediately aboral to the intussusception showed several multifocal, red and slightly raised plaque-like lesions consistent with *hemomelasma ilei*. The tunica muscularis was hypertrophied in the area of the intussusception as well as up to 20 cm aboral to it. A possible causative association between the segmental muscular hypertrophy in the duodenum, the presence of the pseudodiverticulum and the intussusception was made. As lesions consistent with *hemomelasma ilei* were found, involvement of parasites in the pathogenesis of the segmental muscular hypertrophy cannot be excluded. To the author's best knowledge, this is the first report of a duodenoduodenal intussusception in an adult horse. Hence, duodenoduodenal intussusception should be considered as a possible cause for acute colic in adult horses.

## KEYWORDS

horse, colic, diverticulum, duodenum, intussusception



**FIGURE 1** Post-mortem photograph showing the duodenoduodenal intussusception approximately 50 cm aboral to the stomach. The black arrow indicates lesions consistent with *hemomelasma ilei*

## Key points

- Duodenoduodenal intussusception is a rare form of intussusception of the small intestines in adult horses.
- A so-called ring sign may be observed on transrectal or transcutaneous ultrasound examination in horses with intussusceptions.
- In the case presented here, segmental muscular hypertrophy, a pseudodiverticulum, and lesions consistent with *hemomelasma ilei* were identified as possible causative factors.

This is an open access article under the terms of the Creative Commons Attribution-NonCommercial-NoDerivs License, which permits use and distribution in any medium, provided the original work is properly cited, the use is non-commercial and no modifications or adaptations are made.

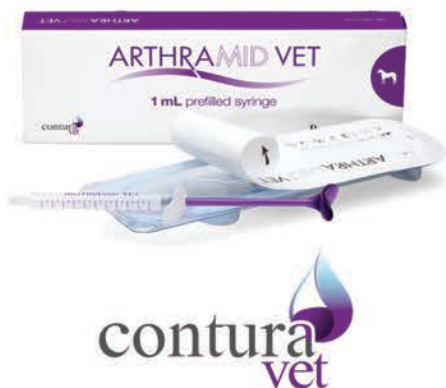© 2022 The Authors. *Equine Veterinary Education* published by John Wiley & Sons Ltd on behalf of EVJ Ltd.

# ARTHRAMID<sup>®</sup> VET



## The Future of Arthritis Treatment Is NOW

### A NEW CLASS OF INJECTABLE JOINT THERAPY



#### *Safe, Long-Term Approach to Managing Osteoarthritis and Degenerative Joint Disease in Horses*

Arthramid<sup>®</sup> Vet goes beyond conventional therapies, using a dynamic bio-scaffold technology to safely and sustainably manage osteoarthritis.<sup>1</sup>

#### *Structural, Long-Lasting Relief*

Patients gain improved load transfer capacity through the joint capsule, reduced effusion and decreased stiffness. Over 80% remained lame-free at 24 months after one injection.<sup>2</sup>

Visit [www.ConturaVetUS.com](http://www.ConturaVetUS.com) or call 800-689-2909

Veterinary use only. This device is restricted to use by or on the order of a licensed veterinarian.

<sup>1</sup>Tnibar, A., Schougaard, H., Camitz, L., Rasmussen, J., Koene, M., Jahn, W., Markussen, B., An international multi-centre prospective study on the efficacy of an intrarticular polyacrylamide hydrogel in horses with osteoarthritis: a 24 month follow up. Acta Vet Scand. 2015; 57: 20-27.

<sup>2</sup>De Clifford, L.T., Lowe, J.N., McKellar, C.D., Chambers, M., David, F., A double-blinded positive control study comparing the relative efficacy of 2.5% polyacrylamide hydrogel (PAAG) against triamcinolone acetonide (TA) and sodium hyaluronate (HA) in the management of middle carpal joint lameness in racing Thoroughbreds. Journal Equine Vet Science; [epub 2021 Sept 24]





# Reliable Solutions for Equine Veterinarians



## **Vetivex® Veterinary pHyLyte™ Injection pH 7.4**

(Multiple Electrolytes Injection, Type 1, USP)  
1000 mL, 3000 mL and 5000 mL bags

## **Vetivex® Hartmann's Solution for Injection**

3000 mL and 5000 mL bags

## **Vetivex® 0.9% Sodium Chloride Injection, USP**

1000 mL and 3000 mL bags

## **Vetivex® Lactated Ringer's Solution Injection, USP**

1000 mL and 5000 mL bags

**NEW!** **Vetivex® Hypertonic Saline Solution  
7.2%, USP** 1000 mL bag



**SCAN ME**

Scan QR code to  
download the Free  
Vetivex Fluids App

Dechra is a registered trademark of Dechra Pharmaceuticals PLC. Vetivex® and pHyLyte® are registered trademarks of Dechra Limited. 04BD-VEC22014-0822

## CASE REPORT

# Standing jejunal enterotomy for resolution of an ileal impaction

Sophie Boorman | Fred Caldwell

Department of Clinical Sciences, JT Vaughan Large Animal Teaching Hospital, Auburn University - College of Veterinary Medicine, Auburn, Alabama, USA

Correspondence: Fred Caldwell

Email: caldwfj@auburn.edu

## SUMMARY

A 22-year-old American Quarter Horse gelding was referred to the JT Vaughan Large Animal Teaching Hospital at Auburn University, College of Veterinary Medicine for colic. A presumptive diagnosis of ileal impaction was made based on physical examination, history of coastal Bermuda hay diet, ultrasonography of the abdomen and clinical-pathological data. The gelding was treated with intravenous fluid therapy, 0.3 mg/kg intravenous *N*-butylscopolammonium bromide, continuous rate infusions (CRI) of intravenous lidocaine and detomidine. The gelding was closely monitored during this initial medical treatment; clinical examination and clinical-pathological data improved, although the gelding continued to demonstrate moderate signs of abdominal pain. Options discussed with the owner included further medical therapy (felt to be the least likely to succeed), exploratory celiotomy under general anaesthesia or a standing procedure to attempt to definitively diagnose and reduce the ileal impaction. The owner elected for the standing procedure.

The gelding was administered antibiotics and anti-inflammatories, positioned in stocks and sedated. The right paralumbar fossa was clipped, aseptically prepared and draped for surgery and a line block

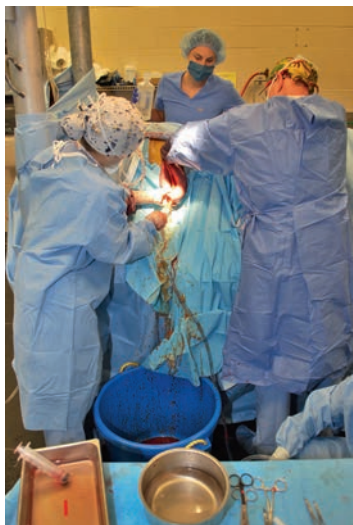performed. A vertical flank incision, beginning 10cm cranial to the tuber coxae and extending 20cm ventrally, was made. The abdomen was accessed using a modified grid approach. Upon palpation of the abdominal contents, an approximately 80-cm ileal impaction, from the ileocaecal orifice to the distal jejunum, was identified. Manual massage of the impaction with sodium carboxymethylcellulose and saline was attempted; however, after no progress was appreciated after 15 min, conversion to an enterotomy was elected.

The jejunum oral to the impaction was exteriorised. An approximately 7-cm linear full-thickness incision was made on the anti-mesenteric surface of the jejunum. A non-sterile assistant poured sterile saline over the exteriorised intestine such that the fluid ran from dorsal to ventral away from the abdominal incision (Figure 1). A medium bore nasogastric tube was introduced into the distal segment of the intestine; a non-sterile assistant pumped in water via the nasogastric tube while the sterile surgery team balloted the intestine. Once the impaction was resolved, the sterile surgeon could appreciate aboral movement of fluid from the ileum to the caecum via the ileocaecal orifice. The enterotomy was closed in two layers: a simple continuous pattern for the submucosa followed by a Cushing pattern in the seromuscular layer. The flank incision was closed, and the gelding returned to the stall.

The gelding was discharged 6 days after surgery after successful treatment for post-operative reflux. Two weeks after surgery, the gelding re-presented for surgical treatment of an incisional abscess. At four-month follow-up, the gelding was reportedly doing well.

## KEYWORDS

horse, abdominal surgery, non-strangulating, small intestine, standing surgery



**FIGURE 1** A 22-year-old gelding undergoing standing flank laparotomy and distal jejunal enterotomy for treatment of ileal impaction.

## Key points

- Standing reduction of ileal impactions via enterotomy could be a viable option for horses experiencing colic when general anaesthesia is not an option.
- Owners should be warned of the need to convert to general anaesthesia if the preoperative diagnosis is not confirmed or if the horse does not tolerate the procedure.
- The potential for post-operative reflux and incisional complications is not eliminated by the standing nature of the surgery.

**CLINICAL COMMENTARY**

# Ileal impactions: How to proceed when a ventral midline celiotomy is not an option?

**Jarred Williams** 

Large Animal Medicine, University of Georgia, Athens, Georgia, USA

**Correspondence** Jarred Williams

Email: jarred@uga.edu

In the case report in this issue, Boorman and Caldwell (2023) performed a standing jejunal enterotomy in a systemically stable, 22-year-old Quarter Horse gelding presented with multiple loops of distended small intestine on transrectal palpation and transabdominal ultrasound. The horse had a history of decreased appetite, episodes of abdominal pain for approximately 12 h, a diet of pasture grazing supplemented with coastal Bermuda hay, no net reflux after nasogastric intubation, a blood lactate of 2.5 mmol/L and pale yellow peritoneal fluid with a lactate of 5.3 mmol/L. Given this background and the fact that the horse was presented to a hospital in the south-eastern region of the United States, the tentative diagnosis was an ileal impaction.

For those living in areas of the USA where ileal impactions are common, this tentative diagnosis seems reasonable. The only worrisome finding was that the peritoneal lactate concentration was more than twice that of the blood lactate, particularly in an aged horse. One would have to be concerned about a possible strangulating lesion, although the other clinical findings to that point would make that seem less likely than a non-strangulating lesion. Based on the history, findings obtained at the initial workup and discussion with the owner, the patient was treated medically, which is what many clinicians faced with this type of case would do. If you have not read the case report, I suggest you do so now to gain a fuller understanding of what transpired over the ensuing 18.5 h when the horse responded to fluid and analgesic therapies and the peritoneal fluid lactate concentration decreased to 2 mmol/L. When signs of colic returned after cessation of a constant rate infusion of analgesics, the owners were given three options: continued medical management, exploratory celiotomy under general anaesthesia or a standing flank laparotomy. If the owners were amenable to the costs associated with surgery performed with the horse under general anaesthesia, it seems unlikely that the standing laparotomy option would have been offered. So, we are left to assume that the owners declined general

anaesthesia and a midline celiotomy, and the clinicians were faced with continued medical management or providing the standing flank laparotomy approach as an alternative. It is at this junction that clinicians' views about how to proceed would differ; what option provides the best chance of resolution with minimal complications for the patient? In any case, the owners chose the standing flank laparotomy approach.

## ARGUMENTS FOR A STANDING FLANK LAPAROTOMY

Medical management of patients with a presumptive diagnosis of non-strangulating obstruction of the small intestine can be challenging for two reasons. First, the diagnosis is presumptive, and you are always concerned about a strangulated loop of intestine being present *somewhere*. The other reason is that these patients experience continual episodes of abdominal pain with dilated loops of small intestine. Managing this scenario requires prolonged sedation and analgesia, plus repeated abdominocenteses. During this process, it is common for confidence about the presumed diagnosis to wane over time without resolution of the problem, or if mild changes in the peritoneal fluid occur. Given all of this, it made sense for the clinicians on this case to recommend an exploratory surgery. If an exploratory surgery under general anaesthesia was not an option for the owners, it is easy to understand why a standing flank laparotomy would make sense.

## ARGUMENTS AGAINST A STANDING FLANK LAPAROTOMY

Although a standing flank laparotomy is not a novel approach for horses presenting with signs of colic, to my knowledge it is not a

This is an open access article under the terms of the Creative Commons Attribution-NonCommercial-NoDerivs License, which permits use and distribution in any medium, provided the original work is properly cited, the use is non-commercial and no modifications or adaptations are made.

© 2022 The Author. *Equine Veterinary Education* published by John Wiley & Sons Ltd on behalf of EVJ Ltd.



well-described procedure for horses with ileal impactions. This is significant because horses with ileal impactions tend to have metres of dilated loops of small intestine that can be unwieldy to control even through a ventral midline celiotomy. Consequently, taking this approach in a standing patient should stimulate the formation of a few questions. For instance, should the approach be via the left or right flank? How large will the incision need to be? How will the dilated small intestine be handled? What other intraoperative complications or difficulties should be expected? The authors chose a right-sided approach and discussed managing the dilated small intestine without complication through an incision that was deemed appropriately sized based on their successful completion of the surgery. Additionally, they described a successful method for performing a small intestinal enterotomy to facilitate resolution of the lesion. Therefore, many may have the opinion that the results of the successful procedure are reason enough to justify it being performed. Others could argue that one success does not imply future successes or justify the procedure.

## THE OUTCOME

As you will read in the case report itself, the horse had a set of unexpected and remarkable complications. Fortunately, the underlying problem was identified and managed successfully. Does the positive outcome justify the decision to use the standing laparotomy approach? One could argue that it does, as the patient may not have responded to medical therapy, and the complications are just the cost of such an effort. However, what if the complications did not resolve and resulted in septic peritonitis, chronic kidney disease or chronic colic? Would we, and the owners, view the outcome differently?

An alternative approach, in this case, would have been to give the owners a different set of three options: continue with medical and analgesic therapy, surgical intervention with the horse under general anaesthesia or euthanasia. Given that most presumed non-strangulating obstructions of the small intestine are managed

medically and some horses with presumed ileal impactions may take days to resolve, I believe I would have encouraged the owners to take the first option. I appreciate that this is certainly a difficult period to idly wait and hope for resolution while the patient is intermittently, or sometimes consistently, painful. In most cases, more time is just what is needed. However, not all resolve with more time and are ultimately euthanised.

Boorman and Caldwell should be commended for their willingness to try something new and to make an effort to be proactive. While the outcome ultimately was positive, they did encounter some pretty serious complications. This is veterinary medicine. We make difficult decisions with options that we may not like. A horse's life was saved, and we learned how a case like this can progress. While I may have taken a different approach, I certainly will think about their case when I am presented with a similar situation.

## CONFLICT OF INTEREST

No conflicts of interest have been declared.

## ETHICAL STATEMENT

Not applicable to this clinical commentary.

## ORCID

Jarred Williams  <https://orcid.org/0000-0001-9873-0201>

## REFERENCE

Boorman, S. & Caldwell, F. (2023) Standing jejunal enterotomy for resolution of an ileal impaction. *Equine Veterinary Education*, 35, 121, e174–e179. <https://doi.org/10.1111/eve.13633>



**How to cite this article:** Williams, J. (2023) Ileal impactions: How to proceed when a ventral midline celiotomy is not an option? *Equine Veterinary Education*, 35, 122–123. Available from: <https://doi.org/10.1111/eve.13682>

## Advertisers' Index

ADM Nutrition.....	116B	Kentucky Performance Products .....	124A
American Regent Animal Health .....	162A	LubrisynHA Family of Products .....	XIII
Arenus .....	C2,C4,127,156B	Merck Animal Health .....	116A
Cargill Animal Nutrition .....	162B	PetVivo .....	130B
ConturaVet .....	120A	Platinum Performance .....	151
Colorado State University CE .....	130A	Rood & Riddle Equine Hospital .....	142B
Dechra Veterinary Products .....	120B	Sedecal (VetRay) .....	C3
E.I. Medical Imaging .....	156A	Vetel Diagnostics .....	124B
Haygain .....	142A	Zoetis .....	138A
Kentucky Equine Research .....	138B		

## CASE REPORT

# Use of barbed suture for thoracoscopic repair of diaphragmatic hernias: Three cases

Louis Kamus<sup>1</sup>  | Pavlina Ruzickova<sup>1</sup> | Perrine Piat<sup>2</sup> | Pierre Trencart<sup>2</sup> |  
Alvaro Antonio Bonilla<sup>1</sup> 

<sup>1</sup>Département de Sciences Cliniques, Faculté de Médecine Vétérinaire, Université de Montréal, Saint-Hyacinthe, Quebec, Canada

<sup>2</sup>Clinique Equine de Provence/Haras de la Trévaresse, Saint-Cannat, France

Correspondence: Louis Kamus  
Email: louis.j.kamus@umontreal.ca

## SUMMARY

Three horses were diagnosed with a dorsally located hernia/tear associated with either a penetrating injury (Case 1) or small intestinal incarceration producing colic signs (Cases 2 and 3). After diagnosis during exploratory thoracoscopy (Case 1) or emergency laparotomy (Cases 2 and 3), closure of the dorsal defect in the diaphragm was performed immediately (Case 1) or after 6 days (Cases 2 and 3) through a standing thoracoscopic approach in all cases.

Horses were restrained in standing stocks and the appropriate thoracic region was prepared and draped aseptically. Standard draping and local anaesthesia of the skin and subcutaneous tissues at the selected thoracoscopic portals were performed. For the first case, with the aid of laparoscopic instruments (needle holder, Babcock forceps, Kelly forceps and scissors), the laceration was closed with absorbable barbed suture (0 USP) placed in a simple continuous fashion. Two suture lines were required for correct closure of the defect as the margins of the defect were friable. The thoracic wound was debrided under thoracoscopic guidance and closed by delayed primary closure using non-absorbable suture. For the second case, the defect was closed and then oversewn with two absorbable barbed

sutures (2-0 and 0 USP) placed in a simple continuous fashion with an automated suturing device (Figure 1). The last horse's defect was closed and oversewn with three barbed sutures (0 USP) placed in a simple continuous fashion with an articulated suturing device.

The horses were discharged 6 days (Case 3) and 14 days (Cases 1 and 2) after surgery.

Telephone follow-up revealed that all horses were alive 2 to 3 years after surgery and fully recovered from the injury. No complications or recurrence were reported by the owners and all horses went back to their previous use.

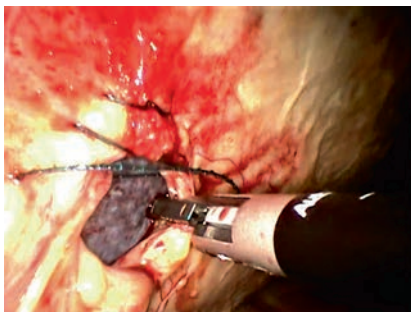## ORCID

Louis Kamus  <https://orcid.org/0000-0002-7192-3377>

Alvaro Antonio Bonilla  <https://orcid.org/0000-0003-0277-4977>

## KEYWORDS

hernia, horse, suturing device, thorax, V-Loc



**FIGURE 1** Intra-operative laparoscopic image of the automated suturing device used to close the diaphragmatic defect of Case 2.

## Key points

- Standing thoracoscopic herniorrhaphy is a reliable technique and shows promise for correction of small dorsal diaphragmatic defects.
- The combination of an automated suturing device with barbed sutures yielded a good outcome in all cases and required minimal training before its use. However, surgeons less familiar with the device and comfortable with direct thoracoscopic suturing can still successfully use barbed suture.
- This approach eliminates the risks and costs associated with general anaesthesia, can improve surgery time, facilitates defect closure and allows accurate suture placement.

# Treating insulin-resistant horses?

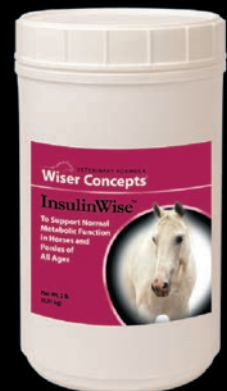

## Recommend

### InsulinWise®

- Maintains healthy insulin regulation and normal body weight.
- Supports a decreased risk of laminitis.
- Formulated with a research-proven blend of polyphenols and amino acids.\*

\*Manfredi JM, Stapley ED, Nash D. Effects of a dietary supplement on insulin and adipokine concentrations in equine metabolic syndrome/insulin dysregulation. In J Equine Vet Sci 2020;88:102930.



### NutrientWise®

- A nutritional supplement specifically formulated for horses/ponies on restricted diets.
- Contains protein levels appropriate for EMS horses.
- Low in NSC, ESC and calories.
- Palatable pellets that can be fed alone or mixed with other feedstuffs.



Available through veterinary supply companies.

Developed by:



KPPvet.com, 859-873-2974

EVE 2023-03



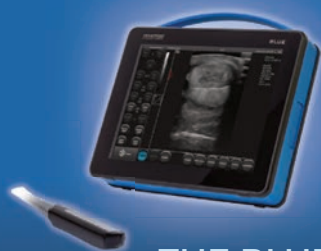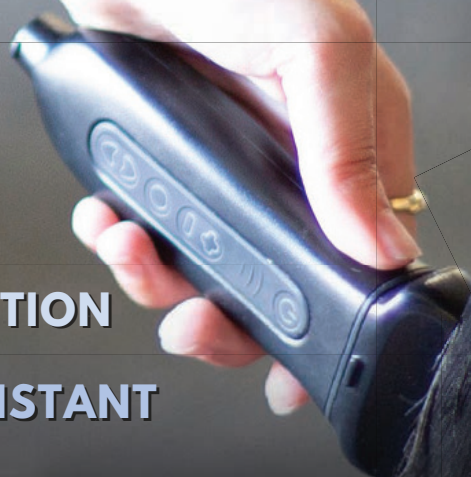# ECHO IQ

## WIRELESS

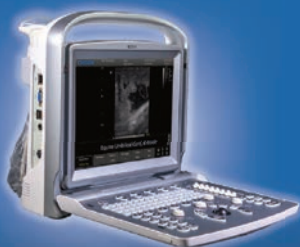## ULTRASOUND



HIGH DEFINITION  
WATER-RESISTANT  
6+ HOUR BATTERY LIFE  
MULTIPLE  
INTERCHANGABLE  
PROBES HEADS  
IMAGE ANYWHERE



THE BLUE



ECO 6



SONOBOOK 8

**ULTRASOUND SOLUTIONS FOR EVERY SETTING**

800-458-8890

[www.veteldiagnostics.com](http://www.veteldiagnostics.com)

[info@veteldiagnostics.com](mailto:info@veteldiagnostics.com)

**CLINICAL COMMENTARY**

# Benefits of equine thoracoscopy

Kara Marchant | Dean A. Hendrickson 

Clinical Sciences, Colorado State University, Fort Collins, Colorado, USA

**Correspondence:** Dean Hendrickson  
Email: dean.hendrickson@colostate.edu**Keywords:** horse, thoracoscopy

Thoracoscopy in the horse is useful for both diagnostic procedures and minimally invasive access to the thorax for surgical procedures. Depending on the surgical approach, various structures within the thorax can be visualised. In the article 'Use of barbed suture for thoracoscopic repair of diaphragmatic hernias: Three cases' (Kamus et al., 2023), thoracoscopy was utilised to repair diaphragmatic hernias on various aspects of the diaphragm in horses. There are three main surgical approaches to the diaphragm via thoracoscopy: dorsal recumbency, lateral recumbency or while under standing anaesthesia utilising pharmacological restraint. These approaches provide different options for viewing of the diaphragm based on organ positioning as well as associated cardiopulmonary effects, and each has their own advantages for their use depending on the individual's needs for thoracoscopy.

When dorsal or lateral recumbency is utilised for thoracoscopy, general anaesthesia is required. In the horse, general anaesthesia has increased the risk of complications including myopathy, post-anaesthetic ileus and associated risks of recovery (Deustch & Taylor, 2022). In addition, when under general anaesthesia, insufflation with carbon dioxide is required as bilateral pneumothorax is more likely to occur (Doherty, et al., 2022). The benefits of general anaesthesia include improved visualisation of the ventral lung surfaces, ventral thoracic cavity, diaphragmatic surfaces and the lateral surface of the heart (Klohn & Peroni, 2000). These factors are to be considered when determining whether general anaesthesia is indicated or if the procedure could be performed under standing pharmacological restraint.

Dorsal recumbency is utilised for visualisation of the ventral aspect of the diaphragm. To achieve better observation of the most cranial surfaces of the diaphragm, it has been reported that horses should be placed in dorsal recumbency, slightly leaning towards the opposite direction of the operating site (about 45 degrees) and in a reverse Trendelenburg position. Horses in dorsal recumbency have increased abnormal ventilation-perfusion mismatch, shunt formation and lower arterial oxygen tension ( $\text{PaO}_2$ ) in comparison with lateral recumbency. The ventilation-perfusion mismatch in recumbency causes significant differences in arterial and alveolar

oxygen tension and leads to decreased functional residual capacity and development of atelectasis. It is believed the increase in gastric and thoracic expiratory pressures in recumbency versus the natural standing position of the horse is responsible for the decrease in functional residual capacity and airway closure during recumbency (Nyman & Hedenstierna, 1989). The ratio of ventilation to perfusion is the primary determinant of pulmonary gas exchange, which expresses the decrease in gas exchange when horses are placed in recumbency, with dorsal recumbency having a more significant shunt in comparison with lateral recumbency (Uquillas et al., 2017).

In lateral recumbency, more dorsal defects of the diaphragm can be observed. Furthermore, positioning in lateral recumbency shifts the intestines caudally allowing for exposure of the ventral aspect of the diaphragm (Toth & Schumacher, 2018). The dependent lung lobe in lateral recumbency has impaired pulmonary function, and this effect is noted to be more severe in right lateral recumbency in comparison with left lateral recumbency. Systolic, diastolic and mean arterial pressures are increased in both left and right lateral recumbency (Youngblood et al., 2020).

Positioning of the head has a major effect on organ placement under general anaesthesia. The reverse Trendelenburg position shifts the intestines caudally, decreasing gastric pressure on the diaphragm and aiding visualisation within the thorax. When situated in the reverse Trendelenburg position, where the horse's head is in an upward position, gas exchange is better preserved compared with the head down Trendelenburg position, especially if applied from the start of anaesthesia (Binetti et al., 2018). In Trendelenburg positioning, oxygen saturation ( $\text{SpO}_2$ ) and transdiaphragmatic expiratory pressure are decreased (Youngblood et al., 2020). Thoracic expiratory pressure is decreased in both standing anaesthetic procedures and when placed in the reverse Trendelenburg position. However, it should be noted the heart rate is increased in the reverse Trendelenburg position and the systolic, diastolic and mean arterial pressures are noted to be decreased in the reverse Trendelenburg position.

Intermittent positive pressure ventilation (IPPV) is also required for thoracoscopy under general anaesthesia because of the

increased predisposition for bilateral pneumothorax to occur in the anaesthetised horse than when standing (Potchileev, et al., 2022). In addition, lung volume is greatly reduced while in recumbency (Toth & Schumacher, 2018). The natural anatomic positioning of organs allows for optimal pulmonary function and gas exchange. Recumbency alters organ placement, leading to abdominal organs increasing pressure on the diaphragm with direct negative consequences for gas exchange. Controlling ventilation through IPPV, arterial blood gas levels can be maintained at normal levels to counteract the effects of gravity leading to progressive atelectasis, left to right pulmonary vascular shunts, ventilation–perfusion mismatch and reduction in cardiac output. Arterial hypoxaemia still is a problem, especially during dorsal recumbency, but the acid–base status can be improved (Shawley & Mandsager, 1990). The downside of IPPV are the effects it has on the cardiopulmonary system, notably the interference of normal venous filling of the vena cava and right atrium, leading to a decrease in cardiac output and arterial blood pressure. Rapid initiation of IPPV is utilised to reduce severity of hypoxaemia, because once anaesthesia is induced, relative hypoxaemia can result from ventilation–perfusion mismatching, and shunt development may occur (Shawley & Mandsager, 1990). Continuous monitoring during anaesthesia can help prevent the negative effects of IPPV.

Standing is the natural position of the horse, allowing for anatomical organ location, so cardiopulmonary effects from organ displacement and impacts of gravity on dead space are not a problem such as when under general anaesthesia (Romero & Rodgerson, 2010). (Romero & Rodgerson, 2010) For example, gastric expiratory pressure is reduced in comparison with dorsal recumbency (Youngblood et al., 2020). A study by Peroni et al. (2000) performed on pharmacologically restrained, healthy and awake horses found no detrimental cardiopulmonary effects or postoperative complications within the first 48-h period after standing thoracoscopy. Standing thoracoscopy has been observed to be well tolerated in a majority of cases, though signs of anxiety, including flaring of the nostrils, restlessness and increased respiratory rate intermittently through procedures have been described (Vachon & Fischer, 1998). Standing thoracoscopy provides visualisation of the dorsal aspect of the thoracic cavity (Pollock & Russell, 2006). However, there is limited to no visualisation of the ventral cranial diaphragmatic and the cranial mediastinal surfaces of the thoracic cavity cranial to the aortic root (Vachon & Fischer, 1998).

Standing thoracoscopy is utilised under a lighter plane of anaesthesia with the horse placed in stocks, avoiding the risks of general anaesthesia and the need for positive pressure ventilation and insufflation. Pneumothorax for standing anaesthesia is induced by inserting a teat cannula allowing atmospheric air to enter the thorax on the side of operation. The lung on the ipsilateral side is allowed to collapse to increase visualisation and decrease risk of trauma to the lung by instruments. Pneumoperitoneum can also be induced with CO<sub>2</sub>. The occurrence of bilateral pneumothorax is more common when insufflation with CO<sub>2</sub> is not employed. The intrapleural pressure should be monitored to avoid pressure greater than 4 mmHg as increased pressure causes cardiovascular and pulmonary

deterioration in dogs (Lugo & Carr, 2018). Because of the potential for bilateral pneumothorax, the surgeon should always have suction readily available in case a bilateral pneumothorax occurs. No adverse alterations in haematology, plasma chemistry values or cardiopulmonary function have been described to occur during laparoscopy under standing chemical restraint. A mild inflammatory response is induced by pneumoperitoneum with CO<sub>2</sub> and should also be monitored (Latimer et al., 2003).

There are many benefits to utilising thoracoscopy for minimally invasive diagnostic and surgical procedures in the thorax. This includes dorsal recumbency and lateral recumbency, performed under general anaesthesia with the head in either reverse Trendelenburg or Trendelenburg position or under standing pharmacological restraint. Each has benefits in viewing various aspects of the diaphragm, organ placement and associated cardiopulmonary effects, which should be taken into account when determining the surgical strategy for each individual patient.

#### AUTHOR CONTRIBUTIONS

D.A. Hendrickson and K. Marchant were both involved in the concept, topic research and writing of the manuscript. Both authors have approved the final version of the manuscript.

#### CONFLICT OF INTEREST

No conflicts of interest have been declared.

#### ETHICAL STATEMENT

Not applicable to this clinical commentary.

#### ORCID

Dean A. Hendrickson  <https://orcid.org/0000-0003-2246-9742>

#### REFERENCES

- Binetti, A., Mosing, M., Sacks, M., Duchateau, L., Gasthuys, F. & Schauvliege, S. (2018) Impact of Trendelenburg (head down) and reverse Trendelenburg (head up) position on respiratory and cardiovascular function in anaesthetized horses. *Veterinary Anaesthesia and Analgesia*, 45(6), 760–771. <https://doi.org/10.1016/j.vaa.2018.01.012>
- Deutsch, J. & Taylor, P.M. (2022) Mortality and morbidity in equine anaesthesia. *Equine Veterinary Education*, 34(3), 152–168.
- Doherty, T., Valverde, A. & Reed, R.A. (Editors). (2022) *Manual of equine anesthesia and analgesia*, Second edition. Hoboken: John Wiley & Sons, Inc.
- Kamus, L., Ruzickova, P., Piat, P., Trencart, P. & Bonilla, A. (2023) Use of barbed suture for thoracoscopic repair of diaphragmatic hernias: Three cases. *Equine Veterinary Education*, 35, 124, e180–e185. <https://doi.org/10.1111/eve.13643>
- Klohnen, A. & Peroni, J.F. (2000) Thoracoscopy in horses. *The Veterinary Clinics of North America. Equine Practice*, 16(2), 351–362.
- Latimer, F.G., Eades, S.C., Pettifer, G., Tetens, J., Hosgood, G. & Moore, R.M. (2003) Cardiopulmonary, blood and peritoneal fluid alterations associated with abdominal insufflation of carbon dioxide in standing horses. *Equine Veterinary Journal*, 35(3), 283–290.
- Lugo, J. & Carr, E.A. (2018) Thoracic disorders. In: Auer, J. & Stick, J. (Eds.) *Equine surgery*. St. Louis: Elsevier Health Sciences, pp. 650–664.

*Continued on page 168*



# ALL OTHERS FALL SHORT.



## *Assure<sup>®</sup> Guard Gold* The Ultimate Digestive Aid<sup>®</sup>

The Trusted Solution of Equine Veterinary Professionals.  
Researched and Patented for the treatment of Recurrent Colic,  
Chronic Diarrhea, Dysmotility and Ulcers.



Arenus Animal Health | 866-791-3344 | [www.arenus.com](http://www.arenus.com)

Ask one of our Veterinary Solutions Specialists how Assure Guard Gold and the new Assure Advisor Mobile App can help you guide your patients to improve digestive health.



## CASE REPORT

# Ultrasonographic identification of mesenteric lipomatosis in a Shetland mare with recurrent colic episodes

Héloïse Lesca  | Alison Fairburn  | Laura Emily Fitzharris  | Tim S. Mair 

Correspondence: Héloïse Lesca  
Email: heloise.lesca@hotmail.com

## SUMMARY

An obese 17-year-old Shetland-pony mare with a history of recurrent colic was presented for investigation of colic signs of a few hours' duration and tachycardia. On presentation, she showed no overt colic signs but had mild-to-moderate abdominal distension. Haematology and biochemistry profiles were unremarkable. Abdominocentesis was unsuccessful, and rectal examination was not possible. Transabdominal ultrasound examination identified a large amount of multilobulated or layered tissue that was hypoechoic to the adjacent retroperitoneal fat within the caudal and ventral abdomen, extending dorsally into the mid-abdomen between the intestinal structures (Figure 1).

The colic episode resolved with medical management, but it was elected to perform an exploratory laparotomy to investigate the recurrent colic episodes. A lipoma at the mesenteric attachment of the mid-jejunum (thought to have caused intermittent

extraluminal compression) as well as abnormally thick layers of fat in the mesentery of both small and large intestine (compatible with lipomatosis) were identified. The lipoma was extirpated, and the resultant mesenteric and serosal defects closed. There was no further involvement of the intestines, and no other surgical treatment was undertaken.

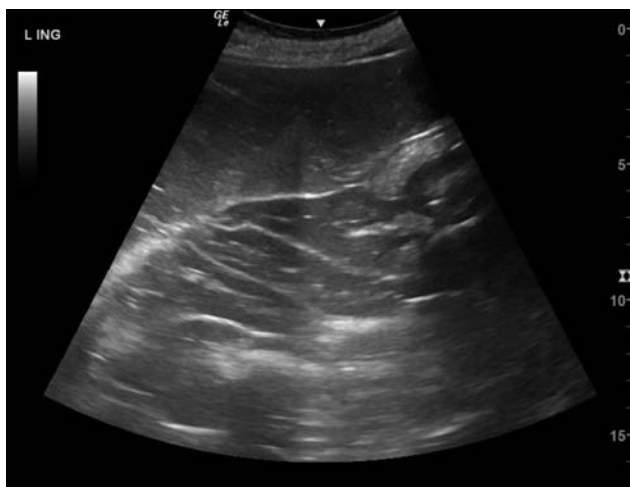Post-operative recovery was uneventful. A strict diet was enforced, resulting in marked weight loss over the 12-week post-surgery period with an improvement of the body condition. Follow-up abdominal ultrasound examination identified a reduction in the thickness of the retroperitoneal fat layer and the abnormal multilobulated tissue.

The mare displayed one colic episode 10 days after surgery that resolved rapidly after flunixin meglumine administration and did not show any further colic signs during the 6-month period post-surgery (to the time of writing).

This is the first case report detailing the ultrasonographic findings in a case of extensive mesenteric lipomatosis in a pony and describing the ultrasonographic improvement following a weight loss programme.

## KEYWORDS

horse, ultrasound, colic, diagnostic, lipomatosis



**FIGURE 1** Ultrasonographic appearance of the lipomatous mass—left inguinal region

## Key points

- Abdominal lipomatosis may be diagnosed by ultrasound examination of the abdomen.
- Weight loss may help reduce the mesenteric fat accumulation.
- Mesenteric lipomatosis can have a favourable outcome when there is no involvement of the intestine layers and no extraluminal obstruction.

**CLINICAL COMMENTARY**

# Colic horse: A diagnostic challenge

**Massimo Magri** 

Clinica Veterinaria Spirano, sp Francesca Spirano, Bergamo, Italy

**Correspondence:** Massimo Magri

Email: magri@clinivetspirano.it

Recurrent colic episodes are a diagnostic challenge. We see increasing cases, mostly involving the large colon. This clinical condition, often termed 'unhappy hindgut syndrome', is not yet well-defined. While obese horses may have substantial mesenteric fat infiltration, we rarely see lipomatosis.

When a strangulating lipoma does occur, it often affects the small intestine and presents as an acute colic episode. It occurs frequently in older horses with a frequency related more to the horse's age than to high body condition score.

Recurrent colic episodes are frustrating for both owners and vets, often addressed on a case-by-case basis, diagnosed nonspecifically and inappropriately as 'colic prone', and frequently treated symptomatically instead of causally. Indeed, sometimes recurrent colic episodes due to large colon entrapment in the nephrosplenic ligament are treated by closing the nephrosplenic space, without investigating the reason why the large colon recurrently moves upwards to the nephrosplenic space. This can prevent the entrapment but does not treat the cause, which remains, potentially causing other symptoms. Indeed, sometimes treating the cause first may render the surgical closure of the nephrosplenic space unnecessary.

The first step in evaluating the cause of the colic episode is a complete clinical examination, the steps of which may need prioritisation and ordering according to the clinical situation and amount of pain present.

We check the heart rate early, certainly before the administration of any pain medicine. However, checking heart rate immediately after a long journey may give misleading results.

If we suspect acute gastric distension, a quick check of the stomach, by trans-abdominal ultrasound, can confirm the need to immediately pass a stomach tube, before performing a rectal examination. In this way, we can avoid the risk of a gastric rupture and have a less painful and more cooperative horse during the remaining work-up.

On the contrary, if marked distension of the abdomen is clearly identifiable at inspection, doing the rectal examination first can allow early trans-rectal decompression, thus avoiding respiratory arrest from high intrabdominal pressure and alleviating the horse's pain. Thus, although the entire examination is necessary, the order of the steps is a matter of good clinical judgement.

The diagnostic work-up of every colic case should include the uniquely useful modality of trans-abdominal ultrasound, especially beneficial in cases in which it is neither possible nor safe for the vet to do a rectal examination, as in the clinical case presented in this issue's article by Lesca et al. (2023).

Although ultrasound equipment is widely available, many equine vets still under-use it in the evaluation of colic. Ultrasound is especially useful during field work-up, even with the cheapest equipment and sub-optimal probes. It yields a wealth of information about the small intestine, large intestine, caecum and large colon, and most importantly, the stomach. It reveals information about distention and motility as well as about the presence and quantity of peritoneal fluid.

It is difficult to evaluate the equine stomach with clinical examination, even with nasogastric intubation, especially in the presence of dry food constipation. Additionally, it is difficult to pass a stomach tube in an uncooperative horse.

On the contrary, trans-abdominal ultrasound of the stomach is easy and quick, and provides unique information. Furthermore, it may guide the decision to pass or not pass a stomach tube, avoiding the stress and danger sometimes accompanying this procedure.

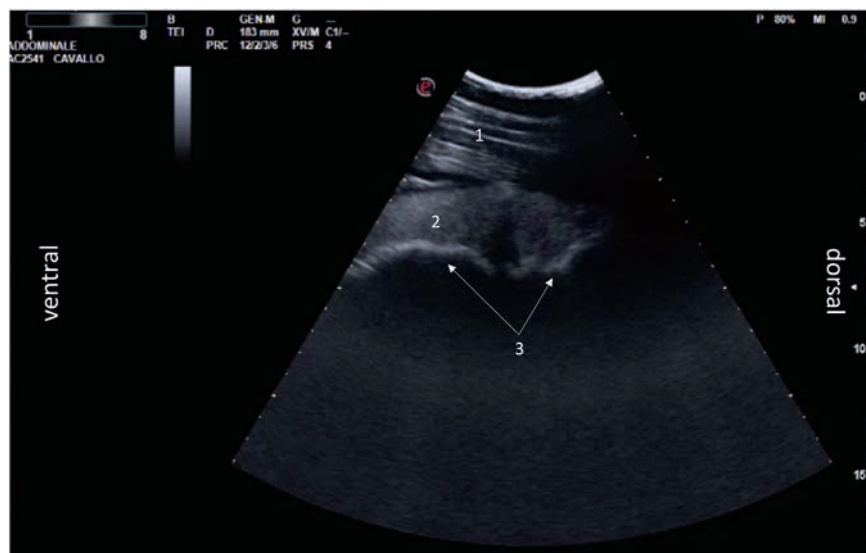Trans-abdominal ultrasound is useful when we suspect constipation of the stomach with dry food. We give the horse 4–5 litres of tap water while evaluating with ultrasound to outline the mass present in the stomach (Figure 1 shows this with aqueous contrast medium).

We do paracentesis in every colic case since abdominal ultrasound is essential to choosing the best location for the tap. Some approaches in this procedure are time consuming, which is why some surgeons do it only when necessary for diagnosis or for determining the need for laparotomy.

However, our paracentesis during the trans-abdominal ultrasound examination of each colic case takes <5 min with quick preparation. We use a 21-gauge needle and determine the depth from the ultrasound. We have never had a complication, not even in the rare case of puncture of an intestinal loop.

Examination of the peritoneal fluid for total protein and lactate is quick and doable in the field, even with cheap instrumentation. The





**FIGURE 1** Trans-abdominal ultrasound with watery contrast medium of the left abdominal wall, 13th intercostal space. 1: Normal abdominal wall; 2: Water administered by nasogastric tube. 3: Solid material, dry food, inside the stomach. This sonogram was obtained with a wide-bandwidth 1–8 MHz convex linear array transducer, operating at 5.0 MHz, at a display depth of 17 cm

information it provides can guide the decision for immediate explorative laparotomy and can also help the prognosis, which allows the owner to make more informed decisions.

Of course, some cases are beyond remedy with the only option being to control the animal's pain. This decision should not be taken lightly and peritoneal fluid examination can guide it.

In this issue's article by Lesca et al. (2023), trans-abdominal ultrasound was fundamental in reaching a presumptive diagnosis and guiding the decision for an explorative laparotomy. Ultrasound in the field can be most useful in determining whether to manage the horse in the field or quickly refer to a clinic when prompt referral can strongly influence the outcome of the case.

Complete examination, including rectal exploration and trans-abdominal ultrasound, is mandatory for even simple-appearing colic cases. Omitting one or the other can involve malpractice liability with all its inconvenience, embarrassment and financial consequences.

The normally present adipose tissue between the abdominal wall and peritoneum can present a special problem in the obese horse because of its thickness and the poor ultrasound characteristics of the adipose.

Adipose tissue is typically found between the abdominal wall and peritoneum; nevertheless, it can seriously compromise ultrasound images in obese horses, like the one described by Lesca et al. (2023). This is due both to its thickness in these horses and the fact that adipose tissue is a poor ultrasound medium.

Worse yet, the thickness of this adipose tissue is not uniform, and even small movements of the ultrasound probe can reveal the thickness differences. Knowing this is important when doing an abdominal tap to obtain a peritoneal fluid sample.

Lesca's sonograms not only clearly identified normal adipose tissue but also demonstrated abnormal layered tissue in another location. This suggested, in conjunction with the other clinical data and the anamnesis of the pony, the need for explorative laparotomy.

While explorative laparotomy is certainly a diagnostic procedure, it is not a shortcut that diminishes our responsibility to collect all data before reaching a diagnosis or initiating an explorative laparotomy.

In some countries, the proliferation of medical insurance for horses tends to influence the decision process. Nevertheless, our ethical code obliges us to do our best to preserve the life, dignity and value of our horses. Collecting all possible data, before reaching a diagnosis, is surely the best way to achieve this goal.

#### CONFLICT OF INTEREST

No conflicts of interest have been declared.

#### ORCID

Massimo Magri  <https://orcid.org/0000-0001-6398-8763>

#### REFERENCE

Lesca, H., Fairburn, A., Fitzharris, L. & Mair, T. (2023) Ultrasonographic identification of mesenteric lipomatosis in a Shetland mare with recurrent colic episodes. *Equine Veterinary Education*, 35, 128, e186–e192. <https://doi.org/10.1111/eve.13653>

**How to cite this article:** Magri, M. (2023) Colic horse: A diagnostic challenge. *Equine Veterinary Education*, 35, 129–130. Available from: <https://doi.org/10.1111/eve.13694>



VETERINARY CONTINUING  
EDUCATION  
COLORADO STATE UNIVERSITY

# BASIC & ADVANCED EQUINE ARTHROSCOPY

AUGUST 23-24, 2023  
AUGUST 24-26, 2023

COLORADO STATE UNIVERSITY VETERINARY CONTINUING EDUCATION

Learn equine arthroscopy from the champions  
of veterinary arthroscopy themselves

Drs. Wayne McIlwraith, Ian Wright, Laurie Goodrich, Chris Kawcak,  
W. Wesley Sutter, Ryan Carpenter, and Brad Nelson will lead two courses:  
Basic Equine Arthroscopy and Advanced Equine Arthroscopy

You'll return to your practice equipped with new skills  
and will be inspired to use them



SCAN TO  
REGISTER NOW

<https://bit.ly/BasicArth23>

<https://bit.ly/AdvArth23>

At the C. Wayne McIlwraith Translational Medicine Institute in Fort Collins, Colorado



C. WAYNE MCILWRAITH  
TRANSLATIONAL  
MEDICINE INSTITUTE  
COLORADO STATE UNIVERSITY



PLATINUM  
PERFORMANCE



[www.CSUVetCE.com](http://www.CSUVetCE.com)



# Manage lameness and joint issues with confidence.

With a single injection of **Spryng™ with OsteoCushion™ Technology**, you have the power to simply, effectively and economically manage lameness and joint issues.

Spryng™ with OsteoCushion™ Technology is an innovative veterinary medical device that takes the treatment of lameness issues into a new arena by addressing the root cause of the conditions — missing and damaged cartilage. Spryng™ aids in the management of joint pain from the loss of cartilage or tissue–bone mechanical malfunction caused by joint disfunction.

When injected into the joint, Spryng™ creates a sponge-like, shock-absorbing matrix — that works with synovial fluid to mimic the protective form and function of natural, healthy joint cartilage. When a horse jumps, runs or performs any movement with joint impact, Spryng™ absorbs and releases synovial fluid in response, with elastic stiffness that complements natural synovial fluid and cartilage dynamics.

Spryng™ also provides a natural scaffold, potentially protecting the joint from further injury, unlike other lameness management options that may only



Learn more and order  
[SpryngHealth.com](https://SpryngHealth.com)



Also available at  
**AmerisourceBergen**  
MWJ Animal Health®



Spryng™ is only available for use by or on the order of a licensed veterinarian.  
Spryng™ with OsteoCushion™ Technology is a veterinary medical device by PetVivo, Inc.  
© PetVivo, Inc, 2023 | SADE-4-0223

**SIMPLE**  
Single injection with rapid results

**LONG LASTING**  
Long duration of joint protection

**INNOVATIVE**  
Address the affliction — helps to restore proper joint mechanics

**A VETERINARY MEDICAL DEVICE**

 **spryng™**  
with OsteoCushion™ Technology



# Three cases of olecranon fracture repair in the standing horse

Pablo Jimenez-Rihuete<sup>1</sup> | Bryan O'Meara<sup>2</sup>

<sup>1</sup>Valley Equine Hospital, Lambourn, UK

<sup>2</sup>Bryan O'Meara Veterinary Consultancy, Newbury, Berkshire, UK

Correspondence: Pablo Jimenez-Rihuete

Email: menezpablo@gmail.com

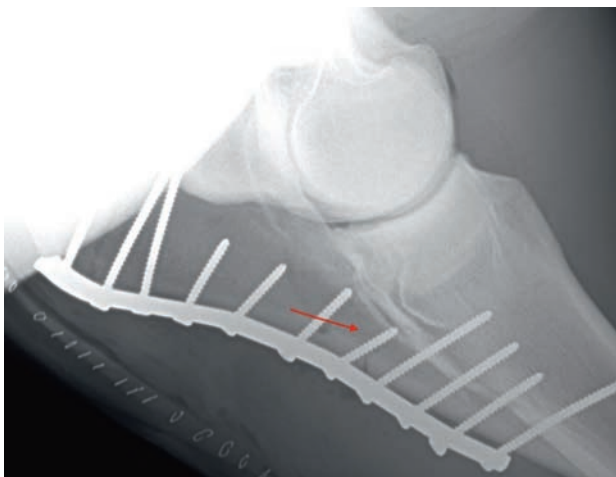
## SUMMARY

Ulnar fractures in three horses were repaired using plate fixation while sedated and restrained in stocks in the standing position. In each horse, the triceps muscle attachment was intact. All horses recovered well from surgery and were stabled for 3 months. The plate was removed three months after surgery in one of the horses because of a surgical site infection. The placement of a lag screw across the fracture line helped to reduce the fracture before placement of the plate in one of the cases. Intraoperative radiographs are difficult to achieve without potentially increasing the chance of contamination. The use of a locking compression plate (LCP) meant that less emphasis was placed on achieving bicortical screws at all screw holes, which was beneficial as radiographic guidance was not employed in these cases until after the plates were placed. Surgical site infections have been reported to reach 11%–20% of cases when repaired under GA. Palpation of the fracture pre- and postreduction, presurgical measurement of

the screw lengths, and the placement of purposely shorter screws near the joint were simple steps employed to ensure the least number of radiographs were required. Conversion to general anaesthesia may be required if the reduction is not achievable or further displacement or inability to achieve extension of the limb was to occur. The length of the incision required for this surgery may increase the risk of developing a surgical site infection when compared to other standing fracture repairs such as lateral condylar fractures of the cannon or sagittal fractures of the pastern, that can be performed through stab incisions. Fractures are the main reason for equine fatalities (71.4%) during anaesthetic recovery. This risk is increased in cases where a fracture repair took place during anaesthesia. Standing surgical procedures carry a risk of injury to the veterinary surgeon and the other members of staff involved. In all three cases, the fracture was adequately reduced, and the horses returned to showjumping, pleasure riding and pasture turnout with a view to begin training (Figure 1). This is the first small case series describing olecranon fracture repair in the standing horse. It is a surgical technique that negates the risks of general anaesthesia; however, there are challenges and increased risks as outlined above.

## KEYWORDS

horse, elbow, fracture, repair, standing



**FIGURE 1** Mediolateral radiograph of the left elbow after surgery showing a complete reduction of the fracture (Case 1)

## Key points

- Three olecranon fractures were repaired successfully with the horse standing.
- Olecranon fracture repair standing has its limitations, including difficulties in obtaining intraoperative radiographs and an increased potential for surgical site infections.
- Standing surgical repair of olecranon fractures can potentially help reduce postanaesthetic fatalities.

# Management of ulna fractures in adult horses

Jörg A. Auer<sup>1</sup>  | Anton E. Fürst<sup>2</sup> | Regula Bettschart-Wolfensberger<sup>2</sup>  | Matthias Haab<sup>3</sup>

<sup>1</sup>Lenzburg, Switzerland

<sup>2</sup>Vetsuisse Faculty, University of Zurich – Equine Hospital Zurich, Lenzburg, Switzerland

<sup>3</sup>Feldbach, Switzerland

**Correspondence:** Jörg Auer  
Email: [jauer@swissonline.ch](mailto:jauer@swissonline.ch)

**Keywords:** horse, internal fixation, kick injuries, LCP, ulna fracture

## INTRODUCTION

Ulna fractures in adult horses are most frequently the result of a kick by another horse on pasture (Donati et al., 2018). In foals, the fracture may occur in association with a fall to one side during halter training (Watkins et al., 2019). The fracture may develop at the body of the ulna, the olecranon process representing the proximal end of the ulna or a combination of both. By far, the majority of patients show a marked lameness immediately after the accident (AAEP 3-4/5, 2020). Different types of ulna fractures have been identified and defined (Nixon, 2020; Watkins et al., 2019), of which type-1 fractures are only diagnosed in foals and young adult horses. The latter represents the most demanding management category.

The classical clinical sign is the dropped elbow stance, which has to be differentiated from the forelimb position of a horse with a radial paralysis (Nixon, 2020) and other pathologies of the upper limb. The triceps muscle inserts at the proximal end of the olecranon process and distracts the proximal fragment of the fracture when it contracts, resulting in loss-of-carpal extension. The amount of swelling noted in the elbow and the triceps region varies and to some extent reflects the amount of trauma that occurred. A small skin abrasion or open wound in the ulnar region caused by the kick represents another indication of an ulna fracture. On some occasions, the horse is able to bear weight on the leg and it is only minimally lame. In these cases, the fracture is mainly located distal to the cubital joint and potentially enters the cubital joint at the ulnar notch, where no articular cartilage is located (type 5, Nixon, 2020; Watkins et al., 2019). In the type-1a fractures, the apophysis is distracted from the rest of the ulna because of triceps pull. In the other fracture types, fragment distraction occurs to a lesser extent but still inactivates the carpal extension mechanism, at least to some extent.

Because of space constraints, this clinical commentary concentrates on the surgical management of ulna fractures in adult horses.

More in-depth information on the management of ulna fractures can be found in the recent literature (Nixon, 2020; Watkins et al., 2019; Wright, 2022).

## MANAGEMENT

### First aid management

Any wound should be attended to, carefully cleaned and protected by a water-soluble dressing. Administration of broad-spectrum antibiotics at that time is recommended.

The most effective limb support and protection of the fracture site can be achieved through the application of regular forelimb bandage up to the proximal aspect of the ulna reinforced with a 'U'-shaped splint created from a PVC pipe (Fürst, 2019). This maintains the carpus in extension and allows the patient to bear full weight on the fractured limb, which helps prevent the development of laminitis in the other forelimb and improves the patient's status during transportation.

### Non-surgical management

This type of management should only be applied in cases where the animals bear near to full weight on the limb, and the fragments are only minimally displaced. It is best to support the limb during the initial 2 weeks with a splint bandage that does not incorporate the foot. It is advisable to take follow-up radiographs after 3 weeks. In the presence of signs of bone healing, the management should be continued. In cases with a lack of signs of bone healing or abnormal widening of the fracture gap, the fracture should be treated surgically (see below). Strict stall rest for at least the first month is a must.

Following that, the management is adapted in relation to clinical signs of improvement, radiographically visible new bone formation and the general condition of the patient.

The only literature listing a prognosis for non-surgical management of ulna fractures is more than 35 years old (Wilson & Riedesel, 1985). The results were not good, as only 33% of the 43 treated horses were sound at follow-up. Additionally, the time to healing was several months longer than surgically treated horses (Wilson & Riedesel, 1985).

## Surgical management

Open reduction and internal fixation (ORIF) is the treatment of choice for the great majority of simple and multi-fragment fractures of the ulna (Nixon, 2020; Watkins et al., 2019). In selected cases, the fracture can be successfully fixed by means of multiple cerclage wires and strategically placed screws (Martin et al., 1995).

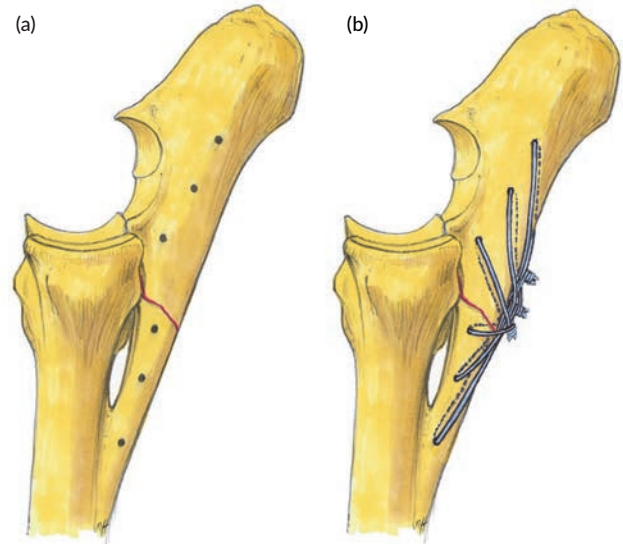
The originally described approach to the caudal aspect of the ulna by Milne and Turner (1979) is still used today (Nixon, 2020; Watkins et al., 2019; Wright, 2022). The skin is incised at the lateral aspect of the top of the olecranon process, immediately followed by a curved incision towards the caudal aspect of the forearm from where the incision is extended distally, dependent upon the location and complexity of the fracture. The subcutaneous tissues and the fascia around the muscles are sharply severed, followed by blunt separation of the bellies of the *ulnaris lateralis* and the ulnar head of the deep digital flexor muscles, leading directly to the caudal ulnar body. At the most proximal part of the olecranon process, the dense fibrous attachments of the aponeuroses of the ulnar head of the deep digital flexor and the flexor *carpi ulnaris* muscles are partly sharply severed to facilitate easy access to the bone.

The caudal aspect of the ulna is exposed to a considerable amount of tensile force. Therefore, the application of a plate or cerclage wires to that region provides superior strength to the fixation, as plates and wires are strongest under tension (Frigg, 2001; Wagner & Frigg, 2006).

## Cerclage wires

Cerclage wire treatment of olecranon fractures is mostly performed in foals with type 1 fractures, frequently in association with pins to assure axial alignment of the fragment with the ulna.

In adult horses, the technique is rarely applied, mainly in cases with good fragment alignment and no or minimal fragment displacement, where plate application may have been an 'overkill'. After accessing the ulna, the same number of 2.5 mm holes (2–3) are drilled in lateral-to-medial direction distal and proximal to the fracture line (Figure 1a). One proximal and one distal hole are united with a 1.25 mm cerclage wire in a figure-of-8 configuration. It is advisable to form a loop of wire opposite the location where the two wire ends are twisted together. This facilitates even tightening of the wire on



**FIGURE 1** (a) Artist drawing of the lateral aspect of radius and ulna depicting the drill holes in the ulna for application of the three cerclage wires in figure-of-8 fashion (b).

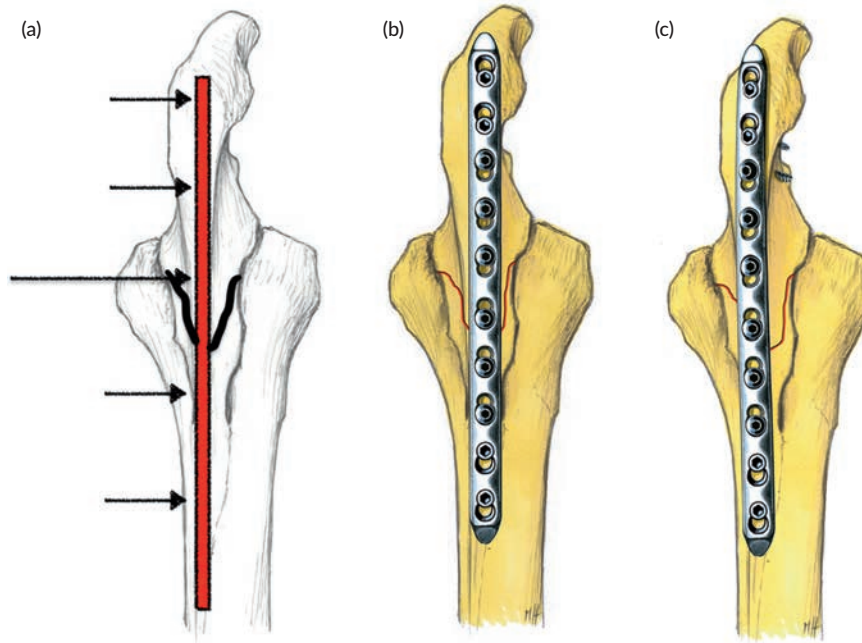
both sides of the ulna. Once all wire fixations are in place (Figure 1b) and all the wire loops are checked for tightness, the surgical site is flushed, followed by apposition of the different layers and suture closure of the skin.

## Plates

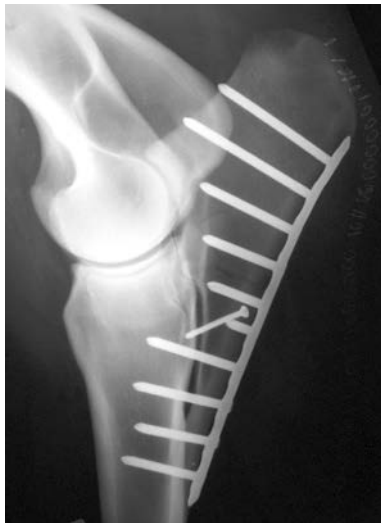Plate application to the caudal aspect of the ulna is presently the treatment of choice in foals and adult horses. There are a number of principles that have to be strictly adhered to for a successful outcome:

1. Whenever possible, a narrow plate should be selected allowing the screws to be inserted through the plate holes into good bone. The plate holes are arranged in one line in the narrow plates, whereas in the broad plate the holes are arranged alternately slightly to the left and right side of the long axis of the plate, making screw insertion somewhat more challenging, especially at the distal end of the plate, where inadvertent screw placement into the lateral radial cortex may lead to complete fracture of the radius (see later).
2. Position the plate at the level of the olecranon perpendicular to the medial side of the olecranon, which results in the plate coming to lie more to the medial side of the olecranon/ulna (Figure 2a). If the plate is positioned more laterally, it tilts to the lateral aspect resulting in the screws exiting at the medial aspect (Figure 2c).
3. Contrary to Nixon (2020), these two main authors propose that the first two screws are inserted towards the ends of the plate, for example the second hole from the top and the bottom. This assures that the entire length of the plate comes to lie on the caudal aspect of the ulna.





**FIGURE 2** (a) Symbolic representation of a 10-hole locking compression plate (LCP) positioned to the caudal aspect of the ulna. The short arrows represent the locations of locking head screws (LHSs), the large arrow location of cortex screw placed in lag fashion across the fracture. The remaining screws are cortex screws. (b) Artist drawing of a narrow LCP applied to the caudal aspect of the ulna. The plate is positioned more to the medial aspect of the bone to prevent exit of the screw across the medial cortex of the bone. (c) with the plate positioned more towards the lateral aspect of the bone, it is easier to insert screws that exit through the medial cortex. This is, especially, important when LHSs are placed, as the direction these screws are placed has to be orthogonal in every plane relative to plate surface.



**FIGURE 3** Lateromedial radiographic projection of an ulna fracture repaired with a 10-hole LCP. All screws inserted through the plate are LHSs. One 3.5 mm cortex screw is placed in lag technique across the fracture. Note, the two most proximal screws exit at cranial edge of the olecranon.

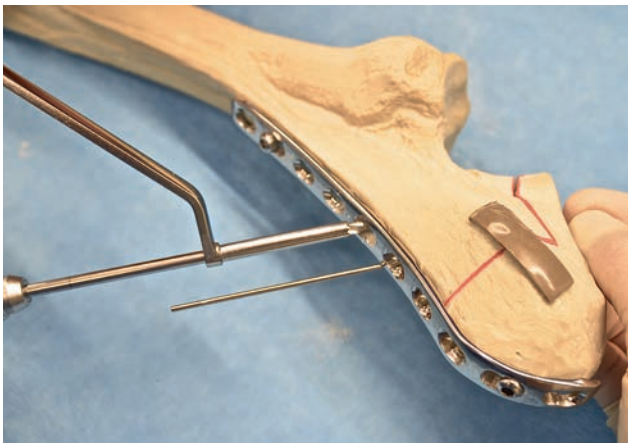4. As a general rule longer plates should be used, especially at the level of the olecranon (Figure 3). Therefore, the top end of the plate should not be positioned at the mid-level of the olecranon because this may potentially lead to a fracture of the bone at the top end of plate.

5. As a rule, the screws should only be placed into the ulna; the bone being exposed to substantial tensile forces strong enough to withstand all fracture distracting forces. However, frequently the screws are extended across the caudal cortex of the radius for additional strength (Figure 3). The cranial and the lateral cortex of the radius should never be penetrated by drill hole/screw. In foals up to at least 7 months of age, the caudal cortex of the ulna should not be penetrated as this prevents the proximal displacement of the ulna along with the growth of the proximal radial epiphysis leading to subluxation of the distal humerus and malformation of the anconeal process (Smith et al., 1991). Therefore, the fracture healing phase should be monitored radiographically at 2-month intervals and if such a subluxation is noted, implant removal is suggested. In severe cases a distal ulnar osteotomy allows correction of the problem (Klopfenstein-Bregger et al., 2011).

The locking compression plate (LCP) has established itself as the implant of choice for the surgical treatment of ulna fractures (Auer, 2019; Jackson et al., 2011; Jacobs et al., 2017; Levine & Richardson, 2007). The LCP is minimally more expensive than a dynamic compression plate (DCP); it is the screws that increase the implant prices significantly. A research study evaluating four different implants under in vitro conditions (Florin et al., 2005) revealed that the LCP construct is superior to the other constructs—one of which represented the limited contact compression plate (LC-DCP)—and that only two locking head screws (LHS) inserted proximal to the fracture line and two LHS implanted distal to it, are necessary to

provide this superior strength. Additional LHSs do not add additional strength but increase the implant costs significantly. Also, LHSs have to be inserted perpendicular to the LCP in all planes limiting the surgeon's ability to implant the screw into solid bone (Frigg, 2001; Sommer et al., 2003; Wagner & Frigg, 2006). The plate holes allow cortex screws to be implanted at various angles, and, therefore, provide the surgeon with more flexibility for screw insertion. Therefore, the use of LHSs and cortex screws in a construct result in an ideal combination. First, a cortex screw is inserted in neutral position to fix the plate to the bone, followed by a second cortex screw implanted in the load position creating axial compression across the fracture plane. Alternatively, the push-pull device can be used to press the plate onto the bone surface. It is important not to 'overcompress' the fracture because it may actually open the fracture line at the cranial aspect near the joint. Also, with the use of the LCPs, axial compression of the fracture with separate cortex screws has lost its importance because of the superior strength of the LHS (Auer, 2019; Sommer et al., 2003). At least one cortex screw should be placed on both sides to the fracture to press the plate onto the bone surface. Any screw placed across a fracture plane should be inserted in lag fashion. Next, the two LHSs are inserted on either side of the fracture plane, as these screws have to be inserted perpendicular to the plate, followed by filling of the remaining empty screw holes with cortex screws, or if preferred, with LHSs. As the cranial cortex of the olecranon is very strong, the screws should engage this part of the olecranon, if possible.

The most important screws in the fixation of Type 1B fractures are the ones crossing the metaphyseal fracture plane. Therefore, it is important to assure that the cortex screws extend to the cranial edge of the bone. This can be achieved by inserting a Steinmann pin along the medial cortex of the olecranon in cranial direction and oriented parallel to the future screw angle. The subsequent drill hole is prepared parallel to the pin in all directions (Figure 4). If the cranial fragment is thin, it may be best not to insert the screw in lag fashion,



**FIGURE 4** Inserting a Steinmann pin along with the medial bone surface of the ulna provides a good aid for drilling the screw hole along with the olecranon and assuring exit of the hole at the cranial edge of the bone. Therefore, the drill guide and drill should be aligned parallel to the pin in all planes.

as inadvertent overdrilling of the fragment may lead to stripping of the few threads left in the fragment. In such cases, placement of a position screw (Auer, 2019) is preferred.

In plate fixation of type 5 fractures, the plate mandates further distal placement of the implant to a region where the ulna is very thin, and the screws need to incorporate also the caudal cortex of the radius. Therefore, cortex screws should be inserted through the distal two plate holes to prevent inserting the LHSs into the lateral cortex of the radius, if the plate is placed far lateral. Screw insertion into the lateral radial cortex may predispose to catastrophic failure of the construct through a complete fracture of the radius (Figure 5) (Kümmerle et al., 2013). Another option to prevent such an incident is the twisting of the distal aspect of the plate to facilitate oblique insertion of the screws.

In severely comminuted and displaced fractures, double plating may be necessary to achieve adequate fracture reconstruction and stability to withstand recovery from anaesthesia and the convalescent period. In these cases, initial application of the lateral plate is encouraged (Nixon, 2020). Occasionally additional cortex screws are inserted across fragments outside of the plate(s).

## Horses operated on in standing position (SP) versus under general anaesthesia (GA)

Surgical management using either technique requires aseptic surgery and the application of meticulous internal fixation techniques. Frequently, intraoperative radiography is indicated, which can more easily be applied to the patient under GA than in SP (Jimenez-Rihuete & O'Meara, 2023).

Presently, the trend is shifting to perform internal fixation of fractures in horses towards SP, as with almost all other surgical interventions. The main reason for the change is to avoid the risk of complications during anaesthesia and severe injuries during the recovery from GA and minimal reduction in costs. Anaesthesia risk in horses is much higher than in other domesticated species (Dugdale et al., 2016) and complications during recovery can result in fatal outcomes. However, when the outcome at 7 days post-surgery was examined, and not only the immediate postsurgical outcome, it was shown in 28 horses for standing fracture repair, that death rate was 3.6% as opposed to 4.2% in 166 horses undergoing fracture repair under general anaesthesia (Gozalo-Marcilla et al., 2021). This ongoing study with to date more than 90 collaborating centres will hopefully elucidate important factors determining outcomes in a larger number of horses.

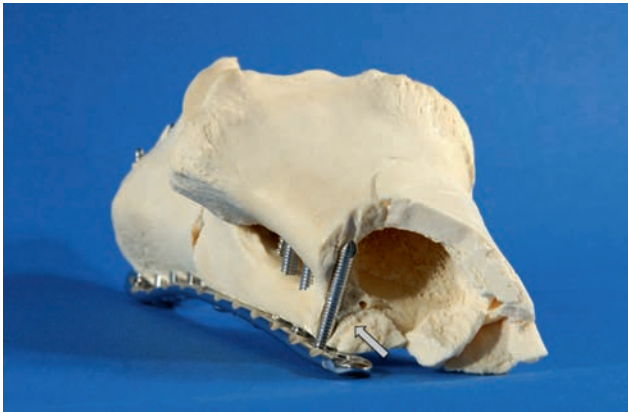Several factors have to be taken into account to make a decision based on facts to select one of the two techniques.

## Position of the surgeon

When the horse is under GA, the surgeon can in most cases adjust the height of the surgery table allowing him/her to operate in

a comfortable body position. This is preferred compared to the frequently crouched position when the horse is operated on in SP. During a 'standing' ulna fracture repair, the surgeon can sit on a chair, which makes it difficult to quickly get out of danger should the patient make a rapid pain-induced defensive movement. Surgical interventions of long duration (>2 h) are definitely easier to perform with the horse under GA.

One option to allow surgery on the horse in SP is to install a pit next to the stand where the horse is placed during the surgical intervention, which allows the surgeon and assistants to stand in an upright position during the intervention (Figure 6a). It is important that the pit can be covered when not used for surgery on a standing horse (Figure 6b). By placing different solid boxes into the pit, the surgeon can adjust his/her position relative to anatomical location of the surgery site. Screw insertion across a proximal palanx fracture is show in Figure 6c.



**FIGURE 5** Post-mortem picture of a fractured radius caused during recovery. Note, the fracture occurred because the second most distal LHS was placed across the lateral cortex of the radius (arrow).

## Surgical technique

Adequate preparation of the surgical site is a must for both techniques. It is a fact that this is easier to maintain while the horse is under GA, therefore, maintaining asepsis throughout the procedure. To give the horse a bath prior to surgery is good practice for both techniques, but it is more important in horses undergoing surgery in SP.

If a stand is used for the surgery, it should have adjustable sides to assure easy access to the surgery site. Standing fracture fixations require a very experienced team of surgeons who not only know the surgical technique but also know horses well and can thus interpret them with confidence during the procedure. One author (AF) prefers free-standing horses for standing fixations of ulna fractures and practically never operates on these patients in an examination stand. Thus, fine movements of the horses can be interpreted very well. Also, the horses' limbs must not be fixed to allow them to make small corrective movements in case of temporary instability. Draping of the horse proximal to the surgery site requires a flexible approach. The limbs are covered with sterile bandages, the ground itself is also covered sterilely and the rest of the horse's body is wrapped with sterile drapes (Figure 7).

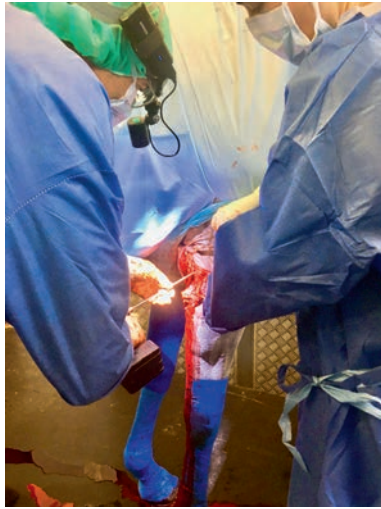The surgical approach to the fractured bone and fracture reduction is easier to perform with the horse under GA. With the horse in SP, it may not be possible to reduce the fracture anatomically without risking major pain-induced defensive movements, therefore, having to accept a less than perfect fracture repair. Only minimally displaced fractures should be selected for standing fracture fixation; usually, they are already very well reduced in the standing horse, therefore, only minor reduction corrections are necessary. In most cases, the actual application of the implants is not different in the two techniques. But experience has shown that it is easier for a right-handed person to operate on a fracture of the left forelimb in the SP and vice versa.

Even though preparation for aseptic surgery including draping of the horses operated on in SP is less perfect than in patients undergoing GA, it has been shown that the infection rate is in the same range



**FIGURE 6** (a) A pit (shown when covered) was installed next to a stand to allow the surgeon to perform surgery in standing position while the horse is standing. (b) When used, the plates covering the pit are elevated and placed aside. (c) Screw insertion across a proximal phalanx fracture with the surgeon and assistant operating from the pit. Image, courtesy of Carlos Veiga, Horse Center, Petropolis—Rio de Janeiro, Brazil.





**FIGURE 7** An ulna fracture is being repaired with the horse in standing position and not secured through a stand.

for both techniques. This is probably related to the fact that general anaesthesia generally depresses the immune system. Furthermore, it is the personal experience of one surgeon (AF) that the risk of laminitis appears to be higher in horses operated under GA.

### General anaesthesia versus sedation and regional anaesthesia

General anaesthesia for fracture repair can only be provided in clinics with the necessary equipment such as inhalation anaesthesia machine, monitoring equipment and a suitable recovery area. To provide sedation and regional anaesthesia needs only a needle, a syringe and the knowledge of different sedation regimes and anatomy of the horse for the relevant local blocks.

Problems that occur as a consequence of anaesthesia are manifold, and in particular in horses, survival rate following surgeries under general anaesthesia is lower than in other domesticated species. In particular, fracture repair in horses carries an even higher fatality risk than colic surgery (Gozalo-Marcilla et al., 2021). This is probably most often as a result of fatal problems in recovery. It is probable that centres with well-trained personnel, and well-equipped recovery boxes (slings, ropes or nets), or even pool recovery systems, to help the horses gain their feet, have a better outcome in this respect.

However, surgery under standing sedation also carries a fatality risk of 0.2%, as recently shown in the newest version of the CEPEF (Confidential Enquiry into Perioperative Equine Fatality) studies (Gozalo-Marcilla et al., 2021). In these preliminary results of 154 horses undergoing fracture repair under general anaesthesia, 95.8% of horses were alive within 7 days of surgery and of 27 horses undergoing fracture surgery under standing sedation 96.4% were alive.

Inhalation anaesthetic agents have immunomodulatory effects (Anderson et al., 2014a), which for horses undergoing fracture

repair could be disadvantageous, as the innate immune response for wound healing and resistance to infection is very important. However,  $\alpha_2$  adrenoceptor agonists and opioids that are mainly used for standing sedation, also negatively impair immune function (Anderson et al., 2014b). To one author's (RBW) knowledge there are no comparative studies in horses to further investigate the effect of general anaesthesia as opposed to standing sedation on immune function, and therefore, in this respect, no recommendations can be made yet. It will be important to perform fracture repair outcome studies that compare survival following standing or general anaesthesia surgery at, for example, 3, 6 and 12 months.

### AUTHOR CONTRIBUTIONS

J. Auer, A. Fürst and R. Bettschart-Wolfensberger all contributed significantly to the manuscript. M. Haab created Figures 1 and 2.

### FUNDING INFORMATION


None.

### CONFLICT OF INTEREST

No conflicts of interest have been declared.

### ORCID

Jörg A. Auer  <https://orcid.org/0000-0002-4062-9802>

Regula Bettschart-Wolfensberger  <https://orcid.org/0000-0001-6259-9678>

### REFERENCES

- AAEP (2020) Lameness examination guidelines. <https://aaep.org/horse-health/lameness-exams-evaluating-lame-horse>.
- Anderson, S.L., Duke-Novakovski, T. & Singh, B. (2014a) The immune response to anesthesia: part 1. *Veterinary Anaesthesia and Analgesia*, 41(2), 113–126. <https://doi.org/10.1111/vaa.12125>
- Anderson, S.L., Duke-Novakovski, T. & Singh, B. (2014b) The immune response to anesthesia: part 2 sedatives, opioids, and injectable anesthetic agents. *Veterinary anaesthesia and analgesia*, 41(6), 553–566. <https://doi.org/10.1111/vaa.12191>
- Auer, J.A. (2019) Principles of fracture treatment. In: Auer, J.A., Stick, J.A., Kümmeler, J.M. & Prange, T. (Eds.) *Equine Surgery*, 5th edition. St. Louis: Elsevier Saunders, pp. 1277–1314.
- Donati, B., Fürst, A.E., Hässig, M. & Jackson, M.A. (2018) Epidemiology of fractures: the role of kicking injuries in equine fractures. *Equine Veterinary Journal*, 50, 580–586.
- Dugdale, A.H.A., Obhrai, J. & Cripps, P.J. (2016) Twenty years later: a single-Centre, repeat retrospective analysis of equine perioperative mortality and investigation of recovery quality. *Veterinary Anaesthesia and Analgesia*, 43, 171–178.
- Florin, M., Arzdorf, M., Linke, B. & Auer, J.A. (2005) Assessment of stiffness and strength of four different implants available for equine fracture treatment: a study on a 2- degree oblique long bone fracture model using a bone substitute. *Veterinary Surgery*, 34, 231–238.
- Frigg, R. (2001) Locking compression plate (LCP). An osteosynthesis plate based on the dynamic compression plate and the point contact fixator (PC-fix). *Injury*, 32(Suppl 2), B63–B69.
- Fürst, A.E. (2019) Emergency treatment and transport of equine fracture patients. In: Auer, J.A., Stick, J.A., Kümmeler, J.M. & Prange, T. (Eds.) *Equine Surgery*, 5th edition. St. Louis: Elsevier Saunders, pp. 301–312.

- Gozalo-Marcilla, M., Bettschart-Wolfensberger, R., Johnston, M., Taylor, P.M. & Redondo, J.I. (2021) Data collection for the fourth multi-centre confidential enquiry into perioperative equine fatalities (CEPEF4) study: new technology and preliminary results. *Animals-Basel*, 11(9), 2549. <https://doi.org/10.3390/ani11092549>
- Jackson, M.A., Kummer, M., Auer, J.A., Hagen, R. & Fürst, A. (2011) Treatment of type 2 and 4 olecranon fractures with locking compression plate osteosynthesis in horses: a prospective study (2002-2008). *Veterinary and Comparative Orthopaedics and Traumatology*, 24(1), 57-61.
- Jacobs, C.C., Levine, D.G. & Richardson, D.W. (2017) Use of locking compression plates in ulnar fractures of 18 horses. *Veterinary Surgery*, 46(2), 242-248.
- Jimenez-Rihuete, P. & O'Meara, B. (2023) Three cases of olecranon fracture repair in the standing horse. *Equine Veterinary Education*, 35, 131, e193-e199. <https://doi.org/10.1111/eve.13686>
- Klopfenstein-Bregger, M.D., Jackson, M.A., Kummer, M., Kircher, P.A., Auer, J.A. & Fürst, A.E. (2011) Ulnar osteotomy for treatment of cubital subluxation, following locking compression plate osteosynthesis of a radius fracture in a foal. *Equine Veterinary Education*, 23(9), 455-461.
- Kümmerle, J.M., Kühn, K., Bryner, M. & Fürst, A.E. (2013) Equine ulnar fracture repair with locking compression plates can be associated with inadvertent penetration of the lateral cortex of the radius. *Veterinary Surgery*, 42(7), 790-794.
- Levine, D.G. & Richardson, D.W. (2007) Clinical use of the locking compression plate (LCP) in horses: a retrospective study of 31 cases (2004-2006). *Equine Veterinary Journal*, 39, 401-406.
- Martin, F., Richardson, D.W. & Nunamaker, D.M. (1995) Use of tension band wires in horses with fractures of the ulna: 22 cases (1980-1992). *Journal of the American Veterinary Medical Association*, 207, 1085-1089.
- Milne, D. & Turner, A.S. (1979) *An Atlas of Surgical Approaches to the Bones of the Horse*. Philadelphia: W. B. Saunders.
- Nixon, A.J. (2020) Fractures of the ulna. In: Nixon, A.J. (Ed.) *Equine Fracture Repair*, 2nd edition. Hoboken: Wiley Blackwell, pp. 545-566.
- Smith, B.L., Auer, J.A., Taylor, T.S., Hulse, D.S. & Longnecker, M.T. (1991) Use of orthopedic markers for quantitative determination of proximal radial and ulnar growth in foals. *American Journal of Veterinary Research*, 52(9), 1456-1460.
- Sommer, C., Gauthier, E., Müller, M., Helfet, D.L. & Wagner, M. (2003) First clinical results of the locking compression plate (LCP). *Injury-International Journal of the Care of the Injured*, 34, S-B43-S-B54.
- Wagner, M. & Frigg, R. (2006) *AO manual of fracture management: internal fixators—concepts and cases using LCP and LISS*. Stuttgart: Thieme Verlag.
- Watkins, J.P., Glass, K.G. & Kümmerle, J.M. (2019) Radius and ulna. In: Auer, J.A., Stick, J.A., Kümmerle, J.M. & Prange, T. (Eds.) *Equine Surgery*, 5th edition. St. Louis, Missouri: Elsevier, pp. 1667-1689.
- Wilson, D.G. & Riedesel, E. (1985) Nonsurgical management of ulnar fractures in the horse: a retrospective study of 43 cases. *Veterinary Surgery*, 14, 283-286.
- Wright, I.M. (2022) In: Wright, I.M. (Ed.) *Fractures in the horse*. Oxford: Fractures of the ulna, Wiley Blackwell, pp. 557-584.

**How to cite this article:** Auer, J.A., Fürst, A.E., Bettschart-Wolfensberger, R. & Haab, M. (2023) Management of ulna fractures in adult horses. *Equine Veterinary Education*, 35, 132-138. Available from: <https://doi.org/10.1111/eve.13710>

#### Brief Summary of Prescribing Information.

**DORMOSEDAN®**  
(detomidine hydrochloride)



Sedative and Analgesic For Use in Horses Only

Sterile Solution  
10 mg/mL

**CAUTION:** Federal law restricts this drug to use by or on the order of a licensed veterinarian.

**INDICATIONS:** Dormosedan® is indicated for use as a sedative and analgesic to facilitate minor surgical and diagnostic procedures in mature horses and yearlings. It has been used successfully for the following: to calm fractious horses, to provide relief from abdominal pain, to facilitate bronchoscopy, bronchoalveolar lavage, nasogastric intubation, nonreproductive rectal palpations, suturing of skin lacerations, and castrations. Additionally, an approved, local infiltration anesthetic is indicated for castration.

**CONTRAINDICATIONS:** Dormosedan® should not be used in horses with pre-existing AV or SA block, with severe coronary insufficiency, cerebrovascular disease, respiratory disease, or chronic renal failure. Intravenous potentiated sulfonamides should not be used in anesthetized or sedated horses as potentially fatal dysrhythmias may occur.

Information on the possible effects of detomidine hydrochloride in breeding horses is limited to uncontrolled clinical reports; therefore, this drug is not recommended for use in breeding animals.

**WARNINGS:** Do not use in horses intended for human consumption. Not for human use. Keep out of reach of children.

**HUMAN SAFETY INFORMATION:** Care should be taken to assure that detomidine hydrochloride is not inadvertently ingested as safety studies have indicated that the drug is well absorbed when administered orally. Standard ocular irritation tests in rabbits using the proposed market formulation have shown detomidine hydrochloride to be nonirritating to eyes. Primary dermal irritation tests in guinea pigs using up to 5 times the proposed market concentration of detomidine hydrochloride on intact and abraded skin have demonstrated that the drug is nonirritating to skin and is apparently poorly absorbed dermally. However, in accordance with prudent clinical procedures, exposure of eyes or skin should be avoided and affected areas should be washed immediately if exposure does occur. As with all injectable drugs causing profound physiological effects, routine precautions should be employed by practitioners when handling and using loaded syringes to prevent accidental self-injection.

**PRECAUTIONS:** Before administration, careful consideration should be given to administering Dormosedan® to horses approaching or in endotoxic or traumatic shock, to horses with advanced liver or kidney disease, or to horses under stress from extreme heat, cold, fatigue, or high altitude. Protect treated horses from temperature extremes. Some horses, although apparently deeply sedated, may still respond to external stimuli. Routine safety measures should be employed to protect practitioners and handlers. Allowing the horse to stand quietly for 5 minutes before administration and for 10-15 minutes after injection may improve the response to Dormosedan®.

Dormosedan® is a potent  $\alpha_2$ -agonist, and extreme caution should be exercised in its use with other sedative or analgesic drugs for they may produce additive effects. When using any analgesic to help alleviate abdominal pain, a complete physical examination and diagnostic work-up are necessary to determine the etiology of the pain.

Food and water should be withheld until the sedative effect of Dormosedan® has worn off.

**ADVERSE REACTIONS:** Occasional reports of anaphylactic-like reactions have been received, including 1 or more of the following: urticaria, skin plaques, dyspnea, edema of the upper airways, trembling, recumbency, and death. **The use of epinephrine should be avoided since epinephrine may potentiate the effects of  $\alpha_2$ -agonists.** Reports of mild adverse reactions have resolved uneventfully without treatment. Severe adverse reactions should be treated symptomatically. As with all  $\alpha_2$ -agonists, the potential for isolated cases of hypersensitivity exist, including paradoxical response (excitation).

**SIDE EFFECTS:** Horses treated with Dormosedan® exhibit hypertension. Bradycardia routinely occurs 1 minute after injection. The relationship between hypertension and bradycardia is consistent with an adaptive baroreceptor response to the increased pressure and inconsistent with a primary drug-induced bradycardia. Piloerection, sweating, salivation, and slight muscle tremors are frequently seen after administration. Partial transient penis prolapse may be seen. Partial AV and SA blocks may occur with decreased heart and respiratory rates. Urination typically occurs during recovery at about 45-60 minutes posttreatment, depending on dosage. Incoordination or staggering is usually seen only during the first 3-5 minutes after injection, until animals have secured a firm footing.

Because of continued lowering of the head during sedation, mucus discharges from the nose and, occasionally, edema of the head and face may be seen. Holding the head in a slightly elevated position generally prevents these effects.

**OVERDOSAGE:** Detomidine hydrochloride is tolerated in horses at up to 200 mcg/kg of body weight (10 times the low dosage and 5 times the high dosage). In safety studies in horses, detomidine hydrochloride at 400 mcg/kg of body weight administered daily for 3 consecutive days produced microscopic foci of myocardial necrosis in 1 of 8 horses.

**HOW SUPPLIED:** Dormosedan® is supplied in 5- and 20-mL multidose vials.

NADA #140-862, Approved by FDA

Manufactured by:

**ORION PHARMA**  
Orion Corporation  
Espoo, Finland

**zoetis** Distributed by:  
Zoetis Inc.  
Kalamazoo, MI 49007

Revised: January 2013

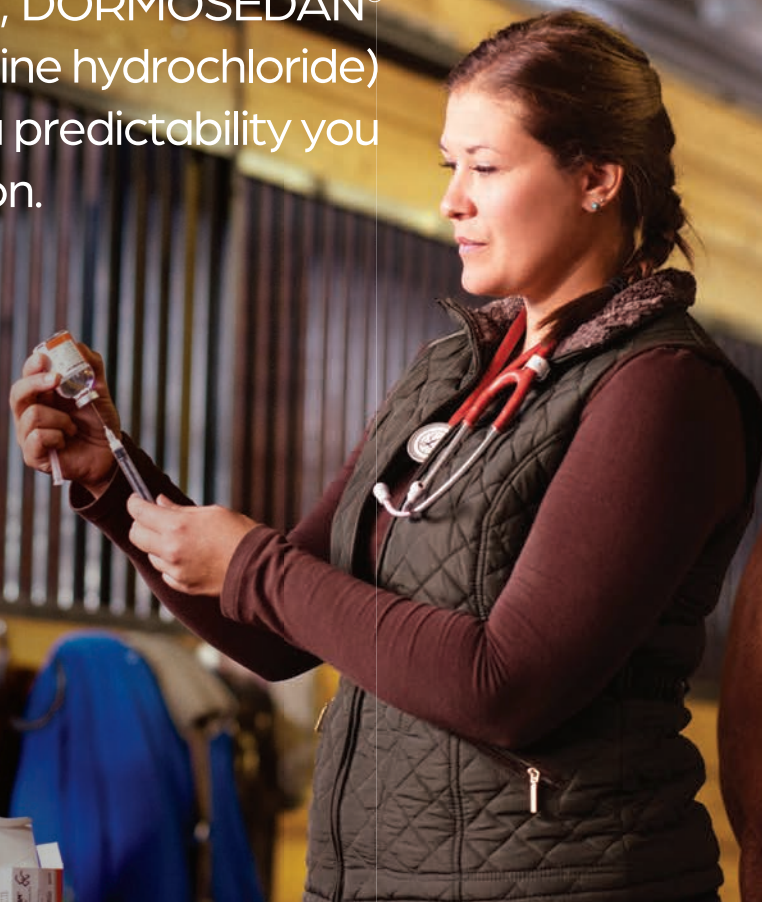107224US-10A&P

Made in Finland



# No two days spent treating equine patients are the same.

As the #1 vet-trusted equine sedative<sup>1</sup>, DORMOSEDAN<sup>®</sup> (detomidine hydrochloride) gives you predictability you can rely on.



**DORMOSEDAN<sup>®</sup>**  
(detomidine hydrochloride)

**Make the trusted choice<sup>1</sup>** for consistent results backed by industry-leading support from Zoetis. Contact your Zoetis representative for more information or visit **DORMOSEDAN.com** today.

**IMPORTANT SAFETY INFORMATION:** Do not use DORMOSEDAN STERILE SOLUTION in horses with pre-existing atrioventricular (AV) or sinoatrial (SA) block, with severe coronary insufficiency, cerebrovascular disease, respiratory disease or chronic renal failure. Intravenous potentiated sulfonamides should not be used in anesthetized or sedated horses. Careful consideration should be given to horses approaching or in endotoxic or traumatic shock, to horses with advanced liver or kidney disease, or to horses under stress from extreme heat, cold, fatigue, or high altitude. Do not use in horses intended for human consumption. Handle dose syringes with caution to avoid direct exposure to skin, eyes or mouth. See Brief Summary of prescribing information on page 138.

<sup>1</sup>Data on file: 2020 Equine Pain & Sedation Market Research Study.

All trademarks are the property of Zoetis Services LLC or a related company or a licensor unless otherwise noted. Dormosedan is a registered trademark of Orion Corporation distributed by Zoetis Inc. © 2021 Zoetis Services LLC. All rights reserved. GEQ-00748

**zoetis**





Shelley Paulson Photography

# Targeted Nutrition for *Challenging Conditions*

You know it as well as we do: some problems are more challenging to treat than others. Take gastric ulcers and certain myopathies. These often require targeted nutritional solutions.

**ReSolvin EQ™** is a revolutionary blend of long-chain polyunsaturated fatty acids proven to reduce the prevalence of squamous gastric ulcers in horses. **MFM Pellet™** features a proprietary blend of amino acids developed specifically for horses diagnosed with myofibrillar myopathy.

[Shop KERx solutions today at shop.ker.com.](http://shop.ker.com)



info@ker.com • 859-873-1988

Developed by Kentucky Equine Research®  
World Leaders in Equine Nutrition™



## ORIGINAL ARTICLE

# Ultrasonography can be used to predict the location of manica flexoria tears in horses

Maria Hibner-Szaltys  | Francesca Cavallier | Federica Cantatore  |  
Jonathan M. Withers | Marco Marcatili 

Pool House Equine Clinic, Lichfield, UK

**Correspondence:** Maria Hibner-Szaltys  
Email: maria.hibner@gmail.com

## SUMMARY

**Background:** Manica flexoria (MF) tears are a well-recognised cause of lameness in horses presenting with effusion of the digital flexor tendon sheath (DFTS). Ultrasonography (US) is a commonly used first-line imaging modality during examination of horses presented with DFTS effusion. However, its reported sensitivity for detection of MF tears is low.

**Objectives:** To describe a novel US technique to predict the location of the MF tear.

**Study design:** Prospective descriptive observational study.

**Methods:** Twenty-two horses (23 limbs) diagnosed with MF tears were included in the study. A standardised US protocol including examination with the limb weight bearing and non-weight bearing was used. Furthermore, with the limb held in flexed position, digital pressure was simultaneously applied to the medial and lateral proximal DFTS outpouchings in axial direction. The aim was to create turbulence of the synovial fluid within the DFTS and improve visualisation of the torn MF. The US examination was performed by one experienced operator and one junior clinician. All horses underwent tenoscopic examination.

**Results:** In all cases, MF tear was diagnosed during tenoscopic examination of the DFTS. The location of the MF tear was correctly predicted in 91.3% (21/23) of the limbs. The main features used to predict location of the MF tear included floatation of the torn fibres of the MF within the synovial fluid, increased distance between DDFT and SDFT on the side at which the MF was torn and recoiling of the MF on the side contralateral to the tear.

**Main limitations:** Relatively small number of cases included.  
**Conclusions:** The novel US technique was useful to identify the location of MF tear and facilitate identification of the previously described ultrasonographic features consistent with tears of the MF. The agreement between operators was perfect as from the data analysis.

## ORCID

Maria Hibner-Szaltys  <https://orcid.org/0000-0002-1507-5123>

Federica Cantatore  <https://orcid.org/0000-0003-1745-6146>

Marco Marcatili  <https://orcid.org/0000-0002-5449-6780>

## KEYWORDS

horse, equine, injury, tendon sheath, imaging



## Clinical relevance

- The study describes a novel ultrasonographic technique that can be useful to identify the location of manica flexoria tears and facilitates diagnosis of MF tears. Preoperative prediction of the location of MF lesions can be useful for surgical planning and patient positioning.
- The described technique is easily performed without the need for any additional equipment and could therefore be used by equine practitioners in an ambulatory setting.
- The described technique can be used in different breeds of horses, including ponies and cobs, and can be performed by an operator without extensive diagnostic imaging training.

# Measurement of ANP, BNP and endothelin-1 concentrations in jumping horses with heart valvular regurgitation and their correlation with the dimensions of heart structures

Sirous Sadeghian Chaleshtori<sup>1,2</sup>  | Mohammad Reza Mokhber Dezfouli<sup>1,2</sup> |  
 Mohammad Hassan Najizadeh<sup>1</sup> | Golam Reza Nikbakht Borujeni<sup>2,3</sup>

<sup>1</sup>Department of Internal Medicine, Faculty of Veterinary Medicine, University of Tehran, Tehran, Iran

<sup>2</sup>Institute of Biomedical Research, University of Tehran, Tehran, Iran

<sup>3</sup>Department of Microbiology and Immunology, Faculty of Veterinary Medicine, University of Tehran, Tehran, Iran

**Correspondence:** Sirous Sadeghian Chaleshtori and Mohammad Reza Mokhber Dezfouli

Emails: s.sadeghian@ut.ac.ir; mokhberd@ut.ac.ir

## SUMMARY

**Background:** Natriuretic peptides and endothelin-1 are used as biochemical biomarkers for the diagnosis and prognosis of heart diseases.

**Objectives:** This study aimed at investigating plasma ANP, BNP and endothelin-1 in jumping horses with various manifestations of heart valve regurgitation and their association with echocardiographic variables.

**Study design:** Clinical evaluations including cardiac auscultation were performed in 198 jumping horses, and 30 horses were chosen.

**Methods:** Sixteen jumping horses with murmurs of grade 3/6 to 5/6 having various degrees of heart valve regurgitation with the severity of insignificant to moderate on colour Doppler echocardiography were considered as the valvular regurgitation group (average age  $9.75 \pm 3.28$  years and weight  $427.43 \pm 82.22$  kg, and consisting of 10 mares, three stallions and three castrated male horses with breeds of 12 Thoroughbred and four crossbred). Fourteen healthy horses were chosen as the healthy group (average age  $8.64 \pm 2.44$  years and weight  $462.14 \pm 77.42$  kg, and consisting of nine mares, three stallions and two castrated males with breeds of 12 Thoroughbreds and two crossbred). Blood samples were collected from the jugular vein, and plasma concentration of ANP, BNP and endothelin-1 was determined using Sandwich ELISA by a horse-specific kit. Then, the plasma concentration of mentioned peptides and echocardiographic variables were compared between the two groups.

**Results:** BNP was significantly increased in horses with valve regurgitation compared to in healthy horses, but increases in ANP and endothelin-1 were insignificant. Also, in the valvular regurgitation group, horses with a pulmonic valve disorder had a significantly higher concentration of BNP and

endothelin-1 than healthy horses. Assessment of the relation between ANP, BNP and endothelin-1 with echocardiographic variables showed a significant correlation between ANP and right ventricle length (RVL) and left ventricle width (LVW) in systole and endothelin-1 with right ventricle width (RVW) and LVW in systole, but BNP had no significant correlation.

**Conclusion and clinical importance:** According to the study results, it can be assumed that the measurement of these cardiac biomarkers can be helpful in the diagnosis of the jumping horse with cardiac valvular disorders (especially pulmonic valve regurgitation) and changes in the dimensions of the heart ventricle.

## ORCID

Sirous Sadeghian Chaleshtori  <https://orcid.org/0000-0001-7441-7325>

## KEYWORDS

ANP, BNP, cardiac valve regurgitation, echocardiography, Endothelin-1, jumping horse



## Clinical relevance

- The measurement of natriuretic peptides and endothelin-1 is helpful in the diagnosis and prognosis of cardiac diseases and valvular disorders in the horse.
- Plasma concentration of BNP, ANP and endothelin-1 increase, in horses with valve regurgitation.
- The horses with pulmonic valve disorder had a significantly higher concentration of BNP and endothelin-1.
- There is a significant correlation between ANP with RVL and LVW in systole, BNP with right ventricle parietal diameter in diastole and, endothelin-1 with RVW, LVW and left ventricle area in systole.



# Genipin treatment of equine palatal dysfunction: A preliminary study of safety and efficacy

Hugh Mathew Dillon  | Etienne John Ogilvy O'Brien  | Cormac Feeney

Troytown GreyAbbey, Equine Veterinary Services, Kildare Town, Ireland

Correspondence: Hugh Mathew Dillon  
Email: hugh.dillon@troytown.ie

## SUMMARY

**Background:** Palatal dysfunction is a common cause of poor performance in racehorses. Although conservative management resolves just over 60% of cases, there is a requirement for further intervention in the residual 40% of cases that do not respond. It is proposed that a palatal stiffening technique that is simple to perform, safe and minimally invasive and enables a rapid return to exercise would be an acceptable first intervention. Genipin is a self-polymerising molecule that bonds to collagen matrices increasing tissue strength, stiffness and resilience. A previous study demonstrated that implanted genipin increased palatal strength and its resistance to deformation and potentially was effective in decreasing likelihood of palatal dysfunction in horses.

**Objectives:** The objective of the study was to appraise the safety and feasibility of implanting genipin oligomers into the equine soft palate and to report on racehorse trainers' subjective assessment of its usefulness in management of palatal dysfunction.

**Study design:** Prospective, non-randomised, pilot study.

**Methods:** Fifty Thoroughbred racehorses diagnosed with palatal dysfunction were implanted trans-endoscopically with genipin. The horses were monitored for adverse reactions during hospitalisation. A standard questionnaire provided to the horses' trainers was used to record additional adverse reactions and satisfaction with the animals' subsequent performance. Post-treatment dynamic endoscopy was performed in a subgroup of animals.

**Results:** One horse developed adverse clinical signs of pyrexia and reduced appetite, which responded to treatment. Post-procedural endoscopic examination revealed mild palatal abnormalities in 6 of 50 horses that showed no clinical signs. One horse had mild generalised oedema, four with mild focal swelling and one with a superficial mucosal ulceration at a single site of implantation of the soft palate. Following treatment,

76% of horses were reported to show clinical improvement by their trainers with 24% reported not to show improvement.

**Main limitations:** The study was not controlled, and outcome measures were mainly subjective.

**Conclusions:** The procedure was well tolerated, safe and minimally invasive and enabled a rapid return to exercise. Trainer-reported improvement was comparable to previously reported palatoplasty procedures.

## ORCID

Hugh Mathew Dillon  <https://orcid.org/0000-0001-6336-2306>E. J. O. O'Brien  <https://orcid.org/0000-0002-9444-0466>

## KEYWORDS

horse, respiratory, poor performance, intermittent dorsal displacement soft palate, genipin



## Clinical relevance

- Palatal dysfunction is a significant cause of poor performance in racehorses with a complex aetiology. There is a requirement for an initial minimally invasive procedure to manage affected horses that have not responded to conservative management.
- Genipin is a self-polymerising molecule that is an effective protein cross-linker and when implanted into the equine soft palate bonds to the native collagen to increase the tissue's tensile stress. This increases the tissue resistance to deformation from external forces (stiffness). It is a minimally toxic biomaterial that is well-tolerated post-implantation.
- The study demonstrates that implantation with genipin is safe and may reduce the clinical signs of palatal dysfunction in racehorses at maximal exercise. The procedure can be utilised alone or in combination with others. Genipin implantation offers advantages over other interventions in that it is a simple and quick procedure performed standing under sedation with minimal disruption of training.

## ORIGINAL ARTICLE

# Blinded comparison of mirror and endoscopic oral examination in the horse: Sensitivity, specificity and observer agreement

Naomi E. Chiero<sup>1</sup> | Jeffrey D. Reiswig<sup>2</sup> | Cleet E. Griffin<sup>3</sup> | Kathryn J. Panigrahi<sup>1</sup> | Alison K. Gardner<sup>1</sup>

<sup>1</sup>Department of Veterinary Clinical Sciences, College of Veterinary Medicine, The Ohio State University, Columbus, Ohio, USA

<sup>2</sup>Department of Veterinary Biosciences, College of Veterinary Medicine, The Ohio State University, Columbus, Ohio, USA

<sup>3</sup>Department of Large Animal Clinical Sciences, Texas A&M University, College Station, Texas, USA

Correspondence: Naomi Chiero  
Email: chiero.4@osu.edu

## SUMMARY

**Background:** Dental disease is commonly encountered in veterinary practice. Due to the horse's deep oral cavity, direct visual examination alone is not adequate for a complete oral evaluation. Typically, a long-handled dental mirror is used as a visual aid. Oral endoscopy is another option to improve visual examination of the mouth. Although recent literature suggests endoscopy is superior to mirror examination, these modalities have not been compared in a blinded study.

**Objective:** The aim of this study was to compare sensitivity and specificity of identifying dental pathologies between oral mirror and rigid endoscopic examination as well as inter- and intra-observer variability of each modality

**Study design:** A prospective randomised trial.

**Methods:** Twenty-one horses underwent oral examination using a mirror and an endoscope with video recording of both techniques. An additional six horses received both pre-mortem and post-mortem examination. Two blinded observers evaluated the video recordings and identified the presence of dental pathology to determine inter-observer and intra-observer agreement. Live examinations were compared with the six post-mortem examinations to determine sensitivity and specificity.

**Results:** Endoscopy sensitivity was far superior to mirror for all pathologies (83% vs. 39%), while specificity was high for both (71% vs. 87%, respectively) when compared to the gold-standard post-mortem examination. Inter-observer agreement of presence of pathology using endoscopy was substantial and higher than mirror examination. Intra-observer agreement was moderate to substantial.

**Main limitations:** The study was limited by the small number of horses and post-mortem examinations, although sample size was increased by assessing the pathology of each tooth.

**Conclusions:** Moderate-to-substantial agreement was found using both endoscopy and mirror examination. Sensitivity was improved with endoscopy. Oral endoscopy may be beneficial for use in monitoring dental disease over time, as many minor pathologies do not require immediate intervention. Endoscopic and mirror videos may also prove valuable in veterinary education.

## KEYWORDS

horse, dentistry, endoscopy, mirror, oral examination



## Clinical relevance

- Equine oral examination requires the use of a visual aid; mirror or rigid endoscope are commonly used. Recordings of a mirror or endoscopic examination are not only utilised to document pathology, but also aid communication with clients, students and other veterinarians.
- Endoscopic examination sensitivity far exceeds the mirror, while both have a high specificity. A mirror is an excellent screening tool and affordable for field-setting use.
- Oral endoscopes are becoming widely available and affordable; they can be used in a field setting but require more equipment set-up. Endoscopy is recommended at the speciality level.

# WHAT'S THE #1 RECOMMENDATION FOR MAINTAINING EQUINE RESPIRATORY HEALTH?

## REDUCING RESPIRABLE DUST IN OUR HORSES' ENVIRONMENT.

### HAYGAIN® HIGH-TEMPERATURE HAY STEAMERS CAN HELP!



Haygain Steaming **REDUCES AIRBORNE RESPIRABLE PARTICLES & MICROBIAL CONTAMINATION BY 99%**, while preserving important nutrients.<sup>1</sup>

Horses fed Haygain Steamed Hay were **65% LESS LIKELY TO RECEIVE AN IAD DIAGNOSIS.**<sup>2</sup>



#### TEMPERATURES AROUND 212°

attained and maintained in a thermally-insulated chest



#### PATENTED STEAMING PROCESS

ensures all hay in chest is thoroughly steamed

### BONUS BENEFITS!



Up to 3X the moisture content of dry hay.



Proven palatability over dry or soaked hay.



PROVEN RESEARCH. PROVEN RESULTS. [haygain.us](http://haygain.us) | 1.888.307.0855

<sup>1</sup>: The Effect of Steaming & Soaking on the Respirable Particle, Bacterial, Mould and Nutrient Content in Hay for Horses, by Moore-Colyer, M.J.S Taylor, J. and James, R. (2016)\_ Journal of Equine Veterinary Science. | <sup>2</sup>: Fungi in the Respiratory Samples of Horses with Inflammatory Airway Disease By Dauvillier, J, ter Woort, F, van Erck-Westergren, E. (2019) Journal Veterinary Internal Medicine





# OUR BEST, FOR YOUR HORSE

**THE OFFICIAL EQUINE HOSPITAL AND  
VETERINARY PHARMACY OF THE BREEDERS' CUP**



## PROVIDING SERVICES IN:

- Surgery/ Diagnostic Imaging
  - Nuclear Scintigraphy
  - CT
  - MRI
  - PET Scan
- Dentistry/Oral Surgery
- Internal Medicine
- Ambulatory
- Chiropractics
- Acupuncture
- Advanced Reproduction
- Podiatry
- Sport Horse Medicine
- Compounding Pharmacy
- Laboratory



# Postoperative exercising endoscopy of the equine upper respiratory tract

Safia Z. Barakzai Equine Surgical Referrals Ltd, Brighton,  
UK**Correspondence**

Safia Z. Barakzai

Email: safia@equinesurgicalreferrals.com

**Summary**

Investigation of horses that continue to make noise or perform poorly after upper respiratory surgery is greatly enhanced by postoperative exercising endoscopy in most cases. This review paper discusses dynamic abnormalities of the equine upper respiratory tract that occur after the most commonly performed upper respiratory tract surgeries.

**KEYWORDS**

horse, larynx, palate, endoscopy, surgery, upper respiratory

## INTRODUCTION

The investigation and treatment of ongoing abnormal respiratory noise or poor performance after upper respiratory tract surgery varies according to the surgery that was previously performed. Occasionally, resting endoscopy will reveal a clear abnormality, but for most cases with ongoing postoperative issues, exercising endoscopy is the gold standard for evaluating whether the surgical technique(s) have been successful and whether any sequelae have developed. Exercising endoscopy is a much more accurate reflection of surgical 'success' than using proxy methods such as evaluation of racing performance, owners' and trainers' perception of improved performance or change in respiratory noise. As with any exercising endoscopic examination, the horse should be performing at the level which is maximal for its particular sporting discipline. In the postoperative patient, adequate time must have been allowed for recovery from surgery and restoration of a normal exercise regime.

## SURGERY FOR PALATAL DYSFUNCTION

The term palatal dysfunction incorporates both dorsal displacement of the soft palate (DDSP) and palatal instability (PI). Medical management should be instituted first, but if that fails, there are many surgeries available to treat this group of disorders. Composite surgeries are often performed in an attempt to get the best results. A minority of cases of DDSP have an identifiable predisposing factor, e.g. epiglottic masses, epiglottic abscesses or epiglottic entrapment,

lesions on the caudal soft palate, tracheal aspiration etc., and in such cases, these issues should be treated primarily.

There are few studies that have documented exercising endoscopic examination of horses after treatment for palatal dysfunction probably because such studies are time-consuming to perform and many horses can be lost to follow-up. Those that have been performed include horses that have had laryngeal tie-forward surgery and a handful of horses, which have undergone soft palate thermal cautery (Barnett et al., 2016; Dart, 2006; McCluskie et al., 2009). DDSP treatments aim to stop DDSP from occurring and possibly to also prevent or reduce the severity of PI. It remains unclear to what extent palatal function should be restored to constitute 'success' (Allen et al., 2012). DDSP is an intermittent event; hence, where PI continues to occur postoperatively, we do not know whether this truly reflects the resolution of DDSP or whether DDSP might occur during subsequent runs or under different exercise conditions. It is important that the same exercise test is undertaken pre- and post-intervention, and for results to be clinically relevant, the exercise test should be representative of that horse's intended use.

When considering results for any surgical intervention for DDSP, it should be borne in mind that spontaneous resolution occurs in some cases. In one study where repeated exercising endoscopy was performed on 78 Thoroughbred racehorses, 14 of these were definitively diagnosed with DDSP during at least one examination. These 14 horses had no treatment or other intervention, and 6/14 showed resolution of DDSP on at least one subsequent exercising endoscopic examination (McGivney et al., 2019).

Horses are usually referred for surgery once conservative treatments have been tried and have been unsuccessful. Thus, results

from surgical cases may represent a subset of horses with DDSP, which are more refractory to treatment.

Barnett et al. (2016) performed overground exercising endoscopy before and after laryngeal tie-forward in 60 horses. The surgery successfully reduced the prevalence of DDSP in the study population by 70%, but 73% of horses still exhibited a degree of palatal instability postoperatively. Within this study, 18 horses underwent additional thermal cautery of the soft palate at the time of surgery, but the inclusion of thermal cautery made no significant difference to the exercising endoscopy results. Causes of failure of laryngeal tie-forward include not having a definitive diagnosis of palatal dysfunction preoperatively, migration of the larynx caudally after surgery and suture pull-through/failure. Radiography and/or ultrasonography of cases that still experience DDSP after tie-forward can be useful to assess the position of the larynx.

For palatal thermal cautery performed alone, McCluskie et al. (2009) reported that 3/6 horses that had DDSP preoperatively had resolution of DDSP postoperatively, but all still had palatal instability. Of six horses that had PI preoperatively, 5/6 still had PI after cautery, and one had developed DDSP after palatal cautery. Results for five horses that had a combination of palatal cautery and laryngeal tie-forward showed no improvement in results for the individual surgeries (McCluskie et al., 2009). Interestingly, subjective trainer assessment of the effect of surgery had no correlation with improvement in exercising endoscopic appearance of the upper airway (McCluskie et al., 2009).

## ARYEPIGLOTTIC FOLD RESECTION

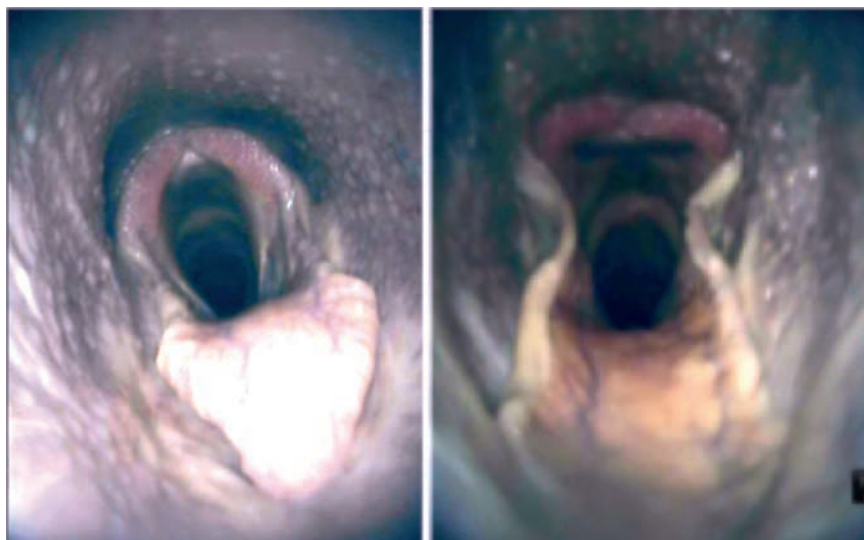
Recurrence of medial deviation of the aryepiglottic folds after surgical aryepiglottic fold resection is unfortunately relatively common and is presumably due to inadequate resection of the

membranous portion of the fold. There is a medial and a lateral component to the aryepiglottic fold: removing the lateral component is more difficult and therefore residual tissue here is the likely cause of the recurrence in most cases. Even so, in some horses where the resting examination appears to show adequate resection of the aryepiglottic folds, a medial deviation of the aryepiglottic folds (MDAF) can still occur during exercise (Figure 1). On close inspection, in some cases, it appears that the lateral edge of the epiglottis is rolling in medially, pulling in with it whatever remaining part of the fold is present.

Both Leutton and Lumsden (2015) and Barnett et al. (2016) reported results of exercising endoscopy after aryepiglottic fold resection (either with concurrent laryngoplasty or tie-forward surgery). They reported that three out of six (50%) horses undergoing concurrent laryngoplasty and 19 of 43 (44%) undergoing concurrent laryngeal tie-forward surgery had continued collapse of remaining tissue in the resected fold(s). Because some tissue has been removed from the fold, it is likely that the degree of MDAF is somewhat improved in these cases but not completely resolved.

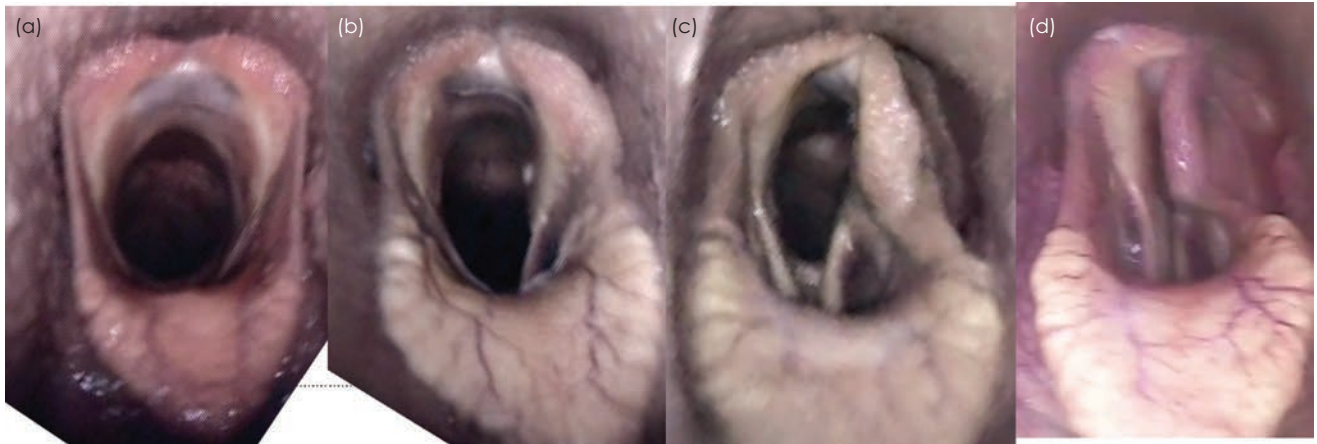
## SURGERY FOR RECURRENT LARYNGEAL NEUROPATHY (RLN)

The most frequently performed surgeries for treatment of RLN in equine practice are laryngoplasty and ventriculocordectomy (Cramp & Barakzai, 2011; Fulton et al., 2012). Re-innervation of the cricoarytenoid dorsalis muscle via direct nerve transplantation has been recently described (Rossignol et al., 2018). After any surgery for RLN, both the degree of abduction and the stability of both the left arytenoid and vocal fold (or area where the fold used to be) should be assessed during exercising endoscopy, when the horse is exercising maximally.



**FIGURE 1** Resting (left) and exercising (right) appearance of a horse that appears to have had extensive bilateral resection of the aryepiglottic folds, yet still experiences MDAF during exercise.





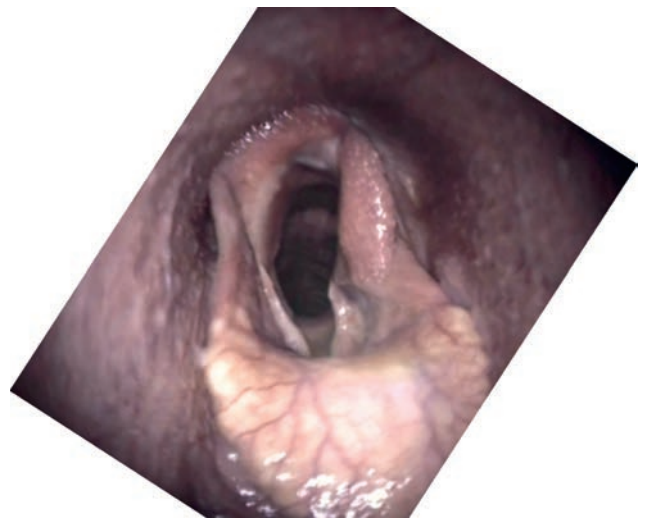**FIGURE 2** Laryngeal grades at exercise (Robinson et al., 2004; Rossignol et al., 2018). (a) full abduction of the arytenoid cartilages during inspiration; (b) partial abduction of the affected arytenoid cartilages (between full and the resting position); (c) abduction held at the resting position; (d) collapse into the contralateral half of the rima glottidis during inspiration.

For horses that have not undergone laryngoplasty, laryngeal function at exercise is graded as A to D (Robinson et al., 2004; Rossignol et al., 2018; Figure 2).

### Ventriculocordectomy

After ventriculocordectomy (VeC), the surgical site should be smooth with little remaining vocal fold tissue and no granulomas present. Some surgeons prefer to do a much less aggressive version of VeC, only removing the vocal ligament and ventricle when they are performing a concurrent laryngoplasty because of fears of a larger ventral glottic 'gap' predisposing to postoperative dysphagia. However, incomplete removal of vocal cord tissue means that the remaining tissue can still collapse during exercise (Figure 3), particularly if ipsilateral arytenoid abduction is moderate or minimal. Results of exercising endoscopic examination of horses after VeC performed unilaterally with a diode laser have been reported by Barakzai et al. (2019). These authors reported that for horses with grade B preoperative laryngeal function and vocal fold collapse, unilateral VeC was effective in abolishing airway obstruction caused by the vocal fold collapse and reducing abnormal respiratory noise. Laser VeC also appears to stabilise previously markedly unstable (Gr C or D) arytenoid cartilages to a degree in many cases (Barakzai et al., 2019), presumably due to fibrosis between the body of the arytenoid and the thyroid cartilage. However, in many horses with grade C or D preoperative laryngeal function, concurrent pre-existing dynamic abnormalities including right vocal fold collapse, medial deviation of the right aryepiglottic fold and arytenoid instability continued to be present and contributed to ongoing postoperative respiratory noise (Barakzai et al., 2019).

Bilateral VeC has been reported to be very effective in reducing abnormal upper respiratory sounds whilst still improving upper airway mechanics (Brown et al., 2003). Unless a length of intact mucosa is left at the ventromedial aspect of left and right vocal folds, there is a chance of postoperative webbing developing after bilateral VeC,



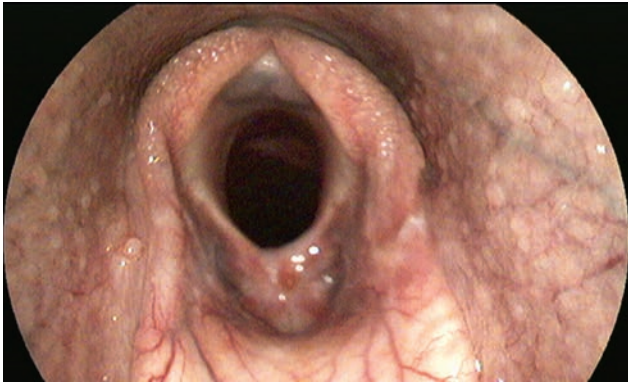
**FIGURE 3** Incomplete bilateral VeCs (performed surgically via laryngotomy)—horse at exercise showing ongoing collapse of both vocal fold remnants during inspiration.

which can be identified on resting endoscopy (Figure 4). For this reason, some surgeons now elect to perform a right-sided cordotomy (horizontal incision in the cord) rather than a cordectomy, which should give less risk of web formation when performed concurrently with a left VeC.

### Laryngoplasty

Laryngoplasty surgery involves placing sutures that mimic the action of the denervated crico-arytenoid dorsalis muscle, thus abducting and stabilising the left arytenoid cartilage. It is often performed with concurrent ipsilateral or bilateral VeC or cordotomy. It would seem intuitive that horses that run at high speed (e.g. racehorses) might need a more widely abducted larynx than those which perform less strenuous activities such as dressage or general riding, but it is not proven what

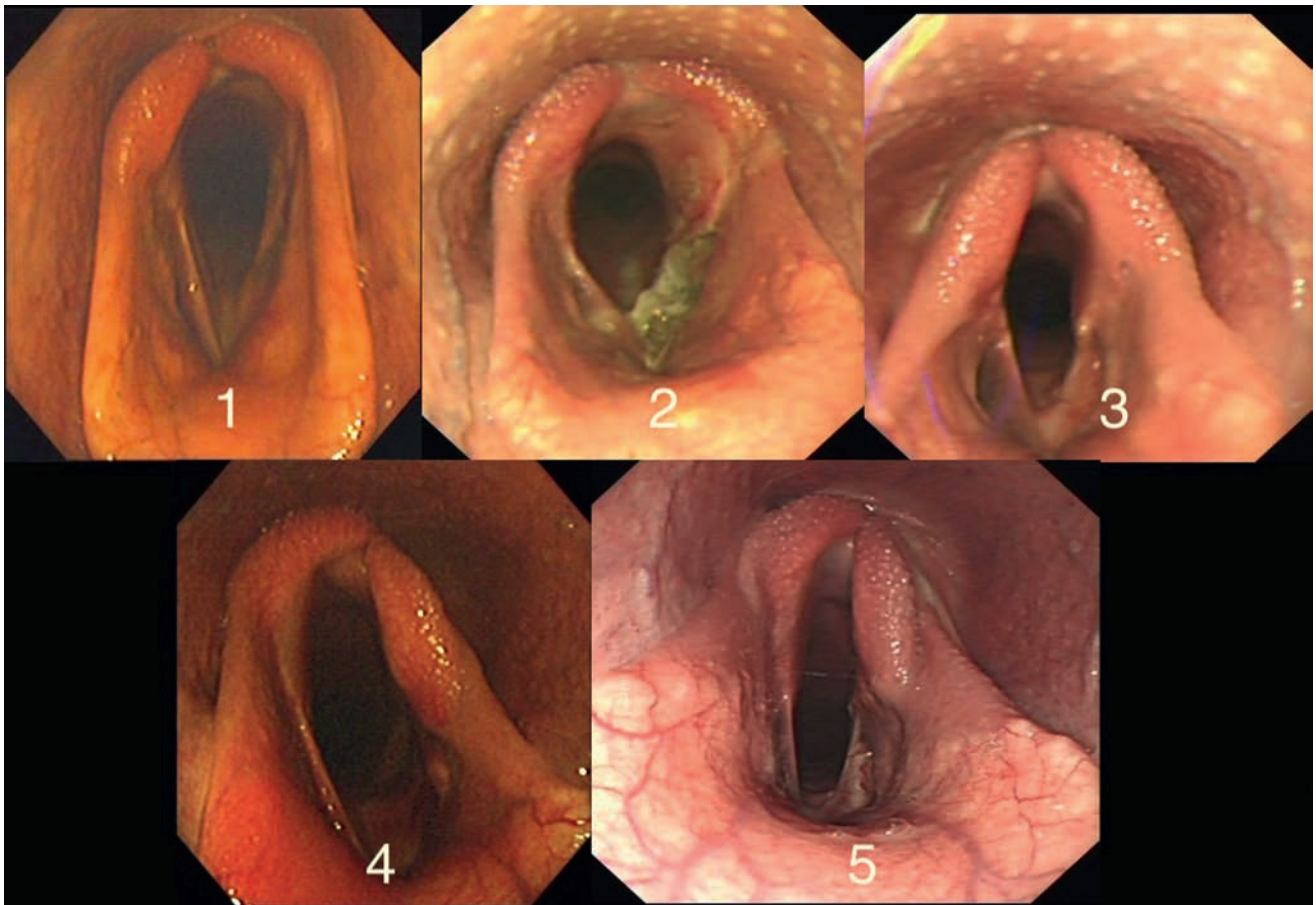
degree of abduction is optimal for horses working in different equestrian disciplines. After laryngoplasty, the degree of surgically achieved arytenoid abduction can be graded endoscopically at rest (Dixon et al., 2003, Figure 5) where grade 1 describes a hyper-abducted arytenoid and grade 5 indicates there is no abduction present, with the arytenoid positioned in the midline. Stability of the abducted cartilage is thought to be as important as the degree of abduction attained



**FIGURE 4** Ventral laryngeal web formation after bilateral VeC.

(Cramp & Barakzai, 2011), and one study demonstrated that most National Hunt (steeplechase) horses with Dixon grade 3 laryngeal abduction can race successfully (Barakzai et al., 2009). It is this author's opinion that for horses doing less strenuous activities such as general riding, showjumping or dressage, a *stable* left arytenoid with grade 3/4 abduction is usually enough to reduce postoperative noise significantly and give the horse an adequate airway to perform successfully. The Dixon grading system (2003) does not strictly apply to exercising horses, so after laryngoplasty surgery, postoperative arytenoid stability should additionally be graded as stable or mild/moderate/severe instability (Barakzai et al., 2019; Barnett et al., 2013a).

After laryngoplasty, at rest, the larynx and pharynx should be examined for the degree of resting abduction (Figure 5), the appearance of the VeC or cordotomy site(s), the presence of food material or saliva, and the shape and size of the corniculate process of the left arytenoid. Multiple research papers have described the results of exercising endoscopy performed after laryngoplasty surgery (Barnett et al., 2013a, 2013b; Compostella et al., 2012; Davidson et al., 2009; Leutton & Lumsden, 2015). All studies found an alarmingly high prevalence of dynamic upper respiratory abnormalities (Table 1), even in horses that were reported to be a 'success' by the



**FIGURE 5** Post-laryngoplasty grades of arytenoid abduction 1–5 as described by Dixon et al. (2003). Grade 1: excessive abduction; Grade 2: (50–80°) of arytenoid abduction; Grade 3: a moderate (circa 45°) degree of arytenoid abduction; Grade 4: a slight degree of arytenoid abduction—slightly more abducted than the normal resting position; and Grade 5: no detectable arytenoid abduction (hanging in the midline).

**TABLE 1** Summed results from four published studies evaluating exercising endoscopy post-laryngoplasty surgery (Barnett et al., 2013; Compostella et al., 2012; Davidson et al., 2009; Leutton & Lumsden, 2015)

Exercising endoscopy findings: (Total horses all studies n = 151)	Mean % (range)
No abnormality	14% (0%–24%)
Unstable arytenoid	35% (20%–43%)
Right vocal fold collapse	32% (20%–46%)
Left vocal fold or remnant collapse	24% (9%–37%)
Medial deviation of the aryepiglottic fold(s)	44% (24%–49%)
Dorsal displacement of the soft palate	21% (3%–46%)
Palatal dysfunction (displacement of palate and/or palatal instability)	55% (53%–56%)
Ventromedial luxation of the apex of the corniculate process	10% (0%–17%)
Nasopharyngeal collapse	7% (2%–17%)
Oesophageal reflux	16% (10%–23%)
Gross food contamination	20% (17%–22%)

Note: Due to the variability in reporting or in categorisation of abnormalities by different authors, not all 151 horses are included in each category.

owners. True laryngoplasty failure, i.e. inability to hold the arytenoid in a fixed abducted position, was more prevalent in the studies evaluating surgical ‘failures’ than in cross-sectional studies. However, all authors reported a wide range of upper respiratory abnormalities in horses with all grades of surgical abduction, many of which are not intuitively attributable to the laryngoplasty procedure. The prevalence of abnormal exercising endoscopic findings amalgamated from these 4 published papers is shown in Table 1.

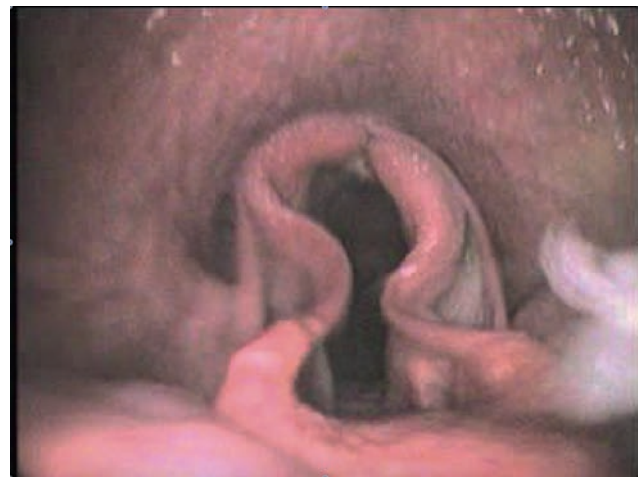#### *Arytenoid stability*

Instability of the arytenoid cartilage after laryngoplasty can be judged as mild, moderate or severe (Barakzai et al., 2019; Barnett et al., 2013a). Severe arytenoid instability constitutes a true surgical failure of laryngoplasty, as the collapsing arytenoid causes complete obstruction of the airway during exercise.

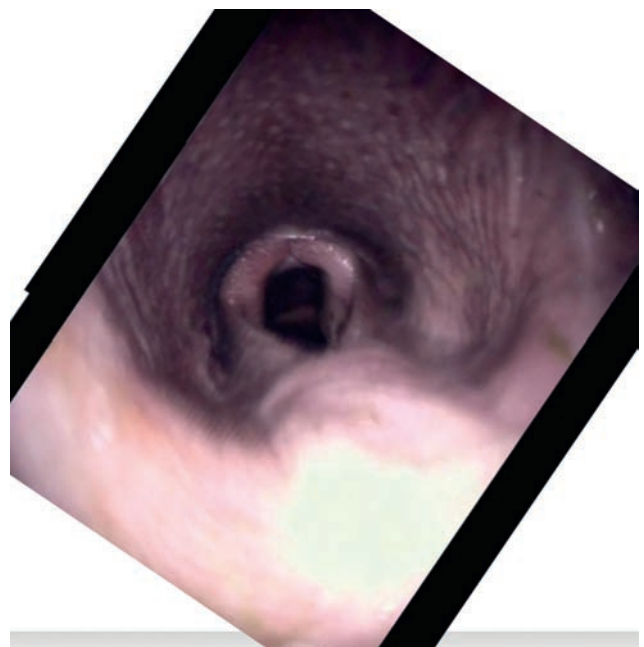
There is conflicting evidence as to whether horses with poor postoperative abduction are more likely to have arytenoid instability than those with wider postoperative abduction. Davidson et al. (2009) examined a population of horses that were returned to their hospital for ongoing abnormal noise: this population had relatively low grades of arytenoid abduction (median grade 4, range 3–5). They reported that post-laryngoplasty, a larynx with Dixon grade 4 abduction was 20 times more likely to be stable at exercise than a larynx with grade 5 (no) abduction. There was no difference in arytenoid stability when comparing horses with grades 3 and 4 abduction. In contrast, Barnett et al. (2013b) examined a cross-section of horses post-laryngoplasty with median grade 3 (range 2–5) abduction. They found no correlation between the resting abduction grade and the stability of the arytenoid at exercise.

#### *Other forms of dynamic collapse post-laryngoplasty*

Preoperatively, almost all horses with grade C or D preoperative laryngeal function have bilateral vocal fold collapse (Barakzai et al., 2019; Leutton & Lumsden, 2015), although the collapse of the left fold is usually more severe than the right. Therefore, concurrent right vocal cordectomy (full or partial), cordotomy or possibly simply right ventriculectomy (Barnett et al., 2013b) are indicated at the time of laryngoplasty. Right and left vocal fold collapse or collapse of the remnants of incompletely removed vocal folds (Figure 3) is common after laryngoplasty (overall prevalence of 32%). Medial deviation of the aryepiglottic folds (either right-sided or bilateral, Figure 6) was also very common (overall prevalence of 44%) and this finding lends

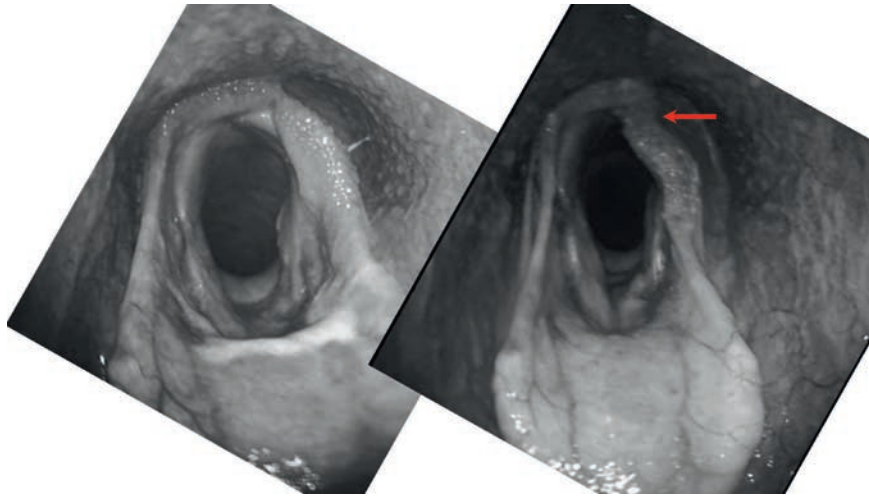


**FIGURE 6** Horse after laryngoplasty with severe bilateral MDAF.



**FIGURE 7** DDSP post-laryngoplasty and left VeC. Note small green particles of food material on the walls of the nasopharynx.





**FIGURE 8** Post-laryngoplasty at rest, with grade 3 abduction (left) and during a fast gallop (right). Ventromedial luxation of the left corniculate process is present at fast work (red arrow). Note the lateral part of the corniculate remains abducted. Mild right MDAF is also present.

some weight to performing routine aryepiglottic fold resection at the time of laryngoplasty.

There are quite wide ranges in the prevalence of palatal dysfunction after laryngoplasty between different published studies (3%–70%, Barnett et al., 2013b; Compostella et al., 2012; Davidson et al., 2009; Leutton & Lumsden, 2015). Palatal dysfunction was categorised in different ways in some of these studies, which may account for some of the variation. Further work that aimed to characterise palatal dysfunction in horses after laryngoplasty described that it often occurred at much lower speeds than traditional idiopathic DDSP and in many cases disappeared or became more intermittent when horses started to canter and gallop (Barnett et al., 2014). Potential causes of post-laryngoplasty palatal dysfunction (Figure 7) are proposed including palatal dysfunction undiagnosed prior to laryngoplasty; postoperative perilaryngeal fibrosis that may reduce the rostral excursion of the larynx; persistent low to moderate grade airway contamination that may induce DDSP in some horses; iatrogenic damage to the cranial laryngeal nerve during surgery that may induce DDSP (Barnett et al., 2014). None of these theories have been proven to date.

Rare abnormalities such as ventromedial luxation of the apex of the corniculate process of the arytenoid (VLAC, Figure 8) and arytenoid chondritis are reported with much higher frequency in horses in the long-term after laryngoplasty as compared to the general population. VLAC was first described in 15 horses by Dart et al. (2005) and 3 of these had had a previous laryngoplasty. It is hypothesised that under the high negative pressures generated during inspiration at exercise, repeated cycling of the collapsing corniculate process in horses with severe RLN may alter the integrity of this cartilage and make it more prone to deformation (N.G. Ducharme, personal communication).

Oesophageal reflux of saliva and food material (Figure 9) has also been described post-laryngoplasty and is seen more frequently during exercise than at rest (Barakzai et al., 2015; Barnett et al., 2013b; Leutton et al., 2015). In recent years, anatomical description of the cranial oesophageal diverticulum and the high risk of

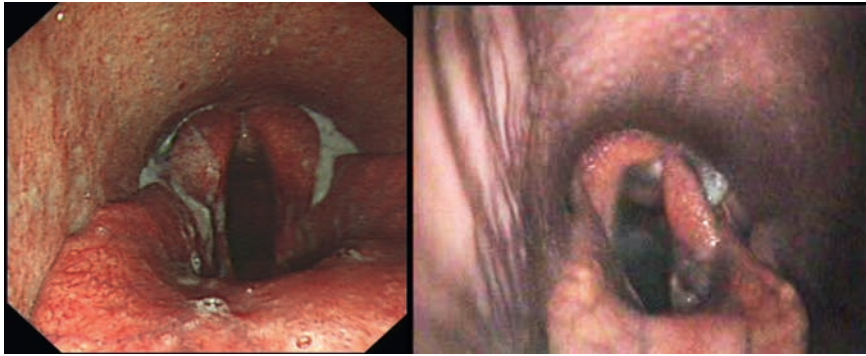
iatrogenic damage to or distortion of this structure during laryngoplasty (Brandenberger et al., 2018) may give an explanation for oesophageal reflux seen after laryngoplasty. A distorted or stretched diverticulum may provide an area where saliva can pool, and then periodically exit, dripping down onto the left corniculate process. Other suggested explanations for oesophageal regurgitation included damage to the caudal pharyngeal constrictor muscles (i.e. cricopharyngeus muscle), the adventitia or intrinsic musculature of the upper oesophagus, or the innervation to these muscles (glossopharyngeal nerve), or damage to the perioesophageal fascia or oesophageal adventitia during surgery may cause upper oesophageal incompetence in horses after laryngoplasty (Barakzai et al., 2015).

To conclude, horses that make excessive noise after laryngoplasty can be doing so for a wide variety of reasons. A minimally invasive surgery such as standing laser VeC or aryepiglottic fold resection may remedy the obstruction in many cases, and in most instances, repeat laryngoplasty, arytenoidectomy or retirement can be avoided. Exercising endoscopy is crucial for postoperative assessment and making the best treatment plan for each individual case.

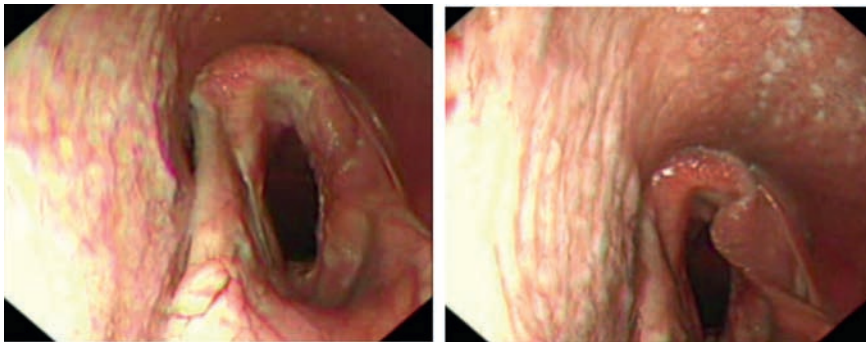
### Re-innervation of the cricoarytenoideus dorsalis muscle

Nerve muscle pedicle grafts (Fulton et al., 2012) are now being replaced with direct re-innervation of the cricoarytenoideus dorsalis muscle using C1-C2 and/or the spinal accessory nerve (Rossignol et al., 2018, 2021). The aim of developing this surgery was to avoid some of the complications seen in horses after laryngoplasty and to provide a more physiological solution for horses affected with RLN. Ipsilateral laser VeC is performed concurrently, often also with right VeC or cordotomy.

Successful re-innervation using the C1/C2 nerves can be tested to a degree in the resting horse by stimulating reflexes that



**FIGURE 9** Oesophageal reflux of saliva after laryngoplasty can be seen at rest (left) and sometimes only during exercise (right).



**FIGURE 10** Horse after standard partial arytenoidectomy during expiration (left) and inspiration (right). There is collapse of mucosal fold from the area of the corniculectomy and the left aryepiglottic fold during exercising endoscopy.

depolarise the first cervical nerve (Fulton et al., 2012) or by using ultrasound-guided stimulation of the first cervical nerve at the alar foramen (Mespoulhès-Rivière et al., 2016). Ultimately, postoperative exercising endoscopic evaluation is also required to be certain that the surgery has been successful and to judge the quality of the re-innervation, i.e. the degree of arytenoid abduction that is attained at exercise. Early results from the C1/C2 implant surgeries have shown that they are successful in around 85% of clinical cases, in preventing complete laryngeal collapse and alleviating clinical signs (Rossignol, 2021). However, in many cases (7/9 horses re-examined at 12 months) the arytenoid abduction often remains at around grade C (Rossignol et al., 2018). The addition of the spinal accessory nerve graft is hoped to improve this exercising abduction grade. Difficulties remain when re-innervating horses with severe disease and very little remaining cricoarytenoideus dorsalis muscle. More recently, a modified laryngoplasty has been combined with the re-innervation technique (Rossignol et al., 2021), with the aim of improving the degree of abduction in sports horses and racehorses, but the results of this 'dynamic neuroprosthesis' operation are not yet available.

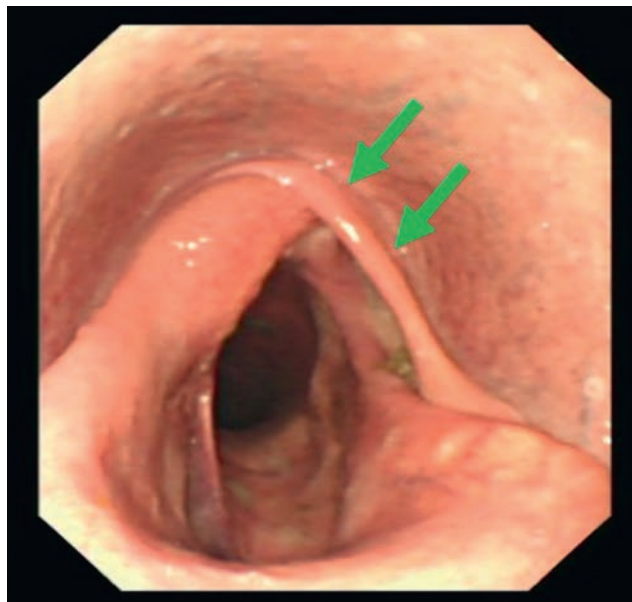
### Arytenoidectomy

Arytenoidectomy surgery is usually performed to remove infected arytenoid cartilage in cases of arytenoid chondritis. Horses that have had resolution of active infection after arytenoid chondritis

can be left with a very thickened cartilage, which causes mechanical obstruction, and arytenoidectomy is also indicated in such cases. Occasionally it might also be used for horses that have a failed laryngoplasty, where repetition of the laryngoplasty is not possible. Some surgeons in the USA also use it as their primary treatment for horses with RLN.

Techniques for performing arytenoidectomy vary, but partial arytenoidectomy is probably the most commonly utilised. Partial arytenoidectomy involves the removal of all the arytenoid cartilage except for the muscular process. Exercising endoscopy of horses after standard partial arytenoidectomy showed that there was often collapse of the ipsilateral aryepiglottic fold tissue, and it was proposed that this was a common cause of ongoing airway obstruction after partial arytenoidectomy (Figure 10, Radcliffe et al., 2006). Thus, a modified partial arytenoidectomy (MPA) was developed, which includes caudal traction and fixation of the left aryepiglottic fold, with any remaining loose ipsilateral tissue removed postoperatively (Radcliffe et al., 2006).

During endoscopy at rest after MPA surgery, obvious complications such as the development of granulomas or excessive postoperative swelling can be noted. At exercise, the ipsilateral or medial collapse of the aryepiglottic fold is probably the most common obstruction observed (Figure 10). Static or dynamic rostral displacement of the palatopharyngeal arch may also be present after MPA (Figure 11). The collapse of other structures including the ipsilateral palatopharyngeal arch, right vocal fold or vocal fold remnants, or



**FIGURE 11** Left-sided RDPA (arrows) seen at rest after modified partial arytenoidectomy.

remnants of mucosa that was previously covering the arytenoid cartilage (Figure 10) can also occur.

## EPIGLOTTIC ENTRAPMENT SURGERY

Surgery to correct epiglottic entrapment consists of division and/or removal of the entrapping tissues. Re-entrapment is reported to occur in 4%–15% of cases (Ducharme & Rossignol, 2019). Exercising endoscopy is not necessary to diagnose re-entrapment in all but very rare cases because this is usually apparent during resting endoscopy, particularly after stimulation of repeated swallow sequences. Similarly, persistent DDSP can be a long-term sequel of epiglottic entrapment surgery in up to 10% of cases, but this is apparent during resting endoscopy.

## CONFLICT OF INTEREST

No conflicts of interest have been declared.

## AUTHOR CONTRIBUTIONS

Safia Z. Barakzai has been the sole author and contributor for this article.

## ORCID

Safia Z. Barakzai  <https://orcid.org/0000-0002-1568-8413>

## REFERENCES

- Allen, K.J., Christley, R.M., Birchall, M.A. & Franklin, S.H. (2012) A systematic review of the efficacy of interventions for dynamic intermittent dorsal displacement of the soft palate. *Equine Veterinary Journal*, 44, 259–266.
- Barakzai, S.Z., Boden, L.A. & Dixon, P.M. (2009) Postoperative race performance is not correlated with degree of surgical abduction after laryngoplasty in National Hunt Thoroughbred racehorses. *Veterinary Surgery*, 38, 934–940.
- Barakzai, S.Z., Dixon, P.M., Hawkes, C.S., Cox, A. & Barnett, T.P. (2015) Upper esophageal incompetence in five horses after prosthetic laryngoplasty. *Veterinary Surgery*, 44, 150–155.
- Barakzai, S.Z., Wells, J., Baldwin, C. & Cramp, P. (2019) Overground endoscopic findings and respiratory sound analysis in horses with recurrent laryngeal neuropathy after unilateral laser ventriculocordectomy. *Equine Veterinary Journal*, 51, 185–191.
- Barnett, T., Barakzai, S., Smith, L. & Payne, R. (2016) *Overground endoscopy findings following laryngeal tie-forward for management of DDSP*. Proceedings of the ECVS Annual Conference, Lisbon.
- Barnett, T.P., Dixon, P.M., Parkin, T.D.H. & Barakzai, S.Z. (2013b) Long-term exercising video-endoscopic examination of the upper airway following laryngoplasty surgery: A prospective cross-sectional study of 41 horses. *Equine Veterinary Journal*, 45, 593–597.
- Barnett, T.P., O'Leary, J.M., Parkin, T.D.H., Dixon, P.M. & Barakzai, S.Z. (2013a) Long term maintenance of arytenoid abduction and correlation between arytenoid abduction grade and stability during exercise following prosthetic laryngoplasty. *Veterinary Surgery*, 42, 291–295.
- Barnett, T.P., O'Leary, J.M., Dixon, P.M. & Barakzai, S.Z. (2014) Characterisation of palatal dysfunction after laryngoplasty. *Equine Veterinary Journal*, 46, 60–63.
- Brandenberger, O., Martens, A., Robert, C., Wiemer, P., Pamela, H., Vlaminck, L. et al. (2018) Anatomy of the vestibulum esophagi and surgical implications during prosthetic laryngoplasty in horses. *Veterinary Surgery*, 47, 942–950.
- Brown, J.A., Derksen, F.J., Stick, J.A., Hartmann, W.M. & Robinson, N.E. (2003) Ventriculocordectomy reduces respiratory noise in horses with laryngeal hemiplegia. *Equine Veterinary Journal*, 35, 570–574.
- Compostella, F., Tremaine, W.H. & Franklin, S.H. (2012) Retrospective study investigating causes of abnormal respiratory noise in horses following prosthetic laryngoplasty. *Equine Veterinary Journal*, 44(Suppl. 43), 27–30.
- Cramp, P. & Barakzai, S.Z. (2011) Surgical management of recurrent laryngeal neuropathy. *Equine Veterinary Education*, 24, 307–321.
- Dart, A.J. (2006) Vocal fold collapse after laryngeal tie-forward correction of dorsal displacement of the soft palate in a horse. *Veterinary Surgery*, 35, 584–585.
- Dart, A.J., Dowling, B.A. & Smith, C.L. (2005) Upper airway dysfunction associated with collapse of the apex of the corniculate process of the left arytenoid cartilage during exercise in 15 horses. *Veterinary Surgery*, 34, 543–547.
- Davidson, E.J., Martin, B.B., Rieger, R.H. & Parente, E.J. (2009) Exercising videoendoscopic evaluation of 45 horses with respiratory noise and/or poor performance after laryngoplasty. *Veterinary Surgery*, 39, 942–948.
- Dixon, P.M., McGorum, B., Railton, D.I., Howe, C., Tremaine, W.H., Dacre, K. et al. (2003) Long-term survey of laryngoplasty and ventriculocordectomy in an older, mixed-breed population of 200 horses. Part 1: Maintenance of surgical abduction and complications of surgery. *Equine Veterinary Journal*, 35, 389–396.
- Ducharme, N.G. & Rossignol, F. (2019) Larynx. In: Auer, J.A., Stick, J.A., Kümmerle, J.M. & Prange, T. (Eds.) *Equine Surgery*, 5th Edition, St Louis, Missouri: Elsevier. pp. 735–769.
- Fulton, I., Anderson, B.H., Stick, J.A. & Robertson, J.T. (2012) Larynx. In: Auer, J.A., Stick, J.A. (Eds.) *Equine Surgery*, 4th Edition, St Louis, Missouri: Elsevier. pp. 592–622.
- Leutton, J.L. & Lumsden, J.M. (2015) Dynamic respiratory endoscopic findings pre- and post laryngoplasty in Thoroughbred racehorses. *Equine Veterinary Journal*, 47, 531–536.
- McCluskie, L.K., Franklin, S.H., Tremaine, W.H., Woodford, N.S. & Allen, K.J. (2009) *Post operative high speed treadmill endoscopy to determine the efficacy of upper respiratory tract surgery in horses with palatal dysfunction*. In: Proceedings of the British Equine Veterinary Association Congress, Equine Veterinary Journal Ltd., Newmarket. p. 168.



IN PRACTICE  
FOR 20 YEARS

# THERE WHEN YOU NEED IT

Bio-Sponge® Supports Intestinal  
Health of the Horse and Foal

Bio-Sponge® has been identified as a highly-effective adsorbent that attracts and binds intestinal compounds associated with intestinal disturbances.

Read more on the research at [PlatinumPerformance.com](http://PlatinumPerformance.com)

## Backed by Years of Research and Proven Results

### PROPHYLACTIC USE

Use Bio-Sponge® for foals on endemic farms or horses being treated with antibiotics.

### INTESTINAL DISTURBANCES

Bio-Sponge® supports horses and foals during intestinal disturbances or occasional diarrhea.

### FOAL HEAT SCOURS

Bio-Sponge® may be helpful to support foals experiencing foal heat scours.




**PLATINUM**  
PERFORMANCE®

(866) 553-2400  
[PlatinumPerformance.com](http://PlatinumPerformance.com)

Available in powder and paste



# Melanocortin-1 receptor influence in equine opioid sensitivity

Elouise K. Bacon<sup>1</sup> | Callum G. Donnelly<sup>2</sup>  | Rebecca R. Bellone<sup>2,3</sup>  | Carrie J. Finno<sup>2</sup>  |  
Brandon D. Velie<sup>1</sup> 

<sup>1</sup>Equine Genetics and Genomics Group, School of Life and Environmental Sciences, University of Sydney, Sydney, New South Wales, Australia

<sup>2</sup>Department of Population Health and Reproduction, School of Veterinary Medicine, University of California, Davis, California, USA

<sup>3</sup>Veterinary Genetics Laboratory, School of Veterinary Medicine, University of California, Davis, California, USA

## Correspondence

Brandon D. Velie

Email: brandon.velie@sydney.edu.au

## Summary

Individual variation in opioid sensitivity can have a profound impact on the safety and efficacy of equine veterinary treatments, with the ability to adequately manage equine pain in a clinical setting currently limited. This review aims to explore the overlap between biological mechanisms associated with opioid metabolism and those mechanisms associated with coat colour in horses as has been documented in humans, with particular focus on the melanocortin-1 receptor (*MC1R*) gene. In the future, the use of the *MC1R* coat colour genotype could help to indicate variable opioid sensitivities thereby greatly improving the use of opioids in clinical settings. The *MC1R* gene has a well-established role in melanogenesis and pigment switching, but involvement in the pain-modulating periaqueductal grey (PAG) descending pathway and in immune responses, both of which contain opioid receptors, has also been suggested in humans. However, this relationship between opioid metabolism and the connection to the three known *MC1R* variants ( $E^E$ ,  $E^e$  and  $E^{ea}$ ) in horses is yet to be explored.

## KEYWORDS

horse, melanocortin, genetics, opioid, sensitivity

## INTRODUCTION

The ability to appropriately manage equine pain in chronic and acute settings remains limited, constrained by challenges in cost, side effects of analgesia and lack of robust evidence regarding efficacy (Mama et al., 2019). Moreover, weight tapes and formulas currently used for the estimation of horse bodyweight have very limited accuracy, compounding the challenges experienced by veterinarians, even when isometric dosing of analgesics is applied (Wagner et al., 2011). Commonly administered analgesics have also failed to produce consistent antinociceptive results, and the effectiveness of opioids on healthy, pain-free horses typically vary greatly from those seen in the presence of pain in a clinical setting (de Oliveira et al., 2014; Robertson et al., 2014). Antinociceptive activity of opioids varies as a result of the proteins involved in the absorption, distribution,

metabolism, elimination and molecular aspects of target pathways (Yiannakopoulou, 2015). Mediated responses to opioids have also been associated with genetic variants, many of which influence a range of biological processes and molecular pathways (Angst et al., 2012; Kim et al., 2009; Klepstad et al., 2011; Stamer et al., 2008).

While direct effects are undoubtedly important, of particular interest are the pleiotropic effects of genes involved in the development of melanocytes within the melanocortin system, which account for several physiological and behavioural functions, including melanin-based coloration (Ducrest et al., 2008; Zhao et al., 2018). For example, the mRNA and protein from the melanocortin-1 receptor (*MC1R*) gene are expressed in the central nervous system in the periaqueductal grey matter of the midbrain in humans (Xia et al., 1995). This area is known to be involved in pain modulation in other species and contains widely distributed mu ( $\mu$ ) and kappa ( $\kappa$ ) opioid

This is an open access article under the terms of the Creative Commons Attribution-NonCommercial License, which permits use, distribution and reproduction in any medium, provided the original work is properly cited and is not used for commercial purposes.

© 2022 The Authors. *Equine Veterinary Education* published by John Wiley & Sons Ltd on behalf of EVJ Ltd.

receptors (Delaney et al., 2010; Gutstein et al., 1998). In horses, coat colour phenotypes also arise from the epistatic interaction of the *MC1R* gene and the agouti signalling protein (*ASIP*) gene—directing the production of red pheomelanin (*MC1R*) or black eumelanin (*ASIP*) (Rieder et al., 2001). Consequently, the chestnut coat colour arises from two recessive variations in the *MC1R* gene,  $E^e$  and  $E^{ea}$  (Marklund et al., 1996; Wagner et al., 2000). Theoretically, these variants may be contributing to opioid sensitivity that differs based on *MC1R* genotype ( $E/E$ ,  $E/E^e$ ,  $E/E^{ea}$ ,  $E^e/E^e$ ,  $E^{ea}/E^{ea}$ ).

As technology and research become more advanced, the importance of pharmacogenetics in pharmacotherapy is becoming increasingly prevalent. Despite this customised form of treatment being in its infancy in veterinary applications, pharmacogenetic testing has already been suggested as the 'standard of care' in canine breeds with a high risk of an *ABCB-1* mutation, especially in cases where vincristine, vinblastine, doxorubicin, loperamide or a macrocyclic lactone is the proposed treatment (Campion et al., 2019). However, cost-effectiveness is an ongoing concern in the uptake of pharmacogenetics, thus the application of an easily determined phenotypic or genotypic link to the variability of opioid sensitivity would enable safer, economical and more ethical use of opioids in clinical scenarios. This review looks to explore the gap in research into the pharmacogenetics of opioids in the horse, with a focus on *MCR* genes, to explore areas of overlap between biological mechanisms associated with opioid metabolism and the genes associated with coat colour. Existing research in horses, alongside opioid sensitivity information in other species, will be drawn upon to highlight key areas for further research in equine opioid sensitivity.

## OPIOIDS IN EQUINE PRACTICE

In the prescription of opioids in equine practice, an epidemiological study into the attitudes towards pain identified analgesic potency as the most important consideration, followed by the information available, and behavioural and gastrointestinal (GI) side effects (Price et al., 2002). Assessment of opioid analgesic potency has proven difficult, as it is often administered in conjunction with a sedative or tranquilising drug, skewing the results of traditional analgesia testing, which predominantly relies on motor responses as the experimental endpoint (Brunson et al., 1987; Clutton, 2010; Kalpravidh et al., 1984; Pippi et al., 1979). Today, it is acknowledged that the assessment of pain must take into account the cause, and animal and environmental factors, leading to the development of multifaceted pain assessment tools considering physiological and behavioural indices within the specific clinical setting (Hector et al., 2018).

Opioids such as morphine, methadone and oxymorphone have been used alone for analgesia and administered in conjunction with an alpha-2 adrenergic agonist responsible for decreasing afferent activity and activating descending inhibitory neurons (Guedes, 2017; Matthews et al., 2007). Alpha-2 adrenergic agonists alone have been associated with lower cardiac output and heart rate, and increased

systemic and vascular resistance (Pignatton et al., 2016; Wagner et al., 1991). However, the combined effect with opioids results in hyperpolarisation and reduced responsiveness of projection neurons, which has been attributed to enhancing analgesia and sedation while reducing side effects associated with opioid usage (Cruz et al., 2011; Guedes, 2017; Lopes et al., 2016).

A range of opioids have been used in horses, including pure  $\mu$ -opioid receptor (MOR) agonists (e.g. morphine, methadone, fentanyl, alfentanil), partial MOR agonists (e.g. buprenorphine) and  $\kappa$ -opioid receptor (KOR) agonist/ $\mu$ -antagonists (e.g. butorphanol, nalbuphine) (Mama et al., 2019). Due to the higher concentration of MORs in the horse's nervous tissue, pure MOR agonists were traditionally considered to have the most potent analgesic effect (Hellyer et al., 2003; Thomasy et al., 2007). However, butorphanol, a KOR agonist and partial MOR agonist, has been seen to have equal or greater efficacy in the treatment of GI pain, with potentially fewer side effects (Kalpravidh et al., 1984; Muir et al., 1985; Sellon et al., 2004; Thomasy et al., 2007). The exact role of different receptors in mediating excitatory behaviours has been difficult to determine due to typically small sample sizes and wide dose ranges of existing studies. Results of clinical investigations into the effectiveness of opioid analgesia varied significantly depending on the individual horse and level of pain, with horses also showing greater variability than other species (Rowland et al., 2014). Clinical studies have also seen variations resulting from age, and some research has been conducted into the effect of some genetic variations on opioid metabolism (Knych et al., 2015; Ohta et al., 2010; Sanchez et al., 2007; Wetmore et al., 2016). Currently, the most common opioid used in equine practice is butorphanol, with morphine, fentanyl and methadone also systemically administered (Robertson et al., 2014). This review will also cover hydromorphone due to the large amount of recent studies on its effectiveness and side effects.

## Overview of opioid metabolism

Opioids vary in their means of metabolism, with a general pattern that leads to the production of both active and inactive metabolites. The ultimate goal is to break down the lipophilic opioid to a hydrophilic state to facilitate urinary excretion (Smith, 2009). Opioid metabolism typically occurs in the liver facilitated by liver enzymes and can be separated into two phases; phase one modification reactions and phase two conjugation reactions, with different opioids going through these phases to varying extents.

Phase one metabolism typically involves hydrolysis or oxidation, involving cytochrome (CY) P450 enzymes in the liver that facilitate a range of reactions. CYP3A4 is the primary enzyme of drug metabolism in humans, acting on more than 50% of drugs, so the risk of drug-drug interactions in this phase is high (Smith, 2009). In horses, the CYP3A enzyme family has similarly been identified as the primary catalyst in phase one opioid metabolism; however, unlike humans, a member of the CYP2D family is also expected to have a role in this reaction (Knych et al., 2019; Sandbaumhuter et al., 2018).



Phase two metabolism involves the conjugation of the drug to a hydrophilic substance, often through glucuronidation, catalysed by the uridine diphosphate glucanosyltransferase (UGT) enzyme. In humans, UGT2B7 has been attributed to catalysing glucuronidation on both the three and six hydroxy positions in opioids, essential for the metabolism of hydromorphone and morphine to their primary metabolites: hydromorphone-6-glucuronide (H6G) and morphine-3-glucuronide (M3G) (Coffman et al., 1997). Incubations of morphine with equine liver microsome and four equine expressed UGTs identified that equine UGT2B31 was capable of metabolising M3G and M6G, indicating its involvement in glucuronidation. However, low yields of M6G suggest the possibility of currently unidentified UGTs contributing to morphine clearance, as is seen in humans (Hamamoto-Hardman et al., 2020). UGT2B31 has also been identified in dogs to catalyse the glucuronidation of opioids with a substrate specificity similar to human UGT2B7 and rat UGT2B1 (Soars et al., 2003). Interestingly, *in vitro* incubations of morphine with UGT2B31 yielded greater concentrations of M3G than those with human UGT2B7 supersomes. Findings in this study suggest glucosidation does not contribute to the clearance of morphine through M3 glucoside in the equine liver, contrary to what is seen in humans (Hamamoto-Hardman et al., 2020). These results indicate some variation in the metabolism efficiency and pathways in horses. However, this study was the first to describe the phase two metabolism of opioids in equine UGTs, with further research required to fully understand the extent and effects of variations between species.

## Opioid receptors

Opioid receptors are 7-transmembrane spanning proteins and part of the G-protein coupled receptor superfamily. Opioid receptor activation via agonists, either endogenous (e.g. endorphin) or exogenous (e.g. morphine), causes the  $G\alpha$ - and  $G\beta$ - $\gamma$  sub-units to dissociate, acting on multiple intracellular effector pathways, in particular, activation of descending inhibitory pathways in the midbrain and the inhibition of neurotransmitter release from spinal cord primary afferent terminals (Al-Hasani et al., 2011; Chahl, 1996). Opioid receptors have been identified as expressed in medulla locus coeruleus, and periaqueductal grey area (PAG) pathways, and in the limbic, midbrain and cortical structure (Al-Hasani et al., 2011). To date, four opioid receptors have been characterised at the cellular, molecular and pharmacological levels; mu ( $\mu$ ), kappa ( $\kappa$ ), delta ( $\delta$ ) and opioid receptor-like 1 (ORL1). All four couple to pertussis toxin-sensitive G-proteins, including  $G\alpha$ - and  $G\beta$ - $\gamma$ , resulting in inhibition of cyclic adenosine monophosphate (cAMP) formation (Al-Hasani et al., 2011). The inhibition of cAMP production impedes neurotransmitter release and, in conjunction with the actions of opioid receptors in modulating potassium and calcium ion channels, results in inhibitory effects on neural excitability.

The primary opioid receptors are  $\mu$ ,  $\kappa$  and  $\delta$ , with the density, distribution and binding characteristics of each varying between species. In horses, the percentage of total opioid binding sites within

the cerebral cortex for  $\mu$ ,  $\kappa$  and  $\delta$ , are 71%, 14% and 15%, respectively, with a significantly higher density of MOR in comparison to rats, with their corresponding values 56%, 4% and 40% (Thomasy et al., 2007). In comparison to dogs, horses have significantly higher binding to MORs in the frontal cortical region of the brain and the colliculus and granule cell layer of the cerebellum, but no significant difference in midbrain subregions (Hellyer et al., 2003). Variations seen in binding density could account for the greater excitatory effects of MOR agonists in horses; however, more horse-specific research is required in the field to understand the mechanisms contributing to this result.

## Butorphanol

Butorphanol is a synthetic 12-hydroxymorphinan analogue that acts as a KOR agonist and partial MOR agonist. Butorphanol is metabolised in the liver primarily by phase one hydroxylation, with the resulting metabolites not retaining their analgesic activity, and are excreted in the urine (Schnellbacher, 2010). When compared with other opioids, butorphanol has been seen to produce the most reliable response when in conjunction with an alpha-2 adrenergic such as detomidine, increasing apparent sedation and decreasing response to external stimuli (Clarke et al., 1988). Still, some side effects including ataxia and excitatory behaviours such as locomotion have been seen at varying extents in conjunction with the administration of butorphanol (Arguedas et al., 2008; de Grauw et al., 2020; Queiroz-Neto et al., 2013; Robertson et al., 1981). However, due to its competitive MOR antagonist effects, low-dose butorphanol has been shown in other species to reverse/minimise some cardiovascular effects of pure MOR agonist opioids (Flecknell et al., 1989; Haw et al., 2016).

## Morphine

Morphine is a MOR agonist and is often the basis for comparison with other opioids. Morphine is broken down in phase two metabolism glucuronidation by UGT2B31 and other UGT enzymes in the horse's liver at the three and six positions to produce its metabolites M3G and lower concentrations of morphine-6-glucuronide (M6G) (Hamamoto-Hardman et al., 2020). Horse liver cultures have also indicated that, unlike in humans, glycooxidation does not contribute to the elimination of morphine through the production of M3 (Hamamoto-Hardman et al., 2020). Morphine administration in horses has resulted in excitatory effects similar to those seen in other MOR agonists. In two studies of IV morphine at dosages of 0.05, 0.1, 0.2 or 0.5 mg/kg, decreased gastrointestinal activity was seen across all groups, and ataxia was observed at higher doses. Researchers also correlated increased morphine dose with increased M3G concentrations and adverse side effects (Hamamoto-Hardman et al., 2019; Knych et al., 2014). Post administration of 0.05 mg  $kg^{-1}$  morphine 12 hourly for 6 days, horses recorded GI dysfunction

for up to 6 h. Defecation frequency decreased from  $3.1 \pm 1$  to  $0.9 \pm 0.5$ , with faecal matter weight decreased from  $4.1 \pm 0.7$  kg to  $1.1 \pm 0.7$  kg and faecal moisture content decreased from  $76 \pm 2.7\%$  to  $73.5 \pm 2.9\%$  (Boscan et al., 2006).

## Fentanyl

Fentanyl is a synthetic MOR stimulating opioid and is metabolised primarily in phase one of drug metabolism by CYP3A4 (Labroo et al., 1997). Resultant of its actions in phase one metabolism, fentanyl is susceptible to drug interactions when given in conjunction with other drugs, which can result in increased presence in plasma or prolonged effect of the opioid (Stanley, 2014). Fentanyl has been associated with similar central nervous system (CNS) excitation effects seen in other MOR agonists, including a dose-related increase in respiratory and cardiac rates, and stepping frequency (Kamerling et al., 1985). Variations in analgesic effects of fentanyl have been noted with age, with IV administration not producing significant antinociceptive effects in adult horses, whilst IV administration to foals at escalating doses resulted in heavy sedation (Knych et al., 2015; Ohta et al., 2010; Sanchez et al., 2007). Additionally, pharmacogenetic research has recently been conducted to explore the effect of genetic polymorphisms on fentanyl effectiveness, with horses harbouring the G57C polymorphism of the MOR displaying a significant increase in locomotion after fentanyl administration ( $20 \mu\text{g}/\text{kg}$ , IV) (Wetmore et al., 2016).

## Methadone

Methadone is a synthetic MOR agonist, administered as a racemic mixture of R- and S-enantiomers, the former of which is responsible for the majority of opioid effects (Volpe et al., 2018). Methadone undergoes N-demethylation by CYP enzymes in phase one metabolism, forming an unstable compound that undergoes spontaneous cyclisation and dehydration, with the metabolites inactive and excreted renally. A comparative study found methadone alone insufficient to increase antinociceptive threshold and resulted in excitatory side effects, whilst a lower dose administered in conjunction with detomidine showing significant sedation without such adverse effects (de Oliveira et al., 2014). However, this result is dose-dependent, with a 2019 study identifying detomidine ( $5 \mu\text{g kg}^{-1}$ ) unable to consistently overcome adverse side effects (Gozalo-Marcilla et al., 2019).

## Hydromorphone

Hydromorphone is a hydrogenated ketone of morphine, metabolised extensively in phase two metabolism to H3G and dihydroisomorphine glucuronide (Murray et al., 2005). Analgesic effects of hydromorphone are from H3G interactions with MORs, also acting centrally at the medulla and depressing respiratory drive (Abi-Aad

et al., 2021). In comparing neuroexcitatory characteristics, dose-dependent excitation after the administration of H3G is similar to that seen with the morphine metabolite M3G (Wright et al., 2001). Additionally, H3G was recorded to be approximately 2.5 times more potent than M3G, and quantitative analysis in naïve adult rat livers saw a 75%–80% microsomal conversion efficiency of hydromorphone to H3G (Wright et al., 1998). Central nervous system excitation and GI dysfunction have been extensively observed following the administration of hydromorphone in healthy, pain-free horses. Single intravenous (IV) hydromorphone administration led to a dose-dependent increase in heart rate and systolic arterial pressure across two studies; however, some contradictions were seen in adverse effects on respiratory rate, arterial gases, faecal output and temperature (Martins et al., 2020; Reed et al., 2019). From this, Reed et al. (2019) identified a dosage rate of  $0.04 \text{ mg kg}^{-1}$  as providing clinically relevant thermal anticonception with minimal adverse effects. Further studies comparing IV and intramuscular (IM) hydromorphone (both at  $0.04 \text{ mg kg}^{-1}$ ) found both methods of administration to provide effective analgesia for up to 8 hours (Reed et al., 2020). The maximum concentration of H3G in plasma after administration was significantly higher in the IV group ( $54.1 \pm 5.84 \text{ ng mL}^{-1}$ ) compared with the IM group ( $23.5 \pm 5.5 \text{ ng mL}^{-1}$ ). However, this study was unable to quantify the excitement characteristics of individuals post-treatment, so the significance of different plasma concentrations and the potential bearing on adverse effects of hydromorphone requires further exploration (Reed et al., 2020).

The dose-dependent nature of side effects attributed to the opioids covered highlights the need for a greater ability to determine the analgesic sensitivity of individual horses, better tailoring treatment to minimise harmful effects and maximise welfare outcomes and safety both for veterinarians and equine patients.

## MELANOCORTIN SYSTEM

Melanocortins are the collective of alpha ( $\alpha$ -), beta ( $\beta$ -) and gamma ( $\gamma$ -) melanocyte-stimulating hormones (MSH) and adrenocorticotropin (ACTH) derived from proopiomelanocortin (POMC) via enzyme activity (Chaki et al., 2005). Due to research availability, much of the information available on the melanocyte system uses humans or mice; however, equine POMC processing appears to be similar to that of other species (Wilson et al., 1982). MC1R is one of 5 receptor subtypes (MC1R–MC5R) of the melanocortins, all of which belong to the G-protein coupled receptor superfamily. MC1R exhibits a high affinity for  $\alpha$ -melanocyte-stimulating hormone ( $\alpha$ -MSH) and has a well-documented role in melanogenesis. This receptor also plays a role in the anti-inflammatory response, and its expression has been recorded on macrophages and monocytes, endothelial cells, glioma cells, astrocytes, fibroblasts and keratinocytes (Mountjoy et al., 1992; Wikberg, 1999). MC2R is predominantly expressed in the adrenal cortex and mediated ACTH-induced steroidogenesis. MC3R has been attributed to a

role in autonomic functions and energy homeostasis, while MC5R resides ubiquitously in peripheral tissues, impacting the regulation of exocrine secretions. MC3R and MC4R are both expressed mainly in the brain, with MC4R critical in the central regulation of feeding behaviour, energy expenditure, addiction to drugs, pain processes and regulation of the hypothalamus-pituitary axis (HPA). In mice, MC4R has also been seen to influence anxiety and depressive behaviours in the dorsal raphe nucleus through regulation of the serotonergic system (Bruschetta et al., 2020). MC1R has similarly been seen to affect anxiety with *MC1R* variants recording significant differences in dental care-related anxiety (Binkley et al., 2009). However, the mechanisms of this relationship are yet to be deeply explored, with a possible explanation being a simultaneous variation of other melanocortin receptors. Of particular interest are the *MC1R* and *MC4R* genes and the potential of dual variations indicating plausibility of the association of coat colour and opioid sensitivity. Whilst there are three variants of the horse *MC1R* gene that have been connected to a pigmentation phenotype, there are no reported variants in *MC4R* that have been connected to a known phenotype in the horse (Andersson, 2003; Corbin et al., 2020).

### Pigmentation expression of melanocortin-1 receptor and agouti signalling protein

Accurate identification of coat colour is key in outlaying a foundation for genetic investigations and for registration purposes. Equine coat colour can be attributed to the interactions of several genes (Sponenberg et al., 2017). The *MC1R* and agouti signalling protein (*ASIP*) genes and their corresponding variants determine the basis of equine coat colour through regulation of eumelanin and pheomelanin (Zhao et al., 2018). *MC1R* resides on the surface of melanocytes, which, when activated by  $\alpha$ -MSH, the dominant *MC1R* ( $E^E$ ) allows the transmission of information to trigger a series of reactions that lead to the production of eumelanin. In horses possessing the common variant *MC1R* ( $E^E$ ) corresponding to a recessive missense mutation (S83F) or the rare recessive allele *MC1R* ( $E^{ea}$ ), the receptor is unable to transmit information from  $\alpha$ -MSH activation, resulting in the production of pheomelanin in place of eumelanin (Marklund et al., 1996; Neves et al., 2017; Wagner et al., 2000). Thus, horses homozygous for the loss of function mutations will only produce red pigment and are described as chestnut colour. *ASIP* acts as an antagonist to the *MC1R* gene, reducing its responsiveness to  $\alpha$ -MSH, limiting the subsequent increase in adenylate cyclase and tyrosinase, the enzymes responsible for melanogenesis. This creates a blockade effect preventing stimulus for the production of eumelanin, subsequently leading to the synthesis of pheomelanin, restricting black coloration to the points resulting in a bay horse (Sponenberg et al., 2017; Swope et al., 2012). The recessive *ASIP* ( $A^a$ ) is caused by an 11 base pair deletion in the second exon initiating a frameshift in the *ASIP* protein, resulting in a loss of function and thus signalling through *MC1R* produces an all-black coat colour (Daverio et al., 2016). The

chestnut coat colour  $E^E/E^E$  or  $E^{ea}/E^{ea}$  is epistatic to *ASIP* (Neves et al., 2017).

### Pleiotropic effects of the melanocortin-1 receptor

Chestnut horses have often been reported by their owners as being flightier than other colours, which suggests a possible association of *MC1R* variants with behavioural traits. A behavioural association study assessed this relationship, utilising an owner-completed questionnaire and visual identification of phenotype. Investigations revealed chestnut horses as significantly more likely to approach foreign stimuli within their environment, perceiving them as 'bolder'. This was the only significant difference to be associated with base coat colour; however, the study did not genotype horses, thus the inability to discern intermediate phenotypes may have weakened potential associations (Finn et al., 2016). Similarly, a behaviour study of genotyped Tennessee walking horses, also using owner surveys, found no significant association of behaviour with *MC1R* locus or combined genotype effects of *ASIP* or *MC1R*. Results revealed the only significant association of colour was in black mares ( $A^a/A^a$ ) significantly more self-reliant than bays ( $A^A/_$ ) defined by restlessness when solitary (Jacobs et al., 2016). Results of both investigations revealed associations with age and sex, with Finn et al. (2016), also seeing associations with breed and age in which the horse was first handled (Finn et al., 2016). Investigations into the association of the *MC1R* variants and behavioural traits to date have been limited and none have explored associations in pain or analgesic sensitivity, with greater research into this area needed in the equine field to improve precision medicine (Chen et al., 2017a, 2017b; Jacobs et al., 2016).


While limited research on *MC1R* outside of coat colour has been done in horses, studies of other species have established numerous other roles of the *MC1R* gene. In addition to its widely accepted roles in pigmentation, the *MC1R* gene has also been correlated with anxiety, being seen as a significant predictor of dental care-related anxiety in humans (Binkley et al., 2009). The *MC1R* gene has also been implicated in burn injury complications, with human studies showing *MC1R* polymorphisms may contribute to systemic infectious response syndrome associated with infectious complications and organ failure following major burn injury (Carter et al., 2018). Pheomelanin pigment pathways resultant from *MC1R* polymorphisms have also been attributed to ultraviolet-radiation independent melanoma carcinogenesis via a mechanism of oxidative damage, with variants presenting the highest melanoma risk (Chen et al., 2017a, 2017b; Mitra et al., 2012; Tell-Marti et al., 2020). Epidemiological studies have established a bidirectional association between melanoma risk and Parkinson's disease, with *MC1R* involvement indicated in this relationship (Huang et al., 2015; Olsen et al., 2006; Siple et al., 2000). Additionally, *MC1R* recessive mutants have been shown to have compromised dopaminergic neuronal integrity, increasing their susceptibility to dopaminergic neurotoxins (Chen et al., 2017a, 2017b; Tell-Marti et al.,



*Sonosite Vet is Gone...Now What?*

# THE NEW EVO

## MEET YOUR NEXT EQUINE ULTRASOUND



*Scan QR code to learn more about our **\$3K+ trade-in allowance** or to request a free trial...*

*No trade? Scan and ask about our other incentives.*

### **SPRING BREEDING**

#### **Minimum \$3K Trade-in Allowance Toward Purchase**

E.I. Medical Imaging has manufactured veterinary-specific ultrasound equipment right here in the US since 1984.

#### **The ALL-NEW EVO III...**

- Compare to EDGE II, M-Turbo images
- Redesigned broadband probes
- Improved battery life
- Ideal for repro, TVA, sports med and more

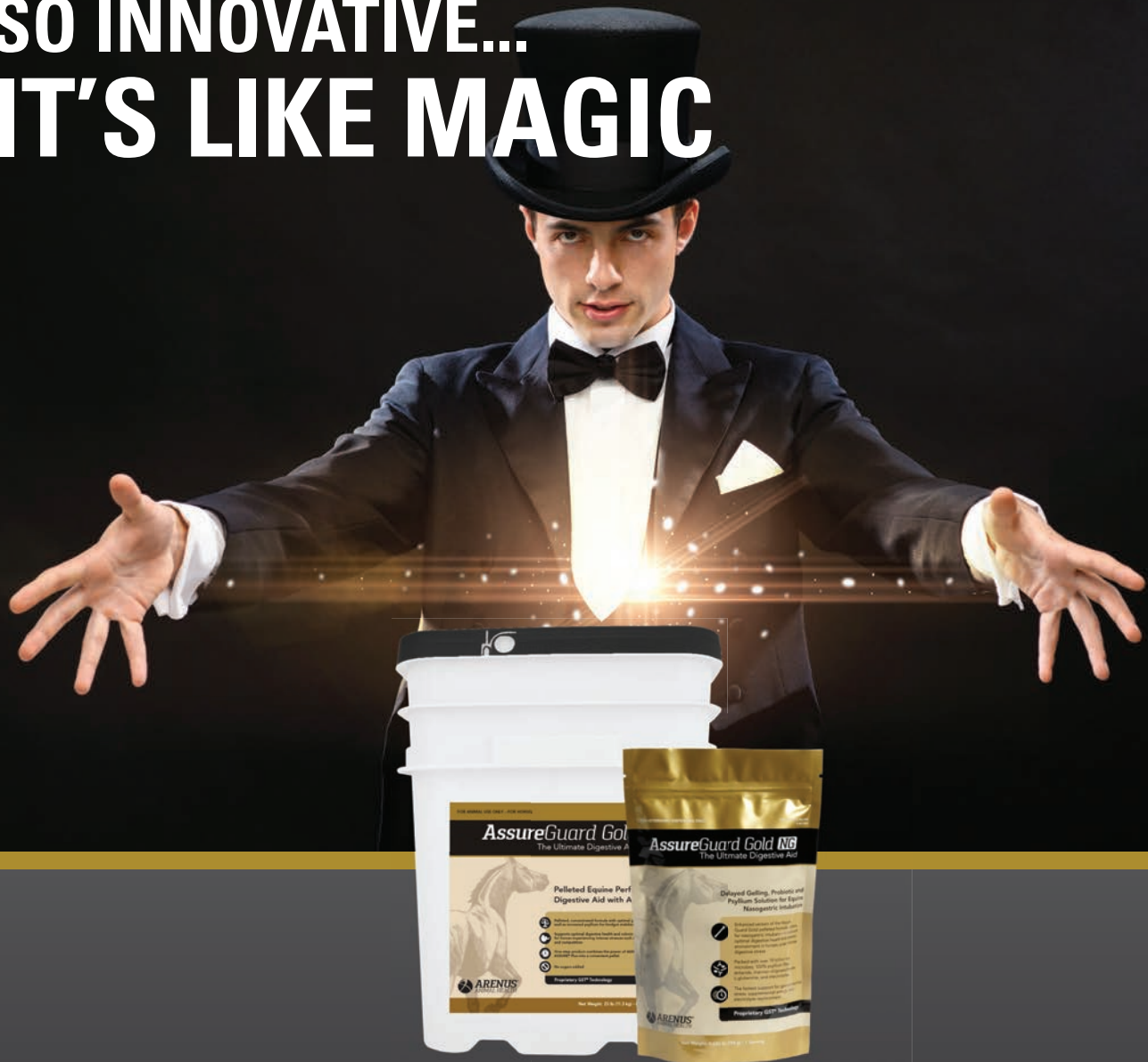#### **Proprietary features that set us apart from the competition**

- Gestation tables
- Customizable annotations
- Split screen
- Post-exam image editing
- Unlimited record length
- USB export
- Streaming app
- Unique eCLi4 probe for repro

*Some Restrictions May Apply*

**E.I. MEDICAL IMAGING**  
1.866.365.6596 • [www.eimedical.com/evo3-equine](http://www.eimedical.com/evo3-equine)

# SO INNOVATIVE... IT'S LIKE MAGIC



## *Assure<sup>®</sup> Guard Gold* AND *Assure<sup>®</sup> Guard Gold **NG*** **The Ultimate Digestive Aid<sup>®</sup>**

### THE REAL MAGIC IS IN THE RESULTS

**Together, Assure Guard Gold-NG And Assure Guard Gold Create A Powerhouse Against Your Most Challenging Digestive Cases.**

**Use Assure Guard Gold-NG For Fast Relief And Maintain Excellent Digestive Health With Assure Guard Gold.**

Replace your mineral oil, electrolytes, adsorbents, or other treatment options with Assure Guard Gold-NG the only effective and easy to administer slow gelling quick relief formulation including 2 cups of ultra pure psyllium, 72 billion CFU of probiotics, prebiotics, antacids, L-glutamine, electrolytes and energy.

For continued support, consider a 10 day supply of Assure Guard Gold after treatment.



Arenus Animal Health | 866-791-3344 | [www.arenus.com](http://www.arenus.com)

Ask your Arenus Veterinary Solution Specialist how Assure Guard Gold-NG and Assure Guard Gold can help your equine patients quickly and effectively recover from the digestive upsets you treat daily.



2020). Moreover, MC1R is essential in the  $\alpha$ -MSH suppression of lipopolysaccharide-induced inflammatory activity in macrophages, indicating a possible variability in the intracellular pathways in which they function when expressed on immune cells (Li et al., 2008). However, it is not yet established if this is due to the effects of this variant or other associated genetic variant(s).

## Roles of the melanocortin-4 receptor

In the equine field, there has also been little investigation into the multiple roles and implications of the MC4 receptor. In fact, to date, no variants in this gene have been connected with any known phenotype in horses. However, various rodent models have been used to demonstrate the extensive range of actions in which MC4R is involved, including feeding, energy expenditure, pain processes and behavioural aspects of addiction, anxiety and depression (Balthasar et al., 2005; Bruschetta et al., 2020; Caruso et al., 2007; Chaki et al., 2005; Chen et al., 2017a, 2017b; Fontanesi et al., 2013; Irani et al., 2005; Kumar et al., 2009; Lu et al., 2003; Mansour et al., 2010; Sandrock et al., 2009; Sartin et al., 2008; Van der Ploeg et al., 2002).

Central to its widespread effects is the involvement of MC4R in the hypothalamus-pituitary axis. Plasma levels of ACTH and corticosterone appear to be influenced by the MC4R gene, supported by the presence of MC4R within a subpopulation of corticotropin-releasing hormone neurons in the paraventricular nucleus of the hypothalamus (Lu et al., 2003; Von Frijtag et al., 1998). The corticotropin-releasing hormone has been hypothesised to act as a downstream mediator contributing to the central melanocortin systems control of feeding and neuroendocrine response via the hypothalamus-pituitary axis. The involvement of the MC4R gene in this area has also been seen to affect the inflammatory regulation of prostaglandins and nitric oxide through its modulatory role in early hypothalamic response to interleukin-1 beta (Cragnolini et al., 2006). Findings of a 2007 study suggest  $\alpha$ -MSH, through MC4R activation, reduces inflammation by decreasing nitric oxide synthase and cyclooxygenase-2 expression and prevents apoptosis of astrocytes through modulation of expressed proteins (Caruso et al., 2007).

Importantly, the MC4R has also been implicated in opioid interactions and nociception and has been identified to be antagonised by agouti-related protein (AgRP) similar to MC1R (Lu et al., 1994). MC4R, POMC and AgRP transcripts have all been detected in the spinal cord and dorsal root ganglion, with upregulation of POMC and MC4R seen in the presence of tactile allodynia and thermal hyperalgesia in neuropathic rats indicating the involvement of the MC4R gene in nociception (Beltramo et al., 2003). Investigations into MC4R opioid interactions saw antinociceptive effects of morphine increase with both pharmacological and genetic blockade of the MC4R, but the potency for locomotor activity is unchanged (Ercil et al., 2005). Additionally, chronic administration of morphine has been seen to cause down-regulation of MC4R mRNA expression in

the nucleus accumbens, striatum and PAG regions involved in behavioural effects of opiates, whilst levels of MC4R mRNA expression in other brain regions were not affected, indicating the possible involvement of MC4R down-regulation in opiate tolerance and dependence (Alvaro et al., 1996). Further studies have suggested that agonist activity at MCRs potentiated amphetamine reward, and changes to MC4R expression resulted in other functional consequences, supporting the role of the MC4R neuropeptide system in both behavioural and biochemical effects of opioids (Alvaro et al., 2003; Cabeza de Vaca et al., 2002). The MC4R gene has also been implicated in stress-induced changes in behaviour, with the administration of a selective MC4R antagonist showing anxiolytic and antidepressant-like activities in various rodent models (Chaki et al., 2003, 2005; Vergoni et al., 1999). Chemogenetic activation of dorsal raphe nucleus MC4R neurons has also been seen to reverse the effects of anxiety, depression and reduced feeding resultant from inhibition of these neurons (Bruschetta et al., 2020).

Further behavioural effects of MC4R have been seen in relation to feeding, with agouti obesity syndrome in mice described as a result of chronic antagonism of the MC4R, disrupting the inhibitory signals that melanocortin neurons exert on feeding behaviour (Fan et al., 1997; Huszar et al., 1997). Activation of the neuronal MC4R is also required for cholecystokinin-induced suppression of feeding and is necessary for the control of dietary fat intake (Fan et al., 2004; Samama et al., 2003). MC4R polymorphisms in pigs identified similar results, with certain mutations significantly affecting production traits including average daily gain and feed gain ratio (Fontanesi et al., 2013). Agouti inhibition of MC4R has also demonstrated modulatory effects on constant grazers similar to horses, stimulating food intake in healthy sheep and preventing appetite inhibition in response to endotoxins (Sartin et al., 2008; Wagner et al., 2004). Subsequent alterations in food intake account for approximately 60% of the effects of the MC4R gene on energy balance, with the remaining 40% due to changes in energy expenditure (Balthasar et al., 2005). MC4R has been hypothesised to play a role in energy partitioning through insulin release and peripheral responsiveness due to its involvement in the communication pathway between the central MC system and pancreatic islets in the regulation of insulin (Fan et al., 2000; Mansour et al., 2010). Moreover, MC4R agonist activity has been shown to improve glucose homeostasis through melanocortin agonist-induced weight loss and liver metabolism improvements (Kumar et al., 2009).

## MELANOCORTIN RECEPTORS AND OPIOID METABOLISM

Due to the extensive distribution of MCRs throughout the CNS, there are many sites of interaction with opioid receptors that may contribute to possible effects on opioid sensitivity. Derivation of both melanocortin and opioid receptors from the G-protein coupled receptor superfamily may also have a role in potential interactions (Al-Hasani et al., 2011; Chaki et al., 2005).



## Melanocortin-1 receptor and opioid receptor interaction in the periaqueductal grey

Primary afferent nociceptors convey pain to the dorsal horn of the spinal cord, after which ascending pathways transmit the information to the brain. These ascending pathways are modulated by supraspinal descending pathways, serving as an endogenous analgesic system (Lau et al., 2014). PAG acts on the rostral ventromedial medulla (RVM) to project to the spinal cord dorsal horn, with activation of this descending pathway inhibiting ascending nociceptive transmission and subsequently eliciting analgesia (Lau et al., 2014). Opioids are hypothesised to act on this system via gamma-aminobutyric acid (GABA) neurotransmitter disinhibition, whereby tonically active GABAergic interneurons within the PAG and RVM release GABA, which acts via GABA<sub>A</sub> to inhibit spinal output neurons (Galaj et al., 2020). Additionally, MORs are highly expressed in GABA neurons; however, direct evidence supporting the opioid-induced GABA disinhibition hypothesis of the PAG-RVM pathway is still lacking.

Patch-clamp recordings from rats showed opioids acted via KORs and MORs but not DORs to inhibit GABAergic and glutamatergic synaptic inputs onto PAG neurons presynaptically, acting on the systems that indirectly control output neurons projected to the RVM (Lau et al., 2020). MOR and KOR mRNA and immunoreactivity (IR) are widely distributed throughout the PAG and RVM, with significant MOR and KOR IR overlap in the nucleus raphé Magnus and ventrolateral PAG. The anatomical distribution of KOR and MOR mRNA and IR in PAG correlated with areas known to project to the RVM, suggesting both receptors play a role as antagonists in regulating the PAG-RVM local circuit required for analgesia (Gutstein et al., 1998). Additionally, investigations into rats have identified the presence of a small number of cells with scattered distribution showing a specific hybridisation signal for MC1R mRNA (Xia et al., 1995). Immunoreactivity for MC1R was also detected in scatter cells within human PAG, indicating a restricted distribution of MC1R in the CNS. Despite lacking evidence from horses, the presence of MC1R in PAG in other species flags it as a gene of interest for further research into variable opioid sensitivity.

## Melanocortin-1 receptor and opioid receptor expression on immune cells

The interactions between the opioid peptide-expressing immune cells and the sensory neurons expressing opioid receptors represent an intrinsic pain control mechanism in both humans and animals (Machelska et al., 2020). Several studies of normal human immune cells have identified mRNA of MORs in T and B lymphocytes, monocytes/macrophages and granulocytes, with DOR mRNA expressed in low levels in T, B and monocyte cell line, and KORs only in B cell lines (Chuang et al., 1995; Gavériaux et al., 1995). Moreover, MC1R has been accepted to have a role in anti-inflammatory response and

its expression has been validated at high levels on melanocytes and granulocytes (i.e. neutrophils, eosinophils and basophils) (Guida et al., 2021). Although it is yet unknown the importance of combined immune cell expression of opioid receptors and the MC1R gene in an equine clinical setting, the implications of this interaction in the presence of pain and increased immune response prior to opioid administration could account for variances in opioid sensitivity. To date, the majority of equine opioid studies have involved healthy horses or retrospective evaluations, so more targeted research is required in this area to best understand the implications of this relationship. Immune cell-mediated analgesia also presents an opportunity for minimising side effects associated with opioids; however, this is yet to be explored in horses.

## Melanocortin-1 receptor gene, pain and analgesia links in horses

To date, studies exploring the relationship of the MC1R to variations in pain and analgesic sensitivity in horses are lacking. As such, information must be extrapolated from the evidence provided by other species to understand the potential role of the MC1R in pain and opioid analgesia.

## Melanocortin-1 receptor gene, pain and analgesia links in humans

In humans, MCRs demonstrate antagonistic effects over the analgesia of morphine and beta-endorphin, with findings suggesting alterations of the MC system within the CNS may be associated with an increased pain state (Vrinten et al., 2000). A study of red-haired and dark-haired women testing the influence of MC1R variation on pain sensitivity saw electrical current perception, pain perception and pain tolerance similar across the two groups. However, red-haired women were more sensitive to thermal pain, recording a 1.8 times increase in sensitivity to cold pain perception (average sensitivities of 22.6 vs. 12.6°C in dark hair group), lower cold pain tolerance (6.0 vs. 0°C) and heat pain tolerance lower by a factor of 1.03 (Liem et al., 2005). Conversely, a gene dosage study of pain and M6G analgesia in humans indicated carriers of a nonfunctional MC1R variant to have a 1.3-time greater tolerance to electrical pain stimulus before M6H administration, with nonfunctional MC1R mice displaying a similar decreased pain sensitivity across a range of nociceptive modalities. After M6G administration, analgesic response in subjects possessing an MC1R variant appeared to be greater, producing a 49% increase in tolerable current, compared with an 18% increase in the control group (Mogil et al., 2005). A possible explanation for the contradictory results across the two studies could be the influence of gender, with Liem et al. only including women (Liem et al., 2005). Nevertheless, both studies demonstrate a degree of pain sensitivity differentiation associated with an MC1R variation, with results representative of the implication of specific pathways involved in pain.

## CONCLUSION

Variable sensitivities to administered opioids in horses result from drug interaction across multiple pathways of its metabolism and actions. Immunoreactivity and mRNA of the *MC1R* gene have been identified in conjunction with opioid receptors in both the PAG pain-modulating descending pathway and in some immune cells in other species. Other members of the melanocortin receptor family have also been identified to be involved in behaviour and potentially pain, allowing the possibility of simultaneous mutations in the melanocortin receptors contributing to analgesic effectiveness. Genetic variations in the *MC1R* gene in humans and other species have been identified to alter pain and analgesic sensitivity. Whilst we acknowledge the pharmacodynamic interactions involved in analgesics are complex, we hypothesise equine coat colour variations to play a role, acting as a possible phenotypic indicator for variations in opioid sensitivity. However, similar studies investigating the three known variation in *MC1R* in horses and connection to pain and analgesic metabolism are yet to be conducted in horses and present itself as a potential area for improvement in the safety and administration of opioids used in equine veterinary practices through greater pharmacogenetic understanding.

## AUTHOR CONTRIBUTIONS

E. Bacon, C. Donnelly, R. Bellone, C. Finno and B. Velie designed the project. E. Bacon and B. Velie prepared the manuscript. E. Bacon, C. Donnelly, R. Bellone, C. Finno and B. Velie commented on and approved the final version of the manuscript.

## CONFLICTS OF INTEREST

R. Bellone is affiliated with the UC Davis Veterinary Genetics Laboratory that offers genetic testing in horses and other species, including testing for *MC1R*. No other authors have personal or financial relationships with people or organisations that could influence the content of this review.

## ORCID

Callum G. Donnelly  <https://orcid.org/0000-0003-1503-1419>

Rebecca R. Bellone  <https://orcid.org/0000-0001-8838-7227>

Carrie J. Finno  <https://orcid.org/0000-0001-5924-0234>

Brandon D. Velie  <https://orcid.org/0000-0001-9359-6138>

## REFERENCES

- Abi-Aad, K.R. & Derian, A. (2021) *Hydromorphone*. Treasure Island (FL): StatPearls.
- Al-Hasani, R. & Bruchas, M.R. (2011) Molecular mechanisms of opioid receptor-dependent signaling and behavior. *Anesthesiology*, 115(6), 1363–1381.
- Alvaro, J.D., Tatro, J.B., Quillan, J.M., Fogliano, M., Eisenhard, M., Lerner, M.R. et al. (1996) Morphine down-regulates melanocortin-4 receptor expression in brain regions that mediate opiate addiction. *Molecular Pharmacology*, 50(3), 583–591.
- Alvaro, J.D., Taylor, J.R. & Duman, R.S. (2003) Molecular and behavioral interactions between central melanocortins and cocaine. *Journal of Pharmacology and Experimental Therapeutics*, 304(1), 391–399.
- Andersson, L. (2003) Melanocortin receptor variants with phenotypic effects in horse, pig, and chicken. *Annals of the New York Academy of Sciences*, 994(1), 313–318.
- Angst, M.S., Phillips, N.G., Drover, D.R., Tingle, M., Ray, A., Swan, G.E. et al. (2012) Pain sensitivity and opioid analgesia: A pharmacogenomic twin study. *Pain*, 153(7), 1397–1409.
- Arguedas, M.G., Hines, M.T., Papich, M.G., Farnsworth, K.D. & Sellon, D.C. (2008) Pharmacokinetics of butorphanol and evaluation of physiologic and behavioral effects after intravenous and intramuscular administration to neonatal foals. *Journal of Veterinary Internal Medicine*, 22(6), 1417–1426.
- Balthasar, N., Dalgaard, L.T., Lee, C.E., Yu, J., Funahashi, H., Williams, T. et al. (2005) Divergence of melanocortin pathways in the control of food intake and energy expenditure. *Cell*, 123(3), 493–505.
- Beltramo, M., Campanella, M., Tarozzo, G., Fredduzzi, S., Corradini, L., Forlani, A. et al. (2003) Gene expression profiling of melanocortin system in neuropathic rats supports a role in nociception. *Brain Research. Molecular Brain Research*, 118(1–2), 111–118.
- Binkley, C.J., Beacham, A., Neace, W., Gregg, R.G., Liem, E.B. & Sessler, D.I. (2009) Genetic variations associated with red hair color and fear of dental pain, anxiety regarding dental care and avoidance of dental care. *Journal of the American Dental Association*, 140(7), 896–905.
- Boscan, P., Van Hoogmoed, L.M., Farver, T.B. & Snyder, J.R. (2006) Evaluation of the effects of the opioid agonist morphine on gastrointestinal tract function in horses. *American Journal of Veterinary Research*, 67(6), 992–997.
- Brunson, D.B. & Majors, L.J. (1987) Comparative analgesia of xylazine, xylazine/morphine, xylazine/butorphanol, and xylazine/nalbuphine in the horse, using dental dolorimetry. *American Journal of Veterinary Research*, 48(7), 1087–1091.
- Bruschetta, G., Jin, S., Liu, Z.W., Kim, J.D. & Diano, S. (2020) MC4R signaling in dorsal raphe nucleus controls feeding, anxiety, and depression. *Cell Reports*, 33(2), 108267.
- Cabeza de Vaca, S., Kim, G.Y. & Carr, K.D. (2002) The melanocortin receptor agonist MTII augments the rewarding effect of amphetamine in ad-libitum-fed and food-restricted rats. *Psychopharmacology (Berl)*, 161(1), 77–85.
- Campion, D.P. & Dowell, F.J. (2019) Translating pharmacogenetics and pharmacogenomics to the clinic: progress in human and veterinary medicine. *Frontiers in Veterinary Science*, 6, 22.
- Carter, D.W., Sood, R.F., Seaton, M.E., Muffley, L.A., Honari, S., Hocking, A.M. et al. (2018) *MC1R* gene polymorphisms are associated with dysfunctional immune responses and wound infection after burn injury. *Journal of Surgical Research*, 231, 448–452.
- Caruso, C., Durand, D., Schioth, H.B., Rey, R., Seilicovich, A. & Lasaga, M. (2007) Activation of melanocortin 4 receptors reduces the inflammatory response and prevents apoptosis induced by lipopolysaccharide and interferon-gamma in astrocytes. *Endocrinology*, 148(10), 4918–4926.
- Chahl, L.A. (1996) Opioids – mechanisms of action. *Australian Prescriber*, 19, 63–65.
- Chaki, S., Ogawa, S.-I., Toda, Y., Funakoshi, T. & Okuyama, S. (2003) Involvement of the melanocortin MC4 receptor in stress-related behavior in rodents. *European Journal of Pharmacology*, 474(1), 95–101.
- Chaki, S. & Okuyama, S. (2005) Involvement of melanocortin-4 receptor in anxiety and depression. *Peptides*, 26(10), 1952–1964.
- Chen, X., Chen, H., Cai, W., Maguire, M., Ya, B., Zuo, F. et al. (2017a) The melanoma-linked "redhead" *MC1R* influences dopaminergic neuron survival. *Annals of Neurology*, 81(3), 395–406.
- Chen, X., Huang, L., Tan, H.Y., Li, H., Wan, Y., Cowley, M. et al. (2017b) Deficient melanocortin-4 receptor causes abnormal reproductive neuroendocrine profile in female mice. *Reproduction*, 153(3), 267–276.
- Chuang, T.K., Killam, K.F. Jr, Chuang, L.F., Kung, H.F., Sheng, W.S., Chao, C.C. et al. (1995) Mu opioid receptor gene expression in immune

- cells. *Biochemical and Biophysical Research Communications*, 216(3), 922–930.
- Clarke, K.W. & Paton, B.S. (1988) Combined use of detomidine with opiates in the horse. *Equine Veterinary Journal*, 20(5), 331–334.
- Clutton, R.E. (2010) Opioid analgesia in horses. *Veterinary Clinics of North America: Equine Practice*, 26(3), 493–514.
- Coffman, B.L., Rios, G.R., King, C.D. & Tephly, T.R. (1997) Human UGT2B7 catalyzes morphine glucuronidation. *Drug Metabolism and Disposition*, 25(1), 1–4.
- Corbin, L.J., Pope, J., Sanson, J., Antczak, D.F., Miller, D., Sadeghi, R. et al. (2020) An independent locus upstream of ASIP controls variation in the shade of the bay coat colour in horses. *Genes*, 11(6), 606.
- Cragonlini, A.B., Caruso, C., Lasaga, M. & Scimonelli, T.N. (2006) Alpha-MSH and gamma-MSH modulate early release of hypothalamic PGE2 and NO induced by IL-1beta differently. *Neuroscience Letters*, 409(3), 168–172.
- Cruz, F.S.F., Carregaro, A.B., Machado, M. & Antonow, R.R. (2011) Sedative and cardiopulmonary effects of buprenorphine and xylazine in horses. *Canadian Journal of Veterinary Research*, 75(1), 35–41.
- Daverio, M.S., Rigalt, F., Romero, S., Vidal-Rioja, L. & Di Rocco, F. (2016) Polymorphisms in MC1R and ASIP genes and their association with coat color phenotypes in llamas (*Lama glama*). *Small Ruminant Research*, 144, 83–89.
- de Grauw, J. & van Loon, T. (2020) Clinical effects of two doses of butorphanol with detomidine for intravenous premedication of healthy warmblood horses. *Veterinary Anaesthesia and Analgesia*, 47(5), 681–685.
- de Oliveira, F.A., Pignaton, W., Teixeira-Neto, F.J., de Queiroz-Neto, A., Puoli-Filho, J.N.P., Scognamillo, M.V.R. et al. (2014) Antinociceptive and behavioral effects of methadone alone or in combination with detomidine in conscious horses. *Journal of Equine Veterinary Science*, 34(3), 380–386.
- Delaney, A., Keighren, M., Fleetwood-Walker, S.M. & Jackson, I.J. (2010) Involvement of the melanocortin-1 receptor in acute pain and pain of inflammatory but not neuropathic origin. *PLoS One*, 5(9), e12498.
- Ducrest, A.L., Keller, L. & Roulin, A. (2008) Pleiotropy in the melanocortin system, coloration and behavioural syndromes. *Trends in Ecology & Evolution*, 23(9), 502–510.
- Ercil, N.E., Galici, R. & Kesterson, R.A. (2005) HS014, a selective melanocortin-4 (MC4) receptor antagonist, modulates the behavioral effects of morphine in mice. *Psychopharmacology (Berl.)*, 180(2), 279–285.
- Fan, W., Boston, B.A., Kesterson, R.A., Hruby, V.J. & Cone, R.D. (1997) Role of melanocortinergic neurons in feeding and the agouti obesity syndrome. *Nature*, 385(6612), 165–168.
- Fan, W., Dinulescu, D.M., Butler, A.A., Zhou, J., Marks, D.L. & Cone, R.D. (2000) The central melanocortin system can directly regulate serum insulin levels. *Endocrinology*, 141(9), 3072–3079.
- Fan, W., Ellacott, K.L., Halatchev, I.G., Takahashi, K., Yu, P. & Cone, R.D. (2004) Cholecystinin-mediated suppression of feeding involves the brainstem melanocortin system. *Nature Neuroscience*, 7(4), 335–336.
- Finn, J.L., Haase, B., Willet, C.E., van Rooy, D., Chew, T., Wade, C.M. et al. (2016) The relationship between coat colour phenotype and equine behaviour: A pilot study. *Applied Animal Behaviour Science*, 174, 66–69.
- Flecknell, P.A., Liles, J.H. & Wootton, R. (1989) Reversal of fentanyl/fluanisone neuroleptanalgesia in the rabbit using mixed agonist/antagonist opioids. *Laboratory Animals*, 23(2), 147–155.
- Fontanesi, L., Buttazzoni, L., Galimberti, G., Calò, D.G., Scotti, E. & Russo, V. (2013) Association between melanocortin 4 receptor (MC4R) gene haplotypes and carcass and production traits in Italian Large White pigs evaluated with a selective genotyping approach. *Livestock Science*, 157(1), 48–56.
- Galaj, E., Han, X., Shen, H., Jordan, C.J., He, Y., Humburg, B. et al. (2020) Dissecting the role of GABA neurons in the VTA versus SNr in opioid reward. *Journal of Neuroscience*, 40(46), 8853–8869.
- Gavériaux, C., Peluso, J., Simonin, F., Laforet, J. & Kieffer, B. (1995) Identification of  $\kappa$ - and  $\delta$ -opioid receptor transcripts in immune cells. *FEBS Letters*, 369(2), 272–276.
- Gozalo-Marcilla, M., Luna, S.P.L., Gasthuys, F., Pollaris, E., Vlamincx, L., Martens, A. et al. (2019) Clinical applicability of detomidine and methadone constant rate infusions for surgery in standing horses. *Veterinary Anaesthesia and Analgesia*, 46(3), 325–334.
- Guedes, A. (2017) Pain management in horses. *Veterinary Clinics of North America: Equine Practice*, 33(1), 181–211.
- Guida, S., Guida, G. & Goding, C.R. (2021) MC1R functions, expression, and implications for targeted therapy. *The Journal of Investigative Dermatology*, 142, 293–302.
- Gutstein, H.B., Mansour, A., Watson, S.J., Akil, H. & Fields, H.L. (1998) Mu and kappa opioid receptors in periaqueductal gray and rostral ventromedial medulla. *NeuroReport*, 9(8), 1777–1781.
- Hamamoto-Hardman, B.D., Baden, R.W., McKemie, D.S. & Knych, H.K. (2020) Equine uridine diphospho-glucuronosyltransferase 1A1, 2A1, 2B4, 2B31: cDNA cloning, expression and initial characterization of morphine metabolism. *Veterinary Anaesthesia and Analgesia*, 47(6), 763–772.
- Hamamoto-Hardman, B.D., Steffey, E.P., Weiner, D., McKemie, D.S., Kass, P. & Knych, H.K. (2019) Pharmacokinetics and selected pharmacodynamics of morphine and its active metabolites in horses after intravenous administration of four doses. *Journal of Veterinary Pharmacology and Therapeutics*, 42(4), 401–410.
- Haw, A.J., Meyer, L.C.R. & Fuller, A. (2016) Nalbuphine and butorphanol reverse opioid-induced respiratory depression but increase arousal in etorphine-immobilized goats (*Capra hircus*). *Veterinary Anaesthesia and Analgesia*, 43(5), 539–548.
- Hector, R.C. & Mama, K.R. (2018) Chapter 3 - Recognizing and Treating Pain in Horses. In: Reed, S.M., Bayly, W.M. & Sellon, D.C. (Eds.) *Equine Internal Medicine*. 4th edn. Philadelphia: W.B. Saunders. pp. 138–157.
- Hellyer, P.W., Bai, L., Supon, J., Quail, C., Wagner, A.E., Mama, K.R. et al. (2003) Comparison of opioid and alpha-2 adrenergic receptor binding in horse and dog brain using radioligand autoradiography. *Veterinary Anaesthesia and Analgesia*, 30(3), 172–182.
- Huang, P., Yang, X.-D., Chen, S.-D. & Xiao, Q. (2015) The association between Parkinson's disease and melanoma: a systematic review and meta-analysis. *Translational Neurodegeneration*, 4(1), 21.
- Huszar, D., Lynch, C.A., Fairchild-Huntress, V., Dunmore, J.H., Fang, Q., Berkemeier, L.R. et al. (1997) Targeted disruption of the melanocortin-4 receptor results in obesity in mice. *Cell*, 88(1), 131–141.
- Irani, B.G., Xiang, Z., Moore, M.C., Mandel, R.J. & Haskell-Luevano, C. (2005) Voluntary exercise delays monogenic obesity and overcomes reproductive dysfunction of the melanocortin-4 receptor knockout mouse. *Biochemical and Biophysical Research Communications*, 326(3), 638–644.
- Jacobs, L.N., Staiger, E.A., Albright, J.D. & Brooks, S.A. (2016) The MC1R and ASIP coat color loci may impact behavior in the horse. *Journal of Heredity*, 107(3), 214–219.
- Kalpravidh, M., Lumb, W.V., Wright, M. & Heath, R.B. (1984) Effects of butorphanol, flunixin, levorphanol, morphine, and xylazine in ponies. *American Journal of Veterinary Research*, 45(2), 217–223.
- Kamerling, S.G., DeQuick, D.J., Weckman, T.J. & Tobin, T. (1985) Dose-related effects of fentanyl on autonomic and behavioral responses in performance horses. *General Pharmacology: the Vascular System*, 16(3), 253–258.
- Kim, H., Clark, D. & Dionne, R.A. (2009) Genetic contributions to clinical pain and analgesia: avoiding pitfalls in genetic research. *The Journal of Pain*, 10(7), 663–693.
- Klepstad, P., Fladvad, T., Skorpen, F., Bjordal, K., Caraceni, A., Dale, O. et al. (2011) Influence from genetic variability on opioid use for



- cancer pain: A European genetic association study of 2294 cancer pain patients. *Pain*, 152(5), 1139–1145.
- Knych, H.K., Baden, R.W., Gretler, S.R. & McKemie, D.S. (2019) Characterization of the in vitro CYP450 mediated metabolism of the polymorphic CYP2D6 probe drug codeine in horses. *Biochemical Pharmacology*, 168, 184–192.
- Knych, H.K., Steffey, E.P. & McKemie, D.S. (2014) Preliminary pharmacokinetics of morphine and its major metabolites following intravenous administration of four doses to horses. *Journal of Veterinary Pharmacology and Therapeutics*, 37(4), 374–381.
- Knych, H.K., Steffey, E.P., Casbeer, H.C. & Mitchell, M.M. (2015) Disposition, behavioural and physiological effects of escalating doses of intravenously administered fentanyl to young foals. *Equine Veterinary Journal*, 47(5), 592–598.
- Kumar, K.G., Sutton, G.M., Dong, J.Z., Roubert, P., Plas, P., Halem, H.A. et al. (2009) Analysis of the therapeutic functions of novel melanocortin receptor agonists in MC3R- and MC4R-deficient C57BL/6J mice. *Peptides*, 30(10), 1892–1900.
- Labroo, R.B., Paine, M.F., Thummel, K.E. & Kharasch, E.D. (1997) Fentanyl metabolism by human hepatic and intestinal cytochrome P450 3A4: Implications for interindividual variability in disposition, efficacy, and drug interactions. *Drug Metabolism and Disposition*, 25(9), 1072.
- Lau, B.K. & Vaughan, C.W. (2014) Descending modulation of pain: the GABA disinhibition hypothesis of analgesia. *Current Opinion in Neurobiology*, 29, 159–164.
- Lau, B.K., Winters, B.L. & Vaughan, C.W. (2020) Opioid presynaptic disinhibition of the midbrain periaqueductal grey descending analgesic pathway. *British Journal of Pharmacology*, 177(10), 2320–2332.
- Li, D. & Taylor, A.W. (2008) Diminishment of alpha-MSH anti-inflammatory activity in MC1r siRNA-transfected RAW264.7 macrophages. *Journal of Leukocyte Biology*, 84(1), 191–198.
- Liem, E.B., Joiner, T.V., Tsueda, K. & Sessler, D.I. (2005) Increased sensitivity to thermal pain and reduced subcutaneous lidocaine efficacy in redheads. *Anesthesiology*, 102(3), 509–514.
- Lopes, C., Luna, S.P.L., Rosa, A.C., Quarterone, C., Crosignani, N., Taylor, P.M. et al. (2016) Antinociceptive effects of methadone combined with detomidine or acepromazine in horses. *Equine Veterinary Journal*, 48(5), 613–618.
- Lu, D., Willard, D., Patel, I.R., Kadwell, S., Overton, L., Kost, T. et al. (1994) Agouti protein is an antagonist of the melanocyte-stimulating-hormone receptor. *Nature*, 371(6500), 799–802.
- Lu, X.-Y., Barsh, G.S., Akil, H. & Watson, S.J. (2003) Interaction between  $\alpha$ -melanocyte-stimulating hormone and corticotropin-releasing hormone in the regulation of feeding and hypothalamo-pituitary-adrenal responses. *The Journal of Neuroscience*, 23(21), 7863–7872.
- Machelska, H. & Celik, M.Ö. (2020) Immune cell-mediated opioid analgesia. *Immunology Letters*, 227, 48–59.
- Mama, K.R. & Hector, R.C. (2019) Therapeutic developments in equine pain management. *The Veterinary Journal*, 247, 50–56.
- Mansour, M., White, D., Wernette, C., Dennis, J., Tao, Y.X., Collins, R. et al. (2010) Pancreatic neuronal melanocortin-4 receptor modulates serum insulin levels independent of leptin receptor. *Endocrine*, 37(1), 220–230.
- Marklund, L., Moller, M.J., Sandberg, K. & Andersson, L. (1996) A missense mutation in the gene for melanocyte-stimulating hormone receptor (MC1R) is associated with the chestnut coat color in horses. *Mammalian Genome*, 7(12), 895–899.
- Martins, F.C., Keating, S.C., Clark-Price, S.C., Schaeffer, D.J., Lascola, K.M. & DiMaio Knych, H. (2020) Pharmacokinetics and pharmacodynamics of hydromorphone hydrochloride in healthy horses. *Veterinary Anaesthesia and Analgesia*, 47(4), 509–517.
- Matthews, N.S. & Carroll, G.L. (2007) Review of equine analgesics and pain management. *Proceedings of the American Association of Equine Practitioners*, 53, 241.
- Mitra, D., Luo, X., Morgan, A., Wang, J., Hoang, M.P., Lo, J. et al. (2012) An ultraviolet-radiation-independent pathway to melanoma carcinogenesis in the red hair/fair skin background. *Nature*, 491(7424), 449–453.
- Mogil, J.S., Ritchie, J., Smith, S.B., Strasburg, K., Kaplan, L., Wallace, M.R. et al. (2005) Melanocortin-1 receptor gene variants affect pain and mu-opioid analgesia in mice and humans. *Journal of Medical Genetics*, 42(7), 583–587.
- Mountjoy, K.G., Robbins, L.S., Mortrud, M.T. & Cone, R.D. (1992) The cloning of a family of genes that encode the melanocortin receptors. *Science*, 257(5074), 1248–1251.
- Muir, W.W. & Robertson, J.T. (1985) Visceral analgesia: Effects of xylazine, butorphanol, meperidine, and pentazocine in horses. *American Journal of Veterinary Research*, 46(10), 2081–2084.
- Murray, A. & Hagen, N.A. (2005) Hydromorphone. *Journal of Pain and Symptom Management*, 29(5), 57–66.
- Neves, A.P., Schwengber, E.B., Albrecht, F.F., Isola, J.V. & Linden, L.D.S.V.D. (2017) *Beyond Fifty Shades: The Genetics of Horse Colors*. *Trends and Advances in Veterinary Genetics*. M. Abubakar, IntechOpen.
- Ohta, M., Wakuno, A., Okada, J., Kodaira, K., Nagata, S.I., Ito, M. et al. (2010) Effects of intravenous fentanyl administration on end-tidal sevoflurane concentrations in thoroughbred racehorses undergoing orthopedic surgery. *Journal of Veterinary Medical Science*, 72(9), 1107–1111.
- Olsen, J.H., Friis, S. & Frederiksen, K. (2006) Malignant melanoma and other types of cancer preceding Parkinson disease. *Epidemiology*, 17(5), 582–587.
- Pignaton, W., Luna, S.P.L., Teixeira Neto, F.J., Oliveira, F.A.D., Castro Neto, E.F.D., Graça Naffah-Mazzacoratti, M.D. et al. (2016) Methadone increases and prolongs detomidine-induced arterial hypertension in horses, but these effects are not mediated by increased plasma concentrations of arginine vasopressin or serum concentrations of catecholamines. *Journal of Equine Veterinary Science*, 37, 39–45.
- Pippi, N.L. & Lumb, W.V. (1979) Objective tests of analgesic drugs in ponies. *American Journal of Veterinary Research*, 40(8), 1082–1086.
- Price, J., Marques, J.M., Welsh, E.M. & Waran, N.K. (2002) Pilot epidemiological study of attitudes towards pain in horses. *The Veterinary Record*, 151(19), 570–575.
- Queiroz-Neto, A., Zamur, G., Mataqueiro, M.I., D'Angelis, F.H.F., Araújo, R.A., Silva, M.H.M. et al. (2013) Behavioral and antinociceptive effects of alfentanil, butorphanol, and flunixin in horses. *Journal of Equine Veterinary Science*, 33(12), 1095–1100.
- Reed, R., Barletta, M., Mitchell, K., Hanafi, A., Bullington, A., Knych, H. et al. (2019) The pharmacokinetics and pharmacodynamics of intravenous hydromorphone in horses. *Veterinary Anaesthesia and Analgesia*, 46(3), 395–404.
- Reed, R.A., Knych, H.K., Barletta, M., Sakai, D.M., Ruch, M.M., Smyth, C.A. et al. (2020) Pharmacokinetics and pharmacodynamics of hydromorphone after intravenous and intramuscular administration in horses. *Veterinary Anaesthesia and Analgesia*, 47(2), 210–218.
- Rieder, S., Taourit, S., Mariat, D., Langlois, B. & Guérin, G. (2001) Mutations in the agouti (ASIP), the extension (MC1R), and the brown (TYRP1) loci and their association to coat color phenotypes in horses (*Equus caballus*). *Mammalian Genome*, 12(6), 450–455.
- Robertson, J.T., Muir, W.W., & Sams, R. (1981) Cardiopulmonary effects of butorphanol tartrate in horses. *American Journal of Veterinary Research*, 42(1), 41–44.
- Robertson, S. & Sanchez, L. (2014) *Clinical application of equine analgesics*. 63–75.
- Rowland, S. & Dupre, J.L. (2014) Analgesia in equine practice. In: Goldberg, M.E. & Shaffran, N. (Eds). *Pain Management for Veterinary Technicians and Nurses*. 1st edn, John Wiley & Sons Inc., New Jersey. pp. 157–184.

- Samama, P., Rumennik, L. & Grippo, J.F. (2003) The melanocortin receptor MCR4 controls fat consumption. *Regulatory Peptides*, 113(1-3), 85-88.
- Sanchez, L.C., Robertson, S.A., Maxwell, L.K., Zientek, K. & Cole, C. (2007) Effect of fentanyl on visceral and somatic nociception in conscious horses. *Journal of Veterinary Internal Medicine*, 21(5), 1067-1075.
- Sandbaumhuter, F.A., Vimercati, S., Thormann, W. & Mevissen, M. (2018) Role of the equine CYP3A94, CYP3A95 and CYP3A97 in ketamine metabolism in presence of medetomidine, diazepam and methadone studied by enantioselective capillary electrophoresis. *Toxicology in Vitro*, 50, 242-248.
- Sandrock, M., Schulz, A., Merkwitz, C., Schoneberg, T., Spänzel-Borowski, K. & Ricken, A. (2009) Reduction in corpora lutea number in obese melanocortin-4-receptor-deficient mice. *Reproductive Biology and Endocrinology*, 7, 24.
- Sartin, J.L., Marks, D.L., McMahon, C.D., Daniel, J.A., Levasseur, P., Wagner, C.G. et al. (2008) Central role of the melanocortin-4 receptors in appetite regulation after endotoxin. *Journal of Animal Science*, 86(10), 2557-2567.
- Schnellbacher, R. (2010) Butorphanol. *Journal of Exotic Pet Medicine*, 19(2), 192-195.
- Sellon, D.C., Roberts, M.C., Blikslager, A.T., Ulibarri, C. & Papich, M.G. (2004) Effects of continuous rate intravenous infusion of butorphanol on physiologic and outcome variables in horses after celiotomy. *Journal of Veterinary Internal Medicine*, 18(4), 555-563.
- Siple, J.F., Schneider, D.C., Wanlass, W.A. & Rosenblatt, B.K. (2000) Levodopa therapy and the risk of malignant melanoma. *Annals of Pharmacotherapy*, 34(3), 382-385.
- Smith, H.S. (2009) Opioid metabolism. *Mayo Clinic Proceedings*, 84(7), 613-624.
- Soars, M.G., Fettes, M., O'Sullivan, A.C., Riley, R.J., Ethell, B.T. & Burchell, B. (2003) Cloning and characterisation of the first drug-metabolising canine UDP-glucuronosyltransferase of the 2B sub-family. *Biochemical Pharmacology*, 65(8), 1251-1259.
- Sponenberg, D.P. & Bellone, R. (2017) *Equine Color Genetics*. Newark, USA: John Wiley & Sons, Incorporated.
- Stamer, U.M., Zhang, L. & Stüber, F. (2008) Impact of genetic variants on pain and analgesia. *European Journal of Pain Supplements*, 2(1), 18-24.
- Stanley, T.H. (2014) The fentanyl story. *The Journal of Pain*, 15(12), 1215-1226.
- Swope, V.B., Jameson, J.A., McFarland, K.L., Supp, D.M., Miller, W.E., McGraw, D.W. et al. (2012) Defining MC1R regulation in human melanocytes by its agonist  $\alpha$ -melanocortin and antagonists agouti signaling protein and  $\beta$ -defensin 3. *Journal of Investigative Dermatology*, 132(9), 2255-2262.
- Tell-Marti, G., Puig-Butillé, J.A. & Puig, S. (2020) Chapter 12 - Melanocortin 1 receptor: Parkinson's disease, melanoma risk, and neuroprotection. In: Martin, C.R. & Preedy, V.R. (Eds.), *Genetics, Neurology, Behavior, and Diet in Parkinson's Disease*. Academic Press, London. pp. 189-203.
- Thomasy, S.M., Moeller, B.C. & Stanley, S.D. (2007) Comparison of opioid receptor binding in horse, guinea pig, and rat cerebral cortex and cerebellum. *Veterinary Anaesthesia and Analgesia*, 34(5), 351-358.
- Van der Ploeg, L.H., Martin, W.J., Howard, A.D., Nargund, R.P., Austin, C.P., Guan, X. et al. (2002) A role for the melanocortin 4 receptor in sexual function. *Proceedings of the National Academy of Sciences of the United States of America*, 99(17), 11381-11386.
- Vergoni, A.V., Bertolini, A., Wikberg, J.E.S. & Schiöth, H.B. (1999) Selective melanocortin MC4 receptor blockage reduces immobilization stress-induced anorexia in rats. *European Journal of Pharmacology*, 369(1), 11-15.
- Volpe, D.A., Xu, Y., Sahajwalla, C.G., Younis, I.R. & Patel, V. (2018) Methadone metabolism and drug-drug interactions. In vitro and in vivo literature review. *Journal of Pharmaceutical Sciences*, 107(12), 2983-2991.
- Von Frijtag, J.C., Croiset, G., Hendrik Gispén, W., Adan, R.A.H. & Wiegant, V.M. (1998) The role of central melanocortin receptors in the activation of the hypothalamus-pituitary-adrenal-axis and the induction of excessive grooming. *British Journal of Pharmacology*, 123(8), 1503-1508.
- Vrinten, D.H., Gispén, W.H., Groen, G.J. & Adan, R.A. (2000) Antagonism of the melanocortin system reduces cold and mechanical allodynia in mononeuropathic rats. *Journal of Neuroscience*, 20(21), 8131-8137.
- Wagner, A.E., Muir, W.W. & Hinchcliff, K.W. (1991) Cardiovascular effects of xylazine and detomidine in horses. *American Journal of Veterinary Research*, 52(5), 651-657.
- Wagner, C.G., McMahon, C.D., Marks, D.L., Daniel, J.A., Steele, B. & Sartin, J.L. (2004) A role for agouti-related protein in appetite regulation in a species with continuous nutrient delivery. *Neuroendocrinology*, 80(4), 210-218.
- Wagner, E. & Tyler, P. (2011) A comparison of weight estimation methods in adult horses. *Journal of Equine Veterinary Science*, 31(12), 706-710.
- Wagner, H.-J. & Reissmann, M. (2000) New polymorphism detected in the horse MC1R gene. *Animal Genetics*, 31(4), 289-290.
- Wetmore, L.A., Pascoe, P.J., Shilo-Benjamini, Y. & Lindsey, J.C. (2016) Effects of fentanyl administration on locomotor response in horses with the G57C mu-opioid receptor polymorphism. *American Journal of Veterinary Research*, 77(8), 828-832.
- Wikberg, J.E. (1999) Melanocortin receptors: perspectives for novel drugs. *European Journal of Pharmacology*, 375(1-3), 295-310.
- Wilson, M.G., Nicholson, W.E., Holscher, M.A., Sherrell, B.J., Mount, C.D. & Orth, D.N. (1982) Proopiomelanocortin peptides in normal pituitary, pituitary tumor, and plasma of normal and Cushing's horses. *Endocrinology*, 110(3), 941-954.
- Wright, A.W., Mather, L.E. & Smith, M.T. (2001) Hydromorphone-3-glucuronide: a more potent neuro-excitant than its structural analogue, morphine-3-glucuronide. *Life Sciences*, 69(4), 409-420.
- Wright, A.W., Nocente, M.L. & Smith, M.T. (1998) Hydromorphone-3-glucuronide: biochemical synthesis and preliminary pharmacological evaluation. *Life Sciences*, 63(5), 401-411.
- Xia, Y., Wikberg, J.E. & Chhajlani, V. (1995) Expression of melanocortin 1 receptor in periaqueductal gray matter. *NeuroReport*, 6(16), 2193-2196.
- Yiannakopoulou, E. (2015) Pharmacogenomics and opioid analgesics: Clinical implications. *International Journal of Genomics*, 2015, 368979.
- Zhao, R.Y., Zhao, Y.P., Li, B., Bou, G., Zhang, X.Z., Mongke, T. et al. (2018) Overview of the genetic control of horse coat color patterns. *Yi Chuan*, 40(5), 357-368.

**How to cite this article:** Bacon, E.K., Donnelly, C.G., Bellone, R.R., Finno, C.J. & Velie, B.D. (2023) Melanocortin-1 receptor influence in equine opioid sensitivity. *Equine Veterinary Education*, 35, 152-162. Available from: <https://doi.org/10.1111/eve.13661>



## There's nothing else like it.

For more than 30 years, Adequan® i.m. [polysulfated glycosaminoglycan] has been administered millions of times<sup>1</sup> to treat degenerative joint disease, and with good reason. From day one, it's been the only FDA-Approved equine PSGAG joint treatment available, and the only one proven to.<sup>2,3</sup>

**Reduce** inflammation  
**Restore** synovial joint lubrication  
**Repair** joint cartilage  
**Reverse** the disease process

When you start with it early and stay with it as needed, horses may enjoy greater mobility over a lifetime.<sup>2,4,5</sup> Discover if Adequan is the right choice. Visit [adequan.com/Ordering-Information](https://www.adequan.com/Ordering-Information) to find a distributor and place an order today.

**BRIEF SUMMARY:** Prior to use please consult the product insert, a summary of which follows: **CAUTION:** Federal law restricts this drug to use by or on the order of a licensed veterinarian. **INDICATIONS:** Adequan® i.m. is recommended for the intramuscular treatment of non-infectious degenerative and/or traumatic joint dysfunction and associated lameness of the carpal and hock joints in horses. **CONTRAINDICATIONS:** There are no known contraindications to the use of intramuscular Polysulfated Glycosaminoglycan. **WARNINGS:** Do not use in horses intended for human consumption. Not for use in humans. Keep this and all medications out of the reach of children. **PRECAUTIONS:** The safe use of Adequan® i.m. in horses used for breeding purposes, during pregnancy, or in lactating mares has not been evaluated. For customer care, or to obtain product information, visit [www.adequan.com](https://www.adequan.com). To report an adverse event please contact American Regent, Inc. at 1-888-354-4857 or email [pv@americanregent.com](mailto:pv@americanregent.com).

Please see Full Prescribing Information at [www.adequan.com](https://www.adequan.com).

Start with it. Stay with it.®

 **Adequan i.m.®**  
polysulfated glycosaminoglycan  
[www.adequan.com](https://www.adequan.com)

1 Data on file.

2 Adequan® i.m. Package Insert, Rev 1/19.

3 Burba DJ, Collier MA, DeBault LE, Hanson-Pointon O, Thompson HC, Holder CL: In vivo kinetic study on uptake and distribution of intramuscular tritium-labeled polysulfated glycosaminoglycan in equine body fluid compartments and articular cartilage in an osteochondral defect model. *J Equine Vet Sci* 1993; 13: 696-703.

4 Kim DY, Taylor HW, Moore RM, Paulsen DB, Cho DY. Articular chondrocyte apoptosis in equine osteoarthritis. *The Veterinary Journal* 2003; 166: 52-57.

5 McIlwraith CW, Frisbie DD, Kawcak CE, van Weeren PR. *Joint Disease in the Horse*. St. Louis, MO: Elsevier, 2016; 33-48.



EDUCATIONAL  
PARTNER



Free equine nutrition  
toolkit, now available  
for AAEP members.



Request your free personalized toolkit  
at **VetNutritionInfo.com**

The create-your-own toolkit includes:

- Clinical disorders booklet
- Weight tapes
- Body condition scoring and topline evaluation handouts
- Vet solution cards for the most common conditions
- Guide to rehabilitating the neglected horse

There's a lot that rides on a horse's nutrition, and we want to help our members stay informed and connected to trusted equine resources. The research and innovation team at Cargill, one of AAEP's partners, developed a nutrition toolkit to help veterinarians develop effective feed as well as diagnose and prescribe treatments for horses.



**Your Educational Partners in Equine Nutrition**

Cargill has dedicated more than three generations of research and discovery to help build a stronger foundation for equine health and performance through greater understanding and innovation in the field of nutrition. We're proud to partner with AAEP and share our resources and knowledge with you.

# What is the most effective treatment in horses with chorioptic mange?

Jevgenija Kondratjeva<sup>1</sup> | Daniel Combarros<sup>1,2</sup> | Charline Pressanti<sup>1</sup> |  
Marie Christine Cadiergues<sup>1,2</sup> 

<sup>1</sup>Small Animal Clinic, Université de Toulouse, ENVT, Toulouse

<sup>2</sup>INFINITY, Inserm, CNRS, UPS, Université de Toulouse, Toulouse, France

## Correspondence

Marie Christine Cadiergues  
Email: marie-christine.cadiergues@envt.fr

## Summary

Chorioptic mange is a common pruritic skin disease in horses and can cause chronic pastern dermatitis. Many to all horses in one stable can suffer simultaneously and transmit the disease to one another through contact or by using the same areas. Treatment often is challenging, and failure and relapses are common. This paper reviews the evidence comparing different types of treatment of chorioptic mange in horses and found that although some protocols are partially effective, further comparisons are required.

## KEYWORDS

horse, chorioptic mange, parasite, skin, treatment

## BACKGROUND

Chorioptic mange is a common pruritic equine skin disease caused by *Chorioptes bovis*. Horses with feathered fetlocks, such as draught breeds, are predisposed (Cremers, 1985) and epidermal material from pasterns can allow external survival of mites as demonstrated from pasterns of cob and draught breeds (Sweatman, 1957). The disease mostly affects distal limbs, causing erythema, alopecia, scaling, crusts and lichenification. Pruritus is variable; some animals with large numbers of mites can be non-pruritic (Mullen & O'Connor, 2018; Taylor et al., 2016). Chorioptic mange may be involved in – or be the only cause of – chronic pastern dermatitis (Yu, 2013). A generalised form, tail and perianal fold pruritus, has also been described (Scott & Miller, 2011). Clinical signs are more severe in winter as mite activity increases when temperatures drop, and horses are more frequently stabled (Mullen & O'Connor, 2018). Diagnosis is based on clinical signs and positive superficial skin scrapings and/or by trapping mites on adhesive tape (Bergvall, 2005).

In many countries, no licenced product is available to treat equine chorioptic mange. The lack of clinical studies that could lead to a licence in the 'chorioptic mange' indication in the equine species may result from several factors. The cost-benefit analysis for a manufacturer is not necessarily favourable and clinical studies are difficult to set up. In addition, guidelines from the registration authorities are

lacking, unlike what is observed in cattle (Committee for Medicinal Products for Veterinary Use, 2021a) or in sheep (Committee for Medicinal Products for Veterinary Use, 2021b). Treatment often is challenging and failure and relapses are common. They may be a result of the inadequacy of initial treatment (e.g. single treatments failing to address all life-cycle stages, failure to clip feathers to ensure adequate topical therapy) or due to reinfestation secondary to the failure to treat in-contacts and the environment (Taylor et al., 2016). The purpose of this study is to use the available evidence to determine the most effective treatment(s) for chorioptic mange.

## CLINICAL SCENARIO

The patient is a 10-year-old draught horse with chronic pruritus of the distal limbs, particularly of the fetlocks and pasterns, expressed by chewing and stamping. On dermatologic examination, crusted and ulcerated lesions, erythema and alopecic plaques are observed. The horse is in contact with other horses without feathered fetlocks and takes part in shows. The other animals show no clinical signs. Microscopical examination of skin scrapes reveals *Chorioptes* spp. mites. Chorioptic mange is diagnosed; the question is which therapeutic protocol will result in clinical and parasitological cure of the horse.

## REFINING THE QUESTION

A population, intervention, comparison, outcome (PICO) question was formulated: 'In horses with chorioptic mange, which treatment is the most effective'?

P (population)=horse with chorioptic mange.

I (intervention)=treatment.

C (comparison)=different types.

O (outcome)=clinical and parasitic resolution.

Preferred study type=clinical trials.

## SEARCH STRATEGY

For different types of treatment, PubMed, CAB and Scopus were searched on 15 September 2021 with the following criteria: ((equine OR horse OR equids) AND (chorioptes OR chorioptic mange OR chorioptes equi OR chorioptes bovis) AND (treatment)).

## QUANTITY OF EVIDENCE

The search yielded 14 results published between 1973 and 2019. Papers in a language other than English were excluded. Other papers were screened for such criteria as relevance to the PICO question and multi-animal inclusion, and six clinical trials were selected, of which one was double-blinded and placebo-controlled, two were controlled, two were comparative and one was a pilot trial.

## QUALITY OF THE EVIDENCE

All the papers were published in three peer-reviewed international journals. Table 1 summarises the journal, the number of subjects and the type of each study.

The quality of evidence in the selected papers varied mostly because of the small to medium number of subjects and the design of the study; however, they were considered to be of acceptable quality to contribute to the conclusions of PICO.

## RESULTS/CONCLUSION OF EVIDENCE

Key results are summarised in Table 2.

Parasitic cure was reported in three studies using three different protocols: (i) application of 1% selenium sulphide shampoo for 10 minutes on three occasions and treatment of the environment together with changing the bedding (Curtis, 1999); (ii) moxidectin oral gel administered once, or ivermectin 2 mg/kg administered twice, plus two treatments of the environment with deltamethrin 2 weeks apart (Rufenacht et al., 2011); (iii) four applications of lime sulphur at 7-day intervals, with or without hair clipping with no treatment of the environment (Paterson & Coumbe, 2009). The lesions and pruritus were successfully healed only in the study in which moxidectin or ivermectin was administered orally (Osman et al., 2006). Moxidectin at the same dose but given twice, 3 weeks apart, with a different treatment of the environment, failed to achieve either parasitological or clinical cure of the animals (Rufenacht et al., 2011). The authors suspected the difference in climate between Western Europe and Egypt, where the first study was conducted, and different environmental treatments (Rufenacht et al., 2011) were responsible for the different outcomes. Furthermore, the type and breed of horses selected by Osman et al. (2006) are not precisely described, whereas it is known to be a crucial factor that predisposes horses to chorioptic mange. In one study, ivermectin administered orally was successfully combined with treatment of the environment with deltamethrin (Osman et al., 2006) but, in the second study in which the environment was not treated, the same treatment significantly reduced the number of mites but did not provide a parasitological cure (Littlewood et al., 1995).

Both Paterson and Coumbe (2009), and Curtis (1999) obtained a parasitological cure and a marked improvement in lesions using different shampoos under different protocols. In particular, in an open study, selenium sulphide shampoo was used on seven horses combined with a broad-spectrum disinfectant applied to the environment (Curtis, 1999). The application of lime sulphur was preceded by either benzoyl peroxide or by acetic acid/boric acid shampoo (Paterson & Coumbe, 2009). It is possible that mechanical cleaning during shampooing also plays a role. The treatment was successful in both studies, despite the fact that several horses did not have the hair on their limbs clipped (Curtis, 1999; Paterson & Coumbe, 2009).

**TABLE 1** Summary of the quality of evidence

Paper	Journal	Number of subjects	Type of study
Littlewood et al (1995)	Veterinary Record	24	Prospective single-blind controlled study
Curtis (1999)	Veterinary Record	7	Prospective open uncontrolled study
Osman et al. (2006)	Veterinary Parasitology	14	Prospective open comparative controlled study
Rendle et al. (2007)	Veterinary Record	17	Prospective randomised comparative clinical study
Paterson & Coumbe (2009)	Veterinary Dermatology	22	Prospective open clinical study
Rufenacht et al. (2011)	Veterinary Dermatology	19	Prospective, double-blind, placebo-controlled study



TABLE 2 Analysis of relevant papers

Reference/tested medication	Patients	Study design	Outcome, key results†	Study weakness
Littlewood et al. (1995) Oral ivermectin	24 horses (17 shires, 4 draught crosses, 3 cobs, all with feathering of the lower limbs).	Diagnosis: skin scrapes ± acetate tape impressions. Oral ivermectin paste: • 0.1 mg/kg 7 days (5) • 0.1 mg/kg 10 days (8) • 0.2 mg/kg twice 2 weeks apart (7) • Untreated (5)	No statistically significant differences were observed between any of the three treatment groups. Statistically significant reduction in the number of mites on the treated horses compared with the control group. % efficacy of oral ivermectin paste: • 0.1 mg/kg 7 days: 96.5% • 0.1 mg/kg 10 days: 95% • 0.2 mg/kg twice 2 weeks apart: 97.5% None of the treatments eliminated mites from all the treated horses.	Small to medium number of animals in each group. No treatment of the environment. No isolation of animals.
Curtis (1999) 1% selenium sulphide shampoo	7 horses (1 shire, 6 cobs, all with feathering of the lower limbs) unresponsive to prior treatments (+20 asymptomatic equids).	Diagnosis: skin scrapes. D0, D5, D10 1% selenium sulphide shampoo left on for 10 minutes. Clipping only in two horses. Treatment of the environment: broad-spectrum disinfectant (Virkon E) and change of bedding.	Parasitological cure on D11, no outbreak for 15 months; % efficacy = 100%. Major improvement of skin lesions and pruritus.	Small number of animals. Uncontrolled study. No isolation of animals.
Osman et al. (2006) Moxidectin vs. ivermectin	14 draught horses, including extensive form.	Diagnosis: skin scrapes. • Moxidectin 2% oral gel 0.4 mg/kg applied once (5) • Ivermectin 0.2 mg/kg administered orally twice 2 weeks apart (5) • Untreated (4) Treatment of the environment: deltamethrin (Butox® 50 %) twice, 2 weeks apart.	Parasitological and clinical cure of all horses in treated groups on D14; no further outbreak until D56. % efficacy = 100% in both groups	Small number of animals. No data provided on feathering of lower limbs. No description of stabling. Product applied in the environment designed to treat animals.
Rendle et al. (2007) Doramectin vs. fipronil	17 cases in 13 equids stabled individually, but that shared riding areas.	Diagnosis: acetate tape impressions. • Doramectin 0.3 mg/kg sc twice 2 weeks apart (8) • Fipronil 0.25% D0 locally on the legs (9).	None of the treatments eliminated mites from all the horses. % efficacy = 88.8% in both groups. No statistically significant differences were observed between the two groups. Statistically significant reduction in the original number of mites in both groups. Complete resolution of behavioural signs by D28.	Medium number of animals in each group. No data provided on feathering of lower limbs. No environmental treatment.

(Continues)

TABLE 2 (Continued)

Reference/tested medication	Patients	Study design	Outcome, key results†	Study weakness
Paterson & Coumbe (2009) 5% lime sulphur	22 horses stabled individually, shared riding areas, unresponsive to prior treatments.	<p>Diagnosis: skin scrapes and acetate tape impressions.</p> <ul style="list-style-type: none"> <li>Clipped legs, benzoyl peroxide shampoo and application of lime sulphur, 4 treatments at 7-day intervals (10)</li> <li>No clipping, no shampoo, only lime sulphur application, 4 treatments at 7-day intervals (7)</li> <li>No clipping, acetic acid/boric acid shampoo, lime sulphur, 4 treatments at 7-day intervals (5)</li> </ul>	<p>Parasitological cure on D28; % efficacy = 100% in all 3 groups</p> <p>Major improvement of skin lesions and pruritus.</p>	<p>Small to medium number of animals.</p> <p>Uncontrolled study.</p> <p>No data provided on feathering of lower limbs.</p> <p>No treatment of the environment.</p>
Rufenacht et al. (2011) Moxidectin + treatment of the environment	19 draught horses with heavily feathered limbs stabled individually.	<p>Diagnosis: skin scrapes.</p> <ul style="list-style-type: none"> <li>Untreated (8)</li> <li>Two doses of moxidectin 0.4 mg/kg administered orally 3 weeks apart (11)</li> </ul> <p>Treatment of the environment:</p> <ul style="list-style-type: none"> <li>D0: 3% solution of phenol</li> <li>4-chloro-3-methylphenol</li> <li>D14: 1% propoxur solution.</li> </ul>	<p>No parasitological cure until D180. % efficacy = 0.</p> <p>Improvement of crust grades during the treatment.</p> <p>No influence of skin fold severity grades and pruritus per treatment.</p>	<p>Medium number of animals.</p> <p>One animal with negative skin scrapings on D0.</p>

†the % efficacy was calculated according to the guidelines of the Committee for Medicinal Products for Veterinary Use (2021). In the absence of a negative control group, the following formula was applied % efficacy = 100\*(total number of animals treated - number of animals still infested after treatment)/total number of animals treated. When a negative control group was present, the Abbott formula was applied: Efficacy (%) = 100 × (mc - mt)/mc with mc = mean number of live parasites on the host animals in the control group and mt = mean number of live parasites on the host animals of the treated group.

Rendle et al. (2007) compared injectable doramectin and topical fipronil, with no treatment of the environment. None of the treatments eliminated mites from all the horses, but both treatments led to a statistically significant reduction in the initial number of mites with no differences between the groups. Pruritus ceased on Day 28, but some skin lesions persisted.

## CLINICAL BOTTOM LINE

Clinical evidence is not sufficient to unequivocally answer the PICO question. Additional controlled, comparative studies using larger numbers of horses are required for clinical confirmation. No single study could claim a licence, as on the cattle (Committee for Medicinal Products for Veterinary Use, 2021a) or the sheep (Committee for Medicinal Products for Veterinary Use, 2021b) several controlled studies would be required to assess the effectiveness of a product. An untreated control group is not justified because of animal welfare reasons; therefore, comparative studies should be recommended. Of the published studies, the Littlewood et al. (1995) (ivermectin paste), Curtis (1999) (1% selenium sulphide shampoo), Osman et al. (2006) (moxidectin vs. ivermectin) and Paterson and Coumbe (2009) (5% lime sulphur) studies would meet >90% efficacy but all have significant limitations (Table 2). Most of these clinical studies were conducted over a relatively short period of time, which possibly could explain to some extent the lack of resolution of clinical signs. Equine chorioptic mange is usually a long-standing, chronic condition (Taylor et al., 2016) and it would be unrealistic to expect all clinical signs to resolve within the time frame of these studies.

Meanwhile, to maximise the chances of achieving parasitological and clinical control in draught horses with feathered distal limbs affected by chorioptic mange, it may be advisable to stable horses individually and to treat the environment, clip the feathers (despite the frequent wish of owners not to do so) and use a shampoo containing benzoyl peroxide or acetic acid/boric acid to clean the surface of the horses' legs, then apply 5% lime sulphur without rinsing, four times, at 7-day intervals. As an alternative to the last two options, 1% selenium sulphide shampoo can be applied three times at 5-day intervals and left for 10 minutes before rinsing. All other animals in contact have to be treated.

If topical therapy is not possible, a single oral dose of 400 µg/kg of moxidectin or two doses of ivermectin at 200 g/kg administered orally at a 2-week interval combined with deltamethrin applied twice in the environment 2 weeks apart could be tried. Although doramectin is routinely used in some countries such as the UK, current evidence supporting the use of doramectin as a first-line medication when the veterinarian chooses to use a systemic treatment needs further studies with larger numbers of horses.

## AUTHOR CONTRIBUTIONS

J. Kondratjeva and M.-C. Cadiergues made a major contribution to study design, search execution, analysis and interpretation of results and preparation of the manuscript. D. Combarros and C. Pressanti contributed to study design, analysis, interpretation of results and writing the manuscript. All authors approved the submission of the final version of the manuscript.

## ACKNOWLEDGEMENT

The authors thank Daphne Goodfellow for English editing.

## CONFLICT OF INTEREST

No conflicts of interest have been declared.

## ETHICAL ANIMAL RESEARCH

Ethical review is not applicable for this critically appraised topic.

## ORCID

Marie Christine Cadiergues  <https://orcid.org/0000-0001-6909-0153>

## REFERENCES

- Committee for Medicinal Products for Veterinary Use (2021a) *Guidelines on specific efficacy requirements for ectoparasiticides in cattle*. EMA/CVMP/625/03-Rev.1. European Medicines Agency - Science medicines health. Amsterdam, The Netherlands: 11.
- Committee for Medicinal Products for Veterinary Use (2021b) *Guidelines on specific efficacy requirements for ectoparasiticides in sheep*. EMA/CVMP/411/01-Rev.1. European Medicines Agency - Science medicines health. Amsterdam, The Netherlands: 9.
- Bergvall, K. (2005) Advances in acquisition, identification, and treatment of equine ectoparasites. *Clinical Techniques in Equine Practice*, 4, 296–301.
- Cremers, H.J. (1985) The incidence of *Chorioptes bovis* (Acarina: Psoroptidae) on the feet of horses, sheep, and goats in the Netherlands. *The Veterinary Quarterly*, 7, 283–289.
- Curtis, C.F. (1999) Pilot study to investigate the efficacy of a 1 per cent selenium sulphide shampoo in the treatment of equine chorioptic mange. *The Veterinary Record*, 144, 674–675.
- Littlewood, J.D., Rose, J.F. & Paterson, S. (1995) Oral ivermectin paste for the treatment of chorioptic mange in horses. *The Veterinary Record*, 137, 661–663.
- Mullen, G. & O'Connor, B. (2018) Mites (Acari) In: Mullen, G.R. & Durden, L.A. (Eds.) *Medical and Veterinary Entomology*, 3rd edition, London: Academic Press, pp. 533–602.
- Osman, S.A., Hanafy, A. & Amer, S.E. (2006) Clinical and therapeutic studies on mange in horses. *Veterinary Parasitology*, 141, 191–195.
- Paterson, S. & Coumbe, K. (2009) An open study to evaluate topical treatment of equine chorioptic mange with shampooing and lime sulphur solution. *Veterinary Dermatology*, 20, 623–629.
- Rendle, D.I., Cottle, H.J., Love, S. & Hughes, K.J. (2007) Comparative study of doramectin and fipronil in the treatment of equine chorioptic mange. *The Veterinary Record*, 161, 335–338.
- Rufenacht, S., Roosje, P.J., Sager, H., Doherr, M.G., Straub, R., Goldinger-Muller, P. et al. (2011) Combined moxidectin and environmental therapy do not eliminate *Chorioptes bovis* infestation in heavily feathered horses. *Veterinary Dermatology*, 22, 17–23.



- Scott, D.W. & Miller, W.H. (2011) Parasitic diseases. In: Scott, D.W. & Miller, W.H. (Eds.) *Equine Dermatology*, 2nd edn. Maryland Heights, Missouri, USA: Elsevier Saunders, pp. 212–250.
- Sweatman, K. (1957) Life history, non-specificity, and revision of the genus *Chorioptes*, a parasitic mite of herbivores. *Canadian Journal of Zoology*, 35, 641–689.
- Taylor, M., Coop, R. & Wall, R. (2016) Parasites of horses. In: Taylor, M., Coop, R. & Wall, R. (Eds) *Veterinary Parasitology*, 4th edn. Chichester: Wiley Blackwell. pp. 524–564.
- Yu, A.A. (2013) Equine pastern dermatitis. *The Veterinary Clinics of North America. Equine Practice*, 29, 577–588.

**How to cite this article:** Kondratjeva, J., Combarros, D., Pressanti, C. & Cadiergues, M.C. (2023) What is the most effective treatment in horses with chorioptic mange? *Equine Veterinary Education*, 35, 163–168. Available from: <https://doi.org/10.1111/eve.13637>

Continued from page 126

- Nyman, G. & Hedenstierna, G. (1989) Ventilation-perfusion relationships in the anaesthetised horse. *Equine Veterinary Journal*, 21(4), 274–281.
- Peroni, J.F., Robinson, N.E., Stick, J.A. & Derksen, F.J. (2000) Pleuropulmonary and cardiovascular consequences of thoracoscopy performed in healthy standing horses. *Equine Veterinary Journal*, 32(4), 280–286.
- Pollock, P.J. & Russell, T. (2006) Standing thoracoscopy in the diagnosis of lymphosarcoma in a horse. *The Veterinary Record*, 159(11), 354–356.
- Potchileev, I., Doroshenko, M. & Mohammed, A.N. (2022) Positive pressure ventilation. [updated 2022 Feb 9]. In: *StatPearls [internet]*. Treasure Island, FL: StatPearls Publishing. Available from: <https://www.ncbi.nlm.nih.gov/books/NBK560916/>
- Romero, A.E. & Rodgerson, D.H. (2010) Diaphragmatic herniation in the horse: 31 cases from 2001–2006. *Canadian Veterinary Journal*, 51(11), 1247–1250.
- Shawley, R.V. & Mandsager, R.E. (1990) Clinical use of positive-pressure ventilation in the horse. *The Veterinary Clinics of North America. Equine Practice*, 6(3), 575–585.
- Toth, F. & Schumacher, J. (2018) Abdominal hernias. In: Auer, J.A. & Stick, J. (Eds.) *Equine surgery*. St. Louis: Elsevier Health Sciences, pp. 654–658.

- Uquillas, E., Dart, C., Perkins, N. & Dart, A. (2017) Effect of reducing inspired oxygen concentration on oxygenation parameters during general anaesthesia in horses in lateral or dorsal recumbency. *Australian Veterinary Journal*, 96(1–2), 46–53.
- Vachon, A.M. & Fischer, A.T. (1998) Thoracoscopy in the horse: diagnostic and therapeutic indications in 28 cases. *Equine Veterinary Journal*, 30(6), 467–475.
- Youngblood, C.D., Hodgson, D.S., Beard, W.L., Song, Y., Prakash, P. & Heflin, L.V. (2020) Effect of position on transdiaphragmatic pressure and hemodynamic variables in anesthetized horses. *Canadian Journal of Veterinary Research*, 84(3), 205–211.

**How to cite this article:** Marchant, K. & Hendrickson, D. (2023) Benefits of equine thoracoscopy. *Equine Veterinary Education*, 35, 125–127. Available from: <https://doi.org/10.1111/eve.13692>

Continued from page 150

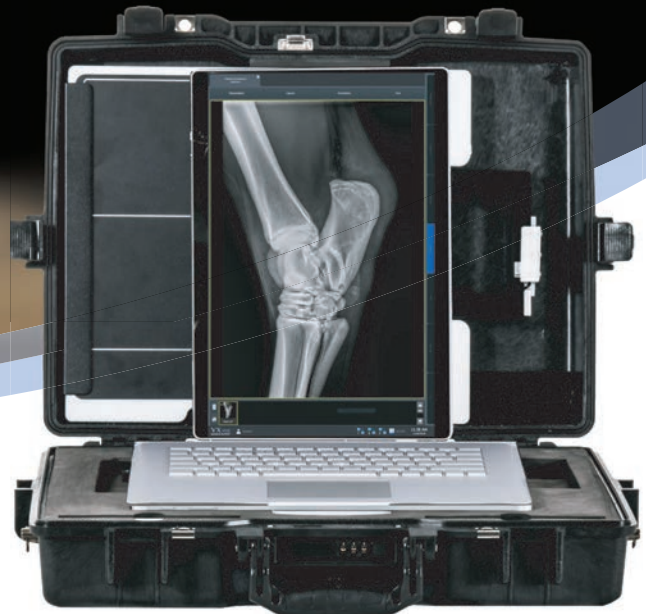- McGivney, C.L., Sweeney, J., Gough, K.F., Hill, E.W. & Katz, L.M. (2019) Serial evaluation of resting and exercising endoscopic examination results in young Thoroughbred racehorses with no treatment intervention. *Equine Veterinary Journal*, 51, 192–197.
- Mespouilhès-Rivière, C., Brandenberger, O., Rossignol, F., Robert, C., Perkins, J.D., Marie, J.P. et al. (2016) Feasibility, repeatability, and safety of ultrasound-guided stimulation of the first cervical nerve at the alar foramen in horses. *American Journal of Veterinary Research*, 77, 1245–1251.
- Radcliffe, C.H., Woodie, J.B., Hackett, R.P., Ainsworth, D.M., Erb, H.N., Mitchell, L.M. et al. (2006) A comparison of laryngoplasty and modified partial arytenoidectomy as treatments for laryngeal hemiplegia in exercising horses. *Veterinary Surgery*, 35, 643–652.
- Robinson, N.E. (2004) Consensus statements on equine recurrent laryngeal neuropathy: conclusions of the Havemeyer Workshop. September 2003, Stratford upon Avon. *Equine Veterinary Education*, 16, 333–336.

- Rossignol, F., Brandenberger, O., Perkins, J.D., Mespouilhès-Rivière, C., Marie, J.-P. & Ducharme, N.G. (2018) Modified first or second cervical nerve transplanted technique for the treatment of recurrent laryngeal neuropathy in horses. *Equine Veterinary Journal*, 50, 457–464.
- Rossignol, F. & Ducharme, N. (2021) *Reinnervation of the larynx: where are we in 2021*. In: Proceedings of the 30th ECVS Annual Scientific Meeting, Online Meeting. Proceedings published online. [www.ecvs.org](http://www.ecvs.org)

**How to cite this article:** Barakzai, S.Z. (2023) Postoperative exercising endoscopy of the equine upper respiratory tract. *Equine Veterinary Education*, 35, 143–151. Available from: <https://doi.org/10.1111/eve.13655>



EQUIPMENT  
THAT WORKS  
AS HARD AS  
YOU DO.



**You work long hours.**

All day imaging, no matter how long your day is...

Book a demo today and get a FREE 12 volt 300 watt vehicle inverter to keep all your equipment running as long as the WEPX!

FOR A FREE DEMO, CALL  
**844.483.8729**

## WEPX-V10

- Over 12 Hours of imaging time!
- Operates as a notebook or tablet
- Easy to carry briefcase design
- Glove friendly touch screen and full keyboard

SIMPLE  
DEPENDABLE  
SMART